VOLUME 24 2004

The Iowa Orthopaedic Journal

Published by the Residents and Faculty of the Department of Orthopaedics, The University of Iowa

Editors: Timothy Fowler, M.D., and Michael Sander, M.D.

THE IOWA ORTHOPAEDIC JOURNAL VOLUME 24, 2004

THE IOWA ORTHOPAEDIC JOURNAL

2004 ● Volume 24

INSTRUCTIONS TO AUTHORS, 2005

Any original article relevant to orthopaedic surgery, orthopaedic science or the teaching of either will be considered for publication in *The Iowa Orthopaedic Journal*. Articles will be enthusiastically received from alumni, visitors to the department, members of the Iowa Orthopaedic Society, residents, and friends of The University of Iowa Department of Orthopaedics and Rehabilitation. The journal is published every June. The deadline to receive articles for the 2005 edition is Friday, February 4, 2005.

Published articles and illustrations become the property of *The Iowa Orthopaedic Journal*. The journal is peer reviewed and referenced in *Index Medicus*. Articles previously published will not be accepted unless their content has been significantly changed.

When submitting an article, it is essential to include:

1. The **original manuscript complete with illustrations**. The corresponding author must be clearly identified with mailing address, telephone/fax numbers and e-mail address. Manuscripts for accepted articles will not be returned.
2. **References,** presented in the text by superscript numbers. The **bibliography** should list references in the order of their appearance in the text, and be double-spaced.
3. **Legends** for all illustrations, listed in order of appearance, and double-spaced.
4. **Illustrations**:
   a. One set of 5 x 7-inch, black-and-white, glossy prints of all photographs.
   b. Original drawings or charts.
   c. Color illustrations may not be used unless it is the opinion of the journal that they convey information not available in black and white.
5. **Electronic copies of all items one through four above**. These should be sent to diana-johannes@uiowa.edu). Special illustrations and photographs are exempt from this electronic requirement and should be mailed to the address listed below.

Preparation of manuscripts: Manuscripts must be typewritten and double spaced using wide margins. Write out numbers under 10 except percentages, degrees or numbers expressed as decimals. Direct quotations should include the exact page number on which they appeared in the book or article. All measurements should be given in SI metric units. In reporting results of surgery, only in rare instances can cases with less than two years of follow-up be accepted.

Preparation of photographs/illustrations: On the back of each photo and illustration, write the figure number, author's name and indicate the *top*. Send prints unmounted—paste or glue will damage them. Drawings, charts and lettering on prints should be done in black using white backgrounds. Put dates or initials in the legends, not on prints. Make lettering large enough to be read when drawings are reduced in size. When submitting an illustration that has appeared elsewhere, give full information about previous publication and credit to be given, and state whether or not permission to reproduce it has been obtained.

+-+-+-+-+-+-+-+

Additional copies of these instructions may be obtained by writing to Diana Johannes, University of Iowa Hospitals and Clinics, Department of Orthopaedics and Rehabilitation, 200 Hawkins Drive, 01006 JPP, Iowa City, Iowa, 52242-1088 or by emailing diana-johannes@uiowa.edu, or you may refer to the Internet site www.uihealthcare.com/depts./med/orthopaedicsurgery/reearch/ioj.html.

Printed on acid-free paper effective with Volume XV, 1995.

EDITORS' NOTE

We hope you enjoy the 2004 version of *The Iowa Orthopaedic Journal*. It represents the diligent efforts of the contributing authors and editorial staff. The *IOJ* continues to embrace the technology of the information age. *IOJ* articles are indexed on PubMed/Medline, and online full-text versions of the articles will be available soon.

For the 2004 *IOJ* we asked many of the visiting faculty over the previous year to submit articles. We would like to express special thanks to Dr. James Nunley, the 2003 Senior Resident Day discussant, and Drs. Richard and Sylvia Cruess, the 2003 Cooper Lecture Series visiting faculty, for their submissions.

The departing fifth year residents also deserve special recognition. Everyone in the department knows that the resident work area, clinics, and conferences will lose a little spark when Mark Hagy departs to Australia. No resident in this program has not asked Aimee Klapach at one time or another about the right thing to do. She is one of the most caring doctors in this institution. The candid Haft commentaries in the OR, on rounds, and in conference will not be easily replicated or replaced. New Zealand will soon hear the Haft rendition of "The Iowa Way." When Chris Sliva moves on to Detroit, we lose our Junior Spine Faculty member for morning pass-on rounds. Hopefully some of us have picked up his skill in organizing and managing busy clinical services; few balance hard work, fun, and excellent patient care better.

We owe a substantial debt of gratitude to Diana Johannes. This publication would not happen without her efforts. As the clinical volume of the Department increases, and resident work hours decrease, it would be impossible for residents to preside over every detail of the *IOJ*. Diana coordinates the advertising, communicates with the publisher, and makes sure we know what needs to be done when. She deserves as much recognition as anyone for making the *IOJ* happen. We would also like to thank our faculty advisors, Dr. Joseph Buckwalter and Dr. Jose Morcuende. Dr. Morcuende's experience as a resident here lets him understand fully the complexities of publishing the *IOJ*. He was always ready and willing to help us.

Finally, we would like to recognize our advertisers and the Department for funding the *IOJ*. Without financial support from both, you would not have this publication before you.

Timothy Fowler, M.D.
Michael Sander, M.D.

IOWA ORTHOPAEDIC JOURNAL
EDITORS EMERITI

The Michael Bonfiglio Award for Student Research in Orthopaedic Surgery

The Iowa Orthopaedic Society Medical Student Research Award for Musculoskeletal Research

The University of Iowa Department of Orthopaedic Surgery, along with the Iowa Ortho-paedic Society, sponsors two research awards involving medical students.

The first, the Michael Bonfiglio Award, originated in 1988 and was named in honor of Mike, who had an avid interest in students, teaching and research. The award is given annually at a medical convocation. It consists of a plaque and a stipend to be used for the purchase of an orthopaedic text. It is awarded to a senior medical student in the College of Medicine who has done outstanding orthopaedic research during his or her tenure as a medical student. The student often has an advisor in the Orthopaedic Department; however, the student must have played a major role in the design, implementation and analysis of the project. They must also be able to defend the manuscript in pubic forum. The research project may have been either clinical or basic science, and each study is judged on the basis of originality and scientific merit. The winner presents their work at the April meeting of the Iowa Orthopaedic Society. This year's award winner is Jesse Templeton.

The second award is the Medical Student Research Award for Musculoskeletal Re-search, for students in the College of Medicine who provide a research project involving orthopaedic surgery during one of their first three years. The award consists of a $2000 stipend, $500 of which is designated as a direct award to the student and $1500 of which is designated to help defray continuing costs of the project and its publication. The student must provide an abstract and a progress report on the ongoing research. The aim of this award is to stimulate research in the field of orthopaedic surgery/ musculo-skeletal problems.

This year, the committee, consisting of members of the Iowa Orthopaedic Society (Drs. Sterling Laaveg and Douglas Cooper) as well as members of the Orthopaedic Surgery Department (Drs. Charles Saltzman and Charles Clark), recommended that the awards be given to the two following students: George S. Oji won the Michael Bonfiglio Award for Student Research for 2004 and Benjamin R. Beecher won the Iowa Orthopaedic Society Medical Student Award for musculoskeletal research.

The Michael Bonfiglio Award and the Medical Student Research Award for Musculoskeletal Research are very prestigious, recognizing student research on the musculoskeletal system. These awards have indeed attained their goal of stimulating such research and have produced many fine projects over the years.

Charles R. Clark, M.D.
Michael Bonfiglio Professor of Orthopaedic Surgery

Department of Orthopaedics

Brian Wolf
2003-present

Michael O'Rourke
2003-present

Sergio Mendoza
2003-present

Jose Morcuende
2001-present

Annunziato Amendola
2001-present

Joseph Chen
2000-present

Todd McKinley
1999-present

R. Kumar Kadiyala
1998-2004

Leon Grobler
1996-1999

Brian Adams
1993-present

Charles Saltzman
1991-present

John Callaghan
1990-present

David Tearse
1989-2000

Ernest Found
1987-present

Lawrence Marsh
1987-present

Curtis Steyers
1985-present

James Nepola
1984-present

Fred Dietz
1984-present

James Weinstein
1983-1996

Barbara Campbell
1982-1984

Charles Clark
1980-present

William Blair
1980-1997

William Pontarelli
1980-1984,
1999-present

Joseph Buckwalter
1979-present

Thomas Lehmann
1978-1987

Arthur Steindler
1912-1949

Theodore Willis
1917-1918

Joseph Milgram
1926-1932

Ernest Freund
1932-1936

Thomas Waring
1932-1939

James Vernon Luck
1936-1939

Ignacio Ponseti
1946-present

Eberly Thornton
1946-1952

Robert Newman
1948-1956

Michael Bonfiglio
1950-1995

Carroll Larson
1950-1978

Adrian Flatt
1956-1979

Reginald Cooper
1962-present

Howard Hogshead
1964-1965

Maurice Schnell
1964-1965

Richard Johnston
1967-1970,
1998-present

Donald Kettelkamp
1968-1971

Gerald Laros
1968-1971

Richard Stauffer
1970-1972

John Albright
1971-present

Doug Mains
1972-1973

Bruce Sprague
1972-1979

Richard Brand
1974-2002

Mike Mickelson
1976-1981

Stuart Weinstein
1976-present

The University of Iowa
Roy J. and Lucille A. Carver College of Medicine

2004 GRADUATING ORTHOPAEDIC RESIDENTS

Geoffrey F. Haft, M.D.

Geoff was born in Reno, Nevada but soon moved to Billings, Montana with his parents and older brother, Paul. After high school he moved to California, and in 1995 he graduated from Stanford University with a Bachelor of Arts in human biology. He then moved up the West Coast to Portland, Oregon where he graduated from the Oregon Health & Science University Medical School.

Geoff married his high school sweetheart Angie during his second year of orthopaedic residency here at The University of Iowa, and in January of 2004 they shared the birth of their first child, Henry. In July, the Hafts will bravely take six-month-old Henry on a very long plane trip and move to Auckland, New Zealand. There, Geoff will begin a yearlong fellowship in pediatric orthopaedics at Starship Children's Hospital with Haemish Crawford. After the fellowship, the Hafts hope to return to the Rocky Mountain region.

Mark Hagy, M.D.

Mark was born and raised in Rocky Mount, Virginia and received his Bachelor of Arts degree in English and Biology from the University of Richmond. Following a career in pharmaceuticals and the building trade, he earned his medical degree from the Medical College of Virginia, Virginia Commonwealth University in Richmond.

After completing his orthopaedic residency here at The University of Iowa, he will begin a fellowship in Foot and Ankle/Sports Medicine in Sydney, Australia under the direction of Kim Slater and Merv Cross. Then he plans to return to the Blue Ridge Mountains of Virginia to begin his practice.

Mark adds that he would like to sincerely thank his wife, Karen and their children Braeton and Caroline for all their support on this journey.

Aimee S. Klapach, M.D.

Aimee was born in Reading, Pennsylvania to Paul and Kathleen Klapach. She was raised in Medford, New Jersey along with her older brother Keith.

Aimee found her way to Iowa City while she was on a high school field hockey recruiting trip and has never looked back. She attended the University of Iowa on a field hockey scholarship and received her Bachelor of Arts in biology. She then attended The University of Iowa College of Medicine and received her M.D. in 1999.

Upon completion of her orthopaedic residency here at The University of Iowa, Aimee will head back east to New York City where she will enter a sports medicine and shoulder fellowship under the direction of Drs. Russell Warren and Thomas Wickiewicz at the Hospital for Special Surgery. After completion of her fellowship, she would like to pursue an academic career.

Christopher D. Sliva, M.D.

Chris was born to parents Oscar and Mary Sliva in Lynchburg, Virginia and was raised in Galesburg, Illinois. He earned a Bachelor of Science degree at the University of Illinois at Urbana-Champaign in 1995 and subsequently attended Rush Medical College in Chicago, Illinois where he received his medical degree in 1999.

Chris and wife Heather have a one-year-old son, Nollan. This summer, the Slivas will move to Royal Oak, Michigan where Chris will pursue a fellowship in spinal surgery at William Beaumont Hospital under the direction of Dr. Harry Herkowitz.

2003-2004 FELLOWS

Pedro Fernandes, M.D.

Pedro comes from Lisbon, Portugal, the western-most country of the European Union. He was awarded his medical degree in 1991 from the University of Lisbon, followed by two years of post-graduate training at The University Hospital of Santa Maria in Lisbon where he started his orthopedic residency in 1994. His six years of orthopedic training were interrupted by a year of service in Portugal's army. During residency he was a visiting fellow in hip replacement at the Nuffield Orthopedic Centre in Oxford, England, and became a member of the Girdlestone Society.

Pedro worked in general orthopaedics at a Portuguese district hospital until 2002 when he was appointed a staff member on the spine unit at The University Hospital of Santa Maria. During this time he became a Fellow of the European Board of Orthopedics and Traumatology.

Pedro's deep interest in spinal pathology brought him to Iowa for a fellowship in spinal surgery with a special focus on pediatric spinal deformities. He, his wife and their three children appreciate the quality of life and friendly people in Iowa City and rate their experience here as outstanding.

Pamela E. Glennon, M.D.

Pamela grew up in Braintree, Massachusetts, a suburb of Boston, and attended the University of Massachusetts at Amherst where she earned her Bachelor of Science degree in microbiology. Before going on to medical school, she worked two years doing basic science research on microbial pathogenesis in the Division of Rheumatology at New England Medical Center in Boston. She then moved to Philadelphia to attend Hahnemann University School of Medicine where she earned her medical degree. Pamela came to Iowa for fellowship training in hand surgery after graduating from the orthopaedic residency program at Tufts-New England Medical Center in Boston.

Pamela and her husband Dan have thoroughly enjoyed their time in Iowa and plan to stay in the Midwest. After her fellowship ends in July, Pamela will join a private orthopaedic practice in Wausau, Wisconsin.

2003-2004 FELLOWS

Heeyoune Jung, M.D.

Heeyoune was born and raised in Pusan, the second largest city in South Korea. After she earned her medical degree from Pusan National University, she and her husband came to the United States to further their education.

Here in the United States, Heeyoune entered the Physical Medicine and Rehabilitation residency program at the Mayo Clinic in Minnesota, while her husband entered The University of Iowa for his Ph.D. In 2003 the family was finally reunited, ending four difficult years of long-distance commuting. Heeyoune is now completing her Musculoskeletal Fellowship here. She and her husband have a three-year-old boy, Jeremy.

Heeyoune is looking forward to going back to her homeland and taking an academic faculty position at her alma mater.

Lisa Wasserman, M.D.

Lisa graduated from medical school in her hometown of Saskatoon, Saskatchewan, and completed her orthopedic residency in Calgary, Alberta, Canada before starting her foot and ankle fellowship here at The University of Iowa in August 2003. Her hobbies include swimming, running, and photography.

After completion of the fellowship, she plans to return to Calgary to begin her practice specializing in foot, ankle, and lower extremity deformity reconstruction.

Phinit Phisitkul, M.D.

Phinit was born in Bangkok, the capital of Thailand. His father is a dermatologist who studied in England, and his mother received her doctorate in chemistry in England. His brothers are physicians also training in the United States.

In 1996 Phinit was awarded his medical degree with high honors from Chulalongkorn University. He completed his internship in Prajaksilla-pakom Army Hospital and became a 1st Lieutenant in the Royal Thai Army. He completed his orthopaedics residency at Phramongkutklao Hospital, receiving top scores on the orthopaedic-in-training examinations and the orthopaedic basic science examination.

After his residency, Phinit became a staff physician at the Phramongkutklao and Sulpra-sittiprasong Hospitals. Dr. Keokarn, President of the Royal College of Orthopaedics (who worked with colleagues of Dr. Michael Bonfiglio), recommended Phinit go to The University of Iowa for orthopaedic fellowships. Phinit is now finishing a sports fellowship and will begin a foot and ankle fellowship in August.

Phinit plans to return to Thailand to provide specialized orthopaedic care. He and his wife enjoy Iowa City and appreciate all that people in the Orthopaedics Department have done for them.

NEW ORTHOPAEDIC FACULTY

Michael R. O'Rourke, M.D.

A native Chicagoan, Michael O'Rourke received his medical degree from Loyola University Chicago Stritch School of Medicine in 1997. He undertook his residency in the Department of Orthopaedics and Rehabilitation at University of Iowa Hospitals and Clinics from 1997 to 2002, and his adult reconstruction fellowship at Rush University, Chicago, Illinois, from 2002 to 2003. He joined the staff at The University of Iowa in the fall of 2003.

His clinical interests include reconstructive hip and knee surgery including total joint arthroplasty, unicompartment knee arthroplasty, and revision arthroplasty. Additional clinical and research interests include the impact of minimally invasive techniques on short- and long-term outcomes following hip surgery, avascular necrosis of the hip, hip dysplasia, acetabular trauma, and management of bone loss in revision surgery.

Brian Wolf, M.D.

Brian Wolf joined The University of Iowa Department of Orthopaedics and Rehabilitation in August of 2003 as part of the Sports Medicine service. Brian and his wife Laura have two children, Jack and Brian James ("BJ").

He is originally from Rock Island, Illinois, and received his undergraduate degree at Loyola University, Chicago, where he also was a member of the men's basketball team for four years. Dr. Wolf then obtained his medical degree from Loyola Stritch School of Medicine in Maywood, Illinois in 1997. In 2002 he completed orthopaedic training at The University of Iowa and subsequently served as a fellow on the sports medicine and shoulder service at The Hospital for Special Surgery in New York before returning to Iowa City.

Brian's special interests are treatment of sports-related injuries of the shoulder, knee, and elbow. He is one of the team physicians for University of Iowa athletics. His research interests include shoulder and knee instability, rotator cuff disease, and outcomes research. Brian's current research topics include tunnel placement during ACL reconstruction, immobilization position following shoulder dislocation, and arthroscopic management of rotator cuff tears. He plans to develop an orthopaedic outcomes research program for disorders of the knee and shoulder. He is participating in the K30 Iowa Scholars in Clinical Investigation Master's program.

Outside of his practice, Dr. Wolf still enjoys playing basketball, as well as golfing and fishing.

DEPARTMENT OF ORTHOPAEDICS AND REHABILITATION
STAFF, FELLOWS AND RESIDENTS 2003-2004

Row 1: Ajay Aggarwal (res II), Mohana Amirtharajah (res II), Reginald Cooper, Joseph Buckwalter, John Albright, Matthew Lavery (res I), Michael Daines (res I)

Row 2: Frederick Dietz, Ignacio Ponseti, Pedro Fernandes (fellow), Todd McKinley, Sergio Mendoza, Tim Fowler (res IV), Michael Sander (res IV), Kevin Jones (res II), Matthew DeWall (res II), Aaron Altenburg (res II)

Row 3: Stuart Weinstein, Phinit Phisitkul (fellow), Aimee Klapach (res V), Lisa Wasserman (fellow), Ned Amendola, Kumar Kadiyala, Christina Ward (res II), Michael O'Rourke, Brian Wolf

Row 4: James Nepola, Geoffrey Haft (res V), Evan Hermanson (res III), J. Lawrence Marsh, Jose Morcuende, Ernest Found, Mark Hagy (res V), Richard Johnston, John-Erik Bell (res IV)

2004-2005
DEPARTMENT OF ORTHOPAEDICS AND REHABILITATION
SCHEDULE OF LECTURESHIPS AND CONFERENCES

(Larson Conference Room, 01090 JPP)

Carroll B. Larson Shrine Memorial Lecture
May 21-22, 2004
David P. Roye, Jr., M.D.
Director of Pediatric Orthopaedic Surgery of Morgan Stanley Children's Hospital
Livingston Professor of Pediatric Orthopaedic Surgery for Columbia University
College of Physicians & Surgeons
New York, New York

2004 Senior Residents and Fellows Day
June 11-12, 2004
David G. Lewallen, M.D.
Mayo Clinic
Rochester, MN

David B. Thordarson, M.D.
University of Southern California
Los Angeles, CA

2005 Senior Residents and Fellows Day
June 17-18, 2005*

Seventh Biennial Johnston Lectureship In Hip Reconstruction
October 15-16, 2004
Cecil Rorabeck, M.D.
James Guyton, M.D.

Hawkeye Sports Medicine Symposium
December 3-4, 2004
Anthony Miniaci, M.D., F.R.C.S.C.
Executive Director Sports Health
Cleveland Clinic Foundation
Team Physician, Cleveland Browns
Cleveland, Ohio

Mark Lovell, Ph.D., A.B.P.N.
Director, University of Pittsburgh Sports Medicine Concussion Program
Director, NFL and NHL Neuropsychology Programs
Pittsburgh, Pennsylvania

Reginald R. Cooper Orthopaedic Leadership Lectures
April, 2005*
Dr. Charles Rockwood

Iowa Orthopaedic Alumni Conference
October 29, 2004 (tentative)*

*Please check with us at a later time for exact dates, times and speakers.

DR. JOHN LAWRENCE MARSH
IOWA ORTHOPAEDIC JOURNAL DEDICATION

Dr. Marsh's office door is always open. The traffic through this door is steady, with residents seeking advice ranging from how one should treat a particular fracture to how one should plan his or her career. The questions are welcomed, and the responses thoughtful. The 2004 edition of the *Iowa Orthopaedic Journal* is dedicated to Dr. Marsh and his commitment to resident education and development.

Dr. John Lawrence Marsh came to the University of Iowa in 1987 and is currently Professor of Orthopaedic Surgery and Director of the Residency Training Program. He was born in upstate New York and received his undergraduate degree from Colgate University in 1975, and his M.D. from Syracuse in 1979. After completing a general surgery internship at Michael Reese Hospital in Chicago, Dr. Marsh entered the Boston University Affiliated Orthopaedic Residency Training Program, graduating in 1984.

Dr. Marsh is "everywhere" at the University of Iowa: Orthopaedic residency director, senior trauma staff, attending surgeon at the VA Hospital, E.T.C. Advisory Subcommittee member, to name just a few of his activities. Dr. Marsh's involvement in orthopaedic education and training, however, goes far beyond eastern Iowa. Since 1994, Dr. Marsh has served as an oral examiner for the American Board of Orthopaedic Surgery. As an active member of the American Academy of Orthopaedic Surgeons, he has served on and chaired numerous committees and professional activities. Amidst all this, Dr. Marsh has written extensively, producing many influential publications and book chapters.

His interest in improving the treatment of patients with traumatic injuries has led Dr. Marsh to conduct a series of innovative research projects. His contributions include studies of the use of external fixation devices for the treatment of tibial plafond fractures, and the results of fractures of the posterior wall of the acetabulum. His investigations of intra-articular fractures have led him to challenge one of the most hallowed tenets of fracture surgeons, that anatomic reduction of intra-articular fractures produces better long-term results, no matter how difficult or extensive the surgery needed to produce that anatomic reduction. Instead, based on his research, Dr. Marsh has proposed that in many instances minimally invasive reductions cause fewer complications and give patients equally functional or better joints. His current N.I.H.-supported investigations of intra-articular fractures will lead to further advances in the understanding and treatment of these injuries.

Left to right: Drs. Rola Rashid, Michael O'Rourke, Dan Fitzpatrick, J. Lawrence Marsh, Brian Wolf and Erin Forest.

In his "spare time", he has presided over arguably the most significant change in resident education in 50 years. Since the ACGME residency work hour rules were instituted, Dr. Marsh has served as a bridge between faculty and residents. This could be more aptly described as a tightrope at times! Over the past two years he has integrated faculty and resident concerns with the letter of the ACGME rules to allow our program to move into a new era of resident work-hour regulation. This has included practical tasks, such as adjusting the call schedule, to more sweeping changes in the philosophy of resident education. Those involved in this process know the difficulties encountered and the paradigm shifts necessary to comply with the ACGME rules.

Dr. Marsh wears two additional hats: those of husband and father. Dr. Marsh resides in nearby North Liberty and shares his life with wife, Linda, and their children, B.J. and Mackenzi. With regular invitations to "mushroom hunts" and other gatherings, residents feel welcomed into his home as well as his office.

"What would Dr. Marsh do with this?" is a question frequently asked by residents when faced with a clinical problem. Indeed, he is complimented daily by our attempts at emulation. The opportunity to dedicate this body of work to Dr. John Lawrence Marsh is an honor. His devotion to the art and science of orthopaedic surgery and to the development of those in training is unparalleled.

IMPLEMENTING CAPSULE REPRESENTATION IN A TOTAL HIP DISLOCATION FINITE ELEMENT MODEL

Kristofer J. Stewart, M.S.[*]; Douglas R. Pedersen, Ph.D.[*†]; John J. Callaghan, M.D.[*†]; and Thomas D. Brown, Ph.D.[*†]

ABSTRACT

Previously validated hardware-only finite element models of THA dislocation have clarified how various component design and surgical placement variables contribute to resisting the propensity for implant dislocation. This body of work has now been enhanced with the incorporation of experimentally based capsule representation, and with anatomic bone structures. The current form of this finite element model provides for large deformation multi-body contact (including capsule wrap-around on bone and/or implant), large displacement interfacial sliding, and large deformation (hyperelastic) capsule representation. In addition, the modular nature of this model now allows for rapid incorporation of current or future total hip implant designs, accepts complex multi-axial physiologic motion inputs, and outputs case-specific component/bone/soft-tissue impingement events. This soft-tissue-augmented finite element model is being used to investigate the performance of various implant designs for a range of clinically-representative soft tissue integrities and surgical techniques. Preliminary results show that capsule enhancement makes a substantial difference in stability, compared to an otherwise identical hardware-only model. This model is intended to help put implant design and surgical technique decisions on a firmer scientific basis, in terms of reducing the likelihood of dislocation.

Departments of *Orthopaedics and Rehabilitation and
†Biomedical Engineering
Orthopaedic Biomechanics Laboratory
University of Iowa, IA 52242, USA

Corresponding author:
Thomas D. Brown, Ph.D.
Orthopaedic Biomechanics Laboratory
University of Iowa
2181 Westlawn Bldg
Iowa City, IA, 52242-1100
Tel: 319-335-7528;
Fax: 319-335-7530;
E-mail address: tom-brown@uiowa.edu

INTRODUCTION

Finite element analysis of total hip dislocation has opened new avenues for understanding the biomechanical factors underlying this all-too-common major complication of total hip arthroplasty (THA). Dislocation, which ranks second only to wear-induced aseptic loosening as a cause of failure, affects 2% to 11% of all patients in primary series and up to 25% of patients in revision series. One third of these dislocation patients require revision surgery due to recurrence, with only 60% of those revisions achieving satisfactory stability. The propensity for dislocation is influenced by many factors: mechanical design of the implant, inappropriate implant placement, untoward hip joint motions by the patient, bony impingement, and compromise of periarticular soft tissue integrity. Unfortunately, the relative influence of individual factors on dislocation propensity is difficult to determine from *post hoc* reviews of clinical records, due to the confounding effects of implant design, surgical technique, soft tissue compromise, surgeon experience, and other variables.

Recent finite element models of THA dislocation[20-22] enable systematic study of how various total hip component design and surgical placement variables contribute to resisting the propensity for dislocation, during at-risk hip joint motions. That work has shown that improved stability (as measured by the peak moment developed to resist dislocation) comes at the expense of compromised range of motion, and conversely. To learn more about the mechanics of the dislocation process under clinically relevant circumstances, quantitative motion data from THA-age-matched (but non-implanted) human test subjects performing dislocation-prone maneuvers were subsequently implemented into this finite element formulation. Results of that study[17], which highlighted seven clinically recognized posture/motion challenges, showed an overall computationally predicted dislocation incidence of 47% if these maneuvers in THA patients were to be followed through the full motion ranges exhibited by non-implanted subjects. The authors of that study emphasized, however, that other factors being equal, their finite element formulation tended to underestimate *in vivo* stability (thus overestimating dislocation propensity), owing to its use of a worst-case scenario in terms of head size and component surgical orientation, and owing to

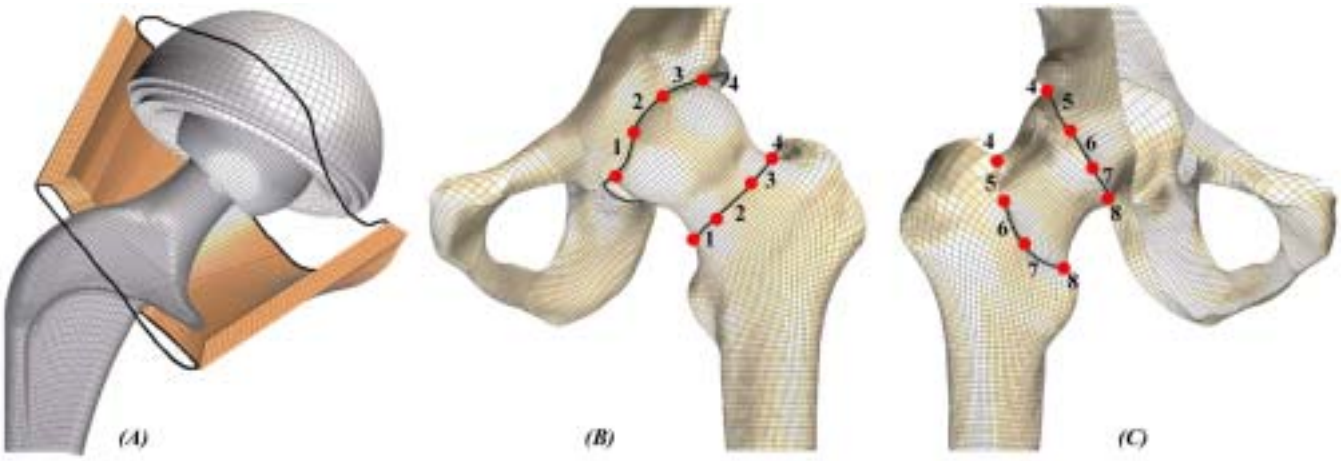

Figure 1. (A) Cut-away of the bony members, illustrating the finite element mesh of THA components and the capsule representation. The dark black lines illustrate the anatomic capsule attachment locus. (B) Anterior and (C) posterior views of the hemi-pelvis and femur finite element mesh, where the individual capsule sector definitions are identified by the red dots.

its absence of capsule representation. The availability of these unique human motion data make it feasible to systematically explore how the inclusion of capsule representation affects both dislocation kinetics and overall THA joint performance, compared to intrinsic "hardware-only" models.

The capsule is important to the stability and proper function of the hip joint. Clinical studies of hip stability primarily catalog the propensity for or treatment of dislocation following hip reconstruction[2,4,8,15,16,18,27], or less often following trauma.[6,9,14,19] Experimental studies of hip stability predominantly have explored the relationship of fracture fragment size and residual instability[4,14,26,28,30], but also have addressed the passive restraints at the extremes of motion.[29] Hewitt et al.[12,13] have recently investigated the role of joint capsule in hip stability and movement by mechanically testing individual ligaments within the capsule itself. In a related study, this group[33] has also shown that an intact posterior capsule increases (by ~2.5 times) the torque required to flex a prosthetic hip joint to dislocation. Since capsular insufficiency is well recognized clinically as predisposing to dislocation[34], incorporating capsule representation is an important next step for making THA finite element dislocation models more fully credible.

The current form of this FE model incorporates nonlinearities arising from finite-deformation multi-body contact, large displacement sliding at contact interfaces, and experimentally derived (hyperelastic) capsule representation. In addition, the modular nature of this model allows for easy incorporation of existing (or future) total hip component designs, at various positions and orientations of surgical placement. Under complex multi-axial physiologic motion inputs, the model reports case-specific component/bone/soft-tissue impingement events, as well as hardware subluxation and dislocation. The purpose of adding capsulo-ligamentous restraints to the THA dislocation finite element model is to improve the model's fidelity to the real world of patient function. This soft-tissue-augmented finite element model can potentially provide valuable new information on both the performance of implant designs for a range of clinically-representative soft tissue integrities, and information about stability differences for various surgical approaches and capsular repair techniques. Hopefully, this model can therefore help put implant design and surgical technique decisions on a firmer scientific basis in terms of reducing the likelihood of dislocation.

MATERIALS AND METHODS

For purposes of incorporating the entire hip capsule into the existing computational model (Figure 1), it was important to include the full circumferential mapping of material properties and geometry, and to unambiguously define a number of discrete sectors. This is because the forces transmitted by different portions of the capsule are entirely dependent upon the orientation of the femur relative to the acetabulum, and upon the location of any forces tending to distract the two bones (i.e., dislocate the hip). Eight individual capsule sectors were defined, as a compromise between needing to map a relatively large number of distinct circumferential locations, versus needing to have tissue samples be large enough to reliably test.

These eight capsule sectors were incorporated into the whole-joint finite element model at anatomically appropriate insertion points, using rigid body renditions of the femur and hemi-pelvis. As illustrated in Figure 2, detailed anatomic features of these bony structures were extracted from CT data, using edge-detection methods

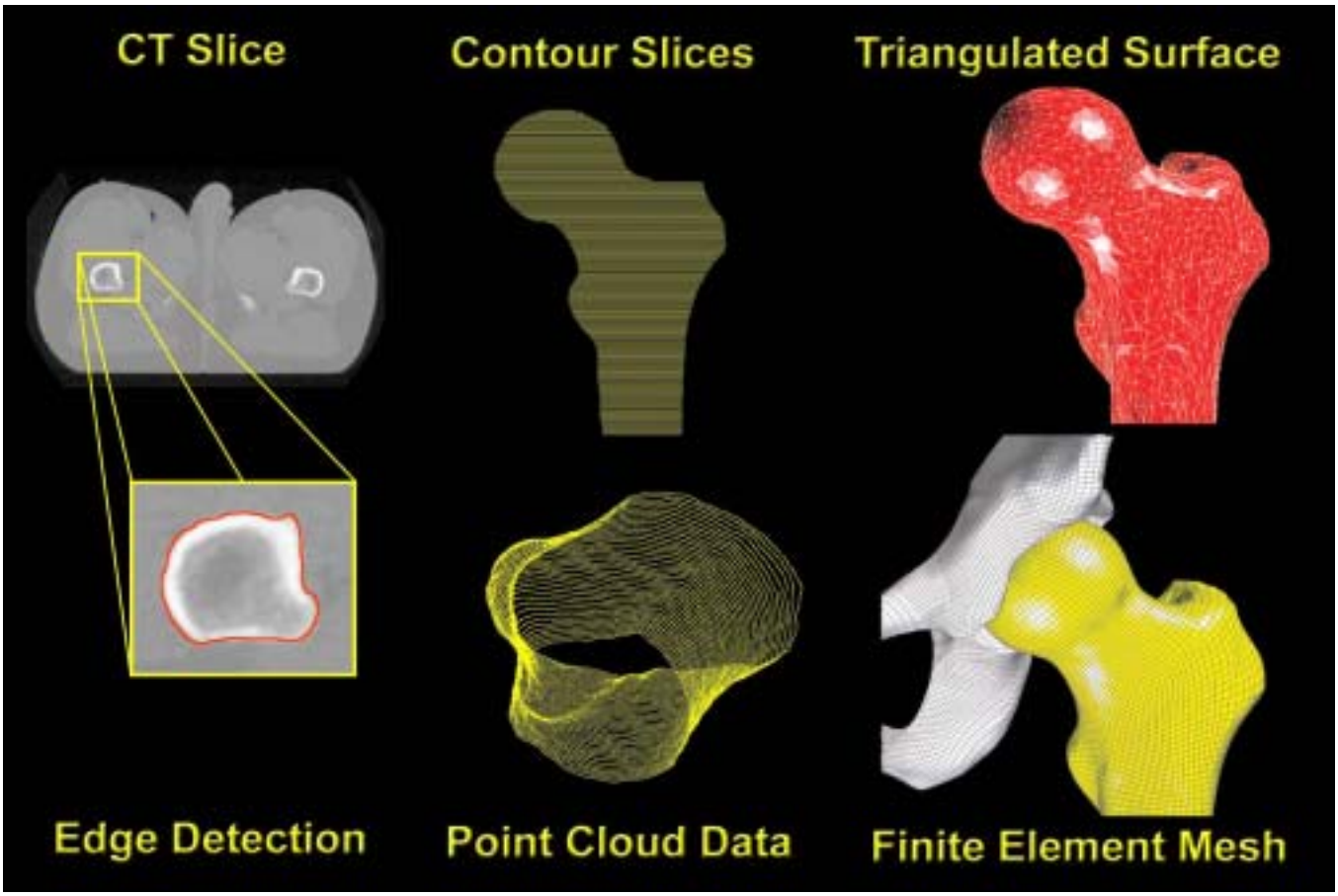

Figure 2: Full sequence of pre-processing steps, beginning with edge detection of individual CT slices. Point cloud data, which record the spatial coordinates of individual points along the detected periosteal surface, result from the accumulation of contoured slices taken at 1mm increments. A triangulated surface was then fitted to the point cloud data for each side of the joint (femur here illustrated). Finally, an all-quadrilateral finite element mesh was projected onto the triangulated surface. The same sequence is used for both the acetabular and femoral sides.

operating on 1-mm serial sections. Triangulated surfaces were fitted to the resulting point cloud data for the femur and hemi-pelvis. These surfaces, which were zoned with a three-dimensional, all-quadrilateral rigid body finite element mesh using TrueGrid's (v2.1, XYZ Scientific Applications, Inc., Livermore, CA) mesh generator, provide a quantitative spatial basis for establishing capsule attachment sites. Accurate registration of each capsule sector in this computational model was achieved using common reference points (the anatomical origin of the hip capsule near the anterior inferior iliac spine, and the insertion on the lesser trochanter) and initial geometric measurements obtained from previous experimental work.[25] Each capsule sector was meshed entirely with hexahedral continuum elements having experimentally-based material characteristics. Of the various hyperelastic material models examined, the Yeoh hyperelastic model[35] (a variation of the reduced-polynomial strain energy function) performed most satisfactorily, in terms of fitting the experimental stress-strain curves for the individual capsule sectors.

Like the earlier hardware-only dislocation models, THA components represented in this now bone/capsule/hardware finite element model consisted of three component parts: a titanium metal backing, an ultra-high molecular weight polyethylene (UHMWPE) acetabular component, and a CoCr alloy femoral component (including head and neck). The geometry adopted was that of a widely used metal-backed THA prosthesis*, with which our institution has considerable clinical and laboratory experience. The CoCr alloy of the femoral component and the titanium of the metal backing have on the order of a thousand-fold higher elastic moduli than UHMWPE. These metal components were therefore

*Endurance Stem (Size 3, Standard Offset) and Duraloc Metal Shell (2/Cluster Hole 54mm OD), Depuy Inc., Warsaw, IN.

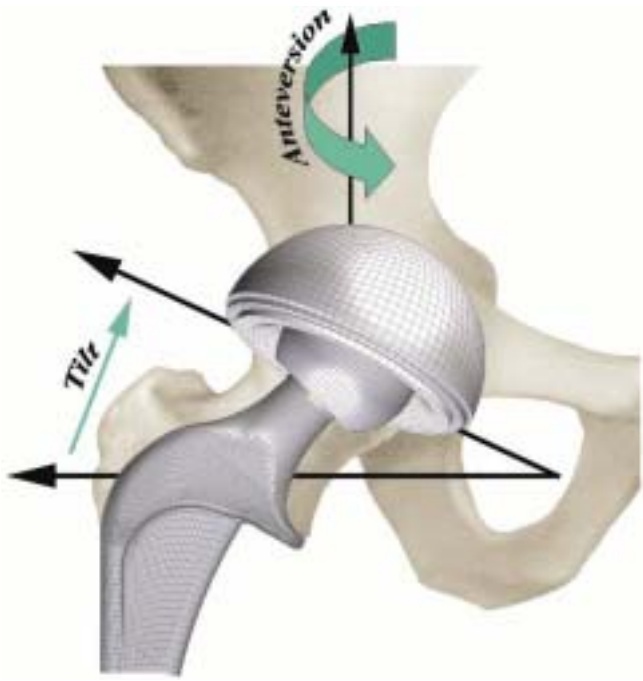

Figure 3: Finite element model surgical placement parameters: cup tilt is defined by the abduction angle from horizontal. Then rotating the 'tilted' component about the superior axis specifies cup anteversion.

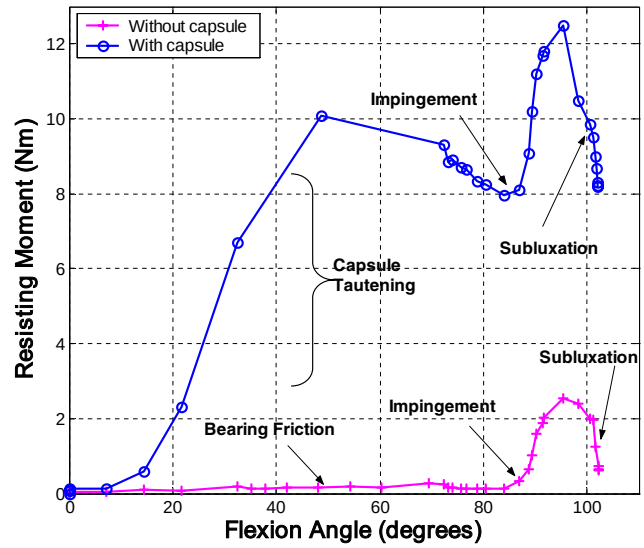

Figure 4: Femoral resisting moment comparison between hardware-only and capsule-enhanced models.

modeled and meshed as rigid bodies, composed of three-dimensional, all-quadrilateral rigid body elements. The acetabular liner was modeled as geometrically and materially nonlinear, with constitutive behaviour based on the fourth order polynomial relationship between von Mises stress and tangent modulus reported by Cripton[7], and implemented in ABAQUS by Scifert et al.[20,22]

The inclusion of hip capsule representation (in the form of eight discrete sectors) introduced the option for multiple independent contact interfaces. Due to recent contact algorithm improvements, ABAQUS/Explicit V6.3-1 (ABAQUS, INC., Pawtucket, RI) provides an efficient method for solving complex contact problems that include such multiple surface definitions. Within ABAQUS/Explicit, general contact simulations are defined by three distinct steps: (1) specifying the surfaces of the bodies that could potentially come into contact, (2) specifying which pairs of such surfaces potentially interact with one another, and (3) specifying the mechanical surface interaction phenomena that govern the behavior of such surface pairs when they are in contact. ABAQUS/Explicit contact capabilities include finite-sliding contact between deformable bodies (e.g., capsule against UHMWPE), contact between a rigid surface and a deformable body (e.g., femoral component against UHMWPE, metal backing against UHMWPE), contact between rigid surfaces (femoral component impinging against metal backing), and contact between a single deformable body and itself (i.e., infolding of individual capsule sectors). In the finite element model, the THA implant components are surrounded by eight distinct deformable capsule regions, each having individual hyperelastic material characteristics. Each such capsule sector can potentially come in contact with the metal backing, the UHMWPE, the femoral component, other capsule sectors, and/or itself, during a dislocation motion event. For all of these possible contact scenarios that could involve capsule wrap-around, ABAQUS/Explicit therefore provides the necessary contact simulation capabilities.

The ability to pre-position the THA components in numerous surgical orientations using tilt and anteversion rotations (Figure 3) provides much-needed flexibility for exploring the effects of surgically-achieved component orientation as a factor pre-disposing to dislocation. A cup placement position of 40 degrees of tilt and 10 degrees of anteversion was chosen, centrally oriented within the conventional "safe zone" for cup placement (30-50 degrees of tilt and 5-25 degrees of anteversion). A global coordinate system origin was defined at the center of the cup, using the following reference frame: X-direction being anterior, Y-direction being medial, and Z-direction being superior. Rotation of the acetabular component about the horizontal plane was performed so as to place it into a surgical orientation of 40 degrees of tilt (abduction). Then, the "tilted" component was rotated about the superior axis, to 10 degrees of anterversion. By definition, each rigid body is associated with a specific node, termed the rigid body reference node, whose motion governs the motion of

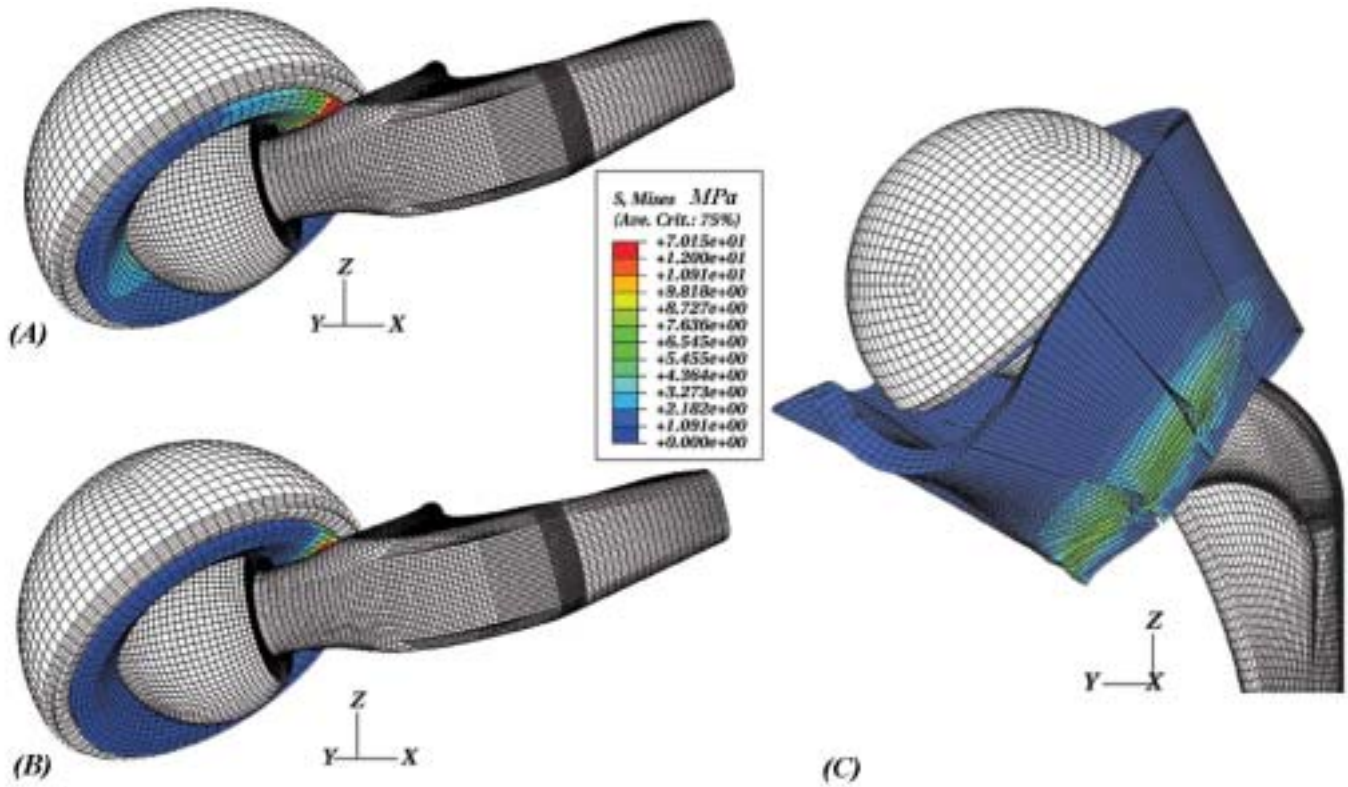

Figure 5: (A) Component-only model at an instant well into impingement, (B) component mesh of the capsule-augmented model at the same configuration, and (C) posterior view of stress contours within the capsule sectors during a low sit-to-stand maneuver.

the entire rigid body. The global origin was used to define two such rigid body reference nodes: one for the metal backing and one for the femoral component. Application of a zero displacement boundary condition (in all three coordinate directions) at the metal backing reference node kept the metal liner constrained against motion throughout the simulation. To highlight the capsule's contribution to stability, kinematics and kinetics were input for the most dislocation-prone maneuver identified by Nadzadi et al.[17]: the low sit-to-stand maneuver, as occurs when rising from a toilet. As implemented in previous models, joint loads and boundary conditions for this specific challenge maneuver were prescribed at the femoral component rigid body reference node. For preliminary validation purposes, the FE model (run using the ABAQUS/Standard v6.3-1 code) had previously been utilized to replicate the simpler situation of an intact, whole-capsule cadaveric hip tensile test[24], in which the femur (with natural femoral head) was distracted away from the acetabulum, in the direction of the femoral neck axis. The previous load-displacement and stress calculations for that simpler test were confirmed using the ABAQUS/Explicit V6.3-1 finite element code.

RESULTS

Modeling the metal backing and femoral component as rigid bodies (each controlled by an independent rigid body reference node) allowed for straightforward tracking of resultant resisting moments (Figure 4). In addition, femoral flexion was explicitly tracked. Resisting moment development as a function of angular motion input (femoral flexion angle) served as the key output metric for this study. Typical resisting moment profiles for "hardware-only" models consisted of three distinct phases: (1) an initial non-zero baseline moment (typically less than 0.2 Nm) due to bearing friction between the UHMWPE liner and the femoral head (friction coefficient = 0.038); (2) the onset (toe region of the resisting moment profile) and eventual full engagement of impingement contact (linearly increasing portion of the resisting moment profile); and (3) a subluxation phase which initiates near the peak resisting moment and is signalled by downslope of the femoral resisting moment value, until onset of computational instability (corresponding to physical dislocation). In the capsule-enhanced model, by contrast, the angular motion input was met with substantial resistance due to progressive tautening of the capsule even from the initiation of flex-

ion. This tautening resistance resulted in a dramatic increase in the resisting moment developed throughout the low sit-to-stand maneuver (see Figure 4). Once impingement occurred, there was an additional, more precipitous spike of resisting moment, roughly comparable to that seen for impingement onset in the hardware-only model. For this particular extreme maneuver, the capsule was stressed (to about 70% of its failure strength[25]). Since this taughtened tissue lies appreciably eccentric to the neck-liner impingement fulcrum, it works efficiently "in parallel" with the implant itself to resist the tendency for dislocation (Figure 5), reducing the peak polyethylene stresses at the impingement site and at the head egress site by typically 27% and 50%, respectively, relative to the hardware-only case. These preliminary results show that capsule representation provides approximately a 3.6-fold increase in construct stability, compared to an otherwise identical hardware-only construct.

DISCUSSION

The purpose of adding capsulo-ligamentous restraints to the THA dislocation model was to improve the model's applicability to the full reality of patient function. Maximal dislocation resistance of the hardware construct itself is of course absolutely desirable. However, the inclusion of the nonlinear restraints (especially, capsulo-ligamentous tautening) was felt to be likely to substantially alter dislocation kinetics. This may lead, for example, to substantially less net clinical efficacy of a specific implant design improvement than might be apparent strictly from the intrinsic hardware performance. Experience to date with hardware-only dislocation models has been that changes of individual component design parameters (e.g., liner lip bevel angle, neck taper angle, head center insert, etc.) which achieve improved stability (as measured by the peak moment developed to resist dislocation) come at the expense of compromised range of motion, or conversely. While implants can be designed to strongly favor either stability or range of motion, hardware-only finite element models provide no guidance as to which type of design is better suited to an individual patient's need, especially if capsule compromise is appreciable.

Successful application of the finite element method to studies of joint and capsule/ligament mechanics is a significant technical challenge, due to complex geometries, large deformations, multi-body contact, and the *in situ* stress that provides resting capsule tension and joint stability. In addition, realistically modeling capsule/ligament structures requires a detailed mathematical description of the material behavior. Previous finite element joint models that have incorporated ligament mechanics into their formulation have used one-dimensional ligament representations[1,3,5,11] (simple springs), two-dimensional representations[23] (isotropic plane strain quadrilateral membrane elements), and fully three-dimensional (hexahedral continuum elements) representations.[10,31,32] Using one-dimensional spring elements, the capsule material behavior can be characterized using a simple (often times nonlinear) load-elongation relationship, which greatly reduces the overall complexity of the model. Unfortunately, one-dimensional representations lack the ability to predict capsule stress distributions, and only allow joint load transfer at the discrete element attachment points (i.e., wrap-around contact between the capsule and the bone/implant is not accommodated). Two-dimensional representations are also insufficient for determining stress distributions throughout the capsule material. Since the forces transmitted by a different portion of the capsule are heavily dependent upon the orientation of the femur relative to the acetabulum, and upon the location of any forces tending to distract the two bones (i.e., dislocate the hip), it was important to make the investment of treating the capsule as a full three-dimensional continuum, with experimentally-based hyperelastic material properties.

Now that capsule inclusion in the total hip dislocation model has been achieved, an attractive application will be to undertake parametric trials of how stability-favoring versus range-of-motion-favoring implant designs perform—in terms of avoiding dislocation—under a range of clinically representative soft tissue integrities. Specific parameters of interest for such purpose include generalized capsulo-ligamentous laxity, and localized stiffness deficit (or absence) of individual ligament and/or capsule structures. These soft tissue abnormalities can be reasonably well appreciated on careful clinical examination, but there currently is no objective basis for knowing what (if anything) to do differently from case to case in terms of implant choice or targeted surgical positioning of the components. Another attractive application will be to undertake parametric series to help put surgical technique decisions on a firmer mechanical basis. Currently, several very distinct surgical approaches to the hip joint are advocated. Surgical approach is widely recognized as a factor in the different dislocation rates experienced by individual surgeons, but the arguments advanced in favor of one or another approach remain entirely subjective. (The particular approach in use at the institution where the surgeon happened to have trained, for example, is often favored simply from familiarity). A related issue is the extent of capsular excision that is appropriate during surgery. Tradeoffs for the presumed stability decrease that accompany partial or full capsule excision

include improved surgical exposure and improved range of motion. The gamut of considerations (again, subjectively based) includes complete capsule removal, posterior capsule removal, distal capsule preservation, superior capsule preservation, or complete capsule preservation. And, the effects of complete or partial incision repair could be quantified for any of these surgical approach variants. Clearly, the capsule-enhanced finite element model can introduce a much-needed source of information for objectively studying these issues, especially during the present era where novel surgical approaches are rapidly evolving for minimally invasive procedures.

ACKNOWLEDGMENTS

This study was supported in part by NIH AR46601. We wish to acknowledge the technical contributions of Dr. Anthony Petrella of DePuy, Inc and of Dr. Nicole Grosland.

REFERENCES

1. **Abdel-Rahman, E., and Hefzy, M. S.:** A two-dimensional dynamic anatomical model of the human knee joint. *J Biomech Eng,* 115(4A): 357-65, 1993.
2. **Amstutz, H. C.; Lodwig, R. M.; Schurman, D. J.; and Hodgson, A. G.:** Range of motion studies for total hip replacements. A comparative study with a new experimental apparatus. *Clin Orthop,* (111): 124-30, 1975.
3. **Andriacchi, T. P.; Mikosz, R. P.; Hampton, S. J.; and Galante, J. O.:** Model studies of the stiffness characteristics of the human knee joint. *J Biomech,* 16(1): 23-9, 1983.
4. **Bartz, R. L.; Nobel, P. C.; Kadakia, N. R.; and Tullos, H. S.:** The effect of femoral component head size on posterior dislocation of the artificial hip joint. *J Bone Joint Surg Am,* 82(9): 1300-7, 2000.
5. **Blankevoort, L.; Kuiper, J. H.; Huiskes, R.; and Grootenboer, H. J.:** Articular contact in a three-dimensional model of the knee. *J Biomech,* 24(11): 1019-31, 1991.
6. **Calkins, M. S.; Zych, G.; Latta, L.; Borja, F. J.; and Mnaymneh, W.:** Computed tomography evaluation of stability in posterior fracture dislocation of the hip. *Clin Orthop,* 227: 152-63, 1988.
7. **Cripton, P.:** Compressive characterization of ultra-high molecular weight polyethylene with applications to contact stress analysis of total knee replacements. In *Mechanical Engineering.* Edited, Kingston, Ontario, Queen's University at Kingston, 1993.
8. **Dorr, L. D.; Wolf, A. W.; Chandler, R.; and Conaty, J. P.:** Classification and treatment of dislocations of total hip arthroplasty. *Clin Orthop,* (173): 151-8, 1983.
9. **Epstein, H. C.:** Posterior fracture-dislocations of the hip; long-term follow-up. *J Bone Joint Surg Am,* 56(6): 1103-27, 1974.
10. **Gardiner, J. C., and Weiss, J. A.:** Subject-specific finite element analysis of the human medial collateral ligament during valgus knee loading. *J Orthop Res,* 21(6): 1098-106, 2003.
11. **Hefzy, M. S., and Grood, E. S.:** An analytical technique for modeling knee joint stiffness—Part II: Ligamentous geometric nonlinearities. *J Biomech Eng,* 105(2): 145-53, 1983.
12. **Hewitt, J.; Guilak, F.; Glisson, R.; and Vail, T. P.:** Regional material properties of the human hip joint capsule ligaments. *J Orthop Res,* 19(3): 359-64, 2001.
13. **Hewitt, J. D.; Glisson, R. R.; Guilak, F.; and Vail, T. P.:** The mechanical properties of the human hip capsule ligaments. *J Arthroplasty,* 17(1): 82-9, 2002.
14. **Keith, J. E.; Brashear, H. R.; and Guilford, W. B.:** Stability of posterior fracture-dislocations of the hip. Quantitative assessment using computed tomography. *J Bone Joint Surg Am,* 70(5): 711-4, 1988.
15. **McCollum, D. E., and Gray, W. J.:** Dislocation after total hip arthroplasty. Causes and prevention. *Clin Orthop,* (261): 159-70, 1990.
16. **Morrey, B. F.:** Instability after total hip arthroplasty. *Orthop Clin North Am,* 23(2): 237-48, 1992.
17. **Nadzadi, M. E.; Pedersen, D. R.; Yack, H. J.; Callaghan, J. J.; and Brown, T. D.:** Kinematics, kinetics, and finite element analysis of commonplace maneuvers at risk for total hip dislocation. *J Biomech,* 36(4): 577-91, 2003.
18. **Nicholas, R. M.; Orr, J. F.; Mollan, R. A.; Calderwood, J. W.; Nixon, J. R.; and Watson, P.:** Dislocation of total hip replacements. A comparative study of standard, long posterior wall and augmented acetabular components. *J Bone Joint Surg [Br],* 72(3): 418-22, 1990.
19. **Pantazopoulos, T.; Nicolopoulos, C. S.; Babis, G. C.; and Theodoropoulos, T.:** Surgical treatment of acetabular posterior wall fractures. *Injury,* 24(5): 319-23, 1993.
20. **Scifert, C. F.; Brown, T. D.; and Lipman, J. D.:** Finite element analysis of a novel design approach to resisting total hip dislocation. *Clin Biomech (Bristol, Avon),* 14(10): 697-703, 1999.

21. **Scifert, C. F.; Brown, T. D.; Pedersen, D. R.; and Callaghan, J. J.:** A finite element analysis of factors influencing total hip dislocation. *Clin Orthop,* 355: 152-62, 1998.
22. **Scifert, C. F.; Brown, T. D.; Pedersen, D. R.; Heiner, A. D.; and Callaghan, J. J.:** Development and physical validation of a finite element model of total hip dislocation. *Computer Methods in Biomechanics and Biomedical Engineering,* 2: 139-147, 1999.
23. **Simbeya, K. W.; Shrive, N.; Frank, C. B.; and Matyas, J. R.:** A micromechanical finite element model of rabbit medial collateral ligament. *Recent Advances in Computer Methods in Biomechanics and Biomedical Engineering.*: 240-249, 1992.
24. **Stewart, K.; Pedersen, D.; Brand, R.; and Brown, T.:** Hyperelastic representation of hip joint capsule: a finite element validation. *Proceedings of the Orthopaedic Research Society*. New Orleans, LA, 2003.
25. **Stewart, K. J.; Edmonds-Wilson, R. H.; Brand, R. A.; and Brown, T. D.:** Spatial distribution of hip capsule structural and material properties. *J Biomech,* 35(11): 1491-8, 2002.
26. **Thomas, K. A.; Vrahas, M. S.; Noble, J. W.; Bearden, C. M.; and Reid, J. S.:** Evaluation of hip stability after simulated transverse acetabular fractures. *Clin Orthop,* (340): 244-56, 1997.
27. **Turner, R. S.:** Postoperative total hip prosthetic femoral head dislocations. Incidence, etiologic factors, and management. *Clin Orthop,* (301): 196-204, 1994.
28. **Vailas, J. C.; Hurwitz, S.; and Wiesel, S. W.:** Posterior acetabular fracture-dislocations: fragment size, joint capsule, and stability. *J Trauma,* 29(11): 1494-6, 1989.
29. **Vrahas, M. S.; Brand, R. A.; Brown, T. D.; and Andrews, J. G.:** Contribution of passive tissues to the intersegmental moments at the hip. *J Biomech,* 23(4): 357-62, 1990.
30. **Vrahas, M. S.; Widding, K. K.; and Thomas, K. A.:** The effects of simulated transverse, anterior column, and posterior column fractures of the acetabulum on the stability of the hip joint. *J Bone Joint Surg Am,* 81(7): 966-74, 1999.
31. **Weiss, J. A., and Gardiner, J. C.:** Computational modeling of ligament mechanics. *Crit Rev Biomed Eng,* 29(3): 303-71, 2001.
32. **Weiss, J. A.; Gardiner, J. C.; and Bonifasi-Lista, C.:** Ligament material behavior is nonlinear, viscoelastic and rate-independent under shear loading. *J Biomech,* 35(7): 943-50, 2002.
33. **Wellman, S.; Hewitt, J.; Glisson, R.; Guilak, F.; and Vail, T. P.:** An intact posterior hip capsule increases resistance to dislocation in a cadaveric model of total hip arthroplasty. *Proceedings of the Orthopaedic Research Society,* pp. 0989. Dallas, TX, 2001.
34. **Woo, R. Y., and Morrey, B. F.:** Dislocations after total hip arthroplasty. *J Bone Joint Surg Am,* 64(9): 1295-306, 1982.
35. **Yeoh, O. H.:** Characterization of elastic properties of carbon-black-filled rubber vulcanizates. *Rubber Chemistry and Technology,* 63(5): 792-805, 1990.

PROFESSIONALISM FOR MEDICINE: OPPORTUNITIES AND OBLIGATIONS*

Sylvia R. Cruess, Sharon Johnston, and Richard L. Cruess

ABSTRACT

- **Physicians' dual roles—as healer and professional—are linked by codes of ethics governing behaviour and are empowered by science.**
- **Being part of a profession entails a societal contract. The profession is granted a monopoly over the use of a body of knowledge and the privilege of self-regulation and, in return, guarantees society professional competence, integrity and the provision of altruistic service.**
- **Societal attitudes to professionalism have changed from supportive to increasingly critical—with physicians being criticised for pursuing their own financial interests, and failing to self-regulate in a way that guarantees competence.**
- **Professional values are also threatened by many other factors. The most important are the changes in healthcare delivery in the developed world, with control shifting from the profession to the State and/or the corporate sector.**
- **For the ideal of professionalism to survive, physicians must understand it and its role in the social contract. They must meet the obligations necessary to sustain professionalism and ensure that healthcare systems support, rather than subvert, behaviour that is compatible with professionalism's values.**

Centre for Medical Education, McGill University, Montreal, Quebec, Canada.
Sylvia R Cruess, MD
Associate Professor of Medicine; and
Member, Centre for Medical Education

Sharon Johnston, LLM
Medical Student
Dartmouth Medical School
Hanover, New Hampshire

Richard L Cruess, MD
Professor of Surgery; and
Member, Centre for Medical Education

***Cruess SR et al. Professionalism for medicine: opportunities and obligations. MJA 2002; 177: 208-211.**

A distinguished journalist has stated that with globalisation has come "a sense that your job, community, or work place can be changed at any moment by anonymous economic and technological forces that are anything but stable".[1] Medicine has not escaped this phenomenon. In developed countries it has changed in one or two generations from a cottage industry to one consuming a significant portion of each country's gross domestic product. Solo practice has become rare, new payment methods have appeared, primary care and specialised medicine have become more complex, and public expectations have altered dramatically. In all parts of the developed world physicians have had to adapt to a new and sometimes unfamiliar world work environment. Most have three concerns:

- their ability to provide quality care;
- the threats to their clinical autonomy; and
- the survival of the values to which they committed themselves when they recited the Hippocratic Oath or its modern equivalent.[2,3]

Among the many responses of the medical profession to the present situation has been an effort to rearticulate and re-emphasise the values that have traditionally characterised medicine.

In society, the physician fills two roles—that of a healer and a professional.[4] In the Western world, the healing tradition goes back to Hellenic Greece, and the Hippocratic Oath (or its modern derivative) has long been an important part of the self-image of the physician.[5] The professions have their origins in the guilds and universities of medieval Europe and England. During these times physicians served only the élite, until the Industrial Revolution provided sufficient wealth for healthcare to be purchased, and science made it worth purchasing.[4-9] The two roles of physicians are linked by codes of ethics governing their behaviour in both roles, and by science which empowers both roles.

WHAT IS A PROFESSION?

A working definition of "profession" from the *Oxford English Dictionary*,[10] with elements drawn from the literature, is:

> An occupation whose core element is work, based on the mastery of a complex body of knowledge and skills. It is a vocation in which knowledge of some department of science or learning, or the practice of an art

> founded on it, is used in the service of others. Its members profess a commitment to competence, integrity, morality, altruism, and the promotion of the public good within their domain. These commitments form the basis of a social contract between a profession and society, which in return grants the profession autonomy in practice and the privilege of self-regulation. Professions and their members are accountable to those served and to society.

The contract between professions and society is relatively simple. The professions are granted a monopoly over the use of a body of knowledge, as well as considerable autonomy, prestige, and financial rewards—on the understanding that they will guarantee competence, provide altruistic service, and conduct their affairs with morality and integrity. In outlining the characteristics of a profession, the obligations which the profession acquires will be linked with each characteristic.

The complexity of the knowledge base

There is general agreement that the *raison d'être* for professions is the complexity of the specialised knowledge which each profession controls.[6-8] In spite of modern information technology, this knowledge is not easily understood by the public, and consequently the professions are given substantial control over its use. In this, they acquire responsibility for its integrity, for its proper application, and for its expansion, which, for medicine, means the support of science. Finally, professions have an obligation to transmit their knowledge by teaching it to future practitioners, the general public, and their patients.

Service

The knowledge is used in the service of others. For almost two millennia, physicians used their knowledge primarily to benefit individual patients. The complexity and cost of healthcare during the past quarter-century have resulted in medicine acquiring an obligation to serve the wider society as well, involving such issues as access to healthcare and a just distribution of finite resources.[11]

Altruism

There is agreement that the trust placed in the professions[12] and their privileged status are only justified by the expectation that they will be altruistic. For physicians this means consistently placing the interests of individual patients and society above their own.[7,13,14] Professions must be devoted to the public good.

Autonomy

Another important characteristic of a profession is autonomy. Individually, physicians are granted sufficient autonomy to act in the best interests of their patients.[7,8] Until late in the 20th century, autonomy was expressed in a paternalistic fashion, but modern society, recognising patient autonomy, now views the physician–patient relationship as a partnership.[15]

The profession is also granted collective autonomy through self-regulation.[4,6-8] It has the privilege and obligation to set and maintain standards for education and training, entry into practice, and the standards of practice. It must guarantee the competence of its practitioners, and has an absolute obligation to discipline unprofessional, incompetent, or unethical conduct.

Professional associations

Professional associations and licensing bodies are characteristic of all professions.[4,7] They operate with State-sanctioned authority, which may be altered if society becomes dissatisfied with their performance. Collegiality helps to establish common goals and encourage compliance with them.[16] Their role in self-regulation is major, as is the expectation that they will advise the public as experts in their domain. The associations and licensing bodies have a primary role in guaranteeing the quality of healthcare services.

Medical associations also have an obligation to protect the interests of their individual members. The two roles can conflict and professional associations have not always managed this conflict wisely, being seen to ignore the public's interests in favour of their own.[3,17] This has contributed to a loss of trust in all professions, including medicine.[12] Because the function of professional associations is so important, they require the support of their members. Individual physicians are responsible for the actions of their associations.

Accountability

For centuries, physicians were accountable to their patients and to their profession.[2,7,15,18] The importance of modern healthcare to society's well-being, coupled with its cost, has engendered a new accountability at economic and political levels.[19] Thus, physicians continue to be accountable for patient care and self-regulation, while acquiring accountability for the financial impact of their decisions and for the health and the well-being of populations.[19,20]

Morality and integrity

The professions are expected to be moral, ethical, and carry out their activities with integrity.[13,14,18] Indeed, professionalism has been defined as "an ideal to be pursued",[18] recognising that physicians will not always meet all of the conditions required, but must continually strive to do so.

Not only are individual physicians expected to demonstrate morality and virtue, but so are the institutions which represent them.[21] Thus, professional associations and licensing bodies must not engage in activities which detract from the morality and integrity of the profession. Finally, morality and virtue must be integral to the rules, processes and procedures by which medicine governs and regulates itself.[22]

Codes of ethics

All professions have developed codes of ethics which govern the behaviour of their members[6,8] and represent the applied morality of the profession. They serve as guidelines for the behaviour of their members and as an important part of the public's expectations of the profession.

THE EVOLUTION OF THE CONCEPT OF THE PROFESSIONS

The literature on the professions is extensive, but, until recently, was found almost exclusively in the social sciences and philosophy, and thus was difficult for physicians to access. This is unfortunate, because there were times when the literature was highly critical of the medical profession. It both reflected and helped to shape public opinion and public policy, and physicians were unaware of its impact on the perception of the profession. In the past decade, analyses have appeared in publications readily accessible to physicians.[4,23-28]

From the early 1900s until the 1950s, the literature was supportive of the concept of professionalism.[29-34] It described the professions, the rationale for their being, and stressed the service commitment of individual professionals. It recognised the conflict between altruism and self-interest, but believed that commitment to service would result in altruistic behaviour.

In the questioning society of the 1960s,[7,8,35-39] the literature changed. It asserted that physicians exploited their monopoly to create a demand for services which they then satisfied.[37,39] It identified serious failures in self-regulation,[7,35,39] and abuse of collegiality to protect incompetent or unethical physicians. It criticised physicians for pursuing their own financial interests at the expense of both individual patients and society. Finally, it questioned the benefits of professionalism to society.[35-37,39]

With the growing importance of governments and the corporate sector in healthcare, the literature of the past two decades has shown a significant shift.[6,13,18,22] It documents the fact that medicine has lost control over the medical marketplace, no longer dictating its structure, methods of payment, or levels of remuneration.[20] Depending on the country, control shifted from the profession to the State and/or the corporate sector. Social scientists recognised that organising healthcare around models based on either State or corporate control imposes different goals and values from models which are structured around professionalism. They have returned to support the "professional model"[22] as being more value laden, but remain unanimous that professionalism must be devoted to the public good—one observer calls it "civic professionalism".[13]

THE CHALLENGES OF THE FUTURE

The changes in healthcare systems throughout the developed world have been dramatic, resulting in medicine having diminished input into major policy decisions by the State and corporate sector.[8,20] The increased complexity and cost of modern medicine undoubtedly made this inevitable, but the consequences for the profession have been substantial. The application of "accounting logic"[20] to the practice of medicine has intruded into the autonomy of individual practitioners.[6,11,17] As the profession participated in the process of renegotiating its social contract with society, it has been at a disadvantage and has not done so effectively. The negotiations appear to primarily concern methods and amounts of remuneration, as well as patterns of practice, but there is evidence that physicians are as worried about the values of their profession as about financial issues.[40] Thus far, values do not seem to have been a distinct issue at the negotiating table.

The principal threats to medicine's professional status come from public mistrust of the profession as a whole. Two major factors contribute to this mistrust—public perception that medicine failed to self-regulate in a way that can guarantee competence, and that it put its own interest above that of patients and the public.[13,17,22] The well-publicised Bristol affair,[41] and the reports on medical errors in Australia[42] and the United States,[43] have contributed to the belief that medicine has protected incompetent or unethical colleagues in the name of collegiality. This belief persists in spite of regulatory procedures becoming more rigorous and more open.

Medicine's reputation for altruism was easier to maintain before the advent of national health services. The tradition of caring for those who could not afford medical care was strong. The virtual disappearance of the

truly medically indigent patient in most developed countries, and the necessity to negotiate for both levels of remuneration and details of practice, have accentuated this problem. In addition, the dual role of medical associations[8,17,44]—acting as expert advisors on matters of health as well as representing their members—has created a difficult conflict of roles. The literature on professionalism is surprisingly kind to the motivation and performance of individual doctors, but is highly critical of the performance of medical associations.[6,8,22]

Can the ideal represented by professionalism be preserved in a way that will give continued meaning to the practice of medicine? There are reasons for hope.[13,17,22,45] As control of healthcare has passed from medicine to the State and the corporate sector, so has the blame for defects in the healthcare system. Patients remain attached to their physicians and do not wish either the State or corporate sector to make decisions about their care. The public and physicians share a view of the changes needed in healthcare systems.[6] Thus, there is an opportunity for medicine to rebuild trust.

Opportunities for action

Medicine has several opportunities for action.

- Because professionalism is at the core of medicine's social contract, physicians must understand the origins and nature of professional status, and the obligations necessary to sustain it. Professionalism must be taught explicitly, and those serving as role models require detailed knowledge of professionalism.[4,23] The growing medical literature on how to teach and evaluate professionalism,[4,23-28] the initiatives taken by educational and certifying bodies[26,46,47] and the important recent elaboration of an "International Charter on Professionalism"[48] aid in this venture.
- Medicine's professional associations must be extremely wise in how they negotiate for their members.[17] Any hint that the public good is being ignored during these negotiations can be damaging to the credibility of the profession and result in loss of the trust, which is so essential to the healing process.[3]
- The privilege of self-regulation entails an absolute obligation to guarantee the competence of members. The setting and maintenance of standards is of overriding importance, and issues such as recertification and revalidation are, without question, now regarded as professional obligations. The disciplining of unethical or incompetent practitioners must be rigorous, open, and have the support of every practising physician. A heavy price has already been paid for failures in this domain.
- Individual physicians must consider the consequences of being seen to put self-interest above that of their patient. Altruism and ethical conduct must serve as the backdrop against which medicine is practised.
- Even if the medical profession itself carries out the above actions, it is unlikely that the values cherished by physicians for centuries can be preserved unless their preservation is encouraged and supported by society through the structure of the healthcare system. Healthcare systems can actively promote desirable behaviour or they can encourage physicians to place their own interest first. If undue competition among physicians is promoted by the system, one should not be surprised if competitive physician-entrepreneurs emerge. If medical manpower policies coupled with payment methods actively encourage physicians to see large numbers of patients to maintain an adequate income, they will do so. Physicians will maintain professional values, but not at any price.[49] Thus, the support of policy makers in preserving a value-based healthcare system becomes critical.[50] For this to occur, the issue must be considered to be important by those negotiating on behalf of the profession.

In closing, it is worthwhile to quote William Sullivan, a prominent medical sociologist: "Neither economic incentives nor technology nor administrative control has proved an effective surrogate for the commitment to integrity evoked in the ideal of professionalism."[13] Without question, the medical profession itself wishes to function within a system dominated by a healthy and flourishing professionalism. As Sullivan[22] and Freidson[50] point out, there should also be substantial advantages to society in preserving professionalism as an effective value-based system. The original reason for the use of the profession as a means of organising healthcare was because of the complexity of the knowledge base, the difficulty in regulating it, and the presumption that the profession would be altruistic and devoted to the public good. We believe that nothing in the past 150 years has altered that fact. Thus, both society and the profession should wish for the same type of physician—competent, moral, idealistic, and altruistic. This is best guaranteed by a healer functioning as a respected professional.

COMPETING INTERESTS

None identified

ACKNOWLEDGEMENTS

We acknowledge funding from the McConnell Family Foundation, Montreal, QC, Canada.

REFERENCES

1. **Friedman T.** The lexus and the olive tree: understanding globalization. New York: Anchor Books, 2000: 12.
2. **Dunning AJ.** Status of the doctor—present and future. *Lancet* 1999; 354 Suppl IV: 18.
3. **Edwards N, Kornacki MJ, Silversin J.** Unhappy doctors: what are the causes and what can be done? *BMJ* 2002; 324: 835-838.
4. **Cruess RL, Cruess SR.** Teaching medicine as a profession in the service of healing. *Acad Med* 1997; 72: 941-952.
5. **Sohl P, Bessford R.** Codes of medical ethics: traditional foundations and contemporary practice. *Soc Sci Med* 1980; 22: 1175-1179.
6. **Krause E.** Death of the guilds: professions, states and the advance of capitalism, 1930 to the present. New Haven: Yale University Press, 1996.
7. **Freidson E.** Professional dominance: the social structure of medical care. Chicago: Aldine, 1970.
8. **Starr P.** The social transformation of American medicine. New York: Basic Books, 1984.
9. **Willis R.** The medical profession in Australia. In: Hafferty FW, McKinlay JB, editors. The changing medical profession: an international perspective. New York: Oxford University Press, 1993: 104-115.
10. Oxford English Dictionary. 2nd ed. Oxford: Clarendon Press, 1989.
11. **Ham C, Alberti KG.** The medical profession, the public, and the government. *BMJ* 2002; 324: 838-842.
12. **Mechanic D.** Changing medical organization and the erosion of trust. *Milbank Q* 1996; 74: 171-189.
13. **Sullivan W.** Work and integrity: the crisis and promise of professionalism in North America. New York: Harper Collins, 1995: 16.
14. **Perkin H.** The rise of professional society: England since 1880. London: Routledge, 1989.
15. **Pellegrino ED.** Trust and distrust in professional ethics. In: Pellegrino ED, Veatch RM, Langen JP, editors. Ethics, trust, and the professions. Washington, DC: Georgetown University Press, 1991: 69-85.
16. **Ihara CK.** Collegiality as a professional virtue. In: Flores A, editor. Professional ideals. Belmont, CA: Wadsworth, 1988: 56-65.
17. **Stevens R.** Public roles for the medical profession in the United States: beyond theories of decline and fall. *Milbank Q* 2001; 79: 327-353.
18. **Kultgen JH.** Ethics and professionalism. Philadelphia: University of Pennsylvania Press, 1988.
19. **Emanuel EJ, Emanuel LL.** What is accountability in health care? *Ann Intern Med* 1996; 124: 229-239.
20. **Moran M, Wood B.** States, regulation and the medical profession. Buckingham: Open University Press, 1993.
21. **Pellegrino ED, Relman A.** Professional medical associations: ethical and practical guidelines. *JAMA* 1999; 282: 1954-1956.
22. **Freidson E.** Professionalism reborn: theory, prophecy and policy. Cambridge, UK: Polity Press, 1994.
23. **Cruess SR, Cruess RL.** Professionalism must be taught. *BMJ* 1997; 315: 1674-1677.
24. **Cruess RL, Cruess SR, Johnston SE.** Renewing professionalism: an opportunity for medicine. *Acad Med* 1999; 74: 878-884.
25. **Cruess RL, Cruess SR, Johnston SE.** Professionalism—an ideal to be pursued. *Lancet* 2000; 365: 156-159.
26. **Irvine D.** The performance of doctors: the new professionalism. *Lancet* 1999; 353: 1174-1177.
27. **Wynia MK, Latham SR, Kao AC,** et al. Medical professionalism in society. *N Engl J Med* 1999; 341: 1612-1616.
28. **Swick HM.** Towards a normative definition of professionalism. *Acad Med* 2000; 75: 612-616.
29. **Webb S, Webb B.** Professional associations. *New Statesman* 1917; 9 (Suppl): 7-19.
30. **Tawney RH.** The acquisitive society. New York: Harcourt Brace, 1920.
31. **Flexner A.** Is social work a profession? *School and Society* 1915; 1(26): 901-911.
32. **Brandeis L.** Business—a profession. Boston: Hole, Cushman and Flint, 1933.
33. **Carr-Saunders AM, Wilson PA.** The professions. Oxford: Clarendon Press, 1933.
34. **Parsons T.** The professions and social structure. *Social Forces* 1939; 17: 457-467.
35. **Freidson E.** Profession of medicine: a study of the sociology of applied knowledge. New York: Dodd and Mead, 1970.
36. **McKinlay J.** Towards proletarianization of physicians. In: Derber E, editor. Professionals as workers: mental labor in advanced capitalism. Boston: G K Hall, 1982: 37-62.
37. **Larson M.** The rise of professionalism: a sociological analysis. Berkeley: University of California Press, 1977.
38. **Haug M.** Deprofessionalization: an alternate hypothesis for the future. *Sociol Rev Monogr* 1973; 20: 195-211.
39. **Johnson T.** Professions and power. London: Macmillan Press, 1972.
40. **Blendon RJ, Schoen C, Donelan K,** et al. Physicians' views on quality of care—a five-country comparison. *Health Aff* 2001; 20: 233-243.
41. **Smith R.** All changed, changed utterly. British medicine will be transformed by the Bristol case. *BMJ* 1993; 316: 1917-1918.

42. **Wilson RM, Runciman WB, Gibberd RW,** et al. The quality in Australian Health Care Study. *Med J Aust* 1995; 163: 458-471.
43. To err is human: building a safer health system. Washington, DC: National Academy Press, 2000.
44. **Berwick TN.** Medical associations, guilds or leaders. *BMJ* 1997; 314: 1564-1565.
45. **Southon G, Braithwaite J.** The end of professionalism? *Soc Sci Med* 1998; 46: 23-28.
46. **American Board of Internal Medicine.** Project professionalism. Philadelphia: ABIM, 1995.
47. **Association of American Medical Colleges.** Professionalism in contemporary medical education: an invitational colloqium. Washington, DC: AAMC, 1998.
48. Medical professionalism in the new millennium: a physicians' charter. *Lancet* 2002; 359: 520-522 [and *Ann Intern Med* 2002; 136: 243-246.]
49. **Casalino LP.** The unintended consequences of measuring quality on the quality of care. *N Engl J Med* 1999; 341: 1147-1150.
50. **Freidson E.** Professionalism: the third logic. Chicago: University of Chicago Press, 2001.

OXYGEN EFFECTS ON SENESCENCE IN CHONDROCYTES AND MESENCHYMAL STEM CELLS: CONSEQUENCES FOR TISSUE ENGINEERING

Farid Moussavi-Harami, Yazan Duwayri, James A. Martin, Farshid Moussavi-Harami, Joseph A. Buckwalter

ABSTRACT

Primary isolates of chondrocytes and mesenchymal stem cells are often insufficient for cell-based autologous grafting procedures, necessitating *in vitro* expansion of cell populations. However, the potential for expansion is limited by cellular senescence, a form of irreversible cell cycle arrest regulated by intrinsic and extrinsic factors. Intrinsic mechanisms common to most somatic cells enforce senescence at the so-called "Hayflick limit" of 60 population doublings. Termed "replicative senescence", this mechanism prevents cellular immortalization and suppresses oncogenesis. Although it is possible to overcome the Hayflick limit by genetically modifying cells, such manipulations are regarded as prohibitively dangerous in the context of tissue engineering. On the other hand, senescence associated with extrinsic factors, often called "stress-induced" senescence, can be avoided simply by modifying culture conditions. Because stress-induced senescence is "premature" in the sense that it can halt growth well before the Hayflick limit is reached, growth potential can be significantly enhanced by minimizing culture related stress. Standard culture techniques were originally developed to optimize the growth of fibroblasts but these conditions are inherently stressful to many other cell types. In particular, the 21% oxygen levels used in standard incubators, though well tolerated by fibroblasts, appear to induce oxidative stress in other cells. We reasoned that chondrocytes and MSCs, which are adapted to relatively low oxygen levels *in vivo*, might be sensitive to this form of stress. To test this hypothesis we compared the growth of MSC and chondrocyte strains in 21% and 5% oxygen. We found that incubation in 21% oxygen significantly attenuated growth and was associated with increased oxidant production. These findings indicated that sub-optimal standard culture conditions sharply limited the expansion of MSC and chondrocyte populations and suggest that cultures for grafting purposes should be maintained in a low-oxygen environment.

Department of Orthopaedics and Rehabilitation
The University of Iowa

INTRODUCTION

Cell based tissue-engineered grafts offer promising options for the repair and regeneration of bone and hyaline cartilage at sites of osteochondral injury. Because they are created using a patient's own cells, engineered grafts minimize rejection and infection hazards, making them an attractive alternative to conventional allografts.[2,3,4,5] Cell based grafts consisting of chondrocytes seeded on various scaffold materials have been used successfully to repair full-thickness osteochondral lesions.[7,8,14] More recently, bone marrow-derived mesenchymal stem cells (MSCs) have been used to promote the repair of bone and cartilage defects.[6,15,26] These cells are relatively easy to isolate from iliac crest aspirates and differentiate readily into chondrocyte-like and osteoblast-like cells both *in vitro* and *in vivo*.[17,18,19,22]

Partly because of the potential for damage caused by culture or storage conditions, fresh MSCs and chondrocytes are commonly preferred for engraftment procedures. However, the ability to safely expand cell populations *in vitro* and to store cells for later use is of great practical advantage to tissue engineers. The *in vitro* expansion of cells over time is calculated in terms of cumulative population doublings (PD). The population-doubling limit (PDL) marks the cessation of growth brought on by irreversible arrest of the cell cycle (cell senescence). Somatic cells that lack telomerase activity, inevitably senesce due to the normal process of telomere erosion. This process, termed "replicative senescence", is the basis of the Hayflick limit that arrests growth after approximately 60 PD.[1,9,11] Telomerase activation *via* ectopic expression of the human telomerase reverse transcriptase subunit (hTERT) prevents replicative senescence by continuously maintaining telomere length.[25] While hTERT expression is sufficient to immortalize human fibroblasts under standard culture conditions, other "telomerized" cell types, including chondrocytes, undergo growth arrest.[10,13,20] Such cells appear to senesce in response to stress, a phenomenon that is not dependent on telomere erosion. Stress-induced senescence is often referred to as "premature" since it can occur long before the Hayflick limit is reached.[13,16,24] Human chondrocytes and MSCs grown

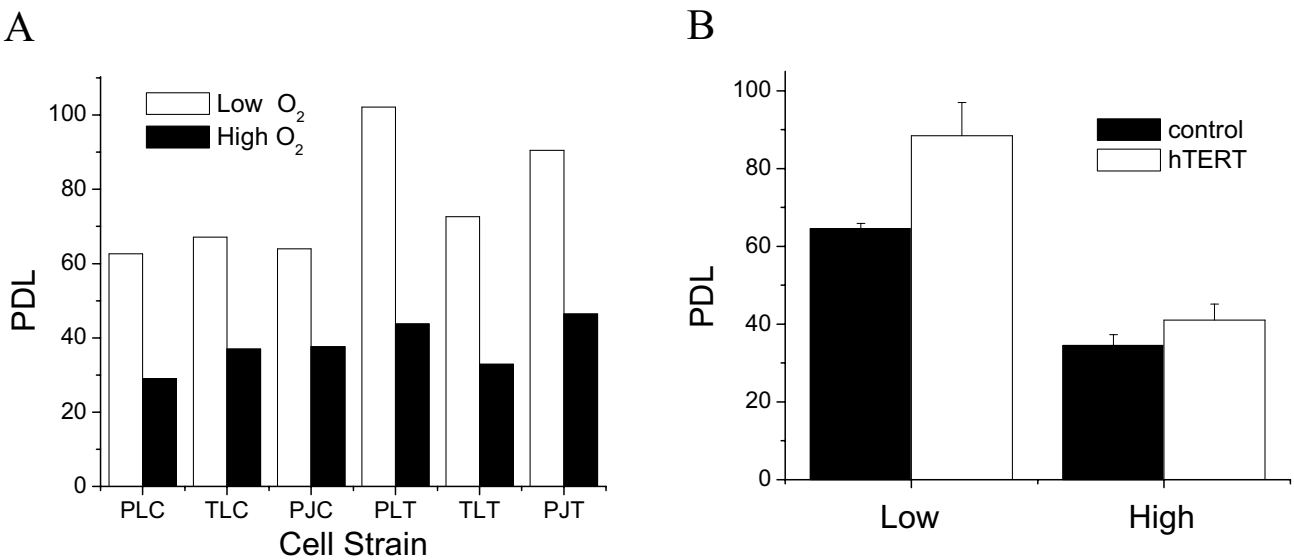

Figure 1. Effects of Oxygen and Telomerase Activation on Chondrocyte Population Growth. A: Population doubling limits (PDL) for 3 chondrocyte strains (PL, TL, PJ) cultured in 5% oxygen (Low O_2) or 21% oxygen (High O_2). Results are shown for control cells (PLC, TLC, PJC) and for cells transduced with hTERT (PLT, TLT, PJT). B: Columns represent mean PDL and standard error of the mean (error bars) for control and hTERT cells in either low or high O_2. PDL values for low O_2 grown cells were significantly greater than for high O_2 grown cells ($p < 0.001$). The differences between hTERT and control cells were not significant in high O_2 ($p = 0.262$) but were very nearly significant in low O_2 ($p = 0.052$).

under standard culture conditions grow to only 10-40 PD[13,23], well short of the 60 PD Hayflick limit.[9] Taken together these findings suggest that standard culture conditions are suboptimal for expansion of MSC and chondrocyte populations.

The *in vitro* growth characteristics of cells are subject to many culture-related factors, such as initial cell densities, media formulation, and oxygen tension.[16,24] Standard culture conditions use oxygen levels (20%-21%) that are hyper-physiologic for many cell types, including articular chondrocytes and bone-marrow derived MSCs, which are adapted to relatively low oxygen levels (< 10%) *in vivo*.[21] This suggests that excessive oxidative stress may limit the growth potential of cells under standard conditions. Indeed, reducing incubator O_2 levels has been shown to have beneficial effects on population growth of oxygen sensitive fetal fibroblasts.[16] Based on these findings we hypothesized that the standard incubator atmosphere of 21% O_2 causes sufficient oxidative stress to induce premature senescence in chondrocytes and MSCs, limiting the number of cells available for tissue engineering. To test this we compared the growth of human MSC and chondrocyte populations in 21% and 5% O_2 and measured oxidant production by cells under the two conditions. hTERT transduced chondrocytes were included in the study to help distinguish between stress-induced growth arrest and growth arrest induced by telomere erosion.

METHODS

Human articular cartilage was harvested from the distal tibial or talar surfaces of normal ankle joints as previously described.[12] Monolayer cultures were grown in medium containing 40% Dulbecco's modified Eagle medium, 40% Modified Eagle Medium-alpha, 10% Ham's F12, 10% fetal calf serum, 0.1 U/ml insulin, 25 µg/ml ascorbate, 5 µM hydrocortisone, and antibiotics (Life Technologies). Growth studies were initiated by trypsinizing the primary cultures, counting the cells manually, and inoculating 100,000 cells in 100 mm tissue culture dishes. These were placed in incubators with either a 5% O_2 (5 % O_2, 90% N_2, 5% CO_2) or 21% O_2 atmosphere (21% O_2, 74% N_2, 5% CO_2) and incubated with medium changes every 2-3 days until the cells were nearly confluent. At that point the cells were trypsinized, counted, and re-innoculated as before. This procedure was repeated for several passages. Chondrocytes were transduced with FIV-hTERT for telomerase activation or with FIV ß-galactosidase (control) as previously described.[13]

Human MSCs were obtained from discarded Cellect®, units (DePuy Acromed) immediately after surgery. Filters were washed with MSC medium (70% DMEM, 20% Ham's F12, 10% FBS) and the washings collected in 2-3 150 mm tissue culture dishes. After incubating for 4-5 days at 37˚C the cultures were washed extensively with Hank's Balanced Salt Solution (HBSS)

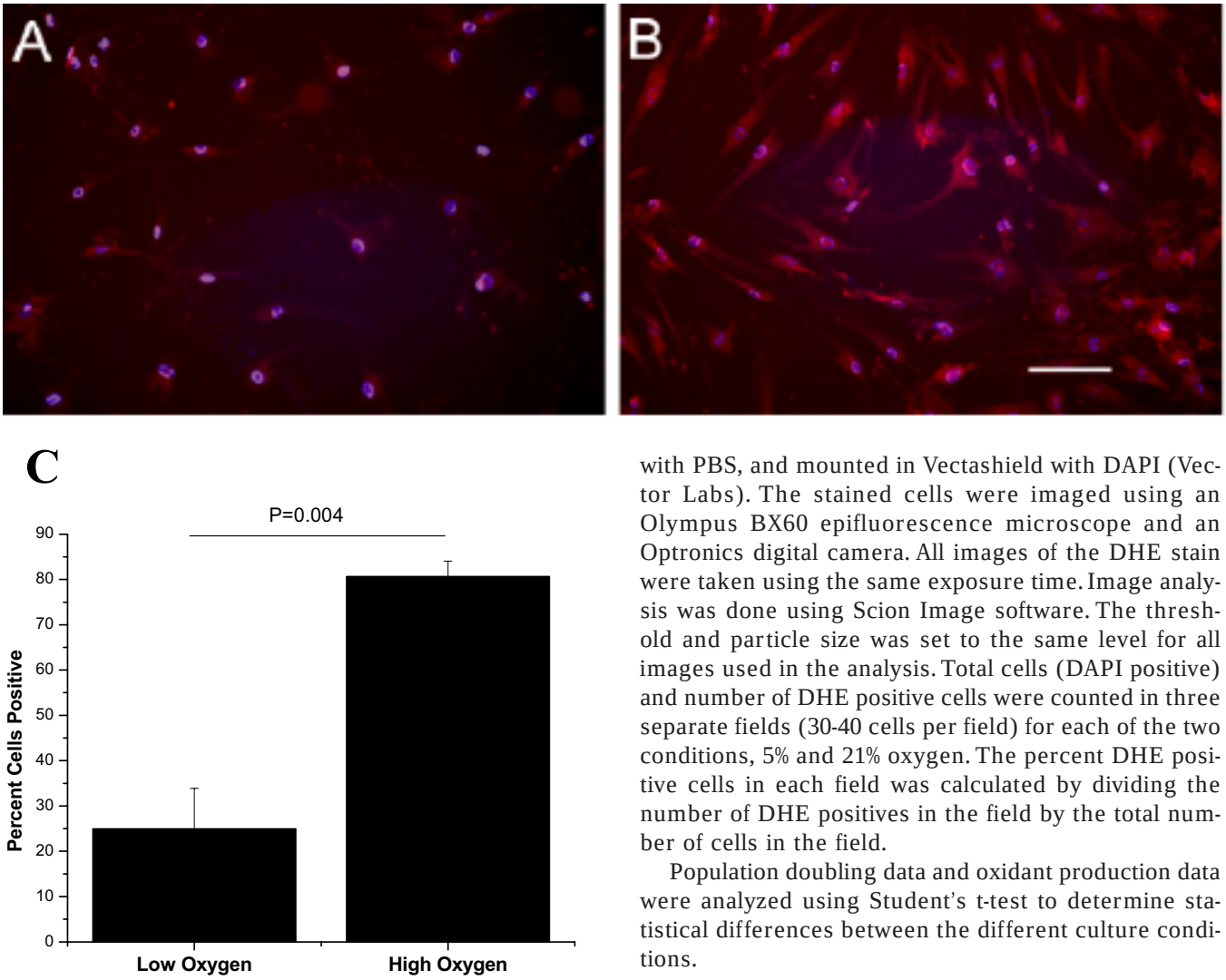

Figure 2. Oxidant Production by Chondrocytes in High and Low Oxygen. A,B: Fluorescence micrographs of cells stained with DHE (red) and DAPI (blue). (A) Cells in low O_2. (B) Cells in high O_2. C: The percentage of DHE positive cells (Percent Cells Positive) in high and low O_2. Columns show the mean and standard error of the mean (error bars) based on 120 cells. There were significantly more positive cells in high O_2 (p = 0.004).

to remove red blood cells and other debris, revealing adherent cells. These were re-fed with MSC medium and incubated an additional 14-30 days to expand cell numbers. Growth studies with human MSCs were done in a manner identical to that explained above for chondrocytes.

The production of oxidants in cell cultures was measured using the oxidation-sensitive dye dihydroethidium (DHE) (11). One chondrocyte strain grown in 5% or 21% O_2 for approximately 20 PD was stained by incubation for 30 minutes at 37˚C with 5 μM DHE (Molecular Probes). After staining, the cultures were washed briefly with PBS, and mounted in Vectashield with DAPI (Vector Labs). The stained cells were imaged using an Olympus BX60 epifluorescence microscope and an Optronics digital camera. All images of the DHE stain were taken using the same exposure time. Image analysis was done using Scion Image software. The threshold and particle size was set to the same level for all images used in the analysis. Total cells (DAPI positive) and number of DHE positive cells were counted in three separate fields (30-40 cells per field) for each of the two conditions, 5% and 21% oxygen. The percent DHE positive cells in each field was calculated by dividing the number of DHE positives in the field by the total number of cells in the field.

Population doubling data and oxidant production data were analyzed using Student's t-test to determine statistical differences between the different culture conditions.

RESULTS

The growth of 3 different chondrocyte populations was enhanced in 5% oxygen (low O_2) *versus* 21% O_2 (high O_2) (Figure 1A). Control and hTERT-transduced chondrocytes in low O_2 reached an average of at least 77 PD, while those in high O_2 senesced after only 37.8. This 2-fold increase was highly significant ($p < 0.001$). Without hTERT, mean doubling limits were 64.6 PD in low O_2 and 34.5 PD in high O_2, a difference that was also highly significant ($p < 0.001$). Separate analysis of hTERT cells revealed similar significant increases in growth in low O_2 ($p = .008$). The mean doubling limit in low O_2 grown cells was 88 PD or more, at least 2-fold greater than the mean for high O_2 grown cells (41 PD). The effects of hTERT-transduction depended to some extent on O_2 level (Figure 1B). The mean PDL for hTERT cells in high O_2 was only slightly greater than for controls (41 PD *versus* 35 PD, respectively), a difference that was not statistically significant ($p = 0.262$).

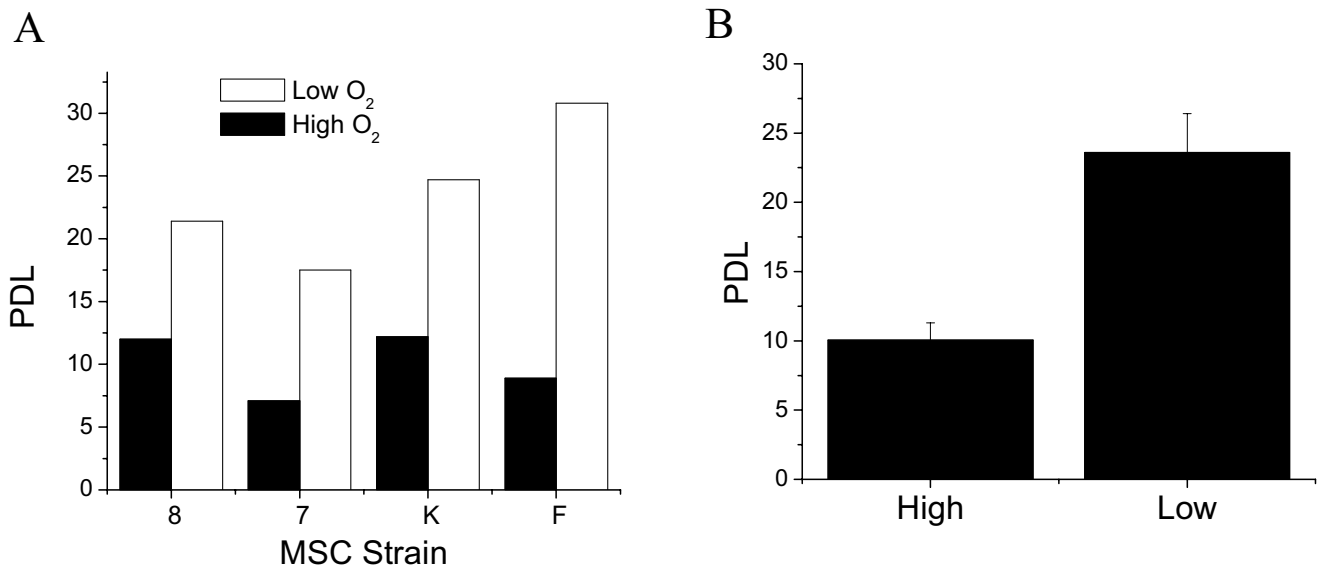

Figure 3. Effects of Oxygen on Mesenchymal Stem Cell Population Growth. A: Population doubling limits (PDL) for 4 MSC strains (8, 7, K, F) cultured in 5% oxygen (Low O_2) or 21% oxygen (High O_2). B: Columns represent mean PDL and standard error of the mean (error bars) for low or high O_2 grown cells. PDL values for low O_2 grown cells were significantly greater than for high O_2 grown cells ($p < 0.05$).

However, in low O_2 hTERT increased growth from 65 PD to at least 88 PD, a somewhat stronger effect that approached statistical significance ($p = 0.052$). Two of the three hTERT-transduced strains maintained in low O_2 were still growing at the time of this report, suggesting that these cells may be immortalized.

Oxidant generation differed in chondrocytes grown under high and low O_2 conditions (Figure 2). Weak DHE staining was observed in cells from a low O_2 culture (Figure 2A) but cells from a high O_2 culture were intensely stained (Figure 2B). Semi-quantitative analysis revealed that 25% of the cells in the low O_2 culture were DHE positive, while 80% of the cells in the high O_2 culture were positive. This difference was highly significant ($p = 0.004$).

The growth of human bone marrow-derived MSCs was also found to be sensitive to O_2 level. Cells from 4 different MSC strains cultured in low O_2 outgrew their high O_2 counterparts by at least 2-fold (Figure 3A). The mean PDL for all MSC populations in high O_2 was 10.5, while the mean for cells cultured in low O_2 was 23.6 PD (Figure 3B). This difference was statistically significant ($p < 0.05$).

DISCUSSION

Our findings support the hypothesis that high oxygen levels used in standard culture conditions are harmful to human chondrocytes and MSCs. Chondrocytes senesced after 25-30 PD when they were cultured under standard conditions, however, the same cells cultured in 5% O_2 grew to 60 population doublings, indicating that the earlier growth arrest in standard conditions was premature. Telomerase activity induced by ectopic expression of hTERT allowed chondrocytes grown in 5% O_2 to exceed 60 PD, indicating that growth arrest at this stage was due to telomere-dependent replicative senescence. In contrast, hTERT expression had little if any impact on senescence in 21% O_2 despite evidence of extensive telomere elongation (data not shown). Thus, premature growth arrest at approximately 30 PD was independent of telomere length, suggesting a stress-induced mechanism of senescence. This conclusion was supported by additional analyses which showed that growth in 21% O_2 increased the cellular production of oxidants. High O_2 conditions were similarly detrimental to the growth of MSC populations. MSCs cultured in high O_2 barely exceeded 10 PD before the cells senesced, but the same populations cultured in low O_2 grew to approximately 20 PD.

Two of three hTERT-transduced chondrocyte strains never reached a doubling limit and continue at the present time to proliferate in low O_2. This suggests that the combination of telomerase activity and low O_2 conditions may be sufficient to immortalize chondrocytes. However, this will be evident only after additional time in culture. In any event, the incomplete growth data reported here probably underestimate the true strength of hTERT effects in chondrocytes cultured in low O_2.

MSC growth was clearly affected by oxygen but the absolute PDL values were lower than some published values for human MSCs cultured in high O_2.

Much of this apparent discrepancy could have been due to unaccounted-for population doublings that accumulated during expansion of the primary cultures. This

will be avoided in future studies by counting the MSCs initially plated so that growth in the primary cultures can be tracked. In some high O_2 cultures the number of cells declined following growth arrest (data not shown), suggesting cell death. Thus, our findings to date indicate that high oxygen levels limit are stressful to MSCs and limit their *in vitro* growth by inducing senescence and apoptosis.

Standard culture conditions were originally developed for growing cell lines and fibroblasts. While fibroblasts perform well under these conditions, reaching their full replicative potential of near 60 PD, other cell types such as keratinocytes, require a more specialized environment to avoid culture-induced premature senescence.[20] Our findings indicate that culture induced stress is the primary factor limiting the *in vitro* growth of chondrocytes and MSCs and that preventing oxidative stress is a key factor in overcoming this barrier. Lowering incubator O_2 levels was an effective and simple means to that end, but other modifications of standard conditions, such as the addition of antioxidants to the culture medium, might confer additional protection against oxidative damage. Moreover, even routine cell culture procedures such as initial cell isolation and trypsinization are potential sources of oxidative stress. Such occasional stress exposures might impact growth even in cultures exposed most of the time to low O_2 conditions and might explain why one low O_2 grown hTERT strain senesced.

The attenuation of growth imposed by culture-related stress seriously restricts cell yields and may have a negative impact on subsequent differentiation of MSCs and chondrocytes. Additional studies will be needed to determine what are likely to be diverse phenotypic effects of oxidative damage. However, the present study shows that low O_2 culture is an effective means to control oxidative stress and to increase the proliferative potential of MSCs and chondrocytes destined for grafting procedures.

REFERENCES

1. **Allsopp RC, Chang E, Kashefi-Aazam M, Rogaev EI, Piatyszek MA, Shay JW, Harley CB.** Telomere shortening is associated with cell division in vitro and in vivo. *Exp Cell Res.* 1995; 220:194–200.
2. **Barry FP.** Mesenchymal stem cell therapy in joint disease. *Novartis Found Symp.* 2003; 249:86-96
3. **Brittberg M, Lindahl A, Nillson A., Ohlsson C, Isaksson O, Peterson L.** Treatment of Deep Cartilage Defects in the Knee With Autologous Chondrocyte Transplantation. *New Eng J Med* 1994; 331(14): 889-895.
4. **Brittberg M, Tallheden T, Sjogren-Jansson B, Lindahl A, Peterson L.** Autologous chondrocytes used for articular cartilage repair: an update. *Clin Orthop.* 2001; 391 Suppl: S337-348.
5. **Caplan AI, Bruder SP.** Mesenchymal stem cells: building blocks for molecular medicine in the 21st century. *Trends Mol Med.* 2001; 7:259-264.
6. **Caterson EJ, Nesti LJ, Danielson KG, Tuan RS.** Human marrow-derived mesenchymal progenitor cells: isolation, culture expansion, and analysis of differentiation. *Mol Biotechnol.* 2002; 20:245-256.
7. **Dell'Accio F, Vanlauwe J, Bellemans J, Neys J, De Bari C, Luyten FP.** Expanded phenotypically stable chondrocytes persist in the repair tissue and contribute to cartilage matrix formation and structural integration in a goat model of autologous chondrocyte implantation. *J Orthop Res.* 2003; 21:123-131.
8. **Gao J, Dennis JE, Solchaga LA, Awadallah AS, Goldberg VM, Caplan AI.** Tissue-engineered fabrication of an osteochondral composite graft using rat bone marrow-derived mesenchymal stem cells. *Tissue Eng.* 2001; 7:363-371.
9. **Hayflick L, Moorhead PS.** The serial cultivation of human diploid cell strains. *Exp Cell Res.* 1961; 25: 585-621.
10. **Herbert BS, Wright WE, Shay JW.** p16(INK4a) inactivation is not required to immortalize human mammary epithelial cells. *Oncogene.* 2002; 21:7897–7900.
11. **Li W; Miller F; Brown M; Chatterjee P; Aylsworth G; Shao J; Spector A; Oberley L; and Weintraub, N:** Enhanced H_2O_2-induced cytotoxicity in "epithelioid" smooth muscle cells implications for neointimal regression. *Arterioscler Thromb Vasc Biol.* 2000; 20: 1473-1479
12. **Martin JA, Buckwalter JA.** Telomere erosion and senescence in human articular cartilage chondrocytes. *J. Gerontol: Biol Sci.* 2001; 56A:B172-179
13. **Martin JA, Mitchell CJ, Klingelhutz AJ, Buckwalter JA.** Effects of telomerase and viral oncogene expression on the in vitro growth of human chondrocytes. *J Gerontol: Biol Sci.* 2002; 57: B48-53
14. **Micheli LJ, Browne JE, Erggelet C, Fu F, Mandelbaum B, Moseley JB, Zurakowski D.** Autologous chondrocyte implantation of the knee: multicenter experience and minimum 3-year follow-up. *Clin J Sport Med.* 2001; 11:223-228.
15. **Muschler GF, Midura RJ.** Connective tissue progenitors: practical concepts for clinical applications. *Clin Orthop.* 2002; 395:66-80.

16. **Parrinello S, Samper E, Krtolica A, Goldstein J, Melov S, Campisi J.** Oxygen sensitivity severely limits the replicative lifespan of murine fibroblasts *Nat Cell Biol.* 2003 Aug; 5(8): 741-747.
17. **Pereira RF, O'Hara MD, Laptev AV, Halford KW, Pollard MD, Class R, Simon D, Livezey K, Prockop DJ.** Marrow stromal cells as a source of progenitor cells for nonhematopoietic tissues in transgenic mice with a phenotype of osteogenesis imperfecta. *Proc Natl Acad Sci U. S.A.* 1998; 95: 1142-1147.
18. **Pittenger MF, Mackay AM, Beck SC, Jaiswal RK, Douglas R, Mosca JD, Moorman MA, Simonetti DW, Craig S, Marshak DR.** Multilineage potential of adult human mesenchymal stem cells. *Science.* 1999; 284: 143-147.
19. **Prockop DJ.** Marrow stromal cells as stem cells for nonhematopoietic tissues. *Science.* 1997; 276: 71-74.
20. **Rheinwald JG, Hahn WC, Ramsey MR, Wu JY, Guo Z, Tsao H, De Luca M, Catricala C, O'Toole KM.** A two-stage, p16(INK4A)- and p53-dependent keratinocyte senescence mechanism that limits replicative potential independent of telomere status. *Mol Cell Biol.* 2002; 22:5157-72.
21. **Scott JE.** Oxygen and the connective tissues trends *Biochem Sci.* 1992; 17:340-343.
22. **Shapiro F, Koide S, Glimcher MJ.** Cell origin and differentiation in the repair of full-thickness defects of articular cartilage. *J Bone Joint Surg Am.* 1993; 75: 532-553.
23. **Stenderup, K, Justesen J, Clausen C, Kassem M.** Aging is associated with decreased maximal life span and accelerated senescence of bone marrow stromal cells. *Bone.* 2003; 33: 919-926.
24. **Toussaint O, Medrano E, Zglinicki T.** Cellular and molecular mechanisms of stress-induced premature senescence (sips) of human diploid fibroblasts and melanocytes. *Exp Gerontol.* 2000; 35: 927–945.
25. **Vaziri H, Benchimol S.** Reconstitution of telomerase activity in normal human cells leads to elongation of telomeres and extended replicative life span. *Curr Biol*, 1998; 8: 279-282.
26. **Wakitani S, Goto T, Pineda SJ, Young RG, Mansour JM, Caplan AI, Goldberg VM.** Mesenchymal cell-based repair of large, full-thickness defects of articular cartilage. *J Bone Joint Surg Am.* 1994; 76: 579-592.

ADAPTIVE MESHING TECHNIQUE APPLIED TO AN ORTHOPAEDIC FINITE ELEMENT CONTACT PROBLEM

Colleen M. Roarty, MS
Nicole M. Grosland, PhD

ABSTRACT

Finite element methods have been applied extensively and with much success in the analysis of orthopaedic implants.[6,7,12,13,15] Recently a growing interest has developed, in the orthopaedic biomechanics community, in how numerical models can be constructed for the optimal solution of problems in contact mechanics. New developments in this area are of paramount importance in the design of improved implants for orthopaedic surgery. Finite element and other computational techniques are widely applied in the analysis and design of hip and knee implants, with additional joints (ankle, shoulder, wrist) attracting increased attention.

The objective of this investigation was to develop a simplified adaptive meshing scheme to facilitate the finite element analysis of a dual-curvature total wrist implant. Using currently available software, the analyst has great flexibility in mesh generation, but must prescribe element sizes and refinement schemes throughout the domain of interest. Unfortunately, it is often difficult to predict in advance a mesh spacing that will give acceptable results. Adaptive finite-element mesh capabilities[1,14] operate to continuously refine the mesh to improve accuracy where it is required, with minimal intervention by the analyst. Such mesh adaptation generally means that in certain areas of the analysis domain, the size of the elements is decreased (or increased) and/or the order of the elements may be increased (or decreased). In concept, mesh adaptation is very appealing. Although there have been several previous applications of adaptive meshing for in-house FE codes, we have coupled an adaptive mesh formulation with the pre-existing commercial programs PATRAN (MacNeal-Schwendler Corp., USA) and ABAQUS (Hibbit Karlson and Sorensen, Pawtucket, RI). In doing so, we have retained several attributes of the commercial software, which are very attractive for orthopaedic implant applications.

Department of Biomedical Engineering
Department of Orthopaedics and Rehabilitation
The University of Iowa

Corresponding Author
Nicole M. Grosland, PhD
1418 Seamans Center
Department of Biomedical Engineering
The University of Iowa
Iowa City, IA 52242
Tel: 319-335-6425
Email: nicole-grosland@uiowa.edu

INTRODUCTION

Finite element analysis was first introduced to the field of orthopaedics in 1972.[3] Since that time, finite element models have been increasingly used for three main purposes: (i) for design and pre-clinical analysis of prostheses; (ii) to obtain fundamental knowledge about musculoskeletal structures; and (iii) to investigate time-dependent adaptation processes (i.e., tissue growth, remodeling and degeneration) in tissues.[11] Successful three-dimensional finite element modeling has been applied to several different prostheses such as the hip[4,9,10,12], the knee[8], the metacarpophalangeal joint[16], and the shoulder.[2]

The analysis of dislocation biomechanics relies heavily on the principles of contact mechanics. Inherently nonlinear, contact problems are difficult to solve. For dislocation problems, in particular, this is further compounded by the highly localized regions of contact. Recently, a growing interest has developed in the orthopaedic biomechanics community in how numerical models can be constructed for the solution of problems in implant contact mechanics. The finite element method has proven a successful tool for such analyses. Scifert et al.[12], for example, developed a three-dimensional nonlinear finite element model for the purpose of studying dislocation of total hip arthroplasty. With this approach, they were able to identify component design modifications that had an increased resistance to dislocation.

FINITE ELEMENT METHODS

Basic to any finite element (FE) task is the geometric discretization of the structure(s) of interest, a process known as mesh generation. The creation of adequate finite-element models for complex structural

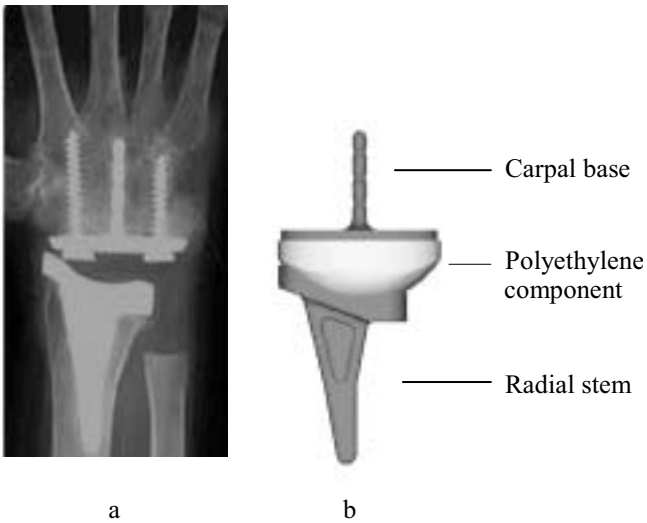

Figure 1. The Universal total wrist implant in the neutral position is shown. Illustrated as (a) a radiograph of the implanted UTW and (b) a rendered FE model of the individual components.

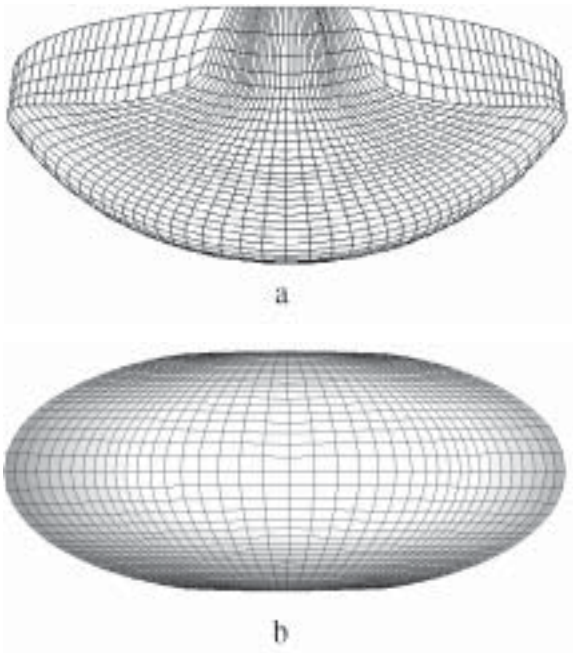

Figure 2. The initial base mesh for the articulating polyethylene carpal component (a) a three-dimensional dorsal view of the component and (b) the articular surface of the mesh.

configurations can be time-consuming. Powerful software tools for mesh generation are commercially available, the limits of which are well understood: PATRAN, (MacNeal-Schwendler Corp., USA), ANSYS (Ansys Inc., Canonsburg, PA), TrueGrid (XYZ Scientific Applications, Inc., Livermore, CA, etc.). Using currently available software, the analyst has great flexibility in meshing, but must prescribe element sizes and refinement throughout the domain. Simplifying assumptions must be made to keep the FE models manageable, not only from the perspective of the complex geometries, but moreover in view of the computational tractability. Prior to accepting the results of a finite element analysis, both the accuracy and validity of the solution must be objectively established.[3] The accuracy of the analysis reflects how well the chosen element types and mesh can approximate the exact solution for the structure, given the assumed simplifying assumptions. The most important factor in establishing accuracy is the element mesh density, in relation to the element type chosen. An objective assessment of the mesh density is typically achieved via a convergence test (i.e., repeated calculations for increased mesh refinement and checking the convergence of a desired parameter; for example, stress). For contact as well as all other types of analyses the solution asymptotically improves as the mesh is refined.

For well-behaved problems, a grid of uniform mesh spacing (in each of the coordinate directions) usually gives satisfactory results. However, there are classes of problems where convergence is more problematic in some regions (due to contact stress concentrations, etc.) than in others. In principle a uniform grid, having spacing fine enough so that the local errors estimated in these difficult regions are acceptable, could be adopted. In practice, such an approach is prohibitively costly computationally. Furthermore, for problems with a spatially migrating contact zone, it is difficult to predict in advance a mesh spacing that will give acceptable results. To reduce engineering time expended in model development, adaptive finite-element mesh capabilities have been recently introduced, offering the capability to continuously refine the mesh to improve accuracy where required. Adaptive meshing for contact problems, however, is in the formative development stage. The majority of adaptive meshing algorithms have, to our knowledge, been employed in theoretical pursuits and applied to simplified geometries. Simple geometries, however, are of little value for the applications currently confronted in orthopaedics.

Several researchers are devoted to the development of adaptive refinement strategies for effective finite element analyses.[5] These include methods such as the adaptive h-refinement techniques, p-refinement techniques, and hp-refinement techniques. The h-refinement technique enhances the mesh, by subdividing the elements, while retaining the order of the elements. The

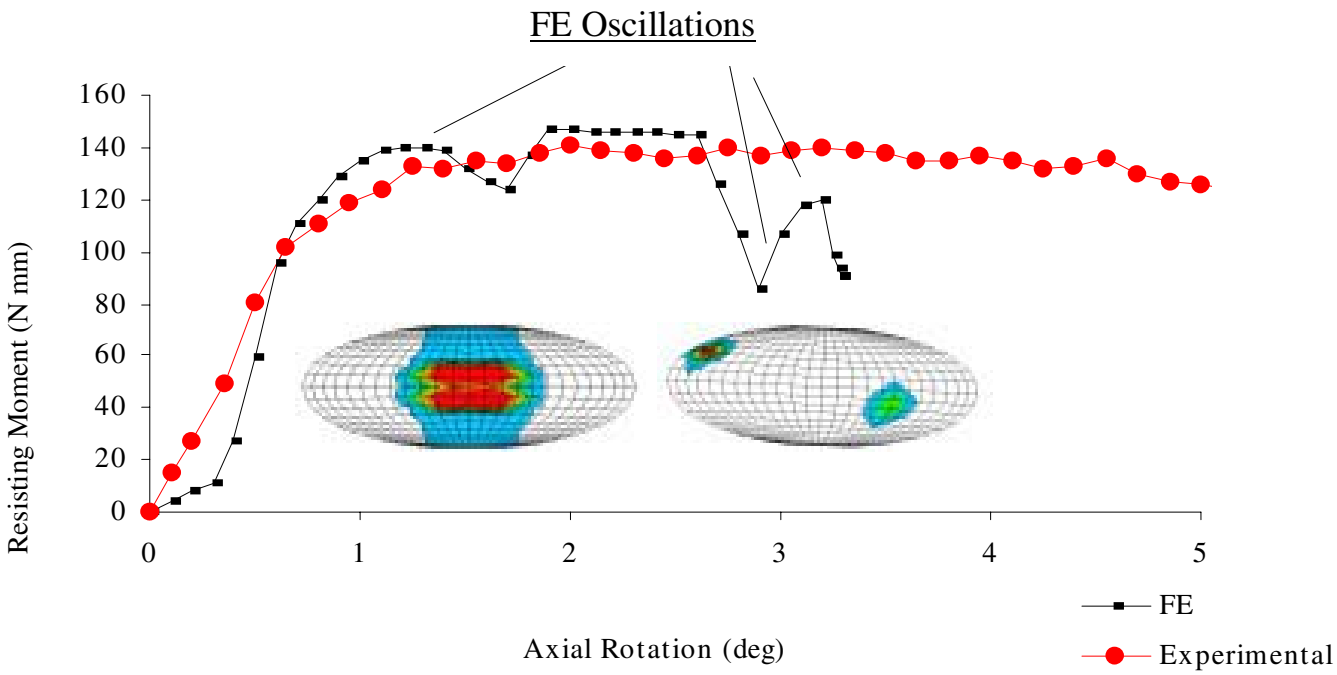

Figure 3. Resisting moment comparison between an experimental test and the FE predictions for an imposed rotation about the anatomic longitudinal axis. As illustrated, the FE predictions exhibit an oscillatory behavior, followed by a failure to converge. Furthermore, a stress contour plot for the UHMWPE carpal component (insets) illustrates (a) the initial contact area and (b) the nearly point contact characteristic of this design during rotation.

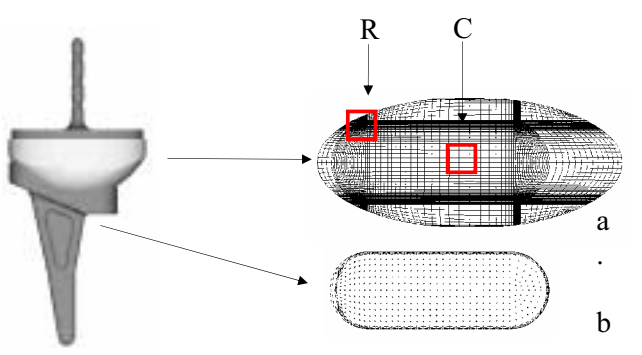

Figure 4. Resulting FE meshes of the articulating (a) UHMWPE carpal and (b) radial surfaces. Note: Contact convergence required extremely high degrees of mesh refinement in regions of potential contact. Square, R, signifies a region where the UHMWPE mesh density is approximately 215 elements/mm^2, whereas densities in non-critical areas (square, C) were as coarse as 1 element/mm^2.

adaptive p-methods raise the order of the interpolation functions while preserving the same mesh. A combination of the two methods yields the hp-refinement technique, thereby enriching the mesh by reducing the size of the elements, while simultaneously raising the order of the elements. If these strategies are employed for the refinement of localized regions the use of either distorted transition grids, specialized transition elements, or multi-point constraints is inevitable. While multiple point constraints tend to be cumbersome from a model development standpoint, distorted elements in the transition zones tend to significantly degrade the accuracy of the results.

Our immediate impetus for pursuing adaptive mesh refinement arose due to challenges encountered when modeling dislocations in an otherwise promising class of total wrist implants, the Universal (Kinetikos Medical, Inc., San Diego, CA) total wrist. Computer Aided Design (Pro/ENGINEER, PTC, Needham, MA) capabilities were used to model the Universal prosthesis based on the manufacturer's dimensional specifications (Figure 1). The model was imported into the solid modeler PATRAN, enabling a base finite element mesh to be generated for each component. The polyethylene carpal component (Figure 2) was modeled as a nonlinear deformable body with an elastic modulus (E) of 634.92 MPa and Poisson ratio of 0.45. Six thousand four hundred eight-noded hexahedral elements were used in the original coarse mesh of the polyethylene component. The elastic modulus of the CoCr and Ti alloys are significantly greater than that of ultrahigh molecular weight polyethylene (UHMWPE). As a result, the carpal base (assumed to be directly bonded to the polyethylene component) and the articulating surface of the radial component were meshed as a rigid body and a rigid surface, respectively. The benefit of this simplifi-

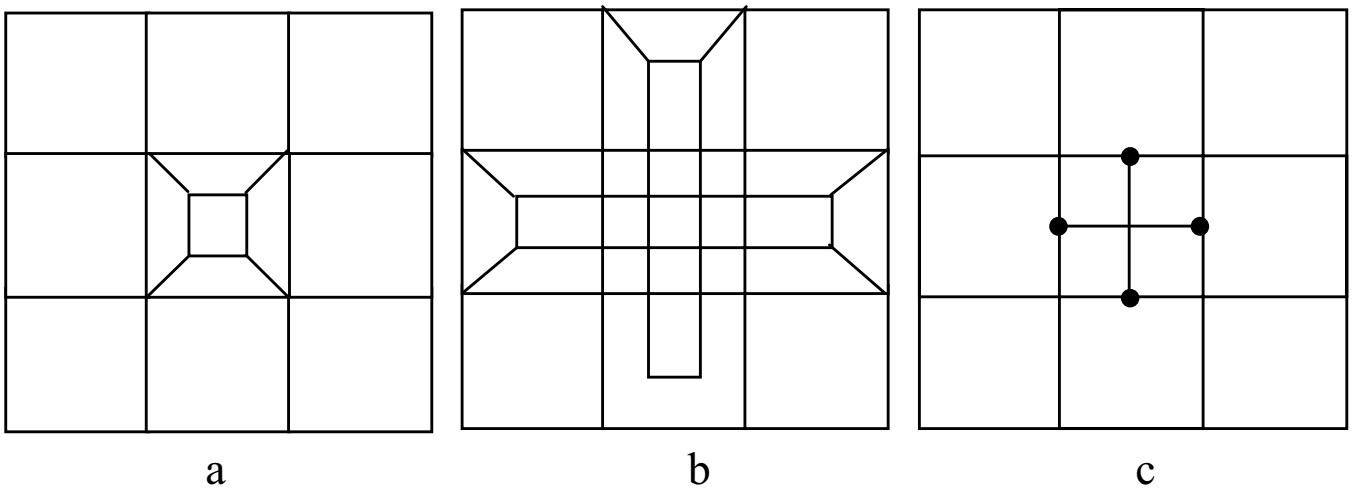

Figure 5. Potential transition patterns from a coarse to a refined mesh, illustrated in two-dimensions. The transitions from a coarse face to a refined face require the use of transition elements in (a & b), while additional nodal constraints (denoted by) are required in (b).

cation is a considerable gain in computational efficiency. The carpal and radial surfaces were represented by 1600 four-noded quadrilateral elements and 2108 three-noded triangular elements, respectively.

To accurately reflect physical motions, the finite element model was prescribed the same degrees of freedom as those specified in our physical experiments. Initiating in the neutral anatomic position (Figure 1), the radial component was free to translate in the radial-ulnar and volar-to-dorsal directions (during translatory dislocation, the radial component was also restricted in the radial-ulnar directions) while the carpal complex was unconstrained along the vertical axis. A 30N compressive load was maintained while the prescribed rotational (5 degrees) or translational (2 mm) displacement was applied.

Initially, a rotation input condition was adopted, such that the motion challenge of interest progressed fully to completion, regardless of the amount of resistance (moment) developed by the prosthesis. This resistance, however, exhibited an oscillatory behavior throughout the prescribed motion (Figure 3). Further compounding the challenge was the initial conformity of the surfaces. As the dislocation event progressed, the initial area contact changed quickly to resemble nearly line contact, and then to nearly point contact (Figure 4). Consequently, a traditional convergence test ensued. Attempts to refine the mesh near the initial contact zone were successful but, as described previously, computationally expensive and difficult to predict in advance. The resulting carpal and radial components were represented by 4-noded quadrilateral elements (n=6,710) and 3-noded triangular elements (n=1,366), respectively. The polymeric component was modeled via 20,130 8-noded hexagonal elements (E = 634.92 MPa, v=0.45). In addition to these user-defined elements, 14,370 elements were defined internally by ABAQUS/Standard 6.2 for contact purposes.

Despite the highly refined regions (Figure 4; mesh densities up to 215 elements/mm^2), once the contact site(s) shifted beyond the refined zone(s), the oscillatory behavior reappeared. For the purpose of obtaining the maximum resistive moment, this particular refinement was sufficient. Had the behavior beyond the point of peak resistance been of interest, the oscillations might have been further postponed by extending the refined region. This, however, further compounded the computational costs. Due to the near-point contact characteristic of this particular model, the additional regions of refinement (i.e., those not immediately adjacent to the point of contact) were unnecessary, and ultimately computationally inefficient. Ideally, if the refined region were localized and able to shift such that it was always adjacent to the region(s) of contact, the total number of elements required would be diminished substantially. Consequently, the objective of the present investigation was to develop a simple and effective hexahedral mesh refinement method to automatically update the mesh, while keeping it general enough to be applicable to a variety of implant designs.

ADAPTIVE MESHING STRATEGY

An automated adaptive meshing routine was developed and applied to the three-dimensional FE model of the Universal (Kinetikos Medical, Inc., San Diego, CA) total wrist implant. The objective was to locally refine the UHMWPE carpal mesh during the analysis with minimal effort by the operator. The realization of reliable refinement was strongly dependent on the appropriate refinement pattern. Figure 5 illustrates the ele-

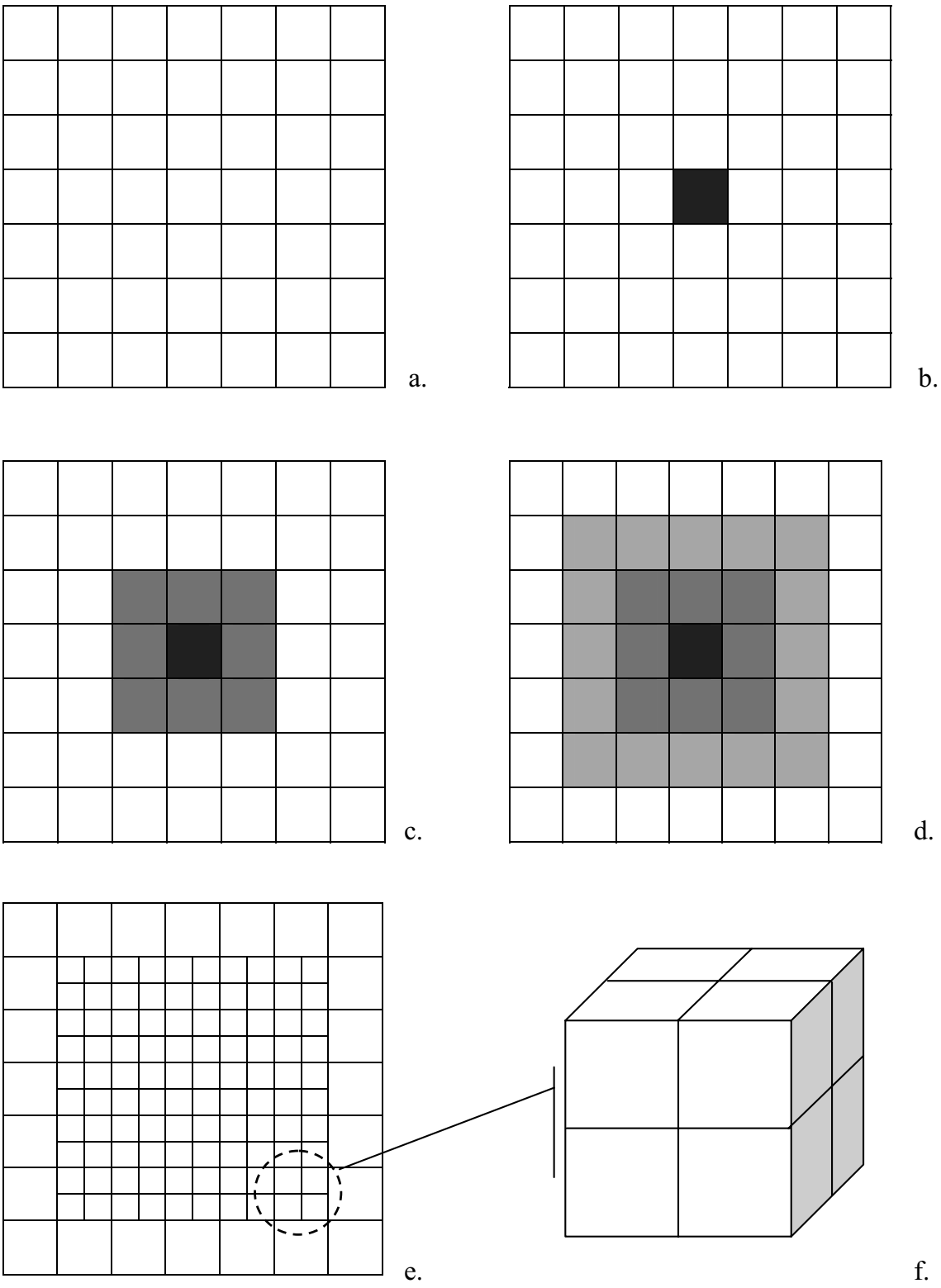

Figure 6. Adaptive meshing refinement strategy: (a) Coarse base mesh illustrated in two-dimensions; (b) the region to be refined is identified by first locating (b) the element experiencing the highest stress averaged over a period of three time steps; (c) the eight neighboring elements are identified, and (d) the elements immediately adjacent to this subset are also included, thereby totaling 25 base elements to be refined. Each element is then subdivided into 8 new elements, illustrated in (e) two- and (f) three-dimensions

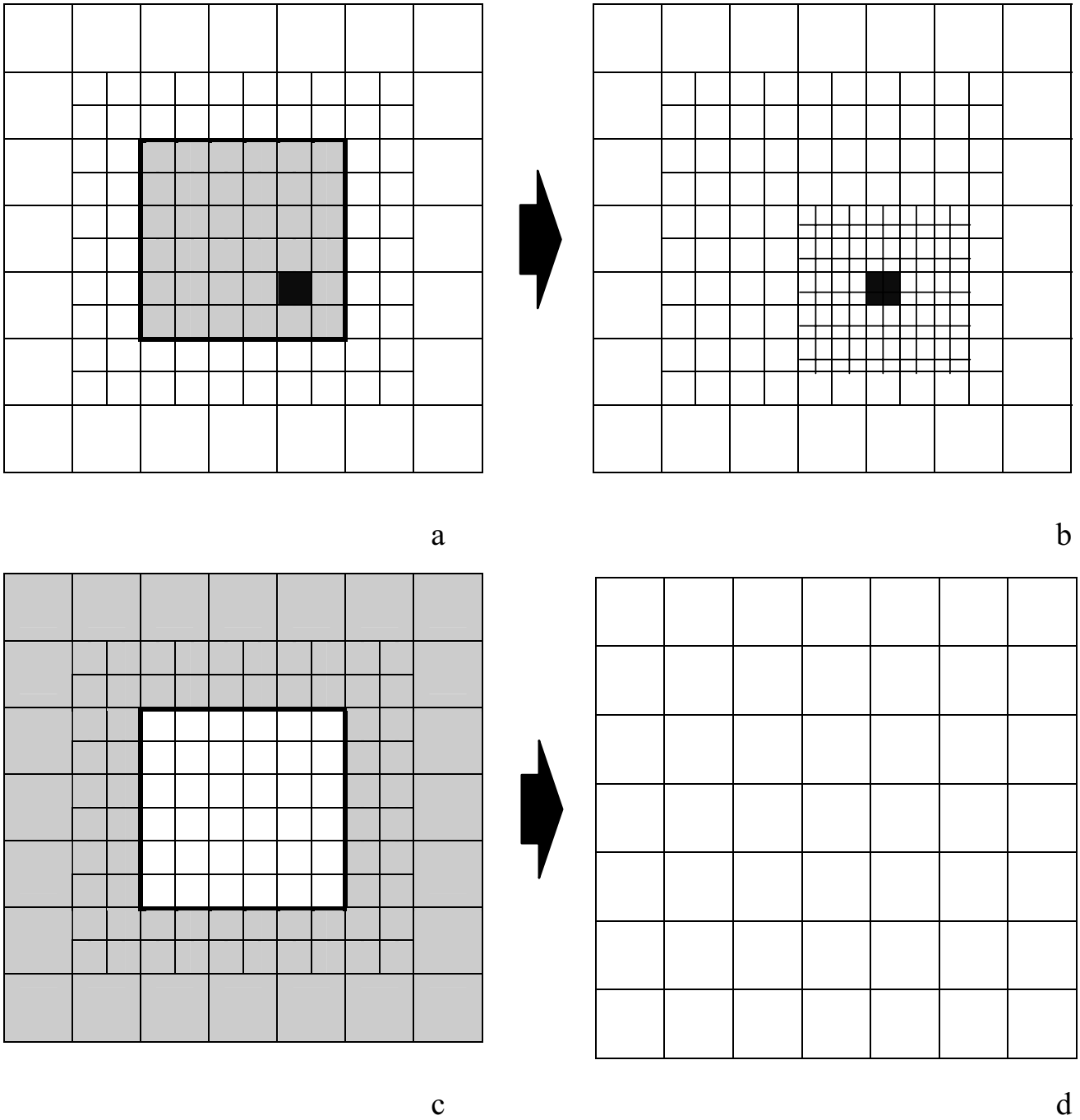

Figure 7. Recursive refinement patterns. (a) To avoid overlapping the offspring grids with the original mesh, based on our current requirement of identifying a 5 x 5 grid, the central element of an offspring mesh must be located within the shaded region illustrated, thereby allowing the required elements to be subdivided appropriately (b). If however, the element falls outside of these bounds as illustrated in (c), the (d) original base mesh is restored and the process repeated.

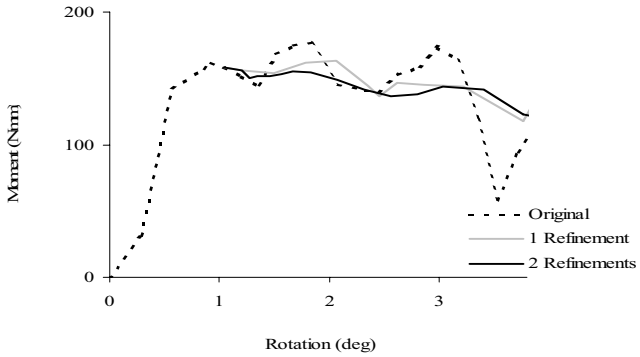

Figure 8. Axial rotation vs. resistive moment. The original rotational resistance is compared to that of the adaptively refined mesh with a single and a double level of refinement.

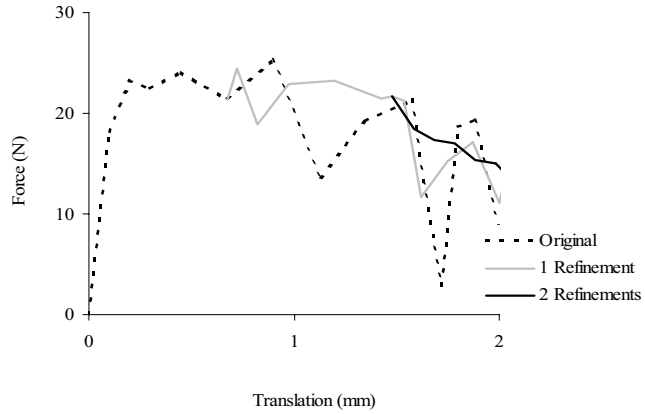

Figure 9. Translation vs. resistive moment. The original rotational resistance is compared to that of the adaptively refined mesh with a single and a double level of refinement.

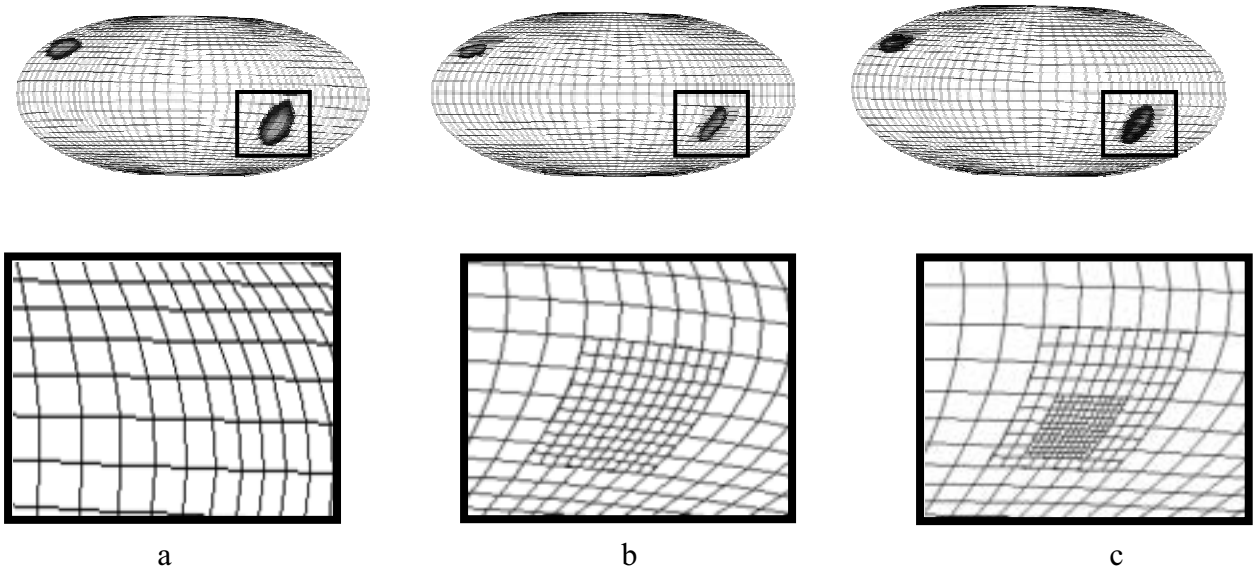

Figure 10. Evolution of the mesh refinement through a rotational dislocation event, progressing from (a) the base mesh to (b) a parent mesh, and to (c) an offspring mesh

ment decomposition schemes that were initially considered. Each scenario retains the hexahedral element type (as opposed to tetrahedral) preferable for contact problems. The first two patterns (Figure 5a,b) preserve global-to-local mesh connectivity, but are prone to distorted elements, especially when subjected to multiple levels of refinement. The latter of the three (Figure 5c), although dependent on constraints, was determined to result in the least amount of distortion throughout multiple refinements; and consequently was the chosen method for element decomposition. With this method, the element boundaries of the newly formed mesh coincide with the boundaries of the underlying global mesh, however, due to the mismatched nodes singularities arise in the stiffness matrix of the assembled equations. These singularities were eliminated by appropriately constraining the mid-side/-face nodes of the local mesh (Figure 5c).

Since the mesh was to be refined locally, an additional consideration was the size of (or number of elements constituting) the localized refinement zone. Due to the near point contact characteristic of this model, it was determined that a 5x5 grid (25 elements) was sufficient to define each refined region. Figure 6 depicts the localized remeshing routine employed in two-dimensions. Our refinement strategy consists of first calculat-

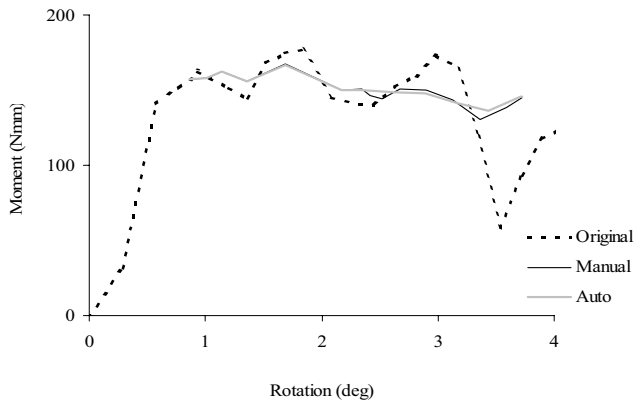

Figure 11. A comparison of the manually (manual) chosen refinement zones versus those chosen automatically (Auto) by the algorithm compared favorably.

ing a preliminary solution on the base mesh for a series of time steps. The local refinement procedure is invoked after an oscillatory resisting moment/force is observed. An error indicator is used to locate regions where greater mesh resolution is needed. A centralized element is located for each such zone. Finer grids are adaptively created in these error-prone regions and the solution and error indicators computed on the finer subgrids. An assessment of the program's ability to locate the region(s) to be refined was tested against a run with the base element(s) chosen manually by the analyst.

The refinement scheme is recursive; thus, fine subgrids may be further refined by adaptively creating even finer subgrids. This relationship leads naturally to a tree data structure. Information regarding the geometry, solution, and error indicators of the base grid is stored as the root, or level 0, of the tree. Subgrids of the base grid are considered offspring and are stored as level 1 of the tree. The structure continues, with a grid at level i having a more coarse parent grid at level i-1 and additional finer offspring at level i+1. Our refinement procedure requires that no two grids overlap and that offspring grids must be properly nested within the boundaries of the parent grid (Figure 7). Additional finer grids are introduced in regions where the error indicators exceed the prescribed tolerance, and the model is solved again on the finer subgrids. Should the oscillatory contact exceed the bounds of the parent mesh, the original base mesh of the model is reinstated and a new parent mesh defined as initially described. This iterative process continues until the oscillatory behavior ceases or, for example, the implant successfully dislocates.

EXAMPLE: VOLAR AND ROTATIONAL DISLOCATION OF THE UNIVERSAL TOTAL WRIST IMPLANT

Numerical studies were conducted to validate the effectiveness of the present technique. The adaptive computations were tested against two dislocation events: a volar and rotational dislocation. Each model was driven under displacement control through the respective dislocation event, first in the absence of the adaptive meshing routine. The adaptive meshing routine, choice of mesh discretization, and error estimator proved effective in reducing the solution's oscillatory behavior during both the rotational (Figure 8) and translational motions (Figure 9). Furthermore, the results supported the use of nested subgrids. Figure 10 illustrates the first two successive refinements during the rotational displacement (note that two separate zones were required during this event). The additional refinements showed a substantial decrease in the error (Figures 8, 9). The decision-making processes implemented in the algorithm proved successful, as compared to the manual selection, when identifying the region, or regions, to be refined (Figure 11).

SUMMARY

An adaptive FE procedure has been developed, using an error estimator based on the oscillatory behavior of a near-point contact analysis. The techniques can be used effectively for enriching the solution space locally. The present approach for adaptive mesh refinement eliminates the use of transition zones and special transition elements. Numerical studies were performed to assess the effectiveness of the present approach for the local refinement of the global mesh in terms of the size of the refined zone(s), in addition to the ability to recursively refine the mesh without introducing significant mesh distortion. Although the present method is effective in avoiding local mesh distortion by eliminating transition zones, distortion of the global mesh is inevitable when discretizing a domain of arbitrary geometry. Consequently, the efficiency of our adaptive mesh-moving and refinement strategies are dependent on our ability to generate a suitable initial mesh and to regenerate a new base mesh should the need arise. The proper base mesh can reduce the need for refinement, and thus increase efficiency. Consequently, future endeavors may benefit from addressing the initial mesh definitions. Although our initial efforts have been applied to an FE model of a total wrist replacement, the methodology holds the potential to be applicable to the countless number of contact problems encountered in orthopaedic biomechanics.

REFERENCES

1. **Brase, D. W., and Millender, L. H.**: Failure of silicone rubber wrist arthroplasty in rheumatoid arthritis. *J Hand Surg [Am]*, 11: 175-183, 1986.
2. **Couteau, B.; Mansat, P.; Estivalèzes, É;** Darmana, R.; Mansat, M.; and Egan, J.: Finite element analysis of the mechanical behavior of a scapula implanted with a glenoid prosthesis. *Clinical Biomechanics.*, 16(7): 566-575, 2001.
3. **Huiskes, R., and Chao, E. Y.:** A survey of finite element analysis in orthopaedic biomechanics: the first decade. *Journal of Biomechanics*, 16(6): 385-409, 1983.
4. **Huiskes, R.; Verdonschot, N.; and Nivbrant, B.:** Migration, stem shape, and surface finish in cemented total hip arthroplasty. *Clinical Orthopaedics & Related Research.*, (355): 103-12, 1998.
5. **Li, L., and Bettress, P.:** Adaptive finite element methods: a review. *Applied Mechanics Review*, 50(10): 581-591, 1997.
6. **Maxian, T. A.; Brown, T. D.; Pedersen, D. R.; and Callaghan, J. J.:** The Frank Stinchfield Award. 3-Dimensional sliding/contact computational simulation of total hip wear. *Clin Orthop*, (333): 41-50, 1996.
7. **Maxian, T. A.; Brown, T. D.; Pedersen, D. R.; and Callaghan, J. J.:** A sliding-distance-coupled finite element formulation for polyethylene wear in total hip arthroplasty. *Journal of Biomechanics*, 29(5): 687-92, 1996.
8. **Miyoshi, S.; Takahashi, T.; Ohtani, M.; Yamamoto, H.; and Kameyama, K.:** Analysis of the shape of the tibial tray in total knee arthroplasty using a three dimension finite element model. *Clinical Biomechanics.*, 17(7): 521-525, 2002.
9. **Namba, R. S.; Keyak, J. H.; Kim, A. S.; Vu, L. P.; and Skinner, H. B.:** Cementless implant composition and femoral stress. A finite element analysis. *Clinical Orthopaedics & Related Research.*, (347): 261-7, 1998.
10. **Pedersen, D. R.; Brown, T. D.; Maxian, T. A.; and Callaghan, J. J.:** Temporal and spatial distributions of directional counterface motion at the acetabular bearing surface in total hip arthroplasty. *Iowa Orthopaedic Journal.*, 18: 43-53, 1998.
11. **Prendergast, P. J.:** Finite element models in tissue mechanics and orthopaedic implant design. *Clinical Biomechanics.*, 12(6): 343-366, 1997.
12. **Scifert, C. F.; Brown, T. D.; and Lipman, J. D.:** Finite element analysis of a novel design approach to resisting total hip dislocation. *Clinical Biomechanics*, 14(10): 697-703, 1999.
13. **Scifert, C. F.; Brown, T. D.; Pedersen, D. R.; and Callaghan, J. J.:** A finite element analysis of factors influencing total hip dislocation. *Clinical Orthopaedics & Related Research*, (355): 152-62, 1998.
14. **Spilker, R. L.; de Almeida, E. S.; and Donzelli, P. S.:** Finite element methods for the biomechanics of soft hydrated tissues: nonlinear analysis and adaptive control of meshes. *Crit Rev Biomed Eng*, 20(3-4): 279-313, 1992.
15. **Vander Sloten, J.; Hobatho, M. C.; and Verdonck, P.:** Applications of computer modelling for the design of orthopaedic, dental and cardiovascular biomaterials. *Proc Inst Mech Eng [H]*, 212(6): 489-500, 1998.
16. **Walker, P. S.; Nunamaker, D.; Huiskes, R.; Parchinski, T.; and Greene, D.:** A new approach to the fixation of a metacarpophalangeal joint prosthesis. *Engineering in Medicine*, 12(3): 135-140, 1983.

BRUCELLA OSTEOMYELITIS OF THE PROXIMAL TIBIA A CASE REPORT

Timothy P. Fowler M.D., Jay Keener M.D., Joseph A. Buckwalter M.D.

ABSTRACT

Brucellosis is a disease of domestic and wild animals that is transmittable to humans. Although endemic in some parts of the world, brucellosis is an uncommon human pathogen in the United States. The clinical presentation of brucellosis is nonspecific, and brucella osteomyelitis can produce lytic lesions on radiographs that resemble neoplasm. Diagnosis can therefore be difficult unless a high index of suspicion is maintained. We present a case of brucella osteomyelitis of the proximal tibia that demonstrates these features.

CASE REPORT

A 79 year-old livestock farmer presented to the Veterans' Affairs Medical Center orthopaedic clinic with a chief complaint of right knee pain. The pain had begun several months prior to the clinic visit and was described as a constant, dull ache made worse with weightbearing. The patient denied any history of trauma, constitutional symptoms, or other arthralgias. His health was otherwise poor, suffering from unstable angina, congestive heart failure, insulin-dependent diabetes mellitus, and chronic renal insufficiency.

Examination revealed a normal appearing knee with no effusion, no joint line tenderness, and full range of motion without instability. The proximal tibia was tender to palpation circumferentially. Radiographs and computed tomography scanning revealed an expansile, well corticated, lytic lesion in the metaphysis of the proximal tibia and mild tricompartmental degenerative changes in the knee (Figures 1a-c). Additional workup revealed a microcytic anemia with a normal white blood cell count and a normal urine protein analysis. A chest radiograph was negative for focal lesions. Open biopsy of the proximal tibia was planned for definitive diagnosis.

Soon after his presentation in clinic however, the patient suffered a myocardial infarction and his health rapidly declined, disallowing any surgical intervention. The ensuing 18 months were punctuated by numerous hospital admissions for cardiopulmonary disease and transient ischemic attacks. The internal medicine and cardiology services felt that the patient was too unstable to undergo any surgical procedure. Meanwhile, the knee pain progressed, rendering the patient unable to ambulate. Even at rest, the pain could not be controlled with narcotic pain medication. Repeat radiographs revealed enlargement of the lesion but no fractures. The patient stated that he was contemplating suicide because of the incapacitating pain. After intense discussion with the patient and his family, the high risk of surgical intervention was accepted and excision and curettage of the lesion was scheduled.

Under a regional anesthetic, an incision was made on the anteromedial leg 3 cm distal to the joint line. Upon penetration of the deep fascia, copious amounts of thick, yellow fluid were encountered flowing through a 2 cm by 2 cm defect in the anterior cortex of the tibia. The fluid filled the entire proximal metaphysis. Tissue samples were obtained and sent to the microbiology and pathology labs for analysis. All necrotic and friable tissue was removed, and the wound was irrigated with several liters of saline. The cavity was then filled with tobramycin-impregnated methylmethacralate.

Staining revealed small Gram-negative rods that were urease-positive (Figure 2), and cultures grew *Brucella suis.* Histopathology was remarkable only for necrotic bone without evidence of neoplasm. The patient's knee pain was nearly completely gone immediately postoperatively and he recovered without any medical complications. Consultation with the infectious disease service was obtained, and the patient was treated with a 3-month course of oral doxycycline and rifampin.

Timothy P. Fowler MD
University of Iowa Hospitals and Clinics
Department of Orthopaedics
Iowa City, Iowa 52242
319-356-2595
timothy-fowler@uiowa.edu

Jay Keener MD
University of Iowa Hospitals and Clinics
Department of Orthopaedics
Iowa City, Iowa 52242
319-356-2595

Joseph A. Buckwalter MD
University of Iowa Hospitals and Clinics
Department of Orthopaedics
Iowa City, Iowa 52242
319-356-2595
joseph-buckwalter@uiowa.edu

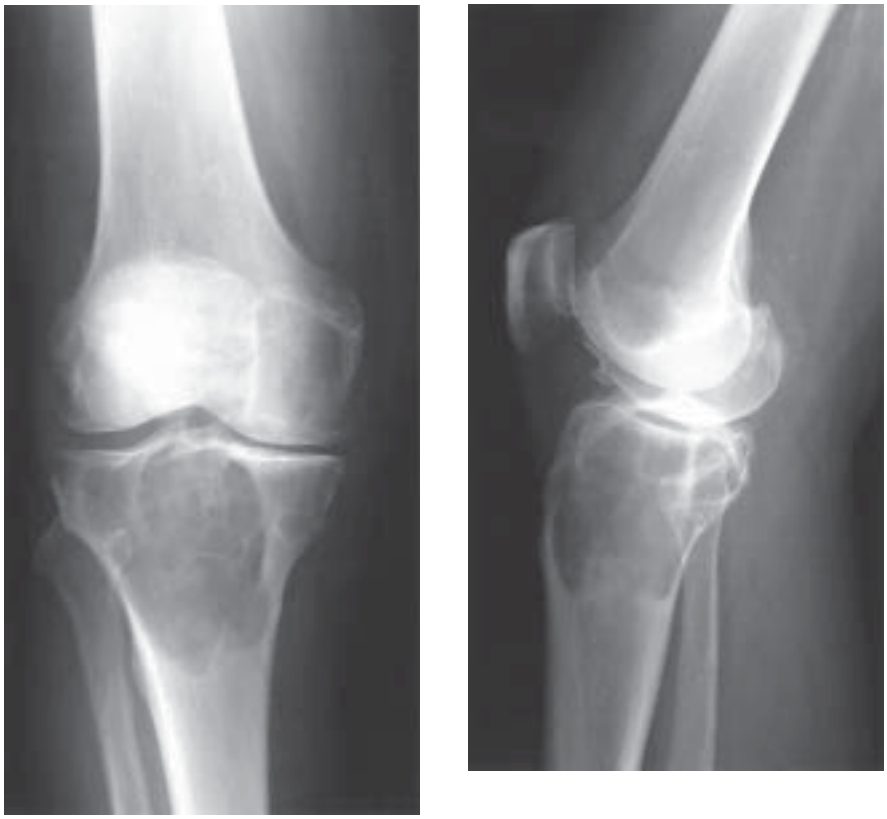

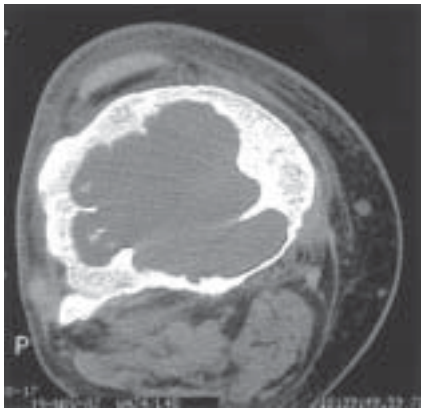

Figures 1a-c. A,B: AP and lateral views of the right knee show an expansile, lytic lesion in the proximal tibial metaphysis. C: An axial CT image of the proximal tibia demonstrates no fractures or cortical defects.

DISCUSSION

Brucellae are small, gram-negative coccobacilli that can be found worldwide.[1] At least six species have been identified, four of which can cause human disease.[2] In animals, brucellosis is a chronic infection that causes abortion and sterility; common carriers include cows, sheep, pigs, and dogs. Brucellosis in humans is thought to always derive from exposure to infected animals through ingestion of unpasteurized dairy products, inhalation of aerosolized bacteria, or from direct contact with contaminated animals through contaminated skin or conjunctiva. Upon entry into the body, the pathogens enter the lymphatic system and replicate in regional lymph nodes. Brucellae are facultative intracellular pathogens that have the capacity to survive within the phagocytic cells of the host. Hematogenous dissemination is often followed by bacteria taking residence in organs rich in cells of the reticuloendothelial system, such as the liver, spleen, and bone marrow.[1]

The clinical features of brucellosis infection vary and are nonspecific. Constitutional symptoms including fevers, sweats, weight loss, and anorexia may be acute or insidious in onset. More focal symptoms and physical exam findings reflect which organ or organ systems are affected. Gastrointestinal and hepatobiliary involvement is commonly noted, afflicting up to 70% of patients with brucellosis. Endocarditis occurs in less than 2% of cases, but accounts for the majority of brucellosis-related deaths.[1] In a series of 21 children affected with brucellosis, fever (91%), arthralgias or arthritis (83%), and hepato-and/or splenomegaly (63%) were the most common clinical manifestations.[3] Skeletal complications are reported in the majority of cases and include arthritis, spondylitis, osteomyelitis, tenosynovitis, and bursitis.[1] Brucellosis may affect the joints of the appendicular skeleton as either an infective monoarticular arthritis where the pathogen is isolated from the synovial fluid, or as a reactive arthritis with polyarticular involvement where no organism is isolated.[4] Over all, the sacroiliac articulation is the most commonly reported site of involvement.[2,5]

As the history and physical are nonspecific, diagnosis is usually difficult. Laboratory tests often reveal only subtle abnormalities such as mild elevation in inflammatory markers. Liver enzymes may be elevated.[3] Radiographic changes are also nonspecific, with findings

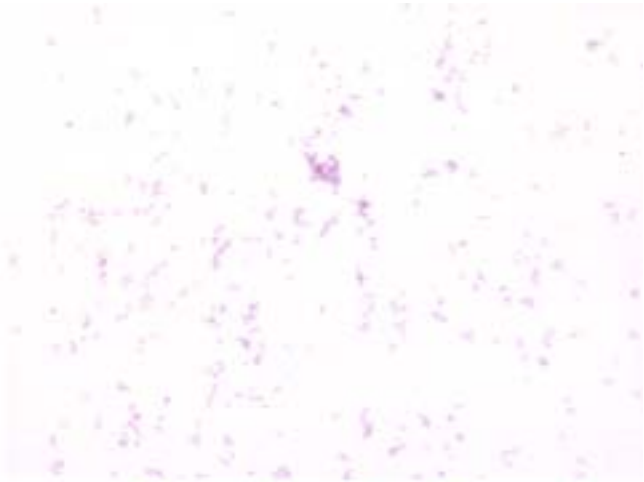

Figure 2: Gram-negative rods seen on a plate smear from sheep blood agar after 72 hours of incubation, computer-photographed at 1000X.

often mimicking slow growing neoplasms such as giant cell tumor or multiple myeloma. The presence of high or rising specific antibodies can support a presumptive diagnosis, but definitive diagnosis is made only when the pathogen is isolated from tissue.[1] Treatment is generally at least 6 weeks of dual agent antibiotic therapy.[1-3] Relapses are not uncommon, and chronic infection can result from persisting suppurative lesions in the bones, liver, spleen or kidneys.[1,3]

A number of cases of human brucellosis have been reported in the literature, most from countries other than the United States. The axial skeleton is most commonly affected[6-11]; other reported sites include the carpus[12], pubis[13], femur[14,15], and the calcaneus.[16] Multifocal brucella osteomyelitis involving both tibias and a humerus has also been reported.[17] Most patients were diagnosed only after months or years of symptoms, suggesting insufficient awareness of the disease.

Although uncommon, brucellosis should be regarded as a potential cause of musculoskeletal disease in a patient with exposure to animals.

ACKNOWLEDGMENTS

We would like to thank Gloria Scharnweber for her assistance with the microbiology slide preparation.

REFERENCES

1. **Mandell, G.L.,** *Principles and Practice of Infectious Diseases.* 5th ed. Vol. 2. 2000, Philadelphia: Churchill. 2386-93.
2. **Koopman, W.J.,** *Arthritis and Allied Conditions.* 14th ed. Vol. 2. 2001, Philadelphia: Lippincott Williams and Wilkins. 2576.
3. **Gottesman, G.,** et al., Childhood brucellosis in Israel. *Pediatr Infect Dis J,* 1996. 15(7): p. 610-5.
4. **Bulstrode, C.,** *Oxford Textbook of Orthopaedics and Trauma.* First ed. Vol. 2. 2002, Oxford: Oxford University Press. 1565-8.
5. **Gonzalez-Gay MA**, et al., Osteoarticular complications of brucellosis in an Atlantic area of Spain. *J Rheumatol,* 1999. 26(1): p. 141-5.
6. **Duyur, B., H.R. Erdem, and S. Ozgocmen,** Paravertebral abscess formation and knee arthritis due to brucellosis in a patient with rheumatoid arthritis. *Spinal Cord,* 2001. 39(10): p. 554-6.
7. **Moehring, H.D.,** Brucella sacroiliitis. A case report. *Orthopedics,* 1985. 8(4): p. 499-502.
8. **Ozgocmen, S.,** et al., Paravertebral abscess formation due to brucellosis in a patient with ankylosing spondylitis. *Joint Bone Spine,* 2001. 68(6): p. 521-4.
9. **Ozgocmen, S.,** et al., Brucella disc infection mimicking lumbar disc herniation: a case report. *Kaohsiung J Med Sci,* 1999. 15(12): p. 710-4.
10. **Samra, Y.,** et al., Brucellosis of the spine. A report of 3 cases. *J Bone Joint Surg Br,* 1982. 64(4): p. 429-31.
11. **Berrocal, A.,** et al., Sternoclavicular brucellar arthritis: a report of 7 cases and a review of the literature. *J Rheumatol,* 1993. 20(7): p. 1184-6.
12. **Seal PV, M.C.,** Brucellosis of the carpus. Report of a case. *J Bone Joint Surg Br,* 1974. 56(2): p. 327-30.
13. **Hoffman, C., R. Maran, and S.T. Zwas,** Case report: Brucella osteomyelitis of the pubic bone. *Clin Radiol,* 1996. 51(5): p. 368-70.
14. **Bonfiglio, M., M.R. Mickelson,** and **G.Y. El-Khoury,** Case report 221. Osteomyelitis of the left femur due to Brucella suis. *Skeletal Radiol,* 1983. 9(3): p. 208-11.
15. **Abrahams MA, T.C.,** Brucella osteomyelitis of a closed femur fracture. *Clin Orthop,* 1985. 195: p. 194-6.
16. **Tasdan, Y.,** et al., Brucella osteomyelitis of the calcaneus. *Pediatr Infect Dis J,* 1998. 17(7): p. 664-5.
17. **Zwass, A. and F. Feldman,** Case report 875: Multifocal osteomyelitis—a manifestation of chronic brucellosis. *Skeletal Radiol,* 1994. 23(8): p. 660-3.

HETEROGENEITY IN GROWTH PROPERTIES OF THE RAT SWARM CHONDROSARCOMA

Jeff W. Stevens

ABSTRACT

Chondrosarcoma remains one of the most difficult clinical conundrums of orthopaedic pathology, with wide variation in clinical course. The natural history of chondrosarcoma ranges from slow indolent growth without metastasis over years to rapid proliferation and lethal metastasis. Molecular regulatory events in the growth of these neoplasms are poorly understood. Of the Swarm rat chondrosarcoma, originating from a single neoplasm in a Sprague-Dawley rat more than thirty-five years ago, two populations were identified with different growth properties. These two Swarm chondrosarcoma lines were characterized for growth properties, histomorphometric and ultrastructural integrity, and the ability for proteoglycans to form aggregates with hyaluronan. After careful comparison, no obvious clues to the variation in growth rate were noted. Further molecular analyses may lead to better understanding of the differential growth properties of these cell lines. Understanding the mechanisms involved in differential growth rates may lead to clinically applicable clues to predict clinical behavior of chondrosarcomas in humans.

INTRODUCTION

Thirty-five years ago, an 18 month-old female Sprague-Dawley rat developed a spontaneous chondroblastic-osteogenic tumor in the thoracic and lumbar vertebrae.[7] The tumor was surgically harvested and has been since maintained as a source of mesenchymal tumor cells by serial subcutaneous transplantation.

Initially subcutaneous transplantation of the tumor into rats yielded similar histology of the original tumor with both ostoegenic and chondroblastic components. However, after several years of transplantation of the tumor the chondroblastic phenotype prevailed. The relatively stable resulting Swarm rat chondrosarcoma[2] cell lines have provided the standard source for in vitro study of the metabolic and biochemical properties of a cartilaginous-like tissue.[1-4,8-10] Nonetheless, different Swarm rat chondrosarcoma cell lines are not identical in attributes. Due to long term maintenance of the cell lines in many laboratories around the world, some lines have developed noticeable variations.

MATERIAL AND METHODS

Animal Care Unit of the University of Iowa approved animal protocol procedure was applied in all aspects of these studies. The SRC-JWS tumor originated from Drs. J. H. Kimura and V. C. Hascall at the NIDR, NIH (Bethesda, MD) in 1981 and the SRC-TRO tumor line from Dr. T. R. Oegema (Rush—St. Luke's Med Cntr, Chicago, IL). Procedures for transplantation and cell isolation were performed as previously described.[6] Tissue samples in paraffin sections were processed for safranin O and fast-green staining, identifying proteoglycan-rich extracellular matrix, as previously described.[11] Ultrastructural analysis of the tumor tissue was performed by transmission electron microscopy.[11] Radiolabelled proteoglycan was used to test each line's ability to form proteoglycan-hyaluronan ternary complex aggregates, as described by Kimata.[5]

RESULTS

Differences in subcutaneous tumor growth rates were observed between tumor lines (Table 1). Comparing tumor growth characteristics of the two tumor lines, the SRC-JWS tumor slurry resulted in the first appearance of growth occurring at day 11, while for the SRC-TRO, growth was not apparent until day 18. Paralleling the difference in the first appearance of tumor growth, a 35-gram tumor is obtained at day 21 for the SRC-JWS tumor line, and for the SRC-TRO line an 11-gram tumor is obtained at 35 days (Figure 1).

Histomorphology and ultrastructural analysis is presented in Figure 2. Tumors from both cell lines were composed of chondrocyte-like cells with a surrounding matrix composed of proteoglycans (as indicated by safranin O staining in Figure 2, panels A and C) and collagen fibrils (Figure 2, panels B and D, arrows). The tumor cells from both lines have the appearance of a

Department of Orthopaedics and Surgery
Ignacio V. Ponseti Laboratory of Biochemistry
and Molecular Biology
The University of Iowa
Iowa City, Iowa 52242-1181
Phone: 319/335-7550
Fax: 319/335-7968
E-mail: jeff-stevens@uiowa.edu

TABLE 1
Growth of Subcutaneous Tumor Inoculated from a Tumor Slurry and Cells Suspension

Line	Source/mode of transplantation	Injection (cells)	Sign of tumor (day)	Harvest (day)	Yield (gm/site)	n=
SRC-JWS	subcutaneous tumor/slurry*	~$1x10^6$	11	21	35.05±5.66	4
SRC-JWS	frozen tumor cells/cells	$1x10^6$	11	24	44.07±8.00	3
SRC-JWS	subcutaneous tumor/cells	$1x10^6$	Not determined	21	36.02±11.99	6
SRC-TGO	subcutaneous tumor/slurry	~$1x10^6$	18	35	10.73±3.46	4

*slurry: ~$7.5x10^6$ cells/g tumor, inject 125 µl (~$1x10^6$ cells)

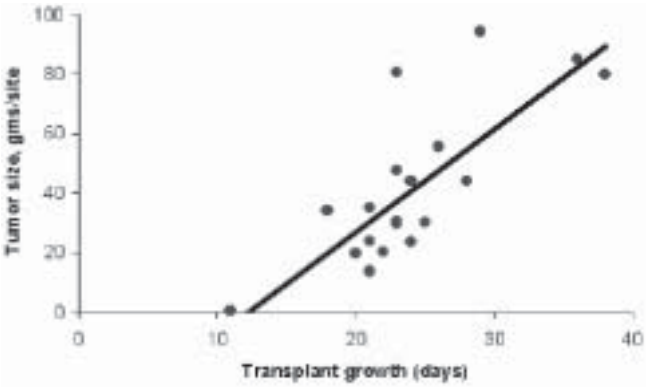

Figure 1. Growth of the SRC-JWS rat Swarm chondrosarcoma line following subcutaneous transplantation of cell ($1x10^6$) suspension over a 9-year period in maintaining the tumor. Each point is presented as the means of 2-16 subcutaneous injections, totaling 119 transplantations. A doubling rate of 5.76 days is calculated from the best-fit line.

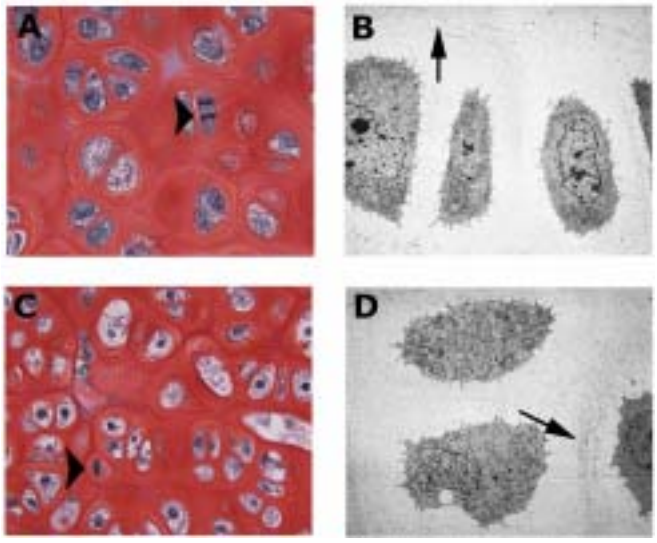

Figure 2. Histomorphometric and ultrastructural analyses of SRC-JWS (panels A & B) and SRC-TRO (panels C & D). Safranin O positive staining (panels A & C), identifying the proteoglycan-rich extracellular matrix. Mitotic bodies are identified by arrowheads, demonstrating active cell proliferation occurring within the tumor (panels A & C). Collagen fibrils are identified forming ring structures around the cells demarcating the interteritorial-territorial interface between cells (panels B & D, large arrow). Similar ultrastructural analysis is observed with chondrocyte-like cells containing many rough endoplasmic reticulum cisternae.

chondrocytes with plentiful rough endoplasmic reticulum and Golgi apparatus for the synthesis and secretion of matrix molecules. Interterritorial-territorial interfaces of the matrix are demarcated with rings of collagen fibrils around the chondrocyte-like cells.

Of the SRC-JWS tumor, a higher percentage of mitotic figures (Figure 2, panel A, arrow head) were observed when compared to the SRC-TRO tumor, supporting the presence of different cell proliferation rates, and not differential matrix mass production as a lone source of tumor size variation. Under light microscopy, the lacunae of the SRC-TRO (Figure 2, panel C) were frequently found to be relatively collapsed compared to SRC-JWS (Figure 2, panel A) tumors. However, at the transmission electron microscopy level the territorial region showed no marked differences between the two tumor lines.

DISCUSSION

Even after twenty years of serial subcutaneous transplantation, the SRC-JWS tumor line has maintained a consistent phenotype. Comparing the data from this study with the line's characteristics 20 years ago, finds little change. Specifically noted, were the following: 1) cell density of $1x10^7$ cells per gram of tumor by Kimura[7] and a $0.7x10^7$ cells per gram of tumor from this study, 2) maintained ability of proteoglycan to form a proteoglycan-hyaluronan aggregating complex, 3) consistent growth rate of a 20-gram tumor in 3 weeks, and 4) unchanged histological and ultrastructural analyses. Likewise, the SRC-TRO tumor has similar characteristics to the initial transplantation studies.[7] Despite long-term phenotypic stability in both lines, marked differences were noted between them. The SRC-JWS tumor line underwent genetic changes from the original lines, to become more proliferate, sometime prior to 1981. These genetic changes did not apparently produce genetic instability. This makes such changes all the more searchable to further genetic study.

This study has identified among Swarm rat chondrosarcoma cell lines, two with markedly different growth rates. Stable cell lines with different clinically important characteristics, such as growth rate, can provide a useful tool for studying the molecular mechanisms behind the varied natural history of chondrosarcomas. Better understanding of the molecular basis for different tumor behaviors can introduce better diagnostic characterization strategies as well as novel therapeutic interventions for future patients with chondrosarcomas.

ACKNOWLEDGMENT

I would like to thank Gail Kurriger for the technical support in this study, Dr. Jerry A. Maynard for his assistance with transmission electron microscopy and Drs. James H. Kimura, Vincent C. Hascall, and Theodore R. Oegema, Jr. for the Swarm chondrosarcoma samples.

REFERENCE

1. **Caterson, B.; and Baker, J. R.:** The link proteins as specific components of cartilage proteoglycan aggregates in vivo. Associative extraction of proteoglycan aggregate from Swarm rat chondrosarcoma. *J. Biol. Chem.*, 254:2394-2399, 1979.
2. **Choi, H.U.; Meyer, K.; and Swarm, R.:** Mucopolysaccharide and protein-polysaccharide of a transplantable rat chondrosarcoma. *Proc. Natl. Acad. Sci. U. S. A.*, 68:877-879, 1971.
3. **Faltz, L.L.; Caputo, C.B., Kimura, J. H.; Schrode, J; and Hascall, V.C.:** Structure of the complex between hyaluronic acid, the hyaluronic acid-binding region, and the link protein of proteoglycan aggregates from the Swarm rat chondrosarcoma. *J. Biol. Chem*., 254:1381-1387, 1979.
4. **Fernandes, R. J.; Schmid, T. M.; Harkey, M. A.; and Eyre, D. R.:** Incomplete processing of type II procollagen by a rat chondrosarcoma cell line. *Eur. J. Biochem*., 247:620-624, 1997.
5. **Kimata, K.; Hascall, V.C.; Kimura, J.H.:** Mechanisms for dissociating proteoglycan aggregates. *J. Biol. Chem*., 257:3827-3832, 1982.
6. **Kimura, J. H.; Hardingham, T. E.; Hascall, V. C.; and Solursh, M.:** Biosynthesis of proteoglycans and their assembly into aggregates in cultures of chondrocytes from the Swarm rat chondrosarcoma. *J. Biol. Chem.*, 254:2600-2609, 1979.
7. **Maibenco, H.C.; Krehbiel, R.H.; and Nelson, D.:** Transplantable osteogenic tumor in the rat. *Cancer Res*., 27:362-366, 1967.
8. **Mason, R. M.; and Bansal, M. K.:** Different growth rates of Swarm chondrosarcoma in Lewis and Wistar rats correlate with different thyroid hormone levels. *Connect. Tissue Res*., 16:177-185, 1987.
9. **Oegema, T.R., Jr.; Hascall, V.C.; and Dzwiewiatkowski, D.D.:** Isolation and characterization of proteoglycans from the Swarm rat chondrosarcoma. *J. Biol. Chem*., 250:6151-6159, 1975.
10. **Oegema, T. R., Jr.; and Parzych, S.M.:** Effect of the retinoic acid analog Ro 11-1430 on proteoglycans of Swarm rat chondrosarcoma. *J. Natl. Cancer Inst.*, 67:99-106, 1981.
11. **Stevens, J.W.; Kurriger, G.L.; Carter, A.S.; and Maynard, J.A.:** CD44s expression in the developing and growing rat intervertebral disc. *Dev. Dynamics.* 219:381-390, 2000.

EFFECT OF CHEMOTHERAPY ON SEGMENTAL BONE HEALING ENHANCED BY rhBMP-2

Jose A. Morcuende, MD, PhD, Pablo Gomez MD, Jeffrey Stack MD, George Oji BS, James Martin PhD, Douglas C. Fredericks BS, and Joseph A. Buckwalter MD

ABSTRACT

Segmental bone defects are challenging clinical problems, and current surgical solutions are associated with high complication rates. In oncologic reconstructive surgery, bone healing will occur coincidently with the administration of chemotherapy to treat the underlying disease. Effective methods of graft modification or bone graft alternatives can be of great help clinically. A series of osteoinductive proteins (bone morphogenetic proteins or BMPs) has been described and shown to enhance bone formation in animal models. This study was designed to evaluate the effect of chemotherapy on bone healing enhanced by rhBMP-2. We used a critical-sized bone-defect rabbit model. Histological and radiological analysis showed that chemotherapy affects both the quantity and the quality of the bone enhanced by the addition of rhBMP-2. These results suggest that the effect of chemotherapy on bone formation could be related to inhibition in a specific pathway stimulated by the rhBMP-2.

INTRODUCTION

The loss of bone that follows operative resection of tumors, traumatic segmental bone loss, or developmental bone defects is a challenging problem. Autogenous, vascularized, and allogenic bone grafts, as well as endoprostheses have been demonstrated to be effective as solutions, but morbidity and complications continue to be troublesome and detract from long-term successful outcomes.[1,14] For example, cumulative rates of complication in oncology surgery approach fifty percent and include wound necrosis, infection, nonunion, fracture, prosthesis loosening, and immunologic complications.[19,23,25,26,28,30,33] In addition, chemotherapy, which has been proven to improve the relapse-free survival time of patients with certain primary bone sarcomas, must be initiated early in the treatment course and may be required for as long as a year after surgical resection.[11] Although chemotherapy is effective in controlling cancer cell growth, it also has systemic effects, especially in the bone marrow. Effective methods of graft modification, or bone graft alternatives to overcome these problems could be of great help clinically.

The formation, maintenance, and regeneration of bone are complex processes involving the interactions of many cellular elements with systemic and local regulators. Recent gains in understanding of the biology of fracture healing and the availability of specific macromolecules have resulted in the development of novel treatments for bone defects. A series of osteoinductive proteins (bone morphogenetic proteins or BMPs) has been described and shown to enhance bone formation in animal models.[1,2,6,9,15,29,31,35] The major capacity of BMPs is to induce the differentiation of both pre-osteoblastic cells and non-committed mesenchymal cells. In addition, using recombinant molecular techniques, BMPs can be produced in large quantities, thus paving the way for their potential use in the healing of bony segmental defects.

Evaluation of BMPs to date has been limited to the treatment of tibial nonunion, and applicability to other indications awaits further experimental and clinical research. For BMPs to be used in the treatment of musculoskeletal tumors it is imperative that we understand the modifying effects chemotherapy may have on the bone healing induced by BMPs. We developed a model in rabbits to evaluate the effects that chemotherapy has in the healing of critical-sized bone segmental defects[1] treated with insoluble bovine bone carriers added with recombinant human bone morphogenetic protein–2 (rhBMP-2).

MATERIAL AND METHODS

Experimental Design

Unilateral two-centimeter critical-segmental bone defects were created in the radial diaphyses of 45 young adult New Zealand White rabbits. Six groups of animals were studied: Group 1: The defect was left empty (untreated controls); Group 2: Defect filled with a collagen-carrier containing zero micrograms of rhBMP-2; Group

Department of Orthopedics and Rehabilitation
University of Iowa Hospitals and Clinics

Address correspondence to:
Jose A. Morcuende, MD, PhD
200 Hawkins Drive
Iowa City, IA 52242
319-384-8041 Tel
319-353-7919 Fax
jose-morcuende@uiowa.edu**Abstract**

TABLE 1
Radiographic measurements at eighth week

Group	*Average Initial Defect (mm)*	*Defect Void*	*Defect Bridging*
Control	21	2 of 9	7 of 9
Control +Chemo	25	4 of 6	5 of 6
Helistat	27	2 of 9	7 of 9
Helistat + Chemo	24	4 of 7	3 of 7
rhBMP2	23	0 of 9	9 of 9
rhBMP2+Chemo	25	3 of 5	2 of 5

3: Defect filled with a collagen-carrier containing thirty micrograms of rhBMP-2; Groups 4, 5, 6: Same as surgically treated groups one, two and three, but each group received intravenous doxorubicin and cisplatin. This study was approved by our institutional Animal Care and Use Committee.

Operative Procedure

The surgical approach to the radius was identical in all rabbits. All operative procedures were performed in a surgical suite using intravenous anesthesia with Ketamine/Xylazine/Acepromazine as described.[1] Cephalothin (40 mg/kg), was administered prior to surgery and twice a day for two days postoperatively. A four-centimeter superomedial incision was made and the soft tissues overlying the radial diaphysis were dissected. A two-centimeter bone segment was removed with the use of an oscillating saw and the defect was filled with the experimental delivery system. Muscle, fascia and skin were closed in a standard fashion. The animals were monitored closely for signs of discomfort or surgical complications post-operatively. Analgesics were administered based on observation by a veterinarian as individually needed to insure the animals' comfort. Throughout the experiment, all animals remained individually caged.

Preparation and Placement of the Delivery System Containing rhBMP-2

The experimental delivery system consisted of a carrier of insoluble bovine bone collagen (Helistat, Integra Life Sciences, Painsbore, NJ) reconstituted with zero (Groups two and five) or 30 micrograms (Groups three and six) of recombinant human bone morphogenetic protein–2 (rhBMP-2) (Genetics Institute, Andover, MA). At the time of the operation, the sterilized collagen carrier was loaded with the reconstituted rhBMP-2. After the twenty-millimeter bone segment had been removed, the gap was irrigated with sterile warm normal saline and the delivery system was positioned in the defect. The muscles, augmented by the soft-tissue closure, retained the graft.

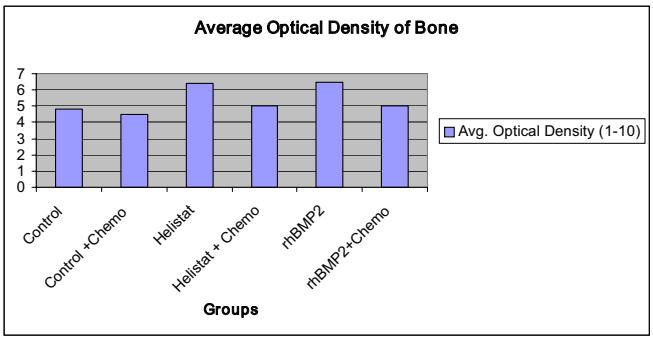

Figure 1. Average radiographic optical density at eight weeks

Doxorubicin and Cisplatin Treatment

The chemotherapy groups (Groups 4, 5 and 6) received 2.5 milligrams per kilogram of body weight of both doxorubicin and cisplatin intravenously four days before the index operation and again at seven and 14 days after the procedure. Hydration during drug administration was performed to decrease nephrotoxicity.

Radiographic Methods

All the rabbits were radiographed postoperatively and at weekly intervals. To insure proper positioning during radiographs, all rabbits were anesthetized with ketamine/xylazine/acepromazine IM. Antero-posterior and lateral radiographs were taken at weekly intervals to evaluate bone healing. The radiographs were interpreted by three of the investigators who were blind to treatment type. Radiographic evaluation was performed by measuring the area of periosteal callus and diaphyseal bone at the osteotomy site using digitized images of the x-rays. Periosteal callus and diaphyseal bone were outlined along the bone between the two bone ends in both the lateral and antero-posterior films. The area was calculated from each view and is expressed as a ratio of periosteal callus to diaphyseal bone. Image J analysis software (NIH) was used for the analysis.

Histological Methods

After the animals were euthanized, radii specimens were stripped of surrounding soft tissues (except directly over the fracture site), fixed in ten percent neutral buffered formalin and decalcified in four percent formic acid for seven to ten days. Specimens were then embedded in paraffin and sectioned longitudinally (5m thick). Three sections from the middle of the diaphysis were stained with hematoxylin and eosin. Stained sections were photographed and magnified 140 times to create an enlarged print of the fracture. Using Image J analysis software (NIH), the relative proportion of bone fracture callus was determined. Points that fall on cor-



Figure 2. Radiograph of a rabbit treated with Helistat and BMP at eight weeks. Note the complete fusion at both ends of the created gap with the formation of a totally recanalized bone, with cortical bone formation both in the medial and the lateral cortex.

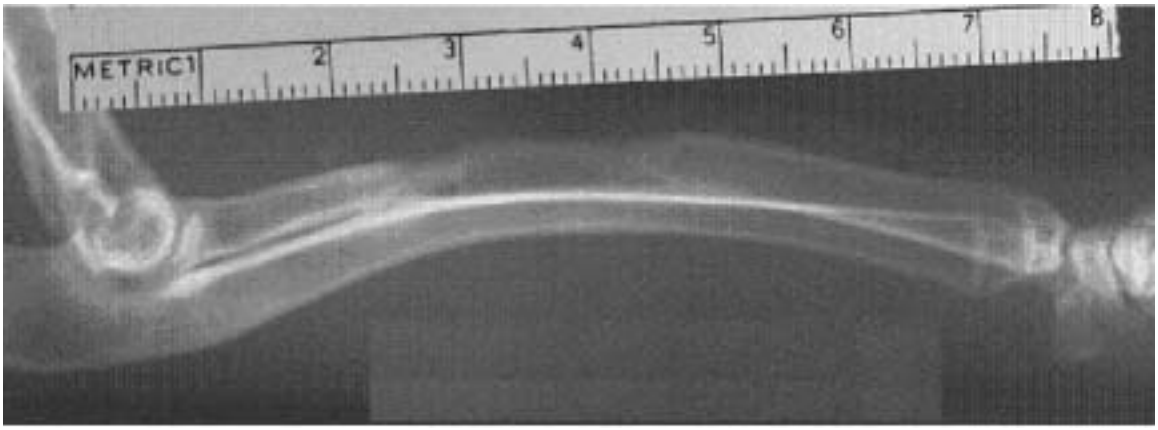

Figure 3. Radiograph of a rabbit treated with Helistat, BMP and chemotherapy at eight weeks. The bone density is decreased when compared with group 5. Note that the bone formed does not have the new medullary channel formation as noted in the previous groups.

tical bone, artifacts, fibrin clot or blood vessels were subtracted from the total number of points.

RESULTS

Radiographic Analysis

A bone bridge developed at two weeks after the procedure in the groups where we used the insoluble bovine bone collagen carrier. Although we found no statistically significant difference between the average optical densities in the different groups, increase in the bone density and area was evident during the next four weeks. The use of BMP improved both area and density of the new bone formation and the quality of bone: the cortical bone formation and the appearance of a new medullary cavity were more evident in the animals treated with BMP. The addition of chemotherapy resulted in impairment of bone formation, with a decrease in the area and density of new bone (Table 1). In the different groups the findings were:

Controls: Although no bone formation was expected from this group, the fact that the rabbits studied were still young adults allowed for some bone formation in the gaps. This probably was due to the remaining periosteum not resected during the surgical procedures (Table 1, Figure 1).

Insoluble bovine bone collagen carrier: Bone formation started at two weeks and progressed through weeks four and six in a uniform fashion. The new bone was fused to the edges of the radius by the end of week two, and there were signs of recanalization of the medullary cavity by the eighth week. Seven of the nine cases bridged the gap and the average optical density was 6.4 (Table 1, Figure 1).

Insoluble bovine bone collagen carrier plus BMP: Bone formation started earlier in this group and was advanced by the second week, with important bone formation and central recanalization of the medullary cavity by the end of week eight (Figure 1). Cortical bone was apparent in the X ray images at that time (Figure 2). The gap was bridged in all the cases, improving the results of the group without BMP addition. The average optical density obtained (6.5) was the highest in all groups (Table 1, Figure 1).

Insoluble bovine bone collagen carrier plus Chemotherapy: Bone formation started at two weeks and progressed in amount of bone and density. The bone was fused to the radius extremes by the end of week two and there were signs of recanalization of the medullary cavity by week six. However, the gap had a void in four of seven cases, showing a deleterious effect of the che-

motherapy in this area. The average optical density was 5, which was less than the density in the group without chemotherapy (Table 1, Figure 1).

Insoluble bovine bone collagen carrier plus BMP plus chemotherapy: Bone formation was evident by the second week, with progression in area and density over the next four weeks. There was a tendency toward recanalization of the medullary cavity by the end of the eighth week (Figure 3). There was an important decrease in the bridging with a failure to accomplishing it in three out of five cases. The average optical density of 5 was also decreased compared to the group without chemotherapy.

Histological Analysis

Controls: There was some bone formation in non-treated rabbits, with minimal periosteal bone formation of immature bone. The area of bone formation was 566 pixels. For the control-plus-chemotherapy group the area was 415 pixels using Image J software.

Insoluble bovine bone collagen carrier: The bone formed in this group was characteristically woven, non-organized bone, with recanalization of the medullary cavity at both extremes in the union with the normal radius. There were no signs of inflammation, fibrous tissue or foreign body reaction in any of the cases. The area of bone formation was 375 pixels using Image J software.

Insoluble bovine bone collagen carrier plus chemotherapy: Characteristically, these cases formed poor organized woven bone. This osseous tissue filled the osteotomy gap, and there was complete fusion with the cortices at both sides of the radius. There were no signs of inflammation, fibrosis, foreign body reaction or cartilage formation. The area of bone formation was 880 pixels using Image J software.

Insoluble bovine bone collagen carrier plus BMP: An improvement in bone organization was noted in this group, with complete recanalization of the medullary cavity in two cases and formation of cortical bone bridging the osteotomy. The amount of new bone formation was improved when compared to the non-BMP treated groups, and the bone unions were completely fused at both ends of the radius. In these cases there were no signs of inflammation, foreign body reaction, fibrosis or cartilage formation. The area of bone formation was 1110 pixels using Image J software (Figure 4).

Insoluble bovine bone collagen carrier plus BMP plus chemotherapy: There was a decrease in the quality of the bone formed in these cases with less bone area, more woven bone appearance, and less cortical bone formation. However, there was full bone fusion at the ends of the radius. There were no signs of inflammation, foreign body reaction, infection or formation of fibrous or cartilaginous tissue. The area of bone formation was 940 pixels using Image J software (Figure 5).

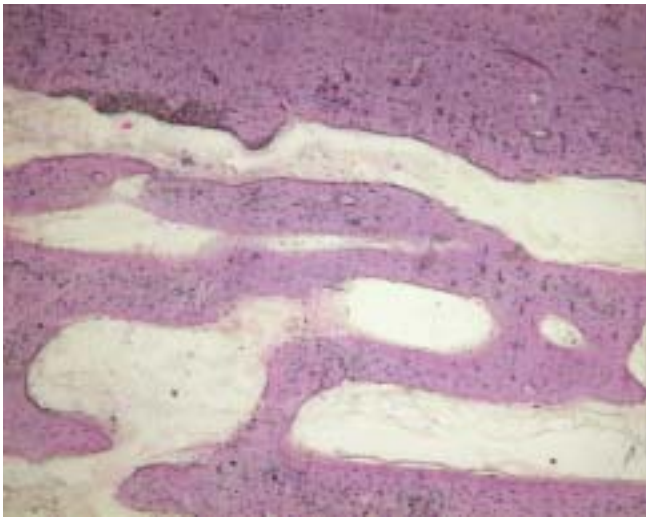

Figure 4. Histological image of the bone formed after eight weeks in an animal treated with Helistat and BMP. Note lamellar organization of the bone in the cortices and the formation of a medullary cavity. There is no evidence of foreign body reaction or fibrous tissue formation.

DISCUSSION

Limb reconstruction after tumor resection continues to be a major challenge in orthopaedic oncology. Many techniques are available, but the most appropriate choice is dictated by local tumor factors (size, location, stage, etc.) and patient factors (age, activity level, systemic disease, etc.). The skeletally immature patient presents special problems, including increased demands on the reconstructed limb, risk for growth disturbances, and the need for long-term optimal results.[14] Factors considered to affect bone healing include inadequate soft-tissue coverage, need for multiple surgeries, and adjuvant chemotherapy or radiation therapy.[16,30] The search for an acceptable substitute for autogenous and allograft bone has involved proteins that induce bone formation *in vivo*.

The molecular cloning of the bone morphogenetic proteins and their subsequent expression in recombinant systems has permitted the use of these molecules in a variety of experimental models.[1,2,6,15,29,31,35] Fifteen BMPs have been characterized and cloned so far. The BMPs are multifunctional proteins and have various effects on cell growth and differentiation according to dosage and cell type. The major characteristic of BMPs is their capacity to induce differentiation of both pre-osteoblasts and non-committed mesenchymal cells. Unlike tissue growth factor beta (TGFb), this potential to commit mesenchymal cells to differentiation is spe-

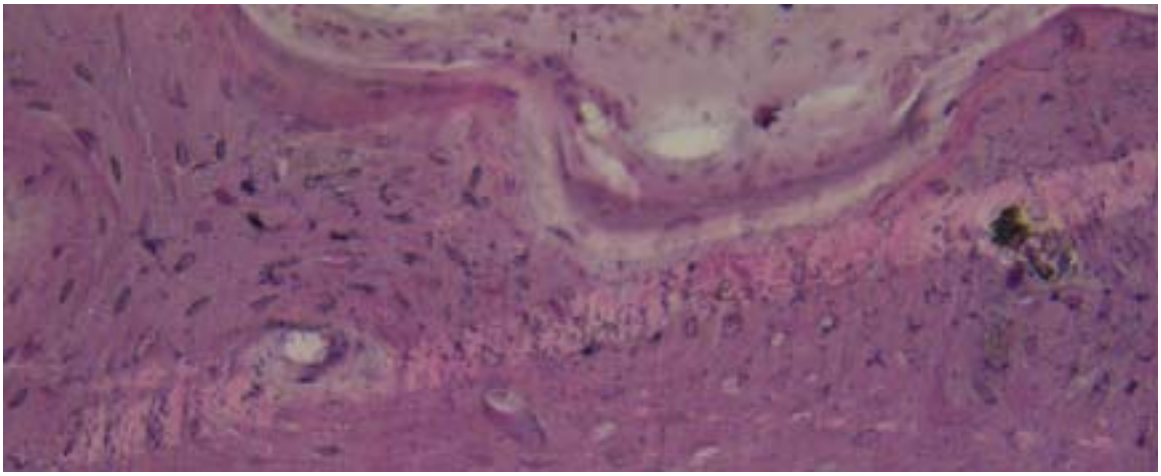

Figure 5. Histological image of the bone formed after eight weeks in an animal treated with Helistat, BMP and chemotherapy. Note the woven orientation of the bone with no cortical organization. No signs of inflammation or foreign body reaction.

cific to BMPs. The effect of BMPs on cell proliferation is variable: Proliferation of osteosarcoma cells is stimulated by BMP-7 and BMP-2, while proliferation of osteoblasts is stimulated by BMP-7, but inhibited by BMP-2 *in vitro*. The ability of rhBMP-2 to stimulate local bone formation was observed in this study as accelerated callus formation and maturation demonstrated by the histologic and radiographic results. This accelerated bone induction was presumed to be an effect of rhBMP-2's well-documented ability to induce the local differentiation of uncommitted mesenchymal and osteoblast precursor cells into osteoblasts.[26,19] This study, in accordance with previous reports,[1,2] shows an improvement in bone healing in a model of critical-sized bone defects treated with bone collagen carriers and rhBMP-2 compared to normal controls.

Importantly, almost all patients with a high-grade bone sarcoma will have adjuvant chemotherapy that must be initiated early in the reconstructive plan and may be required for as long as a year after surgery.[10,11] Many chemotherapeutic drugs used in adjuvant tumor treatment are known to exert their effects on rapidly proliferating cells. Standard doses of many chemotherapeutic agents cause temporary bone marrow suppression occurring one to two weeks post-administration. Therefore chemotherapy, when used in combination with limb salvage procedures, may inhibit bone formation. Combination therapy with doxorubicin (Adriamycin) and cisplatin has been found to be an effective treatment of bone sarcomas.[3,24] Doxorubicin exerts its cytostatic effect by intercalating between DNA base pairs, thus inhibiting DNA synthesis and DNA-dependent RNA synthesis. Cisplatin is thought to act by producing inter- and intra-strand cross-links of cellular DNA, thus inhibiting transcription. The use of this drug combination in adjuvant treatment of musculoskeletal tumors has resulted in greatly improved results.[10,11,24]

The consequences of chemotherapy administration on the process of bone formation remain controversial. Negative effects on bone healing and bone turnover have been found with reduced bone formation, both in normal bone and after fracture, and delay of the incorporation of autografts in segmental cortical defects in animal models. [4,7,8,12,13,17,18,20,22,27] Nilsson et al.[18] evaluated the effect of doxorubicin and methotrexate on orthotopic bone and on the induction of experimental heterotopic bone in rats. They found that doxorubicin treatment, at the time of implantation of bone matrix, caused reduced amounts of bone formation (30-35 percent) in heterotopic bone, whereas orthotopic bone was unaffected. However, six weeks after the treatment the net effect on the induced bone decreased. The results suggested that bone formation is sensitive to inhibition by anti-neoplastic agents, especially in conditions in which recruitment of new bone-forming cells is required. Similar conclusions can be drawn from a rat study by Pelker et al.[20] who studied doxorubicin and methotrexate in a rat osteotomy model. They found a significant decrease in the torsional strength of healing osteotomies in animals receiving chemotherapy while observing no strength difference between intact bones of treated animals and controls. Khoo[31] looked at the effects of preoperative doxorubicin on wound and bone healing in rabbit femoral fractures and reported decreases in wound breaking strength and torsional bone strength in animals that received the agent within one week of surgery. Prevot et al.,[21] using lengthening of adult rabbit tibias, found a slight delay in ossification when methotrexate and doxorubicin were used.

Like doxorubicin, cisplatin has also been demonstrated to alter bone and soft tissue healing in animal models. Zart et al.[34] studied the effect of cisplatin on syngenic and allogenic cortical bone graft incorporation in rats. This work demonstrated smaller total bone areas in the grafts of cisplatin-treated animals. They also

found that revascularization and host-graft union were both slower in cisplatin-treated animals compared to controls. These differences were more pronounced in the animals receiving frozen allografts than in those getting the fresh synthetic grafts. Young et al.,[32] using diaphyseal segmental replacement in dogs, observed that cisplatin in the postoperative period caused a delay in extra-cortical formation and significantly reduced both graft resorption and new bone formation.

In this study we found that chemotherapy affects both the quantity and the quality of the bone enhanced by the addition of rhBMP-2 to a collagen matrix. One possible mechanism would be an increase in the chemotherapy related apoptosis of dividing cells previously stimulated by BMP since the therapeutic agents used in this study act in actively dividing cells. Also, since BMP stimulates cell division and differentiation by activating the cells' DNA machinery, this could create an increased number of cells that chemotherapy could target.

REFERENCES

1. **Bostrom M, Lane JM, Tomin E.** Use of bone morphogenetic protein-2 in the rabbit ulnar non-union model. *Clin Orthop* 327:272-282, 1996.
2. **Boyne PJ, Mark RE, Nevins M.** A feasibility study evaluating rhBMP-2/absorbable collagen sponge for maxillary sinus floor augmentation. *Int J Periodontics and Restorative Dentistry*, 17:11-25, 1997.
3. **Bramwell VHC, Burgers M, Sneath R.** A comparison of two short intensive chemotherapy regimens in operable osteosarcoma of limbs in children and young adults. *J Clin Oncol* 10:1579-1591, 1992.
4. **Buchardt H, Glwczewskie Jr FP, Enneking WF.** The effect of Adriamycin and methotrexate on the repair of segmental cortical autografts in dogs. *J Bone Joint Surg* 65A:103-108, 1983.
5. **Chen F, Mao T, Tao K, Chen S, Ding G, Gu X.** Bone graft in the shape of human mandibular condyle reconstruction via seeding marrow-derived osteoblasts into porous coral in a nude mice model. *J Oral Maxillofac Surg.* 2002 Oct;60(10):1155-9.
6. **Croteau S, Rauch F, Silvestri A, Hamdy RC.** Bone morphogenetic proteins in orthopaedics: from basic science to clinical practice. *Orthopaedics* 22(7):686-695, 1999.
7. **Friedlaender A, Goodman A, Hausman M, Trojano N.** The effects of methotrexate and radiation therapy on histologic aspect of fracture healing. *Trans Orthop Res Soc* 8:224, 1983.
8. **Friedlaender GE, Tross RB, Doganis AC, Kirkwood JM, Baron R.** Effects of chemotherapeutic agents on bone. I. Short-term methotrexate and doxorubicin (Adriamycin) treatment in a rat model. *J Bone Joint Surg* 66A:602-607, 1984.
9. **Gehart TN, Kiker-Head CA, Kriz MJ.** Healing segmental femoral defects in sheep using recombinant human bone morphogenetic protein. *Clin Orthop* 293:317-326, 1993.
10. **Goldman S, Nachman J.** General principles of Chemotherapy. In *Surgery for bone and soft-tissue tumors.* Edited by MA Simon and D Springfield. Lippincott-Raven, Philadelphia, pp. 97-104. 1998.
11. **Gorin A.** Chemotherapy of osteosarcoma and Ewing's sarcoma. In *Surgery for bone and soft-tissue tumors.* Edited by MA Simon and D Springfield. Lippincott-Raven, Philadelphia, pp. 239-244. 1998.
12. **Gravel C, Lee T, Chapman M.** Distraction osteogenesis following chemotherapy in the goat model. *Trans Orthop Res Soc* 19:235, 1994.
13. **Hajj a, Mnaymneth W, Ghandur-Mnaymneh L, Latta L.** The effect of methotrexate on the healing of rat femora. *Trans Orthop Res Soc* 6:79, 1981.
14. **Kenan S, Lewis MM, Peabody TD.** Special considerations for growing children. In *Surgery for bone and soft-tissue tumors.* Edited by MA Simon and D Springfield. Lippincott-Raven, Philadelphia, pp. 245-264. 1998.
15. **Kirker-Head CA, Nevins M, Palmer R.** A new animal model for maxillary sinus floor augmentation: evaluation parameters. *Int J Oral Maxillofac Implants*, 12:403-411, 1997.
16. **Lord CF, Gebhart MC, Tomford WW, Mankin HJ.** Infection in bone allografts, incidence, nature, and treatment. *J Bone Joint Surg* [Am] 70:369. 1988.
17. **Nesbit M, Kriwi W, Heyn R, Sharp H.** Acute and chronic effects of methotrexate on hepatic, pulmonary and skeletal systems. *Cancer* 37:1048-1054, 1976.
18. **Nilsson OS, Bauer HCF, Brostrom LA.** Comparison of the effects of adryamycin and methotrexate on orthotopic and induced heterotopic bone in rats. *J Orthop Res* 8:199-204, 1990.
19. **Peabody TD, Eckardt JJ.** Complications of prosthetic reconstructions. In *Surgery for bone and soft-tissue tumors.* Edited by MA Simon and D Springfield. Lippincott-Raven, Philadelphia, pp. 481-486. 1998.
20. **Pelker RR, Friedlaender GE, Panjabi MM.** Chemotherapy-induced alterations in the biomechanics of rat bone. *J Orthop Res* 3:91-95, 1985.
21. **Prevot J, Poncelet T, Lemelle J.** Etude de l'osteogenese en distraction sur un organisme animal soumis a une chimiotherapie anti-cancereuse. *Chir Pediatr* 29:226-230, 1988.
22. **Ragab AH, Frech RS, Vietti TJ.** Osteoporotic fractures secondary to methotrexate therapy of acute leukemia in remission. *Cancer* 25:580-585, 1970.

23. **Simonds RJ, Holmberg SD, Hurwitz RL.** Transmission of human immunodeficiency virus type I from a sero-negative organ and tissue donor. *N Engl J Med*, 326:726. 1992.
24. **Souhami RL, Craft AW, Van der Eijken JW.** Randomised trial of two regimens of chemotherapy in operable osteosarcoma: a study of the European Osteosarcoma Intergroup. *Lancet* 350:911-917, 1997.
25. **Stevenson S, and Horowitz M.** The response to bone allografts. *J Bone Joint Surg* [Am] 74:939, 1992.
26. **Tomford WW, and Bloem RM.** The biology of autografts and allografts. In *Surgery for bone and soft-tissue tumors*. Edited by MA Simon and D Sprienfield. Lippincott-Raven, Philadelphia, pp 481-485, 1998.
27. **Tsuchiya H, Tomita K, Minematsu K.** Limb salvage using distraction osteogenesis: a classification of the technique. *J Bone Joint Surg*, 79B:403-411, 1997.
28. **Ward, J.** Update on AIDS transmission. Presented at the Musculoskeletal Transplant Foundation International Symposium on Bone and Soft Tissue Allografts. April 27-30, Washington DC, 1995.
29. **Welch RD, Jones AL, Bucholz RW.** Recombinant human BMP-2/absorbable collagen sponge device enhanced healing in a goat tibial fracture model. *Trans Orthop Res Soc* 42:201, 1996.
30. **Wilkins RM.** Complications of allograft reconstructions. In *Surgery for bone and soft-tissue tumors*. Edited by MA Simon and D Springfield. Lippincott-Raven, Philadelphia, pp. 487-496. 1998.
31. **Yasko AW, Lane JM, Fellinger EJ.** The healing of segmental bone defects, induced by recombinant bone morphogenetic protein (rh BMP-2). *J Bone Joint Surg*, 74A:659-671. 1992.
32. **Young DR, Shih LY, Rock MG.** Effect of cisplatin chemotherapy on extracortical tissue formation in canine diaphyseal segmental replacement. *J Bone Joint Surg* 15:773-780. 1997.
33. **Younger EM, and Chapman MW.** Morbidity at bone graft donor sites. *J Orthop Trauma*, 3:192. 1989.
34. **Zart DJ, Miya L, Wolff DA.** The effects of cisplatin on the incorporation of fresh syngenic and frozen allogenic cortical bone grafts. *J Orthop Res* 11:240-249, 1993.
35. **Zegzula HD, Buck DC, Brekke J, Wozney JM, Hollinger JO.** Bone formation with use of rhBMP-2 (recombinant human bone morphogenetic protein-2) *J Bone Joint Surg* 79A:1778-1790, 1997.

MEDIAL TRANSLATION OF THE HIP JOINT CENTER ASSOCIATED WITH THE BERNESE PERIACETABULAR OSTEOTOMY

John C. Clohisy, MD; Susan E. Barrett, MD; J. Eric Gordon, MD; Eliana D. Delgado, MD; and Perry L. Schoenecker, MD

ABSTRACT

This study assessed medial translation of the hip joint achieved by the Bernese periacetabular osteotomy (PAO) in correcting residual acetabular dysplasia deformities. 86 hips in 75 patients with an average age of 25 years (range, 12-50) were treated for symptomatic acetabular dysplasia with a periacetabular osteotomy. Radiographic analysis was performed to assess correction of the acetabular deformity with specific attention to the horizontal position of the hip joint center. All hips were followed until bony union of the iliac osteotomy and the average follow-up was 28 months. The lateral center edge angle improved an average 31.6˚ (-0.4˚ preoperative, 31.2˚ at follow-up). The anterior center edge angle improved 39.3˚ (-4.5˚ to 34.8˚). The acetabular roof obliquity improved an average 21.8˚ (25.1˚ to 3.3˚). Preoperatively, the average distance from the medial aspect of the femoral head to the ilioischial line was 17.6 mm. This distance was decreased to an average 7.8 mm postoperatively. This change resulted in an average medial translation of the hip joint center of 9.8 mm, (range -6 to 31mm). Overall, some degree of medial translation of the hip joint center was obtained in 79 (92%) of the hips. Four (5%) were maintained in the same horizontal position, and 3 (3%) had slight lateral repositioning. For the hips translated medially, the average change was 10.0 mm, and 72% of all hips had an optimal correction with the distance between the medial aspect of the femoral head and the ilioischial line being between 0 and 10 mm. This study demonstrates that in addition to optimizing femoral head coverage, a major and distinct advantage of the periacetabular osteotomy is reproducible and consistent medial translation of the hip joint center.

INTRODUCTION

Residual acetabular dysplasia is a complex, multiplanar deformity of the acetabulum that is characterized by deficient anterior and lateral femoral head coverage, superolateral inclination of the acetabular joint surface and a relative lateral position of the hip joint center.[10,28] The total articular surface area of the dysplastic acetabulum is reduced and version of the acetabulum may also be abnormal. Ideally, the goal of reconstructive osteotomy surgery is to correct all aspects of hip dysplasia which includes both acetabular reorientation and medial translation of the hip joint center. Medial translation is emphasized because it optimizes hip function by decreasing the gravitational lever arm, and therefore decreasing the joint reaction force.[1,2] Theoretically, this may enhance the longevity of the surgically corrected pre-arthritic or early arthritic hip.

A variety of pelvic osteotomies have been developed in order to address the deformities of the dysplastic acetabulum. These have included single[17], double[22], triple,[8,21,23] and spherical osteotomies.[5,16,27] The majority of these reconstructive techniques are limited in achieving consistent medial translation of the hip joint center, and major medial repositioning is not possible with some of these techniques. In contrast, the Bernese periacetabular osteotomy[4,10,14,20,19,25] enables major, multiplanar deformity corrections, including medial translation of the joint center. Nevertheless, there is limited literature describing the reproducibility and magnitude of medial translation of the hip joint achieved with the Bernese periacetabular osteotomy. The purpose of this study was to analyze our first 86 consecutive periacetabular osteotomies to assess acetabular reorientation and medial translation of the hip joint center achieved with this osteotomy.

Department of Orthopaedic Surgery
Barnes-Jewish Hospital at Washington University
School of Medicine and St. Louis Shriner's Hospital for Children
One Barnes-Jewish Hospital Plaza
11300 West Pavilion, Campus Box 8233
St. Louis, Missouri 63110

Correspondence to:
John C. Clohisy, MD
Barnes Jewish Hospital at Washington University
School of Medicine, Department of Orthopaedic Surgery and
St. Louis Shriners Hospital for Children
St. Louis, Missouri 63110
Telephone: 314-747-2566
FAX: 314-747-2599
e-mail: jclohisy@msnotes.wustl.edu

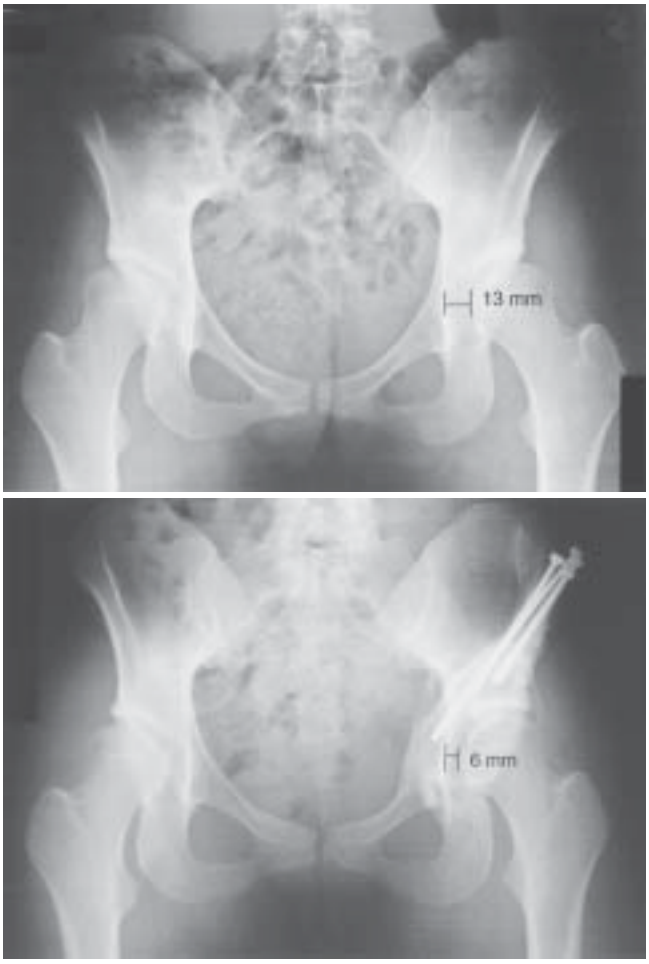

Figure 1. Preoperative (1a) and two year postoperative (1b) anteroposterior pelvic radiographs of an 18 year old female treated with a periacetabular osteotomy for symptomatic acetabular dysplasia. Medial translation of the hip center is demonstrated by the change in the distance from the ilioischial line to the medial aspect of the femoral head as indicated. The hip joint was translated medially 7 mm in this case.

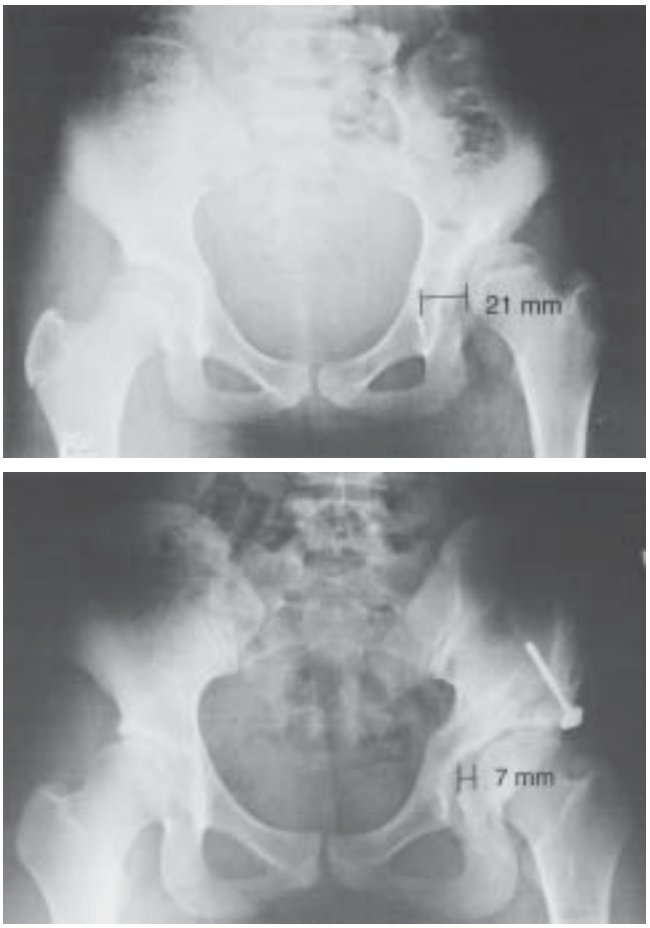

Figure 2. Preoperative (2a) and five year postoperative (2b) anteroposterior radiographs of a thirteen year old female with severe acetabular dyplasia and lateral femoral head subluxation. Major (15mm) medial translation of the hip joint was achieved in this case of severe dysplasia.

MATERIALS AND METHODS

Radiographic assessment was performed on 86 consecutive periacetabular osteotomies in 75 patients treated by the senior authors. All patients were treated at our institution hospitals and this group of patients represents our learning curve experience. There were 52 (58 hips) female patients and 23 (28 hips) male patients. The average age of the patients was 25 years (range, 12 to 50 years). All patients were skeletally mature at the time of surgery and had symptomatic acetabular dysplasia. Three patients had treatment during infancy with closed reduction and casting and five patients had open reduction and casting. Five patients had previous pelvic osteotomy surgery and four had previous femoral osteotomy surgery. Preoperative evaluation demonstrated a radiographically congruent hip joint and adequate range of motion to tolerate reorientation of the acetabulum. No patient had advanced osteoarthritis.

All osteotomies were performed on a radiolucent table. Intraoperative fluoroscopy was used to direct the osteotomy cuts and to assess acetabular reduction intraoperatively. Cell saver and spontaneous EMG monitoring were utilized throughout the procedure. The modified anterior[15] or the modified Smith Petersen approach[10,12] were used in all cases. A standard sequence of periacetabular cuts was performed as previously described.[4,10] Acetabular reduction was then achieved by first translating the acetabulum medially. After adequate medial translation was obtained, the acetabulum was

TABLE 1

	Pre-op	*Post-op*	*Average change*
Medial translation	17.6 mm	7.8 mm	9.8 mm
LCE angle	-0.4°	31.2°	31.6°
ACE angle	-4.5°	34.8°	39.3°
ARO	25.1°	3.3°	21.8°

Summary of radiographic correction in 86 hips treated with the periacetabular osteotomy. Values are shown for average medial translation, lateral center-edge (LCE) angle, anterior center-edge (ACE) angle and acetabular roof obliquity (ARO). The differences between preoperative and postoperative values are all significant at p<0.0005.

reoriented to achieve lateral coverage, anterior coverage, and maintain or obtain anteversion of the acetabulum. The osteotomy was then provisionally fixed with K-wires, and the acetabular reduction was assessed intraoperatively with fluoroscopy. Definitive acetabular fragment fixation was performed with 4.5 mm screws in the majority of cases and pelvic reconstruction plate fixation in selected cases. At the time of provisional acetabular reduction and after definitive fixation, we assessed lateral coverage of the femoral head, anterior coverage of the femoral head, the inclination of the acetabular joint surface, medial translation of the hip joint center, and version of the acetabulum. Care was taken to avoid excessive leg lengthening and over correction of the acetabulum anteriorly.

Postoperatively, patients were treated with 30 pounds partial weight bearing and no active hip flexion for six weeks. Over the following month, 50% weight bearing was allowed, with full weight bearing permitted at ten weeks postoperatively. Strengthening exercises were initiated six weeks postoperatively. Patients were gradually progressed to independent ambulation on an individual basis.

Radiographic analysis of these cases was performed by two of the authors (JCC, SEB). Standing AP and false profile views were assessed for all patients. These included preoperative, immediate postoperative, and final follow-up radiographs. Lateral center-edge angle[28], anterior center-edge angle[9], acetabular roof obliquity[11], and the hip joint center position in the vertical and horizontal planes were measured. The vertical position of the hip was determined by measuring the distance from a line drawn between the ischial tuberosities and the superior margin of the lesser tuberosities. The change in horizontal position of the hip center was determined by measuring the distance between the ilioischial line and the medial aspect of the femoral head (Figures 1 and 2). The distance measured postoperatively was subtracted from the preoperative distance to determine the change in the horizontal and vertical positions of the hip joint. Medial translation of the hip joint center was calculated by determining the relative position of the hip joint center on preoperative and postoperative radiographs. A change was considered significant if it demonstrated a difference greater than 2 millimeters. Osteotomy union was also assessed radiographically. Pre-operative values for all variables were compared to post-operative values using a Student's t-test.

RESULTS

Radiographic analysis was completed on all 86 hips in 75 patients. All hips were followed to bony union of the ilium and the average radiographic follow-up was 28 months (range, 13 to 62 months). No hips were lost to follow-up. Overall, radiographic corrections are summarized in Table 1. The lateral center edge angle improved from the preoperative average of –0.4° to a postoperative average of 31.2°. Anterior center edge angle improved from an average -4.5° to 34.8° postoperatively. The acetabular roof obliquity improved from 25.1° preoperatively to 3.3° postoperatively. The average distance from the most medial aspect of the femoral head to the ilioischial line on preoperative radiographs was 17.6 mm. This value decreased to an average 7.8 mm after surgery. Therefore, the average hip joint center was translated medially an average of 9.8 mm. All of these radiographic changes comparing preoperative and postoperative measurements were significant at $p < 0.0005$. Seventy-nine of 86 hips (92%) had some degree (>2mm) of medial translation, while four (5%) maintained the same horizontal position. Three hips (3%) had slight lateral repositioning not according to the preoperative plan. Sixty-two (72%) had an optimal correction with the postoperative distance between the ilioischial line and the medial aspect of the femoral head measuring between 0 and 10 mm. Inferior displacement of the hip center averaged 4.0 mm.

DISCUSSION

Various osteotomies have been designed to address the complex deformities associated with acetabular dysplasia.[1,4,5,8,16,17,21,22,23,27] For example, the Chiari osteotomy is a salvage procedure designed to enhance femoral head coverage with nonarticular fibrocartilage. In Chiari's original work, he emphasized the importance of decreasing the lever arm of the hip abductors in the lateral plane as a goal of osteotomy surgery.[1] Since that time, many osteotomies have been described, each with a varying ability to normalize joint biomechanics and correct the multiple associated deformities of the dysplastic hip. Hogh et al. reported on their results following 94 Chiari osteotomies in 81 patients.[6] Medial displacement was measured as the percentage of

displacement of the acetabular side of the osteotomy from its original location. In this study, the osteotomy was translated an average of 68% of the width of the ilium. However, by measuring the horizontal distance from the medial aspect of the femoral head to the most inferior point of the teardrop, he noted an average of 1 mm of lateral subluxation of the femoral head within the acetabulum. Therefore, while the hip joint center is displaced medially, the actual position of the femoral head within the acetabulum may be inconsistent. Kubo evaluated changes in hip center position using CT scans before and after Chiari osteotomies in 23 patients.[7] He documented an average medial displacement of the center of the hip joint of 6 mm. Therefore, these studies support the feasibility of medial translation of the hip joint center with the Chiari osteotomy. Nevertheless, despite some ability to achieve medial translation, the major weakness of the Chiari procedure is lack of femoral head coverage with articular hyaline cartilage. Rather, coverage is achieved with metaplastic fibrocartilage, which is suboptimal.

Salter described his innominate osteotomy as a treatment for hip dysplasia in both children and adults. In this procedure a single osteotomy allows the surgeon to rotate the acetabulum to improve both anterior and lateral coverage of the femoral head.[17] In our review of the literature, we found no studies which documented medial translation achieved with Salter's innominate osteotomy. Therefore, while the innominate osteotomy may theoretically improve on the Chiari by maintaining the congruity of the hip joint and enhancing articular cartilage coverage, the ability to reliably translate the hip joint medially, to our knowledge, has not been established.

Double and triple innominate osteotomies have also been employed in the treatment of acetabular dysplasia. Sutherland and Greenfield acknowledged the benefit of medial displacement in reconstructive pelvic osteotomy and proposed that one advantage of the double osteotomy over the Salter innominate osteotomy is the ability to translate the hip center toward the midline. They reported their results on 25 patients in whom they performed the double innominate osteotomy.[22] This procedure began with the iliac osteotomy described by Salter, but was then followed by a second osteotomy placed medial to the obturator foramen between the pubic tubercle and the symphysis pubis. Radiographic follow-up revealed an average measurement of 15 mm of medial translation.[22] In terms of medial translation of the hip, their data clearly improve on the correction obtained by the single osteotomy. Additionally, Steel proposed a triple innominate osteotomy with the intention of further improving the ability to correct the multiplanar deformity associated with developmental dysplasia of the hip.[21] Frick et al. reported on seven patients who underwent CT scanning before and after triple innominate osteotomy.[3] While these patients represented more complex cases which the authors felt required pre-operative CT evaluation, no significant change in horizontal position of the hip was found after surgery. Despite its small sample size, this study describes a decreased ability to reliably translate the hip joint center with a triple innominate osteotomy. These results reflect inherent difficulties in controlling the correction of a multiplanar deformity with a relatively large acetabular fragment that can be tethered with muscular and ligamentous attachments. Nevertheless, it should be noted that the Tönnis triple innominate osteotomy[23] may provide medial translation as the inferior osteotomy is superior to the sacrospinous ligamentous attachment which may facilitate acetabular repositioning.

Another class of osteotomies have been proposed and evaluated in terms of deformity correction in dysplastic hips. Wagner introduced the spherical osteotomy[27], and subsequently described the Type III modification of his original osteotomy. This Type III osteotomy was intended for treatment of patients with dysplasia characterized by lateralization of the hip center. In such cases, he performed his original spherical osteotomy, and then displaced the hip center medially via a combined Chiari osteotomy. Unfortunately, to our knowledge no data have been reported on the actual medial translation achieved by adding this modification to the procedure. His work does, however, reinforce the biomechanical principles of hip joint preservation by reduction in joint reactive force acting on the hip.

Nakamura, et al. reported on 97 patients in whom they performed a rotational acetabular osteotomy.[16] They found an average medial displacement of 7 mm measured from the medial border of the femoral head to the ilioischial line. In their study, 58 of 97 patients were optimally corrected, defined as translation of the hip 2.5 to 12.5 mm medial to its starting position. They achieved no change in the horizontal direction in 22 patients (22%). Twelve patients were overcorrected, defined as translation more than 12.5 mm, while 5 hips moved more than 2.5 mm in the lateral direction. Based on their criteria, 58% of patients were optimally corrected with respect to medial translation of the hip joint center.[16] Thus, the rotational acetabular osteotomy does enable medial translation in the majority of cases.

In attempts to improve on the rotational osteotomy, Hasegawa et al. describe an eccentric rotational osteotomy, which maintains all of the benefits of the spherical osteotomies, but also adds the ability to trans-

late the hip center toward the midline. They performed the procedure on 132 hips and found an average medial displacement of 4.1 mm.[5] While this data is promising, the amount of medial translation achieved appears to be less than that afforded by the PAO, and the operation is technically more demanding. Sotelo-Sanchez et al., in a recent review, state that the spherical osteotomies are limited in translating the hip joint center medially[18], since the medial aspect of the quadrilateral plate remains intact with these osteotomies.

Since its description[4], the Bernese periacetabular osteotomy has gained favor in terms of its ability to improve the acetabular position in multiple planes. Siebenrock et al. reported on their first 75 procedures in 63 patients and demonstrated an average correction of 6 mm of medial translation of the hip joint.[20] Other investigators[12,13 14 24 25 26] have also reported that, in general, medial translation of the acetabulum can be achieved with the periacetabular osteotomy. Nevertheless, the magnitude of correction and the reproducibility of medial translation has not been emphasized in the literature. Our data, collected from our learning curve experience, indicate that medial translation can be achieved consistently with this technique. Specifically, we obtained an average 9.8 mm of medial translation in our cases. Perhaps, more importantly, some degree of medial translation was obtained in 92% of hips and 72% were thought to have an optimal correction. Thus, in addition to major corrections of anterior and lateral femoral head coverage, reliable medial translation of the hip joint is a distinct advantage of the Bernese periacetabular osteotomy. This advantage is most notable in severely dysplastic hips with major lateral subluxation (Figure 2).

REFERENCES

1. **Chiari, K.:** Medial displacement osteotomy of the pelvis. *Clin Orthop,* 98: 55-71, 1974.
2. **Frankel, V. H., and Pugh, J. W.:** Biomechanics of the Hip. In *Surgery of the Hip Joint*, pp. 115-131. Edited by Tronzo, R. G., 115-131, New York, Springer-Verlag New York, Inc., 1984.
3. **Frick, S. L.; Kim, S. S.; and Wenger, D. R.:** Pre- and postoperative three-dimensional computed tomography analysis of triple innominate osteotomy for hip dysplasia. *J Pediatr Orthop,* 20(1): 116-23, 2000.
4. **Ganz, R.; Klaue, K.; Vinh, T. S.; and Mast, J. W.:** A new periacetabular osteotomy for the treatment of hip dysplasias. Technique and preliminary results. *Clin Orthop,* (232): 26-36, 1988.
5. **Hasegawa, Y.; Iwase, T.; Kitamura, S.; Yamauchi Ki, K.; Sakano, S.; and Iwata, H.:** Eccentric rotational acetabular osteotomy for acetabular dysplasia: follow-up of one hundred and thirty-two hips for five to ten years. *J Bone Joint Surg Am,* 84-A(3): 404-10, 2002.
6. **Hogh, J., and Macnicol, M. F.:** The Chiari pelvic osteotomy. A long-term review of clinical and radiographic results. *J Bone Joint Surg Br,* 69(3): 365-73, 1987.
7. **Kubo, M.:** Anatomical changes in the pelvis after modified Chiari pelvic osteotomy. *Kurume Med J,* 46(1): 9-15, 1999.
8. **LeCoeur, P.:** Corrections des de fauts d'orientation de l'articulation coxo-femorle par osteotomie de listhume iliaque. *Rev Chir Orthop,* 51: 211, 1965.
9. **Lequesne, M., and de, S.:** [False profile of the pelvis. A new radiographic incidence for the study of the hip. Its use in dysplasias and different coxopathies]. *Rev Rhum Mal Osteoartic,* 28: 643-52, 1961.
10. **Leunig, M.; Siebenrock, K. A.; and Ganz, R.:** Rationale of periacetabular osteotomy and background work. *J Bone Joint Surg Am,* 83: 438-448, 2001.
11. **Massie, W. K., and Howorth, M. B.:** Congenital dislocation of the hip. Part I. Methods of grading results. *J Bone Joint Surg Am,* (32A): 519, 1950.
12. **Matta, J. M.; Stover, M. D.; and Siebenrock, K.:** Periacetabular osteotomy through the Smith-Petersen approach. *Clin Orthop,* (363): 21-32, 1999.
13. **Mayo, K. A.; Trumble, S. J.; and Mast, J. W.:** Results of periacetabular osteotomy in patients with previous surgery for hip dysplasia. *Clin Orthop,* (363): 73-80, 1999.
14. **Millis, M.; Murphy, S.; and Poss, R.:** Osteotomies about the Hip for the Prevention and Treatment of Osteoarthrosis. *J Bone Joint Surg Am,* 77-A: 626-647, 1995.
15. **Murphy, S. B.; Millis, M. B.; and Hall, J. E.:** Surgical correction of acetabular dysplasia in the adult. A Boston experience. *Clin Orthop,* (363): 38-44, 1999.
16. **Nakamura, T.; Yamaura, M.; Nakamitu, S.; and Suzuki, K.:** The displacement of the femoral head by rotational acetabular osteotomy. A radiographic study of 97 subluxated hips. *Acta Orthop Scand,* 63(1): 33-6, 1992.
17. **Salter, R. A., and Thompson, G. H.:** "The role of osteotomy in young adults." Proceedings of the seventh open meeting of The Hip Society.: 278-312, 1979.
18. **Sanchez-Sotelo, J.; Trousdale, R. T.; Berry, D. J.; and Cabanela, M. E.:** Surgical treatment of developmental dysplasia of the hip in adults: I. Nonarthroplasty options. *J Am Acad Orthop Surg,* 10(5): 321-33, 2002.

19. **Siebenrock, K. A.; Leunig, M.; and Ganz, R.:** Periacetabular Osteotomy: The Bernese Experience. *J Bone Joint Surg Am,* 83-A(3): 449-455, 2001.
20. **Siebenrock, K. A.; Scholl, E.; Lottenbach, M.; and Ganz, R.:** Bernese periacetabular osteotomy. *Clin Orthop,* (363): 9-20, 1999.
21. **Steele, H. H.:** Triple osteotomy of the innominate bone. *J Bone Joint Surg Am,* 55(2): 343-50, 1973.
22. **Sutherland, D. H., and Greenfield, R.:** Double innominate osteotomy. *J Bone Joint Surg Am,* 59(8): 1082-91, 1977.
23. **Tönnis, D.:** Pelvic Operations for Dysplasia of the Hip. In *Congenital Dysplasia and Dislocation of the Hip in Children and Adults*, pp. 356-385. Edited, 356-385, Berlin, Springer-Verlag, 1984.
24. **Trousdale, R. T.; Cabanela, M. E.; Berry, D. J.; and Wenger, D. E.:** Magnetic resonance imaging pelvimetry before and after a periacetabular osteotomy. *J Bone Joint Surg Am,* 84-A(4): 552-6, 2002.
25. **Trousdale, R. T.; Ekkernkamp, A.; Ganz, R.; and Wallrichs, S. L.:** Periacetabular and intertrochanteric osteotomy for the treatment of osteoarthrosis in dysplastic hips. *J Bone Joint Surg Am,* 77(1): 73-85, 1995.
26. **Trumble, S. J.; Mayo, K. A.; and Mast, J. W.:** The periacetabular osteotomy. Minimum 2 year followup in more than 100 hips. *Clin Orthop,* (363): 54-63, 1999.
27. **Wagner, H.:** Osteotomies for congenital hip dislocation. In *The Hip Society 4th annual meeting*, pp. 45-66. Edited, 45-66, 1976.
28. **Wilberg, G.:** Studies on dysplastic acetabular and congenital subluxation of the hip joing. With special reference to the complication of osteoarthritis. Parts HV. *Acta Chir Scand Suppl,* 58: 7-38, 1939.

ULNOHUMERAL ARTHROPLASTY

Diane M. Allen, M.D., Jon P. Devries, M.D., James A. Nunley, M.D.

ABSTRACT

Seven patients underwent 9 ulnohumeral arthroplasties for degenerative arthritis of the elbow. At mean follow-up of 26 months, 5 elbows were pain free; two continued to cause mild pain and one to cause moderate pain. Extension improved from 22˚±8˚ preoperatively to 12˚±9˚ postoperatively (p=0.02); the average correction was 10˚±10˚. Flexion improved from 122˚±8˚ to 133˚±8˚ (p=0.02); the average correction was 11˚±11˚. One patient had a late supracondylar humerus fracture which healed well with open reduction and internal fixation. Overall, we believe that ulnohumeral arthroplasty is relatively safe and easy to perform. Our patients did have modest improvements in range of motion, but complete relief of pain occurred in only about two thirds of the patients.

INTRODUCTION

Although degenerative joint disease of the elbow is much less common than that of the knee and hip, it can be a significant source of pain and disability. The typical patient with primary elbow arthritis is a 40-50 year old male who has been involved in manual labor for many years. Presenting symptoms include limited range of motion and pain, especially at terminal flexion and extension. Catching and locking may also be present. Lateral radiographs show typical coronoid and olecranon spurs while AP views may show obliteration of the olecranon fossa with osteophytes (Figure 1).

Diane M. Allen, M.D.
Assistant Professor
Division of Orthopaedic Surgery
Box 3384
Duke University Medical Center
Durham NC 27710

Jon P. DeVries, M.D.
South Carolina Sports Medicine and Orthopaedic Center
9100 Medcom Street
North Charleston, SC 29406

James A. Nunley, M.D. (Corresponding Author)
Professor and Chief, Division of Orthopaedic Surgery
Box 2923
Duke University Medical Center
Durham NC 27710
Phone: (919) 684-4033
Fax: (919) 681-8377

Because of its rarity, Morrey believes primary elbow arthritis to be underdiagnosed and undertreated.[1] For many years, he has been treating these patients with "ulnohumeral arthroplasty," a slight modification of the Outerbidge-Kashiwagi procedure; in 2002, Antuna et al. reported the results of this treatment strategy.[2] Their 45 patients (46 elbows) had modest pain relief and improvement in motion and were in general satisfied with the procedure at an average follow-up of six and one half years. Thirteen patients did have ulnar nerve symptoms postoperatively, 6 of whom required a second operation to decompress or transpose the nerve. They concluded that ulnohumeral arthroplasty for primary osteoarthritis of the elbow gave satisfactory intermediate to long-term results. They recommended ulnar nerve mobilization for all patients with preoperative nerve symptoms.

On review of the English language literature, however, other authors have not had as successful results with similar procedures. Hertel and associates reported three poor results in six patients with degenerative elbow arthritis following transhumeral debridement.[3] Half of their patients had more pain following the procedure than before. They concluded that although range of motion was improved, work-related pain was not relieved. To resolve this issue for ourselves, we reviewed the senior author's (J.A.N.) experience of nine consecutive ulnohumeral arthroplasties in seven patients with degenerative arthritis of the elbow.

MATERIALS AND METHODS

The records of all patients who underwent ulnohumeral arthroplasty by one surgeon (J.A.N.) were identified. Indications for treatment included stiffness and pain, especially at the extremes of motion, coupled with radiographic findings of coronoid and olecranon spurs with or without loose bodies. We did include two patients who had had prior radial head fractures as these intraarticular fractures did not affect the ulnohumeral articulation directly.

All patients were determined to have failed conservative management prior to recommending surgery. Occupation, hand dominance, duration and nature of symptoms, prior operations and complications of treatment were collected by chart review. Level of pain and range of motion were recorded before and after surgery. Range of motion values before and after surgery were compared with a paired t-test.

Figure 1. A: AP elbow radiograph of a 40-year-old man showing partial obliteration of the olecranon fossa.

Figure 1. B: Lateral radiograph of the same patient showing coronoid and olecranon spurs.

The surgical technique used was that described by Morrey in 1992.[1] His operation differs from the Outerbridge-Kashiwagi procedure only in the elevation rather than split of the triceps during the approach, and the use of a trephine rather than a drill to remove osteophytes. Specifically, a straight posterior incision was made and the triceps were elevated from medial to lateral. Osteophytes on the olecranon tip were debrided. A tube saw of appropriate diameter to leave the medial and lateral columns intact was used to remove osteophytes from the olecranon fossa (Figure 2). The saw was directed slightly proximally to avoid damaging the trochlea. The elbow was then flexed and osteophytes were removed from the coronoid. Any loose bodies in the anterior joint were irrigated out. The elbow was then closed in the standard fashion in layers over a suction drain, which was left in place for 24 hours.

The patient was initially placed in a posterior splint. The dressings were removed 4-5 days postoperatively and the patients were referred to hand therapy for active range of motion exercises. Patients who were having trouble regaining extension at 3-4 weeks were prescribed dynamic splints.

RESULTS

Seven patients underwent nine ulnohumeral arthroplasties between January 1993 and January 1999. Six patients were male; one was female. The average age at the time of surgery was 45 (range 32-66). Most patients were manual laborers, although one was incarcerated and one was retired. All were right-handed; in unilateral cases, only one non-dominant extremity was involved. This patient had had a prior minimally displaced radial head fracture in the ipsilateral elbow. One patient had a contralateral above elbow amputation. All patients had disabling pain and stiffness. Most described clicking and locking of the elbow. Others complained of swelling and/or upper extremity weakness. All had tried various nonoperative management techniques such as medications and physical therapy to increase range of motion. Most patients had had symptoms for several years at the time of presentation. Two patients had had prior radial head excisions; one had had a presumed

Figure 2. A: Postoperative AP radiograph of the same patient following ulnohumeral arthroplasty.

Figure 2. B: Lateral view.

osteophyte debridement through medial and lateral incisions. One patient who had had a prior radial head resection was felt to have coexisting ulnar impaction syndrome and underwent simultaneous ulnar shortening osteotomy with ulnohumeral arthroplasty. Two patients were Workers' Compensation cases.

Five of nine elbows were pain free following the procedure. Two patients continued to have mild pain. One patient who was pain free at one-year follow-up developed significant pain, swelling and locking in the ensuing year. Radiographs showed recurrent osteophyte formation. One patient was lost to follow-up after her four-month visit.

Range of motion was improved in both flexion and extension (Table). Extension improved from 22˚ ± 8˚ to 12˚± 9˚ (p =0.02); the average correction was 10˚± 10˚. Flexion improved from 122˚ ± 8˚ to 133˚± 8˚ (p =0.02); the average correction was 11˚± 11˚. (All values are expressed as average ± standard deviation.)

There were no early postoperative complications. One patient suffered an extraarticular supracondylar humerus fracture 9 months following the index procedure while playing sports. This was treated with open reduction and internal fixation and healed uneventfully.

DISCUSSION

Our patient population was very similar clinically and demographically to that of other series. We were able to produce gains in range of motion that were similar to Morrey's and are likely clinically significant. We were not quite as successful in eradication of pain. The recurrence of pain in one of our patients was related to recurrence of radiographic disease within two years. One patient in Morrey's original series also developed recurrent osteophytes; his developed in the cubital tunnel and required ulnar nerve transposition one year after ulnohumeral arthroplasty.[1] In his more recent longer-term study, over half of the patients developed recurrent spurs and reossification of the olecranon fossa at a mean follow-up of 6 years. However, these findings were not associated with failure of the procedure or recurrent symptoms.[2] Minami and Ishii also noted gradual closure of the humeral fenestration with maintenance of range of motion in patients that were followed from 6 months to 11 years.[4] Other methods of debridement arthroplasty of the elbow have also been reported to have recurrence of osteophytosis. All eighteen pa-

TABLE
ELBOW RANGE OF MOTION

Patient	*Extension Pre/postoperative (degrees)*	*Flexion Pre/postoperative (degrees)*
51M	12/3	122/120
40M right	15/15	not known/130
left	30/5	120/130
66M right	30/12	130/145
left	15/22	120/145
41M	26/10	135/135
34M	30/25	115/130
32F	12/0	124/125
57M	30/20	108/135

tients in one series who had been followed for over five years after medial or lateral approach debridement arthroplasty developed recurrent radiographic changes although few of these had recurrent pain.[5]

Another possible treatment alternative with which we have no experience is arthroscopic transhumeral osteophyte debridement. Savoie et al. developed a fully arthroscopic ulnohumeral arthroplasty with which they frequently include radial head excision.[6] They reported remarkably good results with this technique in 24 patients with a variety of elbow arthritidies. All patients had relief of pain at a minimum follow-up of 2 years. They had large gains in range of motion, gaining 32˚ of extension and 49˚ of flexion on average. Not everyone has been so successful with arthroscopic techniques, however. Cohen et al. performed a two-institution study comparing the Outerbridge-Kashiwagi procedure to arthroscopic debridement and fenestration of the olecranon fossa as described by Redden and Stanley[7] for patients with primary and posttraumatic elbow arthritis with a minimum follow-up of one year.[8] Their arthroscopic group gained only average 3˚ extension and 4˚ flexion. We believe these changes to be 1) within the measurement error of the standard goniometers[9] and 2) if real, not clinically significant. The open group did slightly better averaging 15˚ improvement in flexion and 6˚ improvement in extension. The arthroscopic group did have slightly better relief of pain. Overall, 36 of 44 elbows were felt by the patients to be “better” or “much better” following the procedure.

In conclusion, primary elbow arthritis is a condition that occurs primarily in middle-aged, active males. It produces stiffness and pain at the extremes of motion and has a characteristic radiographic appearance. Patients with severe symptoms may be improved at least in the intermediate term with ulnohumeral arthroplasty. For those surgeons who are adept at elbow arthroscopy, the arthroscopic technique seems to be a reasonable alternative to open ulnohumeral arthroplasty.

REFERENCES

1. **Morrey BF:** Primary Degenerative Arthritis of the Elbow. *J Bone Joint Surg* 74-B:409-13, 1992
2. **Antuna SA, Morrey BF, Adams RA, O’Driscoll SW:** Ulnohumeral arthroplasty for primary degenerative arthritis of the elbow. *J Bone Joint Surg Am* 84:2168-2173, 2002
3. **Hertel R, Pisan M, Balmer F:** Operative management of the stiff elbow: Sequential arthrolysis based on a transhumeral approach. *J Shoulder Elbow Surg* 6:82-8, 1997
4. **Minami M, Ishii S:** Outerbridge-Kashiwagi arthroplasty for osteoarthritis of the elbow joint. The elbow joint. Proceedings of the International Congress. Kashiwagi D, (ed). Japan, Amsterdam, Elsevier, 1985; pp 180-196
5. **Oka Y, Ohta K, Saitoh I:** Debridement arthroplasty for osteoarthritis of the elbow. *Clinical Orthop* 351:127-134, 1998
6. **Savoie FH, Nunley PD, Field LD:** Arthroscopic management of the arthritic elbow: indications, technique and results. *J Shoulder Elbow Surg* 8:214-219, 1999
7. **Redden JF, Stanley D:** Arthroscopic fenestration of the olecranon fossa in the treatment of osteoarthritis of the elbow. *Arthroscopy* 9:14-16, 1993
8. **Cohen AP, Redden JF, Stanley D:** Treatment of osteoarthritis of the elbow: a comparison of open and arthroscopic debridement. *Arthroscopy* 16:701-6, 2000
9. **Armstrong AD, McDermid JC, Shrikant C,** et al: Reliability of range-of-motion measurement in the elbow and forearm. *J Shoulder Elbow Surg* 7:573-80, 1998

COMPLICATIONS OF TREATING DISTAL RADIUS FRACTURES WITH EXTERNAL FIXATION: A COMMUNITY EXPERIENCE

John T. Anderson, M.D.*, George L. Lucas, M.D.**, and Bruce R. Buhr, M.D.***

ABSTRACT

Objective: To analyze the immediate postoperative complications associated with treating distal radius fractures with external fixation.

Design: A retrospective chart review of data obtained from 24 consecutive patients who were treated with small AO external fixators in 1997.

Setting: Two community medical centers.

Intervention: Preoperative and postoperative radiograph measurements were taken of radial inclination, radial tilt, and radial length, and fractures were classified according to the AO system. Patient charts were reviewed to document demographics, type of fixator used, open or percutaneous technique for pin placement, use of augmentation, additional operations, and complications.

Main Outcome Measurements: Complications associated with treating distal radius fractures with one type of external fixator.

Results: Sixteen of the 24 patients had complications: 5 with neuropathies of the median or superficial radial nerve, 9 with pin track infections, 2 with pin loosening, one with a nonunion, 2 with malunion, and 4 patients each with radial shortening, loss of radial tilt, collapse of ulnar border or volar intercalated segment instability (VISI) of the lunate and rotatory subluxation of the scaphoid.

Conclusions: Postoperative complications following distal radius fractures treated with external fixation are common. Their effect, however, on long term functional results and patient satisfaction is negligible, with the exception of those patients with complications intrinsic to the fracture itself, i.e., nonunion, malunion or carpal malalignment.

The University of Kansas School of Medicine—Wichita
Department of Surgery, Section of Orthopaedics
Orthopaedic Residency Program
Via Christi Regional Medical Center—St. Francis Campus
Wichita, Kansas

* Resident in Orthopaedic Surgery
The University of Kansas School of Medicine—Wichita
Wichita, Kansas 67214-3882

** Professor & Chairman
Section of Orthopaedic Surgery
Department of Surgery
The University of Kansas School of Medicine—Wichita
Wichita, Kansas

*** Clinical Assistant Professor
The University of Kansas School of Medicine—Wichita
Wichita, Kansas 67214-3882

Editorial correspondence to
John T. Anderson, M.D.
Department of Orthopaedics
Via Christi Regional Medical Center
St. Francis Campus
929 N. St. Francis
Wichita, Kansas 67214-3882.
(316) 268-5988; FAX (316) 291-7799

INTRODUCTION

The distal radius fracture has been an orthopaedic conundrum since its description by Colles[4] in 1814. External fixator use for distal radial fracture stabilization, which began over a half century ago in the United States, has provided improved anatomical and clinical results in 80-90 percent of patients as shown by several studies.[1,7,8,14,16,24,25,30] The literature concerning early postoperative complications, however, gives variable information.[7-9,14,16,21,24,25,30,31] The overall complication rate has been reported as low as 9.6 percent[16] to as high as 61 percent.[31] Such complications include pin track infection, pin loosening and fracture, neuropathies involving the radial and median nerves, tendon rupture, metacarpal fractures, reflex sympathetic dystrophy and nonunion.

This study is meant to serve as an analysis of the postoperative complications associated with treating distal radius fractures with one type of external fixator in a community setting.

MATERIALS AND METHODS

The records of twenty-four consecutive patients, seven males and seventeen females, who were treated with small AO external fixators in 1997 were reviewed. Operations were performed by nine board certified orthopaedic surgeons in two community hospitals. Twenty-one fractures were classified by the AO system (Figure 1), indicating a variety of fracture types. There was one A2 fracture, two A3 fractures, two B3 fractures, one C1 fracture, seven C2 fractures and eight C3 fractures. Preoperative radiographs for three patients could not be located. Thirteen of the fractures involved only

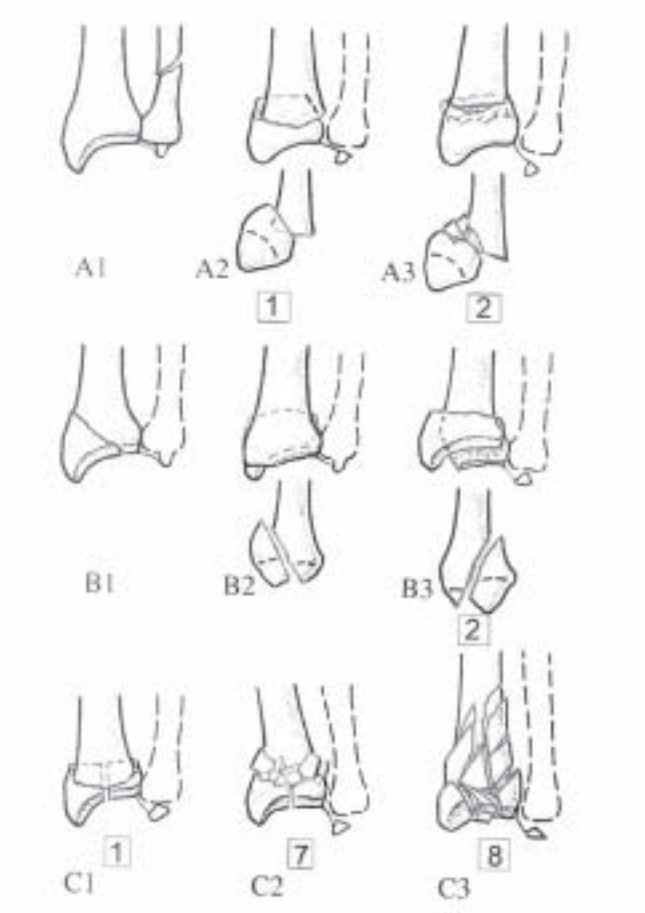

Figure 1. AO Classification of the Distal Radial Fractures. Permission granted for reproduction of illustration.

TABLE 1
PREOPERATIVE MEASUREMENTS

Fracture Classification	Radial Inclination*	Radial Tilt*	Radial Length
C2.2	20	15	12mm
C1.2	N/A	N/A	N/A
A2.2	30	25	7.5mm
N/A	N/A	N/A	N/A
A3.2	27.5	22.5	8mm
C2.2	10	-25	2mm
C3.2**	N/A	45	N/A
C2.1	0	45	0mm
C3.2	0	20	0mm
C2.2	20	0	8mm
N/A	N/A	N/A	N/A
A3.2	20	25	7mm
B3.3	15	-25	9mm
C3.2**	N/A	27.5	N/A
C3.3	15	0	8mm
C2.2	12.5	25	7mm
C3.3	15	-5	4mm
B3.3	15	-12.5	4.5mm
C3.2	57.5	-20	13mm
C2.2	22.5	-15	7mm
C3.3	15	37.5	5mm
C3.1	7.5	5	4mm
C2.1	17.5	30	7mm
N/A	N/A	N/A	N/A

***In degrees**
****Radial inclination and length could not be measured due to extreme comminution**

the distal radius; nine of the fractures also involved the distal ulna (five of the ulnar styloid); two fractures were associated with a disruption of the distal radio-ulnar joint; and three of the fractures were open. Radial inclination, radial tilt and radial length were measured from the preoperative radiographs in all but four patients (Table 1). Postoperative measurements of the same parameters were also obtained (Table 2). For two patients, the preoperative measurement of radial inclination and radial length was not possible due to extreme comminution in the posteroanterior view.

The patients' charts were reviewed to document: 1) the type of fixator used; 2) if an open technique was used for pin placement; 3) if augmentation was used; 4) patient demographics; 5) additional operations; and 6) complications. The period of follow-up lasted until the patients were discharged from care. Follow-up phone calls were made to four patients. One of these patients relocated shortly after the application of her external fixator; the other three were contacted to clarify the status of neuropathy symptoms.

As stated above, all fractures were reduced and stabilized with a small AO external fixator. An open technique for pin placement was documented in twenty-three of the twenty-four cases. In one case, it was not mentioned in the operative report if incisions were made for metacarpal pin placement, but "stab" incisions were made for radial pin placement. This patient did not experience any complications. Some form of augmentation was utilized in fourteen of the twenty-four cases (58.3%); Kirschner wires in fourteen patients, allograft bone in three patients and a volar buttress plate in one patient. In two patients, Kirschner wires and bone graft were used simultaneously; in the latter patient, Kirschner wires, bone graft and a volar buttress plate were used simultaneously.

TABLE 2
POSTOPERATIVE REDUCTION

Fracture Classification	Radial Inclination*	Radial Tilt*	Radial Length
C2.2	20	-7.5	8mm
C1.2	12.5	-10	6.5mm
A2.2	20	0	6mm
N/A	12.5	0	5mm
A3.2	15	10	6mm
C2.2	25	-7.5	11mm
C3.2	25	0	8mm
C2.1	17.5	-7.5	7mm
C3.2	10	-10	8mm
C2.2	17.5	15	9mm
N/A	17.5	-5	12mm
A3.2	25	-15	6mm
B3.3	15	-7.5	7mm
C3.2	17.5	0	10mm
C3.3	20	-7.5	8mm
C2.2	20	-15	8mm
C3.3	20	0	12mm
B3.3	17.5	-10	7mm
C3.2	25	-17.5	9mm
C2.2	22.5	-20	9mm
C3.3	12.5	-10	4mm
C3.1	25	-7.5	12mm
C2.1	25	-7.5	13mm
N/A	10	7.5	8mm

***In degrees**

Patient ages ranged from 21 to 91 years, the mean being 53.8 years. Seventeen patients were women (70.8%) and seven were men (29.2%). The injury to surgery time ranged from zero to twelve days (mean three days). The duration of external fixation ranged from 4.1 to 14.4 weeks (mean eight weeks). The duration of follow up ranged from two months to fourteen months (mean 6.5 months).

Nineteen (79.2%) fractures were the result of a fall. Two of the falls were from a substantial height: one from approximately 50 feet and the other from a horse. Three (12.5%) of the fractures were the result of a motor vehicle accident, one patient (4.2%) was struck by a car, and another patient (4.2%) suffered a fracture in an ultra-light plane crash (Table 3).

Three patients (12.5%) required an additional operation; one of them required two. The operations included: 1) carpal tunnel release and manipulation under anesthesia; 2) hemiresection arthroplasty of the distal radio-ulnar joint; 3) scapho-lunate reconstruction with capsulodesis; and 4) scapho-lunate-capitate fusion. Procedures three and four were performed on the same patient.

TABLE 3
MECHANISM OF INJURY

Mechanism	Number of Patients	Percent
Fall*	19	79.2
MVA**	3	12.5
Automobile/Pedestrian Accident	1	4.2
Ultra-light Plane Crash	1	4.2

***One patient fell approximately 50 feet; another from a horse.**
****One patient was ejected from the automobile.**

TABLE 4
COMPARISON OF PREOPERATIVE VS POSTOPERATIVE MEASUREMENTS*

	Radial Inclination**	Radial Tilt**	Radial Length
Preoperative	17.7	11	6.3mm
Postoperative	18.6	-5.5	8.3mm

*** Mean values**
****In degrees**

RESULTS

Of the twenty-four patients, sixteen (66.7 %) had some complication. The following complications were documented: 1) neuropathy of the superficial radial and median nerve; 2) pin track infection; 3) pin loosening; 4) nonunion; 5) malunion; 6) radial shortening; 7) loss of radial tilt; 8) collapse of ulnar border; 9) volar intercalated segment instability (VISI) of the lunate; and 10) rotatory subluxation of scaphoid (Figure 2). The latter two complications can not be ascribed to the fixator but are listed for completeness. Five (21%) of the patients experienced neuropathies: three involving the median nerve and two involving the superficial branch of the radial nerve. One patient with median nerve symptoms had complete resolution following carpal tunnel release. Of the other two patients with median nerve symptoms, one still has symptoms, and the other could not be contacted. Of the two patients with neuropathies involving the superficial branch of the radial nerve, one patient's symptoms were transient, and the other still has symptoms. Whether the median nerve neuropathies were the result of trauma or the fixator is impossible to determine. The most common complication documented was

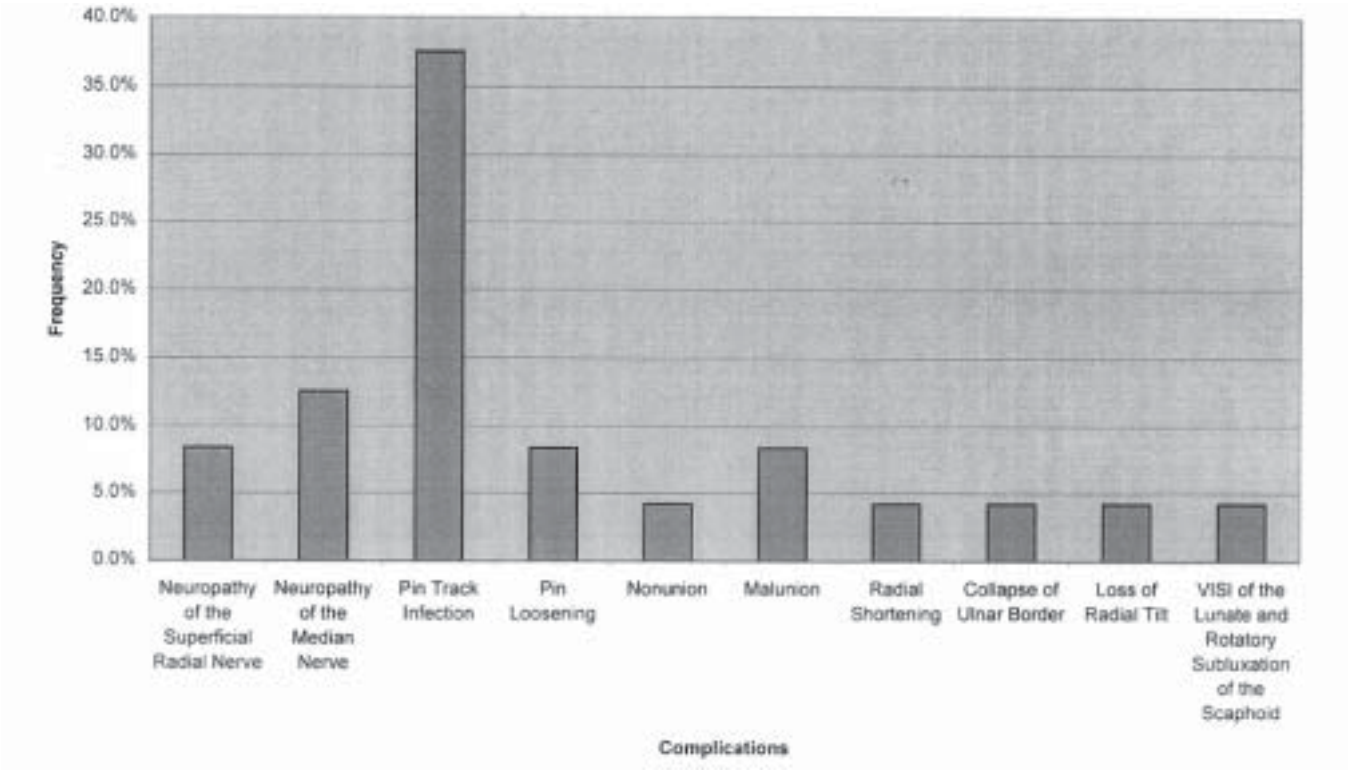

Figure 2. Complications and Frequencies

pin track infection, occurring in nine patients (37.5%). All, however, resolved quickly with local and oral antibiotic treatment. Pin loosening occurred with two patients (8.3%). A nonunion occurred in one patient (4.2%). Malunion occurred in two patients (8.3%). The following occurred in one case each: 1) radial shortening; 2) loss of radial tilt; 3) collapse of ulnar border; and 4) VISI of the lunate with concomitant rotatory subluxation of the scaphoid. Four patients (16.7%) had two of the aforementioned complications. One patient (4.2%) had three complications (median nerve neuropathy, malunion, and radial shortening). One patient (4.2%) had four complications (pin track infection, pin loosening, loss of radial tilt, and nonunion). Reflex sympathetic dystrophy was not documented in any of the twenty-four patients.

Preoperative radial inclination ranged from zero to 57.5 degrees, with a mean value of 17.7 degrees. Preoperative radial tilt ranged from 25 degrees of palmar angulation to 45 degrees of dorsal angulation, with a mean of 11.0 degrees of dorsal angulation. The preoperative radial length ranged from zero to 13 mm, with a mean of 6.3 mm.

Postoperative radial inclination ranged from 10 to 25 degrees, with a mean of 18.6 degrees. Postoperative radial tilt ranged from 20 degrees of palmar angulation to 15 degrees of dorsal angulation; the mean was 5.5 degrees of palmar angulation. Postoperative radial length ranged from 4 to 13 mm, the mean being 8.31 mm (Table 4).

DISCUSSION

This is a retrospective analysis of the complications encountered while treating twenty-four patients with distal radius fractures utilizing a small AO external fixator. The complication rate was high at 66.7 percent, but similar to the results obtained by Szabo and Weber.[31] Sixty one percent of their thirteen patients treated with external fixation experienced complications. As in our study, pin track infection was the most common complication (23%). Unlike other series,[7,8,14,16,21,24,25,30,31] but similar to ours, they reported one case that resulted in nonunion.

Pin track infections occurred in nine of our twenty-four patients (37.5%). These all resolved with antibiotics. This rate was higher than in other studies, which had a range of 0-27 percent.[7,8,14,16,21,24,25,30,31] As in our series, peroxide pin site cleansing was utilized at other centers as well. Interestingly, Raskin and Melone[24] reported no pin track infections in their study. They attribute this to their method of pin site care. Instead of exposing the pin sites daily, they covered the external fixator frame with sterile gauze at the skin contact interface, which obviated the need for daily pin site care.

Rather, the pins were exposed only during scheduled dressing changes at the surgeon's office, approximately four times during an eight-week period.

Other authors have made recommendations that they felt would reduce the incidence of pin track infection. Graff and Jupiter[11] recommend obtaining an adequate reduction prior to placing the pins; this is done to reduce the risk of skin necrosis and subsequent pin track infection. Other authors have advocated measures that reduce the amount of time the external fixator is worn, and thus, reduce the incidence of pin track infections. Putman and Fischer[23] recommend a combination of intraoperative external distraction, ORIF, and postoperative external fixation for four weeks. Leung et al.[19] recommend packing autogenous bone graft into the fracture site during the application of the external fixator. With this technique, the external fixator is worn for only three weeks, after which time a functional brace is used.

Five of our twenty-four patients experienced neuropathies of either the median nerve (three cases) or superficial branch of the radial nerve (two cases). Again, it is difficult to ascertain if the neuropathies involving the median nerve were the result of the initial injury or the effect of external fixation. Gelberman et al.[10] demonstrated that over distraction can cause increased pressures in the carpal tunnel, and to avoid this, Hertel and Ballmer[12] recommend obtaining preliminary reduction with over distraction, then stabilizing the fracture with crossed Kirschner wires, followed by reduction of distraction to neutral length and position.

It seems reasonable to assume that the incidence of superficial radial nerve irritation is largely dependent on the surgeon's technique of pin placement. By using an open technique, the superficial branch of the radial nerve can be protected. In twenty-three of our twenty-four patients, an open technique was used. It is unclear from the record whether the other patient had open or closed pin placement, but regardless, this patient did not experience symptoms of superficial radial nerve irritation. Other studies have also reported neuropathies in the distribution of the superficial radial nerve, despite using an open technique.[7,14,25] In most cases, however, the neuropathy was transient. Of the studies (including ours) that utilized an open technique for pin placement, the incidence of superficial radial nerve irritation ranged from 0 percent to 16.7 percent.[7,8,14,16,24,25]

Pin loosening can certainly be problematic. Other studies have reported this complication in zero to 20 percent of their patients.[6,7,8,14,16,21,24-26,30,31] Two studies where the small AO external fixator was utilized reported no occurrences of pin loosening.[8,14] In our study, pin loosening occurred in two cases (8.3%), but premature removal of the external fixator was not required in either case. To avoid pin loosening, some investigators have discouraged external fixation for patients exceeding a certain age.[3,5,15,17,18] Jenkins et al.[17] believed this age limit to be sixty years, while Howard et al.[15] set their limit at seventy-five years of age. Other studies do not seem to support the exclusion of patients on the basis of age, however. For example, in a study of thirty patients, aged 31 to 81 (mean=56), Edwards et al.[8] reported no cases of pin loosening, despite ten (33.3%) of their patients being considered osteoporotic. Additionally, Rikli et al.[25] experienced no occurrences of pin loosening in their study of forty-nine patients, ages eighteen to eighty-four (mean=55.6). In the study conducted by Szabo and Weber,[31] two of their thirteen patients (15.4%) experienced pin loosening as a complication, but the mean age of their patient population was only 36.9 years. In our study, the two patients with pin loosening as a complication were a male and female, aged forty and sixty-four, respectively.

The incidence of malunion and nonunion was surprisingly high (12.5%) in our study. A case of nonunion occurred in Szabo and Weber's[31] patient group but was not reported in other studies.[7,8,14,16,21, 24,25,30,31,] Hertel and Jakob,[13] however, commented in their article that nonunion is an occasional occurrence in fractures extending proximally, to the metaphysis or diaphysis. This was indeed the situation in our patient with nonunion, a sixty-four-year-old female with poor bone quality, who had an AO class C3.3 fracture. Hertel and Jakob[21] recommend combined internal (e.g., palmar buttress plate) and external fixation in these cases. Considering our patient's poor bone quality, it is difficult to determine if combined internal fixation/external fixation would have prevented the nonunion. The patient opted not to undergo additional surgery to correct the nonunion and reports being satisfied with the outcome of this decision.

One of our two cases of malunion occurred in a patient who had fallen from a height of approximately 50 feet, resulting in a Grade I open fracture of the ulna. Her radius fracture was intraarticular and severely comminuted. Her course was complicated by a recurring, draining wound abscess involving the volar-ulnar aspect of the involved wrist. The patient's postoperative course was also complicated by the fact that she was a noncompliant schizophrenic.

The other case of malunion occurred in a forty-five-year-old female who fractured her wrist from a simple fall. Follow up radiographs obtained five months postoperatively revealed a deformity of the distal radio-ulnar joint. To improve her marked limitation of supination and pronation, hemiresection arthroplasty of the distal radio-ulnar joint was performed, which improved supination and pronation postoperatively.

TABLE 5
COMMUNITY ANALYSIS OF POSTOPERATIVE REDUCTION

	Radial Inclination**	Radial Tilt**	Radial Length
Wichita*	18.6	-5.5	8.3mm
Szabo and Weber*	17.1	-2	11.7mm
Dienst et al.*	21	0	9mm

***The mean value obtained in each study**
****In degrees**

The patient who developed a VISI configuration of the carpus required two additional operations: scapho-lunate reconstruction with capsulodesis and subsequent scapho-lunate-capitate fusion. This patient was a thirty-year-old pregnant female who sustained an AO class C3.2 fracture during a fall. The VISI deformity was noted approximately three and a half months after her initial surgery. Initial roentgenograms showed no carpal abnormality in the immediate perioperative period. When scapho-lunate disassociation is present preoperatively, it should be kept in mind that distraction may aggravate displacement of the scapho-lunate joint.[29] In these situations, the authors of one article recommend using the external fixator in a strictly neutral position, to facilitate healing of the disrupted ligaments.[22]

Other complications include: 1) radial shortening (one case); 2) collapse of ulnar border (one case); and 3) loss of radial tilt (one case). In the cases involving radial shortening and ulnar border collapse, the defect was noted prior to removal of the external fixator. In both cases, no augmentation was used. Perhaps these complications may have been avoided by employing the use of Kirschner wires, bone graft or some form of internal fixation such as suggested by Pennig and Gausepohl,[22] who commented that supplementary internal fixation is justified whenever there is significant comminution of two or more cortices in the anteroposterior and lateral radiographs. Seitz[27] recommends supportive bone grafting when shortening exceeds 5mm, and according to Leung et al.,[19] the use of bone grafting prevents late collapse of the fracture site.

In regard to restoring radial tilt or volar tilt, some authors[16,31] have found this to be a difficult task. In a study conducted by Bartosh and Saldana,[2] Frykman Class VII fractures were created in nineteen fresh cadaver wrists, and then reduction was attempted by means of external fixation. Initially, the dorsal and palmar ligaments were left intact. The authors found that they were unable to restore radial tilt unless the entire palmar ligamentous structures were transected at the radiocarpal joint.

Preoperative and postoperative measurements of radial inclination, radial tilt and radial length for our twenty-four cases can be viewed in Tables 1 and 2, respectively. These measurements would be more helpful in a prospective study analyzing the correlation between the quality of reduction and long term functional results. Our results are compared to those obtained in two other studies[7,31] as shown in Table 5.

Complications documented in other studies but not encountered in ours include: deep pin track infection;[7,25] fractured pins;[21,30] tendon rupture;[21,25] and intrinsic contracture of the hand.[21]

CONCLUSION

External fixation is a popular and effective treatment for distal radius fractures in our community. Postoperative complications are common, but in most instances, their effect on short term functional results and patient satisfaction is negligible, except in the patient with complications such as nonunion, malunion and deformities of the carpus. It appears that, as a community, our ability to reduce distal radius fractures is comparable to others.

The limitations of this study are obvious. Relying on chart review for data collection is always suboptimal in comparison to direct patient assessment. We do believe that we have identified the level of complications to be expected with external fixation use for distal radius fractures by “average” orthopaedists in an “average” community.

ACKNOWLEDGMENTS

The authors thank Judy K. Dusek, R.N., M.Ed. for manuscript editing.

REFERENCES

1. **Anderson R, O’Neil G:** Comminuted fractures of the distal end of the radius. *Surg Gynecol Obstet,* 1944;78:434-440.
2. **Bartosh RA, Saldana MJ:** Intraarticular fractures of the distal radius: a cadaveric study to determine if ligamentotaxis restores radiopalmar tilt. *J Hand Surg,* 1990;15(Am):18-21.
3. **Clyburn TA:** Dynamic external fixation for comminuted intra-articular fractures of the distal end of the radius. *J Bone Joint Surg,* 1987;69(Am):248-254.
4. **Colles A:** On the fracture of the carpal extremity of the radius. *Edinb Med Surg J,* 1814;10:181.
5. **Cooney WP:** Management of Colles’ fractures (editorial). *J Hand Surg,* 1989;14(Br):137-139.
6. **Cooney WP, Linscheid RL, Dobyns JH:** External pin fixation for unstable Colles’ fractures. *J Bone Joint Surg,* 1979;61(Am):840-845.

7. **Dienst M, Wozasek GE, Seligson D:** Dynamic external fixation for distal radius fractures. *Clin Orthop,* 1997;338:160-171.
8. **Edwards GE:** Intraarticular fractures of the distal part of the radius treated with the small AO external fixator. *J Bone Joint Surg,* 1991;73(Am):1241-1250.
9. **Gainor BJ, Groh GI:** Early clinical experience with Orthofix external fixation of complex distal radius fractures. *Orthopedics,* 1990;13:329-333.
10. **Gelberman RH, Szabo RM, Mortensen WW:** Carpal tunnel pressures and wrist position in patients with Colles' fractures. *J Trauma,* 1984;24:747-749.
11. **Graff S, Jupiter J:** Fracture of the distal radius: Classification of treatment and indications for external fixation. *Injury,* 1994; 25 Suppl, 4:S-D14-25.
12. **Hertel R, Ballmer F:** Complications of external fixation of the wrist. *Injury,* 1994;25 Suppl 4:S-D39-43.
13. **Hertel R, Jakob RP:** Static external fixation of the wrist. *Hand Clinics,* 1993;9:567-575.
14. **Horesh Z, Volpin G, Hoerer D,** et al: The surgical treatment of severe comminuted intraarticular fractures of the distal radius with small AO external fixation device: A prospective three-and-one-half-year follow-up study. *Clin Orthop,* 1991;263:147-153.
15. **Howard PW, Stewart HD, Hind RE, Burke, FD:** External fixation or plaster for severely displaced comminuted Colles' fractures? A prospective study of anatomical and functional results. *J Bone Joint Surg,* 1989;71(Br):68-73.
16. **Jakim I, Pieterse HS, Sweet MBE:** External fixation for intraarticular fractures of the distal radius. *J Bone Joint Surg,* 1991;73(Br):302-306.
17. **Jenkins NH, Jones DG, Johnson SR, Mintowt-Czyz WJ:** External fixation of Colles' fractures. An anatomical study. *J Bone Joint Surg,* 1987;69(Br):207-211.
18. **Jakob RP, Fernandez DL:** The treatment of wrist fractures with the small AO external fixation device. In *Current Concepts of External Fixation of Fractures,* 307-314. Edited by H.K. Uhthoff and Elvira Stahl. New York, Springer, 1982.
19. **Leung KS, Shen WY, Tsang HK,** et al: An effective treatment of comminuted fractures of the distal radius. *J Hand Surg,* 1990;15(Am):11-17.
20. **Lucas GL, Sachtjen KM:** Thomas Jefferson, therapeutic nihilism and Colles' fracture. *Orthop Rev,* 1977;6:83-86.
21. **Nakata RY, Chand Y, Matiko JD, et al:** External fixators for wrist fractures: A biomechanical and clinical study. *J Hand Surg,* 1985;10(Am):845-851.
22. **Pennig D, Gausepohl T:** External fixation of the wrist. *Injury,* 1996;27:1-15.
23. **Putman MD, Fischer MD:** Treatment of unstable distal radius fractures: methods and comparison of external distraction and ORIF versus external distraction-ORIF neutralization. *J Hand Surg,* 1997; 22(Am):238-251.
24. **Raskin KG, Melone CP:** Unstable articular fractures of the distal radius: Comparative techniques of ligamentotaxis. *Orth Clin North Am,* 1993;24:275-286.
25. **Rikli DA, Kupfer K, Bodoky A:** Long-term results of the external fixation of distal radius fractures. *J Trauma,* 1998;44:970-976.
26. **Schuind F, Donkerwolcke M, Rasquin C, Burny F:** External fixation of fractures of the distal radius: A study of 225 cases. *J Hand Surg,* 1989;14(Am):404-407.
27. **Seitz WH Jr:** External fixation of distal radius fractures. Indications and technical principles. *Orthop Clinic North Am,* 1993;24:255-264.
28. **Seitz WH Jr, Froimson AI, Leb R,** et al: Augmented external fixation of unstable distal radius fractures. *J Hand Surg:* 1991;16(Am):1010.
29. **Tiel van Buul MMC, van Beck EJR, Broekhuizen AH,** et al: Diagnosing scaphoid fractures. *Injury,* 1992;23:77.
30. **Vaughan PA, Lui SM, Harrington IJ,** et al: Treatment of unstable fractures of the distal radius by external fixation. *J Bone Joint Surg,* 1985;67(Br):385-389.
31. **Weber SC, Szabo RM:** Severely comminuted distal radial fracture as an unsolved problem: Complications associated with external fixation and pins and plaster techniques. *J Hand Surg,* 1986;11(Am):157-165.

LEG LENGTH DISCREPANCY IN UNILATERAL CONGENITAL CLUBFOOT FOLLOWING SURGICAL TREATMENT

Kenneth J. Noonan, M.D.*, Alex M. Meyers*, Kosmas Kayes, M.D.*

ABSTRACT

Length discrepancy secondary to limb hypoplasia has been described as an associated finding in patients with unilateral clubfoot. In this manuscript we bring attention to limb length discrepancy as a result of surgical treatment in unilateral clubfoot. Three patients who underwent extensive posterior, medial and lateral release were noted to have an average discrepancy in foot height of 2.1 centimeters (range, 2.0-2.3 centimeters). A decrease in foot height in addition to baseline limb hypoplasia may lead to a significant discrepancy that may justify surgical treatment. In this manuscript we point out that length discrepancy in such cases may not be adequately quantified on standard anteroposterior scanograms. Standing lateral foot radiographs will document loss in foot height as a possible factor in length discrepancy in surgically treated clubfoot patients.

INTRODUCTION

The initial management of clubfoot has not changed a great deal since the time of Hippocrates (460-377 BC).[10] It is generally accepted that preliminary management of clubfoot should be non-operative; in North America, the preferred approach utilizes variably described serial manipulations followed by short- or long-leg casting.[3,4,6,18,20,21] Should the deformity prove resistant to non-operative treatment, operative intervention may be considered to correct residual deformity. Despite differences in surgical incision and approach, most authors recommend release or lengthening of ligaments and tendons, which variably constitute posterior, medial and/or lateral release.[1,2,5,7,8,14,16,19,24]

Immediate complications of extensive surgical release include infection, skin slough and breakdown, or neurovascular compromise. Intermediate term complications include recurrence of deformity and need for adjunctive treatment. Longer-term outcomes may include over-correction, under-correction, stiffness and pain. An associated finding in unilateral congenital clubfoot includes limb length discrepancy,[12] which may be attributed to limb hypoplasia with tibial and/or femoral shortening.[9,15,26] Limb length discrepancy may also be secondary to a decrease in foot height, which rarely exceeds one centimeter.[11,15,26]

It is the purpose of this series to bring attention to an excessive loss in foot height as a complication following surgical release in unilateral clubfoot. We report three patients who underwent extensive surgical release for the treatment of resistant idiopathic clubfoot and whose limb length deformity was inadequately quantified with standard scanograms.

CASE REPORTS

Case 1: H.B. was born with unilateral clubfoot involving her left lower extremity. She was treated with manipulation and casting for the first four months of her life when the left foot continued to show marked heel varus, rigid metatarsus adductus and dorsiflexion to five degrees. Radiographs documented talocalcaneal angles of ten degrees on anteroposterior and five degrees on lateral radiographs. Casting with manipulation was discontinued and surgical correction was elected.

At 11 months of age, H.B. underwent surgical reconstruction, which has been previously described.[7] Through a Turco-style medial skin incision, the Achilles tendon was z-lengthened and the fibro-fatty pulvinar between the Achilles and the tibiotalar and subtalar joints was resected. Complete subtalar release including the interosseus ligament was performed. Abductor hallucis muscle and plantar fascia were released. The posteromedial release was continued with z-lengthening of the posterior tibialis, flexor digitorum longus and flexor hallucis longus. The master knot of Henry was excised as well. Release of the talonavicular and calcaneocuboid joints and sectioning of the spring ligament were performed with the Navicular pinned in a reduced

*Department of Orthopaedic Surgery
Indiana University School of Medicine
702 Barnhill Dr., Rm. 1134
Indianapolis, IN 46202-5215
Tel: (317) 278-0961
Fax: (317) 274-7197

Address reprint requests and correspondence to:
Dr. Kenneth J. Noonan
Email: Knoonan@uipui.edu
No outside funds or donations were accrued in the publication of this manuscript.

Figure 1. Photo of H.B. in prone position at 12 years of age demonstrating a significant discrepancy with an overcorrected foot in comparison to the other.

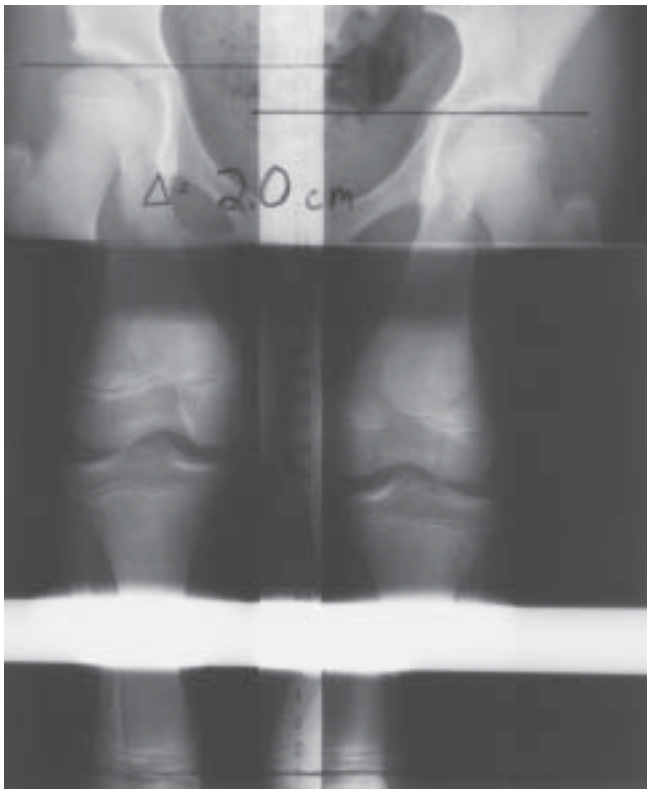

Figure 2. Anteroposterior scanograms of H.B. at 12 years of age demonstrating a 2.0-centimeter discrepancy in the left versus the right tibia.

position. A pin was also passed through the talus and calcaneus following correction of hindfoot varus and equines. Anterior tibialis transfer to the midfoot was also performed prior to closure and placement in a long-leg cast for six weeks. After cast removal, straight last shoes and night splints were used for eight months post-operatively.

Figure 3. Left and right lateral leg and foot scanograms of H.B. at 12 years of age demonstrating a total discrepancy of 4 centimeters.

At two-and-a-half years of age, H.B. began to show evidence of over-correction into valgus with left calf atrophy. At four years of age, H.B. was ambulating well with a clinical leg-length discrepancy (left shorter) of one-and-one-half centimeters as measured from the anterior superior iliac spine to the medial malleolus. Her clinical discrepancy progressed and at 12 years of age she had a noticeable limp with asymmetric standing knee heights and a negative Galeazzi sign. In the prone position her left tibia and foot appeared to be four centimeters shorter than the right (Figure 1). Standard anteroposterior scanograms of the lower extremities at that time showed a discrepancy of 2.0 centimeters in the left tibia in comparison to the right (Figure 2). Due to the discordance between clinical and radiographic measurements, it was speculated that the additional loss of length was coming from the discrepancy in foot height. This was inadequately quantified on the scanograms and was confirmed on standing lateral foot films and a lateral leg-foot scanograms (Figure 3). The later radiographs identified a 2.0-centimeter loss in foot height in addition to the previously noted tibial discrepancy of 2.0 centimeters. In order to recoup the total discrepancy, distal femoral and proximal tibial epiphysiodesis were performed at 12 years, 3 months of age. She did well following the procedure and at one-year follow-up she has limb length discrepancy of 2.5 centimeters in the left leg and foot with one year of growth remaining.

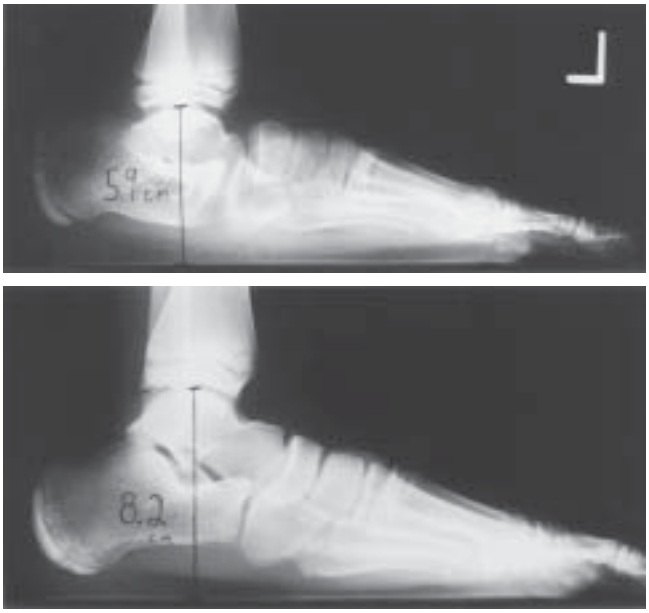

Figures 4 and 5. Left and right standing lateral foot radiographs of M.C. at 11 years of age demonstrating a 2.3-centimeter discrepancy in foot height.

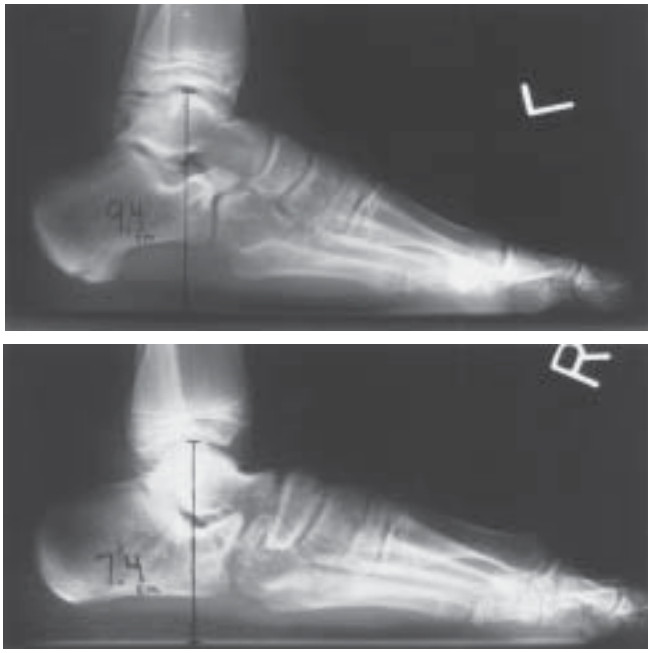

Figures 6 and 7. Left and right standing lateral foot radiographs of J.G. at 13 years of age demonstrating a 2.9-centimeter discrepancy in foot height.

Case 2: M.C. was born with unilateral clubfoot involving his left lower extremity. He was treated with serial manipulation and casting for the first three months of his life followed by corrective shoes. Initial evaluation at our hospital was at 17 months of age. Physical examination of the left foot at that time continued to show residual equines and varus, and surgical intervention was elected upon. Surgical correction consisted of posterior, medial and lateral release with dorsal transfer of tibialis anterior as described above. After surgery, a long-leg cast was placed and was continued for eight weeks post-operatively. Following cast removal, he wore night splints and straight last shoes.

At two years and nine months postoperative follow-up, M.C. showed left calf atrophy and slight heel valgus. Radiographs demonstrated that the talus was also medially and inferiorly subluxed. Physical examination at 11 years old showed the left foot was two sizes too small and a clinical limb length discrepancy of 2.5 centimeters (left lower extremity shorter than right). Anteroposterior scanograms at 13 years of age revealed a tibial discrepancy of 0.5 centimeters. A loss in foot height of 2.3 centimeters was noted when comparing standing lateral radiographs of the left foot to the right (Figures 4 and 5). Although he complains of occasional foot pain, a custom shoe insert accommodates his collapsed arch and limb-length discrepancy. The family is considering the option of contralateral epiphysiodesis at a later age in order to recoup his deficit.

Case 3: J.G. was born with right unilateral clubfoot and was treated with serial manipulation and casting started at one day of age. At 11 months of age the right foot continued to show rigid metatarsus adductus, varus and equines deformity and surgical correction was elected.

J.G. underwent posterior, medial and lateral release as described above without dorsal transfer of the anterior tibialis tendon. He was placed in a long-leg cast for six weeks following the procedure, after which he wore night splints and straight last shoes for one year. At three years of age, J.G. was able to perform all activities despite calf atrophy that was noted on physical examination. At thirteen years, J.G. began to develop pain about the right foot and ankle. Physical examination revealed the right foot to be in excessive valgus with attendant weakness of the gastrocnemius-soleus muscles as well as hyperextension of the right hallux during swing phase. Standing lateral radiographs taken at that time revealed talar flattening and a decrease in foot height of 2.0 centimeters in comparison to the contralateral foot (Figures 6 and 7).

DISCUSSION

Wynne-Davis, in 1964, reported a study of 47 individuals with unilateral clubfoot, with less than half having a leg-length discrepancy. One-third had some loss in foot height, which was not quantified. One-half of the affected males had a leg-length discrepancy while all of

the females had a leg-length discrepancy. This finding was attributed to the earlier closure of the epiphyses in females. Little et al. reported an incidence of limb length discrepancy in unilateral clubfoot of 18 percent with an average discrepancy of 2.1 centimeters.[15] In this review, tibial shortening made up the majority of the loss in height. Yet due to the high incidence of femoral length discrepancy, they hypothesize that global limb hypoplasia is the cause of significant limb length discrepancy. Of the 259 patients with unilateral clubfoot, the authors do not objectively measure the amount of loss in foot height, but maintain an average loss of ten millimeters in nine percent of unilateral clubfeet. Unfortunately, the authors do not describe the treatments utilized in these patients, yet they suggest increased limb length discrepancy in patients with multiply operated feet.

Some mild decrease in foot height should be expected in unilateral clubfoot, yet we are unaware of any cases of significant discrepancy as a result of loss in foot height in patients who are treated with manipulation and casting alone. Untoward outcomes of surgical correction of clubfeet include: Wound infection, skin necrosis, severe scarring, stiff joints, ankle and subtalar joint pain, over-correction and heel valgus, under-correction, dislocation of the navicular, fracture and flattening of the talus or necrosis, weakness of the plantar flexors and calf atrophy, and decrease in foot size.[2,9,14,17,19,22,25,26] Significant discrepancy as a result of loss in foot height is heretofore an apparent result of extensive surgical release. Huang et al. also found that loss in foot height is a potential complication in the treatment of clubfoot.[11]

Mild decrease (<one centimeter) in foot height in clubfeet may be due to hypoplasia of the calcaneus and talus.[13,26] In our series, the loss in height on standing lateral radiographs is approximately 2 to 2.3 centimeters. The discrepancy is apparently due to a combination of midfoot collapse, excessive hindfoot valgus and possible growth retardation of the talus and os calcis. Others have also speculated that apparent calcaneal shortening in radiographs of children with clubfoot may be due to true shortening of the calcaneus or secondary to rotation of the calcaneus in the coronal plane.[23] We theorize that extensive surgical release may predispose to late collapse at Chopart's joints as well as a tendency to drift into extreme valgus. Although difficult to prove, it also seems reasonable that wide peri-talar release may predispose to growth retardation of the talus as a result of vascular insult at the time of release.

An important point in this report is the observation that clinical limb-length discrepancy may not be adequately quantified on standard anteroposterior studies such as a scanograms. In patients with unilateral clubfoot it is critical to realize that fairly significant discrepancy may be due to a loss in foot height after extensive surgical release. The total discrepancy may become significant in prepubescent patients with a combination of limb hypoplasia and postoperative loss in foot height (Case 1). Measuring the difference in distance from the talar dome to the floor on standing lateral foot films easily assesses the discrepancy and may be added to any concurrent shortening of the leg.

BIBLIOGRAPHY

1. **Altar D, Lehman WB, Grant AD.** Complications in clubfoot surgery. *Orthop Rev* 1991;20:233-9.
2. **Aronson J, Puskarich CL.** Deformity and disability from treated clubfoot. *J Pediatr Orthop* 1990;10:109-19.
3. **Carroll NC.** Congenital clubfoot: pathoanatomy and treatment. *In Instructional Course Lectures, The American Academy of Orthopaedic Surgeons*. 1987;39:117-21.
4. **Cowell HR.** The management of club foot [editorial]. *J Bone Joint Surg* [Am] 1985;67:991-2.
5. **Crawford AH, Marxen JL, Osterfeld DL.** The Cincinnati incision: a comprehensive approach for surgical procedures of the foot and ankle in childhood. *J Bone Joint Surg* [Am] 1982;64:1355-8.
6. **Cummings RJ, Lovell WW.** Current concepts review. Operative treatment of congenital idiopathic clubfoot. *J Bone Joint Surg* [Am] 1988;70:1108-12.
7. **DeRosa PG, Stepro D.** Results of posteromedial release for the resistant clubfoot. *J Pediatr Ortho* 1986;6:590-5.
8. **Esser RD.** The medial sagittal approach in the treatment of the congenital clubfoot. *J Pediatr Orthop* 1994;302:156-63.
9. **Haasbeek JF, Wright JG.** A comparison of the long-term results of posterior and comprehensive release in the treatment of clubfoot. *J Pediatr Orthop* 1997;17:29-35.
10. **Hippocrates.** Vol. 3, Loeb Classical (Trans., Dr. E.T. Withington, E.T., 1972). London, Heinemann; New York, Putman 1972;347-51.
11. **Huang YT, Lei W, Zhao L, Wang J.** The treatment of congenital club foot by operation to correct deformity and achieve dynamic muscle balance. *J Bone Joint Surg* [Br] 1999;81:858-62.
12. **Hutchins PM, Foster BK, Paterson DC, Cole EA.** Long-term results of early surgical release in club feet. *J Bone Joint Surg* [Br] 1985; 67:791-9.
13. **Irani RN, Sherman MS.** The pathological anatomy of idiopathic clubfoot. *Clin Orthop* 1972;84:29-38.
14. **Levin MN, Kuo KN, Harris GF, Matesi DV.** Posteromedial release for idiopathic talipes

equinovarus. A long-term follow-up study. *Clin Ortho* 1989; 242:265-8.

15. **Little DG, Aiona MD.** Limb length discrepancy in congenital talipes equinovarus. *Aust NZ J. Surg* 1995;65:409-11.
16. **Lu YP, Wang CL, Huang YT, Lu Y, Li MC.** Treatment of congenital clubfoot by early operation. *Orthopaedics* 1988;11:1093-101.
17. **Main BJ, Crider RJ.** An analysis of residual deformity in club feet submitted to early operation. *J Bone Joint Surg* [Br] 1978;60:536-43.
18. **McKay DW.** New concept of and approach to clubfoot treatment: section II – correction of the clubfoot. *J Pediatr Orthop* 1983;3:10-21.
19. **McKay DW.** New concept of and approach to clubfoot treatment: section III – evaluation and results. *J Pediatr Orthop* 1983;3:141-8.
20. **Nather A, Bose K.** Conservative and surgical treatment of clubfoot. *J Pediatr Orthop* 1987;7:42-8.
21. **Ponseti IV, Smoley EN.** Congenital club foot: the results of treatment. *J Bone Joint Surg* [Am] 1963;45:261-75.
22. **Ponseti IV.** Current Concepts review treatments of congenital club foot. *J Bone Joint Surg* [Am] 1992;74:448-54.
23. **Swann M, Lloyd-Roberts GC, Catterall A.** The anatomy of uncorrected club feet. A study of rotational deformity. *J Bone Joint Surg* [Br] 1969;51:263-9.
24. **Turco VJ.** Resistant congenital club foot: one-stage posteromedial release with internal fixation. A follow-up report of a fifteen-year experience. *J Bone Joint Surg* [Am] 1979;61:805-14.
25. **Wesely MS, Barenfeld PA, Barrett N.** Complications in the treatment of clubfoot. *Clin Orthop* 1972;84:93-6.
26. **Wynne-Davies R.** Talipes equinovarus. A review of eight-four cases after completion of treatment. *J Bone Joint Surg* [Br] 1964;46:464-76.

SPINE HEIGHT AND DISC HEIGHT CHANGES AS THE EFFECT OF HYPEREXTENSION USING STADIOMETRY AND MRI

Dimitrios Kourtis MSc, Marianne L. Magnusson DrMedSc, Francis Smith MB, BCh, MD*, Alex Hadjipavlou MD#, Malcolm H Pope DrMedSc, PhD, DSc

ABSTRACT

Study Design. In vivo biomechanical design using stadiometry and MRI to measure the height change due to (hyper)extension.

Summary of Background Data. Spine height is decreased under loads such as lifting, whole body vibration and sitting. Extension including increased lumbar lordosis reduces the load on the spine.

Methods. The aim was to assess the effects of a supine hyperextended posture as a means of restoring the intervertebral disc height after loading and allowing rehydration of the discs. Ten healthy male subjects were tested. A hyperextension intervention was achieved by the means of an inflatable cushion placed under the lumbar spine. The spine height was measured using a stadiometer and MRI was used to assess disc height changes.

Results. The spine height gain after 10 minutes of a supine hyperextended posture differed significantly between individuals but everybody gained height. MRI images of the lumbar spine were used to measure the disc height. All but one subjects gained height during the hyperextension. Images of the spine during hyperextended posture showed increased lumbar curve and an increased anterior height of each disc compared with the dimensions of the disc with the spine in neutral posture.

Conclusions. All subjects lost height during sitting. Both methods demonstrated a recovery of height due to hyperextension. Hyperextension could be considered as a prophylaxis against the height loss in occupational loading.

INTRODUCTION

There is a normal diurnal change in spine height. This change is increased under occupational exposures such as lifting, whole body vibration and sitting. In sitting, the normal lumbar lordosis flattens and the intradiscal pressure increases. The beneficial effects of extension (increase of lumbar lordosis) were demonstrated by Williams et al.[10], which showed that a lordotic posture results in less back pain than a kyphotic one. It has been shown that a sitting posture causes the spine to lose height.[3] The height changes are due to both compression and creep of the intervertebral disc and the postural change.

A popular method for seated height measurements is a stadiometer described by Magnusson et al.[3] The stadiometer is a device for assessing overall spinal height change while controlling the posture (Figure 1). Height changes are measured using a linear variable transformer (LVDT) with a plunger directly over the top of the head. The technique has been used in a number of studies to evaluate the effects of seat back inclination on spine height changes[5], whole body vibration[4], back supports[9], and passive and active extension interventions.[6-8] It is believed that the amount of height loss/gain is proportional to increasing or decreasing compressive loads on the spine. Magnusson and Pope[6] showed that passive hyperextension for 20 minutes resulted in a significantly increased height recovery compared to a prone flat posture. It is believed that, during hyperextension the facet joints act like a fulcrum, in such a way that they allow more fluid to return into the intervertebral disc, resulting in a height increase.[4] They tested the hypothesis that stretching hyperextension effort shifts the load pathways in the lumbar spine; however the recovery in height is temporary.[8] During hyperextension, the facet joints support a certain amount of load that is normally applied to the intervertebral disc. Moreover, the hydration of the disc in-

Liberty Worksafe Research Centre
Dept. of Environmental and Occupational Medicine
University of Aberdeen
Foresterhill Road
Aberdeen, AB25 2ZP Scotland and

* Aberdeen Royal Infirmary
Grampian University NHS Trust
Aberdeen, Scotland and

#University of Crete
Greece

Corresponding Address
Dr. M. Magnusson
Department of Environmental and Occupational Medicine
Foresterhill Road
University of Aberdeen
AB25 2ZP, Scotland, UK

Figure 1. Modified Stadiometer for sitting measurements (from Magnusson et al. 1990).

creases (temporarily) and this results in an improvement of disc nutrition. Another study showed that the optimal time and angle combination was 20° for 20 minutes, as it resulted in the largest recovery and also remained for a relatively long period of time.[7] This method can be useful in therapy and in primary and secondary prevention of low back pain.

MATERIALS AND METHODS

For measuring the effects of 10 minutes hyperextension after 5 minutes loading in a seated position, two different methods were used, stadiometry and MRI.

STADIOMETRY

A stadiometer modified for seated postures was used (Figure 1). The subject was positioned in the stadiometer, the supports for head and pelvis were adjusted and four rods to control posture were adjusted to the subject's spinal curve. The subjects were asked to focus their eyes on a spot straight ahead, in order to keep the head still. A linear variable differential transformer (LVDT) with a plunger was lowered on to the top of the subject's head. The sample frequency was 1 Hz. The adjustable rods were placed at four different regions of the spine: a) the mid lumbar region (~L3), b) the mid to lower thoracic region (~T8), c) the upper thoracic region (~T4) and d) the mid cervical region (C4). The seat pan was fixed, while the footrest was adjustable up-down and forwards-backwards, in order to achieve 90°, 75° and 75° angles, for the hip, knee and ankle joints respectively. The LVDT was connected to an analogue oscilloscope and was calibrated by 5mm thick flat metal plates.

All the subjects were males between 23 and 30 years old (mean: 26.3, Sd: 2.26), with no history of any musculoskeletal disorder. Their height ranged from 1.67 - 1.97 m (mean: 1.8 m, Sd : 0.077 m), their weight from 65 - 101 Kg (mean: 80.5 Kg, Sd: 12.349 Kg). Prior to the measurements, each subject underwent a training session of repositioning in the stadiometer, in order to achieve a variation less than 1 mm due to posture differences.

Figure 2. Inflatable cushion used to increase the lumbar curve.

All measurements were made between 9:00 to 13:00. The subject lay for 10 minutes in a supine position with the spine in a neutral angle, to normalise hydration from any pre-loading. Thereafter, the subject was positioned in the stadiometer and was loaded with 4.5 Kg on each shoulder for 5 minutes. After removing the loads, a curve of the length changes of the LVDT over time was obtained for 5 minutes, which was followed by a 10 minutes intervention, where the subject adopted a supine hyperextended posture, achieved by means of an inflatable lumbar support. Finally, the subject was placed again in the stadiometer and another curve of the length changes of the LVDT over time was obtained for 5 minutes. For each set of measurements (prior and post hyperextension) the oscilloscope readings were recorded every 20 seconds.

The lumbar support (Figure 2) used to achieve hyperextension was a plastic, inflatable, ellipsoidal cushion with dimensions of 34 cm x 11 cm when deflated. The air pressure of the cushion was 180 mm of H_2O ± 10%, depending on parameters such as the height, weight and flexibility of each subject, but also on the tolerance of the subjects to this slightly uncomfortable posture. The natural curvature of the lumbar spine provided the means for positioning the cushion always at the same point for each subject i.e. right under the peak curve. Thus, a fairly good repeatability of the procedure was achieved as well as the attainment of a symmetrical hyperextended posture.

MAGNETIC RESONANCE IMAGING

The procedure for the MRI scans was kept as close as possible to the procedure that was followed for the stadiometry measurements. The subjects who were scanned were the same ones that underwent the stadiometry procedure and all the scans were taken

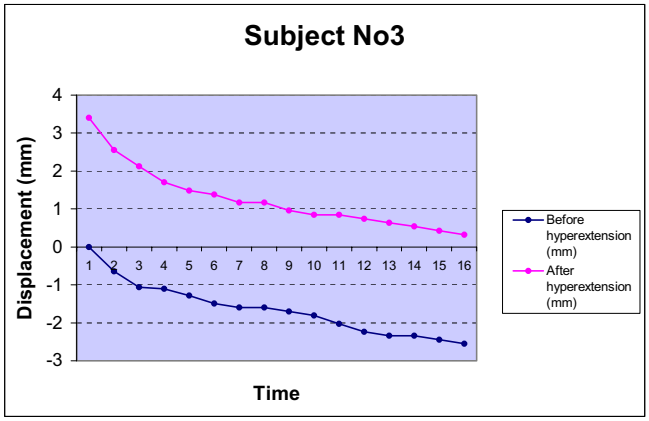

Figure 3. Stadiometer results for one subject.

TABLE 1
Average height changes pre- and posthyperextension

Sec	Prehyperextension	Posthyperextension
0	0	**+5.234 (1.798)mm**
20	-1.226 (0.831) mm	-1.873 (1.194) mm
40	-1.883 (1.172) mm	-2.617 (1.729) mm
60	-2.272 (1.260) mm	-3.277 (2.208) mm
80	-2.549 (1.298) mm	-3.774 (2.715) mm
100	-2.905 (1.407) mm	-4.130 (2.890) mm
120	-3.206 (1.515) mm	-4.466 (3.050) mm
140	-3.370 (1.516) mm	-4.781 (3.220) mm
160	-3.681 (1.792) mm	-5.066 (3.258) mm
180	-3.868 (1.894) mm	-5.253 (3.359) mm
200	-4.141 (1.917) mm	-5.479 (3.455) mm
220	-4.275 (1.982) mm	-5.636 (3.493) mm
240	-4.440 (1.986) mm	-5.866 (3.551) mm
260	-4.562 (2.010) mm	6.023 (3.613) mm
280	-4.838 (2.165) mm	-6.198 (3.665) mm
300	**-5.030 (2.266)mm**	**-6.374 (3.766) mm**

between 9:00 and 13:00. First, the subject lay supine for 10 minutes with the spine in a neutral angle and then sat on a chair for 5 minutes with loads of 4.5 kg on each shoulder. Thereafter, the subject lay in a supine neutral position inside the magnet and a scan was performed, which lasted for 4 minutes. The inflatable cushion was thereafter placed under the lumbar spine, so a hyperextended posture was adopted. This lasted for 10 minutes, after which another image was obtained, starting from the 6th minute of hyperextension and finishing at the 10th minute. For each subject, the air pressure inside the cushion was exactly the same as the one used in the stadiometry. Finally, the cushion was removed and another 4 minutes scan was taken with the spine in a neutral position.

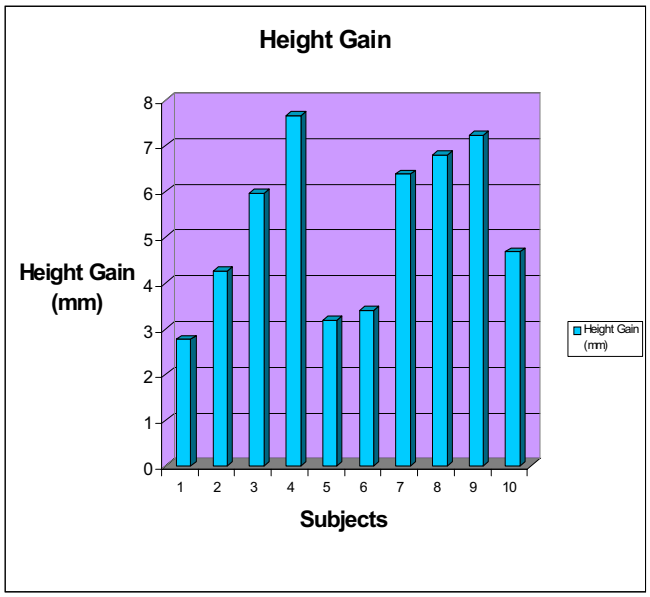

Figure 4. Height gain for each subject after 10 minutes in a supine hyperextended posture.

TABLE 2
Percentage of height loss per minute

Minutes	1	2	3	4	5
Pre-Hyperextension	45.169 %	18.569 %	13.161 %	11.371 %	11.730 %
Post-Hyperextension	51.412 %	18.654 %	12.347 %	9.617 %	7.970 %

The magnet, which was used was a 0.2 Tesla "C-shaped" open magnet (Siemens Magnetom Open Viva). As we were interested in measuring the difference in height of the intervertebral discs, took sagittal images of the lumbar spine were taken using a standard pulse sequence for this purpose, called Turbo Spin Echo. The parameters that were used were the following:

Echos	TR (repetition time)	TE (echo time)	Scan time	Field of view	Slices	Acquisitions
15	3900msec	134msec	3min16sec	175mmx350mm	9(6mm)	3

RESULTS

Stadiometry

Typical results of one subject using the stadiometer are presented in Figure 3. The average over all subjects is presented in Table 1.

Readings of the oscilloscope were taken every 20 seconds. The table shows the readings while seated, pre- and post hyperextension. The figures represent the height lost by the subjects for each point of time, with the Sd given within parentheses. The average amount of height gain after 10 minutes in the supine hyperextended posture (5.234 mm ± 1.798 mm) was almost the

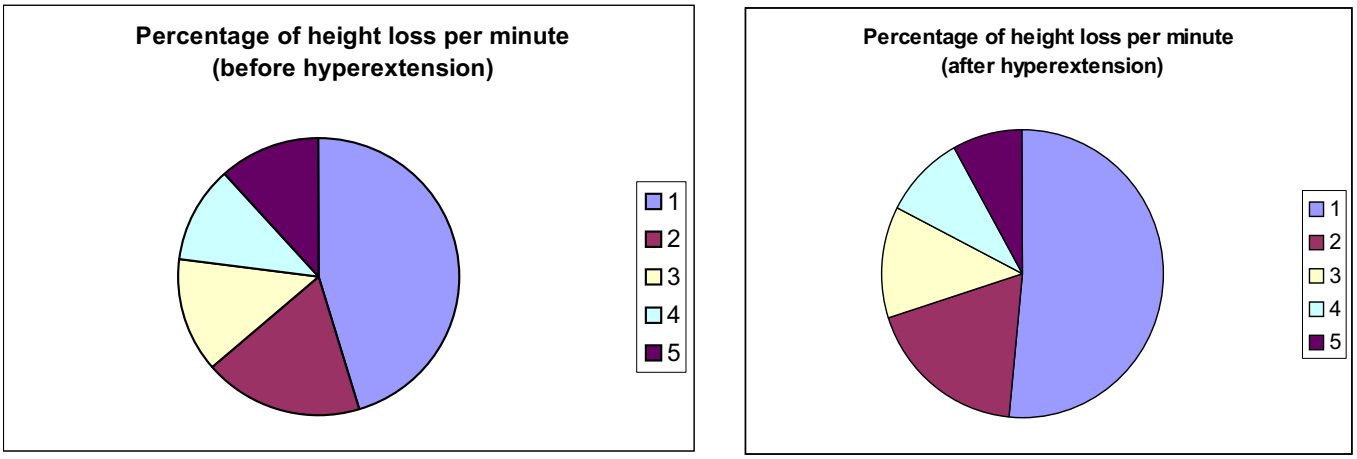

Figure 5. Percentage of average height loss per minute before (A) and after (B) hyperextension.

Figure 6. Image of the lumbar spine in a neutral angle (A), and in the hyperextended posture (B).

same as the height lost (5.030 mm ± 2.266 mm) during the seated posture before hyperextension. The starting point is different from the first measurements as it is the point that is defined as the difference between the mean height gained during hyperextension (5.234 mm) and the mean height lost during sitting before hyperextension (5.030 mm), that is 0.204 mm higher than the original point. It is worth mentioning that the mean amount of height lost after hyperextension was about 1 mm greater than the height gained during hyperextension; however the standard deviation was as large as ~ 2 mm. As for individual subjects, eight of them lost more than gained height during hyperextension. Although there are differences between subjects, all graphs follow a similar pattern. Of most interest was the amount of height gain after 10 minutes of a supine hyperextended posture. While it differed significantly between individuals, everybody gained height, as shown in Figure 4. The values varied from 2.766 mm to 7.660 mm with a mean of 5.234 mm (Sd 1.798 mm).

The amount of height lost pre- and posthyperextension was also compared. Before hyperextension, the subjects lost height from 2.340 mm up to 8.936 mm with a mean value of 5.030 mm and a standard deviation of 2.266 mm. After hyperextension, the amount of height loss varied from 2.872 mm up to 15.319 mm, with a mean value of 6.374 mm and a standard deviation of 3.766 mm. With the exception of one subject, all subjects lost

TABLE 3
Spine (part of it) length pre- and posthyperextension

Subjects	Spine length pre-hyperextension (mm)	Spine length post-hyperextension (mm)	Difference (mm)
1	212	214	+ 2
2	208	206	- 2
3	228	231	+ 3
4	216	220	+ 4
5	217	220	+ 3
6	233	236	+ 3
7	206	208	+ 2
8	200	202	+ 2
9	234	236	+ 2
10	245	247	+ 2

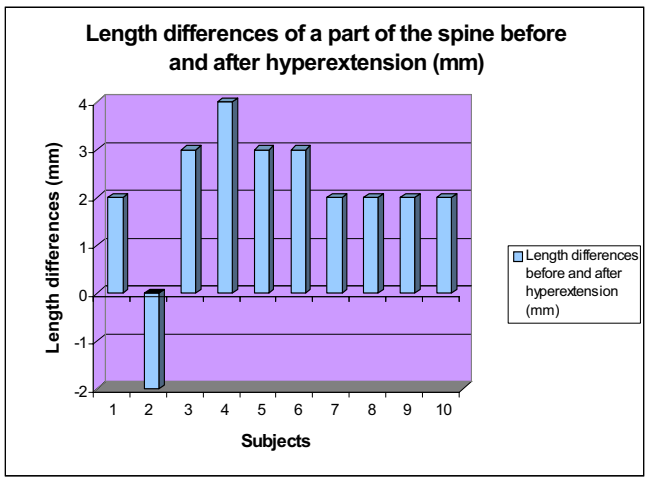

Figure 7. Height (length) gain and loss of the lumbar spine before and after hyperextension.

more height after the hyperextension intervention than before it.

One other parameter derived from the measurements was the percentage of height loss per minute. The largest amount of height loss occurred during the first minute both in pre- and posthyperextension (Table 2 and Figures 5 A and B).

MAGNETIC RESONANCE IMAGING

Three images of the lumbar area of the spine were taken. The first and the third image were taken with the spine in a neutral angle (Figure 6A), before and after the 10 minutes intervention of hyperextended posture (Figure 6B).

The most interesting parameter was the difference in height after hyperextension. However, it was not possible to image the whole spine, because of the limited field of view. In addition, it was not practical to measure the possible height gain in separate intervertebral discs, because the height difference was expected to be a fraction of a mm, thus it would be impossible to have adequate accuracy in our measurements. Thus, we elected to measure the length of the part of the spine that was clear in the images for all the volunteers. This included seven intervertebral discs: S1/ L5 to T12/11. However, these are the thickest discs in the spine. The measurements were made using the available software of the magnet. The measurements were repeated three times for each subject and the estimated error was less than 0.5 mm. The collected data are displayed in Table 3.

TABLE 4
Comparison between the anterior and posterior height (in cm) of the lumbar intervertebral discs pre- and posthyperextension

Subjects	L_1/L_2		L_2/L_3		L_3/L_4		L_4/L_5	
	Ant	Post	Ant	Post	Ant	Post	Ant	Post
1 – Pre	1.0	0.7	1.1	0.9	1.4	1.0	1.6	0.7
1 – Post	1.1	0.7	1.2	0.9	1.6	0.9	1.7	0.6
2 – Pre	0.8	0.7	0.9	0.6	1.2	0.9	1.2	0.8
2 – Post	0.9	0.6	1.1	0.6	1.2	0.8	1.3	0.8
3 – Pre	1.2	0.8	1.2	0.9	1.3	0.9	1.5	1.0
3 – Post	1.3	0.7	1.3	0.8	1.5	0.9	1.7	0.9
4 – Pre	0.8	0.6	1.0	0.7	1.1	0.8	1.5	0.8
4 – Post	0.9	0.6	1.1	0.7	1.3	0.7	1.6	0.8
5 – Pre	1.1	0.7	1.1	0.7	1.3	0.9	1.5	0.9
5 – Post	1.2	0.6	1.3	0.7	1.4	0.8	1.6	0.8
6 – Pre	0.9	0.6	1.0	0.8	1.2	0.9	1.5	0.8
6 – Post	1.2	0.5	1.3	0.7	1.4	0.7	1.6	0.8
7 – Pre	0.8	0.6	1.0	0.8	1.2	0.8	1.3	0.7
7 – Post	0.9	0.5	1.1	0.7	1.2	0.8	1.5	0.6
8 – Pre	0.6	0.6	0.8	0.7	1.1	0.7	1.2	1.0
8 – Post	0.7	0.7	1.0	0.7	1.1	0.7	1.2	0.9
9 – Pre	0.7	0.5	1.0	0.7	1.2	0.8	1.5	0.9
9 – Post	1.0	0.4	1.1	0.7	1.3	0.7	1.6	0.9
10 – Pre	1.0	0.7	1.1	0.8	1.3	0.8	1.1	0.9
10 – Post	1.3	0.7	1.3	0.7	1.5	0.8	1.3	0.9

Nine of the ten subjects gained height during the 10 minutes of hyperextension. Half of them gained 2 mm, three others gained 3 mm, one gained 4 mm while one lost 2 mm. The mean gain in height was 2.1 mm, while the standard deviation (mostly due to the subject who lost height) was 1.57 mm. The results are schematically displayed in Figure 7.

Images of the spine when the volunteers adopted a hyperextended posture for 10 minutes were taken. It was obvious that the lumbar curvature had increased. Moreover, the anterior height of each disc increased while the posterior height had decreased, when compared with the dimensions of the disc with the spine in

neutral angle before the hyperextension intervention. The mean anterior height increased from 1.13 to 1.27cm ($p<0.005$) and the posterior height decreased from 0.777 to 0.725 ($p<0.005$). The dimensions for the intervertebral disc space between each lumbar vertebra are presented in Table 4.

DISCUSSION

The curve obtained using the stadiometer, which describes the average height loss pre and post hyperextension is an overall indication of the behaviour of the spine, under the conditions described in this study. It is worth mentioning that the standard deviation is very high; in some cases it is almost 70% of the mean value. However, this is something that was expected, since the only common characteristics of our volunteers were their age (23-30 years old) and their gender (male). There were remarkable differences in height (up to 30 cm), in weight (up to 37 Kg), in stamina and even differences in their character, which made some of the subjects less focused to the procedure or less tolerant to the requirements (i.e., sitting completely still for 5 minutes). Moreover, although none of the subjects had a history of back problems, the MRI scans revealed some pathological conditions (e.g., Subject No 9 is scoliotic, Subject No 10 has two degenerated "black" intervertebral discs) that may have affected the results.

Nevertheless, the graphs for individual subjects followed a similar pattern. All subjects lost height during sitting, as it was expected, since when a person is sitting the lumbar lordosis tends to flatten, so the intradiscal pressure rises, resulting to fluid transport out of the intervertebral disc.[4, 10] The measurements also showed that most of the height is lost during the first minute. This verifies previous research[3] and it is believed that this occurs due to the osmotic swelling pressure within the disc, which tends to resist the hydrostatic pressure derived from compressive loads and prevents the disc of becoming completely dehydrated.[1,2]

After the 10 minute hyperextension intervention, all the subjects gained height. However, it cannot be argued that the height recovery for any person going through the same procedure will be of this magnitude. An unknown, and practically impossible to measure, amount of height loss took place during the interval in which the subject got up from the bed and positioned himself in the stadiometer. In addition, although each volunteer underwent a training session of positioning in exactly the same posture in the stadiometer (with no more than 1 mm variability), it cannot be certain that the desired accuracy was obtained when the subjects were tired and un-concentrated at the end of the 30 minutes procedure.

It is clear that hyperextension causes height gain, as has been shown in previous research.[6-8] In addition, we were able to verify this by using MRI. It was clear that during hyperextension the Functional Spine Units were more "open" anteriorly than in a neutral posture (Figure 7, Table 4). Even in the neutral position, the anterior part of the FSUs were more "open" than the posterior parts; this is probably one reason for recovering height when resting on a bed. The anterior height of four intervertebral discs, during hyperextension, was even 40% greater than normal in some cases, while the posterior height decreased up to 20%. Consequently, more fluid is allowed to be imbibed into the disc and at a faster rate when compared to "flat" supine posture.[7]

In the MRI scans, due to the limited field of view, only a part of the spine was possible to image. However, this included the whole lumbar part, which was most important since the purpose of the cushion was to increase the lumbar lordosis of the spine. The comparison of the length of this part of the spine pre and post hyperextension (Table 3) showed that the individuals gained and also maintained height, since lying on a bed is not a loading condition for the intervertebral discs. The reduction in height after hyperextension in one subject could possibly be caused by small muscle contractions or that the subject rolled slightly over his glutei, by compressing his spine (the subject was rather obese).

Another indication of the rehydration of the disc due to hyperextension is the fact that nine out of ten volunteers lost more height when sitting in the stadiometer after being hyperextended than before. Also, the percentage of height that was lost during the first minute was greater after hyperextension (51.412% of the total amount) than before (45.169%), as we can derive from Table 2 and Figures 5 and 6. One of the properties of a well hydrated intervertebral disc is its relatively low osmotic swelling pressure, which retains fluid in the disc. Therefore, under a compressing condition (e.g., sitting), more fluid is "available" to flow out of the disc and it can be argued that it will occur faster than in a less hydrated disc. In this study, there was one subject who had opposite results than the others, i.e. he lost more height before hyperextension. However, this subject (as it was shown in the MRI scans) had scoliosis, which possibly could have affected the distribution of the loads on his spine. Another reason could be that he tried to remain still in the stadiometer by pressuring his hands on his lap rather than having them relaxed.

Comparing the two methods (stadiometry and Magnetic Resonance Imaging), although following similar procedures, it cannot be argued that there is a direct correlation between results. One important reason for

this is that the measurements with the stadiometer were taken while the subjects were sitting, while in MRI the subjects were lying. Therefore, the already compressed spine from the weight bearing (4.5 Kg on each shoulder for 5 minutes), became even more compressed before the hyperextension intervention in stadiometry. On the contrary, in order to obtain the MRI images, after the weight bearing period, the subjects had to lie, which started to unload the spine, so the effects of hyperextension could not be the same, since the measurements started from different conditions of the intervertebral discs.

Another difference is that using the stadiometer, the height changes of the whole spine (including the head, the neck and the glutei) were measured. With the MRI only 7 intervertebral discs, although the whole lumbar spine, were imaged. The advantage of the stadiometer was that data were recorded every 20 seconds.

For the MRI measurements a "fast" sequence (Turbo Spin Echo) was used, which is the standard for imaging the spine. The advantage of this sequence, as it is for every "fast" sequence, is that it produces images of adequate quality in a relatively short time (in this case about 4 minutes including tuning of the machine and adjustment of the field of view). However, the image was not obtained in "real time," but it was the average of 3 acquisitions, which required 3 minutes and 16 seconds (net scan time). The huge advantage of this technique is that it provides images of the actual intervertebral discs, consequently allowing us to measure height differences caused only by fluid flow inwards and outwards of the discs, excluding any other parameter, which may induce height changes (in the case of the stadiometer, fatigue and inability to maintain a still posture).

REFERENCES

1. **Adams MA, McNally DS and Dolan P.** Stress distribution inside intervertebral discs: The effects of age and degeneration. *J Bone and Joint Surg* (Br) 1996;78: 965-972.
2. **Botsford DJ, Esses SI and Ogilvie-Harris DJ.** In vivo diurnal variation in intervertebral disc volume and morphology. *Spine,* 1994; 19: (8) 935-940.
3. **Magnusson ML, Hult E, Lindstrˆm I, Lindell V, Pope MH and Hansson T.** Measurement of time-dependent height-loss during sitting. *Clin Biomechanics,* 1990; 5; 137-142.
4. **Magnusson ML, Almqvist M, Broman H, Pope M and Hansson T.** Measurement of height loss during whole body vibrations. *J Spinal Disorders,* 1992; 5:(2) 198-203.
5. **Magnusson M, Hansson T, Pope MH.** The effect of seat back inclination on spine height changes. *Applied Ergonomics,* 1994; 25(5):294-298.
6. **Magnusson ML, Pope MH and Hansson T.** Does hyperextension have an unloading effect on the intervertebral disc? *Scand J Rehab Med,* 1995;27; 5-9.
7. **Magnusson ML, Aleksiev AR, Spratt KF, Lakes RS and Pope MH.** Hyperextension and spine height changes. *Spine,* 1996; 21: (22) 2670-2675.
8. **Magnusson ML and Pope ML.** Body height changes with hyperextension. *Clin Biomechanics,* 1996; 11: (4) 236-238.
9. **Magnusson M, Pope MH, Hansson T.** Does a back support have a positive biomechanical effect? *Applied Ergonomics* 1996; 27 (3):201-205.
10. **Williams MM, Hawley JA, McKenzie RA and Van Wijmen PM.** A comparison of the effects of two sitting postures on back and referred pain. *Spine,* 1991;16:(10) 1185-1191.

PLANTAR FOOT SURFACE TEMPERATURES WITH USE OF INSOLES

Michelle Hall, B.S.E., Donald G. Shurr, C.P.O., P.T., M. Bridget Zimmerman, Ph.D., Charles L. Saltzman, M.D.

ABSTRACT

Purpose—Patients with diabetes are often prescribed foot orthoses to help prevent foot ulcer formation. Orthotics are used to redistribute normal and shear stress. Shear stresses are not easily measurable and considered to be responsible for skin breakdown. Local elevation of skin temperature has been implicated as an early sign of impending ulceration especially in regions of high shear stress. The purpose of this study was to measure the effects of commonly prescribed insole materials on local changes in plantar foot temperature during normal gait.

Methods—Six commonly used foot orthosis materials were tested using the Thermo Trace™ infrared thermometer to measure foot temperature. Ten healthy adult volunteers without any history of diabetes or abnormal sensation participated in the study. During each trial the subject walked on a treadmill with the test material in the dominant foot's shoe, for six minutes at a speed of four miles per hour and rested for six minutes between trials. Four locations on the foot (hallux, first and fifth metatarsal heads, and heel) and the contralateral bicep temperatures were measured at 0, 1, 3, 5 minutes during the rest period. The order of material and skin location testing was randomized.

Results—Significant differences were found between baseline temperatures and foot temperatures for all materials. However, no differences were found between materials for any location on the foot.

Conclusion—Previous studies have attempted to characterize materials based on laboratory and clinical testing, while other studies have attempted to characterize the effect of pressure on skin temperature. However, no study has previously attempted to characterize foot orthosis materials based on foot temperatures. This study compared foot temperatures of healthy adults based on the material tested. Although this study was unable to distinguish between materials based on foot temperatures, it was able to show a rise in foot temperature with any material used. This study demonstrates a need to a larger study on a population with diabetes.

Corresponding author:
Charles Saltzman, MD
Professor
Orthopaedics and Rehabilitation
Bioengineering
University of Iowa
319-356-7149

Acknowledgments: This study was supported by NIH RO1 NR07721-03

INTRODUCTION

Diabetes is the leading cause of lower-limb amputations in the United States, totaling 82,000 per year between 1997 and 1999.[1] Although patients diagnosed with diabetes only account for 6.2% of the U.S. population, 19% of the personal healthcare expenditures in 2002 were for this population.[1] Patients with diabetes are often prescribed foot orthoses to help prevent or treat plantar foot ulcers. The purpose of the orthotic is generally to reduce pressure and shear.[4, 7-10, 12-13] Brand has suggested that the main problem causing ulceration is shear induced "tenderizing" of the plantar soft tissue with resultant elevated temperature that results in cellular injury.[3] In a case series he has shown that repeated injury increases focal plantar temperatures and has correlated repeated shear stresses to tissue breakdown and ultimate ulceration. [3]

Although several investigators have examined the effects of pressure[11.14], diabetes[2,5,6], leprosy[6], and diabetic neuropathy[2,5] on skin temperature, none have evaluated the potential interaction of orthotic material and plantar soft tissue temperature. The purpose of the present study is to evaluate the thermal response of the sole of the foot to standard insert material with substantially different structural and material properties.

METHODS

Subjects

Thirteen healthy young adult volunteers were recruited from the University of Iowa for participation in this IRB approved study. All subjects denied any his-

tory of diabetes, lower extremity deformity, abnormal sensation in the lower limbs, traumatic injury to the lower extremities within the last 12 months, or previous use of lower limb orthoses. Subjects were able to walk unassisted. The subject group consisted of 7 men and 6 women with mean: age 21.9 years (range 19-27 years), height 164.2cm (range 83.5-184cm), weight 77.1 kg (range 57.6-117.2 kg). Each subject's dominant foot, determined by which foot he or she would kick a ball, was tested. Subjects were issued the same style and brand of shoe and socks.

TABLE 1

Location	Mean	SD
1st MT	84.6	0.43
5th MT	82.2	1.18
Bicep	89.8	0.28
Hallux	83.3	3.12
Heel	85.1	0.60

Means and standard deviations for repeatability study. Highest variation was found at hallux. Results expressed in degrees Fahrenheit.

Surface Temperature Measurement

The ThermoTrace infrared thermometer (Delta TRAK Scientific, model 15007) was used to test skin temperature over the contralateral biceps and four locations on the plantar aspect of the foot: hallux, first (1st Met) and fifth (5th Met) metatarsal heads, and heel. One cotton swab was attached to each of the four corners of the thermometer to guarantee that the same orientation and distance from the skin surface was used for each subject. The tip of the swab was set 1" from the end of the device ensuring that an area with 0.1" diameter was measured. All subjects used the same heart rate monitor (Polar Electro Inc., New York, Model 1901201) for all tests, to monitor each subject's exertion.

Materials

Seven materials and the shoe sock liner were tested. The tested materials were: Bocklite (BOC), Pe-Lite (PEL), Plastazote (PLA), Poron (POR), Nylon-covered Poron (NPOR), Ortholite EVA (EVA), and a tri-laminate of Ortholite/Poron/Ortholite (TRI). All materials were $^1/_4$", except the tri-laminate which was made out of $^1/_{16}$" Ortholite, $^1/_{16}$" Poron, and $^1/_8$" Ortholite.

Testing Protocol

Each subject was tested three times, approximately one week apart. No more than three materials were tested during any session. The order of testing was randomized for each subject. During the first test day each test site was marked with a semi-permanent pencil. These marks were then transferred to a piece of paper and the foot traced, to be used for marking the foot during the next two test days. The protocol for every test day was the same. Once the foot and biceps were marked with the semi-permanent pencil, the subject sat without shoe or sock for 10 minutes to allow the foot to acclimate to room temperature. Baseline temperatures were taken prior to the start of any trials each day to account for individual daily variability.

The subjects then completed a warm-up walk on a treadmill for 6 minutes at 4mph. After that, subjects sat for 6 minutes without shoe or sock; no measurements were taken at that point. Each trial was then performed by the subject walking with a test material in the shoe for 6 minutes at 4mph, followed by a 6-minute measurement and rest period without shoe or sock. A new sock was issued for each trial to avoid potentially confounding effects of foot perspiration. The following measurements were recorded for each trial: start and end treadmill heart rate, and heart rate and temperature measurements at the five sites during the rest period. The temperature and heart rate measurements were taken in a random order and within the first 25 seconds after shoe and sock were removed (0 min) to avoid a cooling affect and at 1, 3, and 5 minutes afterwards. The 0 minute data was collected to determine surface plantar foot temperature after use of a material, while the 1, 3, and 5 minute data were collected to examine the cooling effect of the foot. All measurements are expressed in degrees Fahrenheit.

Repeatability and reliability measurements were gathered on three subjects, not in the study. The same five locations' temperatures were measured three times each; subject, site, and order were randomized; all testing occurred on the same day. All subjects sat for 10 minutes without shoe or sock prior to testing and only baseline measurements were gathered.

Data Analysis

Each subject was considered his or her own control, eliminating covariables of height, weight, age, and gender. Each material was compared for each test location. A paired t-test was used to compare each subject's baseline temperature to the temperature for each test material and location. Bonferroni's method was used to adjust the p-values to account for the number of tests performed; p-value <0.05 was considered statistically significant. Temperatures for all test materials were compared for each location and for all subjects using the linear mixed model for repeated measures. To ad-

TABLE 2
Mean Difference from Baseline for Each Material, Each Location, All Subjects at 0 min

	Bicep		Hallux		1st Met		5th Met		Heel	
	Mean (SD)	p-val	Mean (SD)	p-val	Mean (SD)	p-val	Mean (SD)	p-val	Mean (SD)	p-val
TRI	-1.40 (3.28)	1.0000	9.49 (6.79)	0.0020	6.84 (4.27)	0.0007	5.89 (3.75)	0.0008	7.65 (4.13)	0.0002
BOC	-1.97 (1.27)	0.0009	7.34 (5.98)	0.0060	5.57 (5.20)	0.0180	5.73 (5.04)	0.0120	6.58 (4.30)	0.0010
NPOR	-1.90 (1.27)	0.0020	7.48 (7.73)	0.0360	7.53 (5.39)	0.0020	6.84 (5.79)	0.0096	9.06 (6.50)	0.0020
POR	-1.83 (3.21)	0.4980	11.36 (5.94)	0.0001	8.81 (4.35)	0.0000	8.96 (5.18)	0.0003	11.07 (5.97)	0.0002
PEL	-1.47 (3.07)	0.8790	7.91 (8.22)	0.0370	6.44 (6.14)	0.0210	4.85 (6.11)	0.1140	8.04 (5.86)	0.0020
PLA	-2.48 (1.33)	0.0002	8.07 (9.02)	0.0580	8.44 (6.85)	0.0060	7.12 (7.02)	0.0260	8.94 (5.85)	0.0010
EVA	-2.47 (1.79)	0.0020	9.93 (7.94)	0.0060	9.02 (4.93)	0.0002	7.64 (6.35)	0.0080	8.66 (5.07)	0.0004
SHOE	-1.72 (1.51)	0.0110	10.95 (7.95)	0.0020	9.18 (5.45)	0.0004	7.48 (5.56)	0.0030	8.68 (5.12)	0.0004

The mean differences and standard deviations of plantar surface temperature immediately after walking for each material and location. Positive values indicate increased temperatures in degrees Fahrenheit. Materials tested included Bocklite (BOC), Pe-Lite (PEL), Plastazote (PLA), Poron (POR), Nylon-covered Poron (NPOR), Ortholite EVA (EVA), and a tri-laminate of Ortholite/Poron/Ortholite (TRI).

just for differences in the baseline temperature, room temperature, and heart rate, these variables were included as covariates in the model. Tukey's test was used as the post-hoc test for pair-wise comparison of the means between materials and the overall significance level was controlled at 0.05.

RESULTS

The mean and standard deviations for the repeatability testing is recorded in Table 1. The hallux had the greatest variability for all subjects, while the biceps site had the least.

With walking, the mean temperature on the sole of the foot was increased at 0 minutes and 5 minutes. Immediately after walking, the temperature increase averaged 9.1˚ (range, 7.3˚-11.4˚) under the hallux, 7.7˚ (range, 5.6˚-9.2˚) under the first metatarsal head, 6.8˚ (range, 4.9˚-9.0˚) under the fifth metatarsal and 8.6˚ (range, 6.6˚-11.1˚) under the heel (Table 2). Five minutes after walking, the temperature increase averaged 8.8˚ (range, 6.1˚-11.7˚) under the hallux, 7.3˚ (range, 5.1˚-9.0˚) under the first metatarsal head, 7.5˚ (range, 4.7˚-8.7˚) under the fifth metatarsal and 6.8˚ (range, 4.6˚-7.9˚) under the heel (Table 3). No significant differences were found between any materials for any location. Baseline had a positive effect on temperature for all locations and room temperature had a positive affect on the biceps site reading, while heart rate had no affect on temperature at any location.

DISCUSSION

The repeatability testing indicated that the device and method used to test skin temperatures was adequate for determining differences in temperatures. The changes at the hallux were likely due to localization difficulties on this relatively small target. Similarly, the low standard deviations at the heel and biceps sties were likely related to the relative ease of reproducing a site specific reading in these anatomically less discrete areas.

Lack of differentiation between materials can be due to several effects. First, there may be no true difference in the response of plantar skin to the varying material properties of these insert materials, and selection of materials should be made purely each individual's need to redistribute foot loads. The potential other causes for lack of differentiation between the effects of orthotic materials on plantar skin temperature relate to the testing protocol. The type of shoewear, duration and type of testing were selected to facilitate the performance of the tests. We realized the limitations and difficulties with insuring that subjects returned multiple times for the same tests, and that to some extent fatigue and loss of interest may undermine our ability to collect sufficient data to perform the comparison. The choice of walking speed and the duration of all aspects of the testing were based on these considerations. The choice of shoe and sock were based on the typical footwear of a diabetic patient with neuropathic-related foot disease.

The use of young healthy adults may be responsible for the lack of differentiation between material effects on plantar thermal response. These subjects all were presumed to have intact neurovascular responses and may have been able to modify their gait or plantar loading to prevent any regions from excessive stress.

TABLE 3
Mean Difference from Baseline for Each Material, Each Location, All Subjects at 5 min

	Bicep		Hallux		1st Met		5th Met		Heel	
	Mean (SD)	p-val	Mean (SD)	p-val	Mean (SD)	p-val	Mean (SD)	p-val	Mean (SD)	p-val
TRI	-0.85 (1.27)	0.2620	8.59 (8.00)	0.0180	6.74 (5.65)	0.0080	7.22 (6.16)	0.0100	6.00 (5.94)	0.0270
BOC	-1.18 (1.48)	0.1120	6.09 (7.33)	0.0890	5.08 (4.45)	0.0100	4.65 (5.09)	0.0520	4.55 (5.17)	0.0640
NPOR	-1.36 (1.46)	0.0460	7.63 (6.26)	0.0070	7.50 (4.74)	0.0008	7.50 (4.46)	0.0005	7.86 (4.96)	0.0008
POR	0.41 (5.44)	1.0000	11.02 (6.63)	0.0005	8.50 (4.05)	0.0000	8.72 (4.40)	0.0000	7.82 (6.16)	0.0050
PEL	-1.38 (1.14)	0.0070	7.75 (9.64)	0.1070	5.99 (7.20)	0.0900	6.48 (8.14)	0.1130	5.88 (6.90)	0.0770
PLA	-1.08 (1.17)	0.0460	7.53 (8.47)	0.0600	7.40 (6.20)	0.0080	8.62 (7.67)	0.0130	7.52 (5.92)	0.0050
EVA	0.22 (5.14)	1.0000	10.04 (7.13)	0.0020	9.02 (5.19)	0.0003	8.55 (5.48)	0.0009	7.52 (5.72)	0.0040
SHOE	-0.42 (1.06)	1.0000	11.74 (7.64)	0.0010	7.83 (6.56)	0.0080	7.86 (7.42)	0.0190	6.85 (6.47)	0.0200

The mean differences and standard deviations of plantar surface temperature 5 minutes after walking for each material and location. Positive values indicate increased temperatures in degrees Fahrenheit. Materials tested included Bocklite (BOC), Pe-Lite (PEL), Plastazote (PLA), Poron (POR), Nylon-covered Poron (NPOR), Ortholite EVA (EVA), and a tri-laminate of Ortholite/Poron/Ortholite (TRI).

Whether these findings are generalizable to neuropathic patients is unknown. The effects of peripheral neuropathy in diabetes can be protean-inducing a change or elimination of a sweating response, eliminating protective sensation, and causing pressure problems from intrinsic muscle wasting, toe clawing and arch elevation. Because of these clear differences, further study in the diabetic neuropathic population is needed to delineate if these orthotic materials differentially increase skin temperature.

REFERENCES

1. **American Diabetes Association.** "Economic Costs of Diabetes in the U.S. in 2002." *Diabetes Care.* 2003; 26(3): 917-32.
2. **Armstrong DG, Lavery LA,** et al. "Infrared Dermal Thermometry for the High-risk Diabetic Foot." *Physical Therapy.* 1997; 77(2): 169-77.
3. **Brand, PW.** "Tenderizing the Foot." Foot Ankle Int. 2003 Jun; 24(6):457-61.
4. **Birke JA, Foto JG, Pfiefer LA.** "Effect of Orthosis Material Hardness on Walking Pressure in High-Risk Diabetes Patients." *Journal of Prosthetics and Orthotics.* 1999; 11(2) 43-46.
5. **Boyko EJ, Ahroni JH, Stensel VL.** "Skin Temperature in the Neuropathic Diabetic Foot." *Journal of Diabetes and Its Complications.* 2001; 15: 260-64.
6. **Clark RP, Goff MR, Hughes J, Klenerman L.** "Thermography and Pedobarography in the Assessment of Tissue Damage in Neuropathic and Athersclerotic Feet." *Thermology.* 1988; 3: 15-20.
7. **Curryer M, Lemaire ED.** "Effectiveness of Various Materials in Reducing Plantar Shear Forces: A Pilot Study." *Journal of the American Podiatric Medical Association.* 2000; 90(7): 346-53.
8. **Hosein R, Lord M.** "A Study of In-shoe Plantar Shear in Normals." *Clinical Biomechanics (Bristol, Avon).* 2000 Jan; 15(1): 46-53.
9. **Lavery LA,** et al. "Novel Methodology to Obtain Salient Biomechanical Characteristics of Insole Materials." *Journal of the American Podiatric Medical Association.* 1997 Jun; 87(6) 266-71.
10. **Lord M, Hosein R.** "A Study of In-shoe Plantar Shear in Patients with Diabetic Neuropathy." *Clinical Biomechanics (Bristol, Avon).* 2000 May; 15(4): 278-83.
11. **Mahanty SD, Roemer RB.** "Thermal Response of Skin to Application of Localized Pressure." *Archives of Physical Medicine and Rehabilitation.* 1979; 60: 584-90.
12. **McPoil TG, Cornwall MW.** "Effect of Insole Material on Force and Plantar Pressures During Walking." *Journal of the American Podiatric Medical Association.* 1992 Aug; 82(8): 412-16.
13. **Sanders JE.** "Thermal Response of Skin to Cyclic Pressure and Pressure with Shear: A Technical Note." *Journal of Rehabilitation Research and Development.* 2000 Sep; 37(5): 511-15.
14. **Sanders JE**, et al. "Material Properties of Commonly-Used Interface Materials and Their Static Coefficients of Friction with Skin and Socks." *Journal of Rehabilitation Research and Development.* 1998 Jun; 35(2):161-76.

PATIENT AND PARENT PERSPECTIVES ON TREATMENT FOR ADOLESCENT IDIOPATHIC SCOLIOSIS

Melanie J. Donnelly, M.D.*, Lori A. Dolan, Ph.D. (C)^; Linda Grande, B.S.N.+, Stuart L. Weinstein, M.D.^

INTRODUCTION

There is little doubt that long-term, untreated adolescent idiopathic scoliosis (AIS) can cause significant cosmetic deformity. However, researchers do not agree on the psychosocial effects of deformity, or on the diagnoses and treatments themselves. Previous studies have reported little evidence for psychosocial dysfunction due to scoliosis, while others have found that AIS can cause serious disturbances in body image and other indicants of mental health and adjustment.[1-4] These studies have mainly been retrospective, and each study has used different instruments to measure psychological parameters and adherence. Based on the data from these studies it can be concluded that bracing may cause some psychological stress to the patient, at least at the initiation of treatment and possibly long-term. Orthopedists, however, still consider bracing to be a benign treatment that is not invasive or necessarily disruptive. Possible stress resulting from brace treatment needs to be considered in the decision-to-treat equation, and the benefits of bracing must outweigh the risk of adverse psychosocial sequelae.

There is conflicting information about the potential for long-term psychosocial sequelae associated with either bracing or surgery. MacLean et al.[3] examined this issue and discovered that there is a significant period of stress and self-esteem change at the initiation of brace-wear in the majority of patients (88%). They found "no evidence of overt psychopathology" but did describe some of the issues patients face with brace wear such as soreness, discomfort with activity, and torn clothing.

The treatment decision process is likely to have a substantial impact on adherence to bracing regimen. Once the brace is delivered, treatment compliance is completely in the hands of the patient, thus "buy-in" is necessary. Angst and Deatrick[5] explored the decision to undergo surgery for AIS by 8 patients and parents. They found children are involved in decisions surrounding the possibility of surgery and that some families make decisions based on cues predominantly from their physician. This process has not been explored among patients undergoing brace treatment. Difficulties with brace wear were also reported by Vandal et al.,[6] including problems with decreased mobility, altered physical appearance, clothing choices, and family/personal relationships.

DiRaimondo[7] estimated that patients wore their braces 65% of the instructed time. Two families experienced "profound family strife . . . due in part to conflicts over brace compliance." Vandal et al.[6] used a "compliometer" to measure adherence with brace wear schedules and found that patients significantly over-reported the number of hours they wore their brace. Patients reported wearing the brace 88% of the prescribed time, compared to the 33% tracked by the monitor. A more recent report confirms this discrepancy. Takemitsu et al.[8] found that patient-reported compliance is higher than that logged by a temperature monitor (85% versus 75%). They also observed that compliance decreases with the age of the patient, and that compliance is highest with shorter-wear prescriptions (e.g., 8 hours versus 12, 16 or 23 hours per day).

Taken as a whole, the current literature suggests that treatment decisions and compliance with these decisions is not an easy process for patients and families. This study used qualitative methods to explore issues surrounding AIS treatment (surgery and bracing) among a sample of current patients and parents, from their point of view. Qualitative methods are an ideal way to discover patient perspectives surrounding disease and treatment. These methods encourage patient participation in the process and offer an open-ended format for discussion. Subsequently, issues that may have otherwise been ignored can be discovered.[9,10] This is especially true in adolescent research since survey responses are typically created by adults, making it likely that topics important to the patient are overlooked. Therefore, the objectives of this study were carried out using the focus group method with patients, and group interviews with their parents. Focus group methods have been endorsed as an especially effective research tool when working with children between the ages of

*Dartmouth-Hitchcock Medical Center
Hanover, New Hampshire

^University of Iowa
Department of Orthopaedics and Rehabilitation
Iowa City, Iowa

+University of Iowa
College of Nursing
Iowa City, Iowa

11 and 14. Children in that age group are more relaxed within a group setting and more likely to share among a group of peers than one-on-one with a stranger.[11]

This study will examine, through qualitative methods, issues surrounding AIS treatment (surgery and bracing) among a sample of patients and parents that are currently undergoing or have recently undergone treatment. The purpose of this study is to explore three aspects of treatment for adolescent idiopathic scoliosis (AIS) from the perspective of the patient and family. Discussions centered on three core areas: 1) The decision process when choosing a treatment, 2) The impact of the treatment on daily living, and 3) Ease or difficulty in compliance with recommendations.

METHODS

Sample

The human subjects research review committee approved this study. The sample was recruited from the practice of an orthopedic surgeon practicing at a tertiary referral center, and was identified through a departmental database. Inclusion criteria included: Diagnosis of AIS, age between twelve and eighteen, treatment and follow-up in our institution, and female gender. Invitations to enroll in the study were sent to all patients meeting the above criteria (n=110). Replies were received from 18 patients and their parents expressing interest in participating. They were called and a discussion of the study took place over the phone to insure that patients and parents understood the study. After agreeing to participate, further information was mailed. A follow-up phone call was placed to the family the week of the study to again remind them of the time and place for the study.

Focus Groups and Interviews

As stated, qualitative methods are an ideal way to discover patient perspectives on a disease or particular issues surrounding a disease. These methods encourage patient participation in the process and offer an open-ended format for disucussion. Subsequently, issues that may have otherwise been ignored can be discovered.[9,10] This is especially true for adolescents since survey responses are typically created by adults for teens and children, making it even more likely that important topics are overlooked. Therefore, the objectives of this study were carried out using the focus group method (with patients) and group interviews (with parents of AIS patients). Focus group methods have been endorsed as an especially effective research tool when working with children between the ages of 11 and 14. Children in that age group are more relaxed in a group setting and more likely to share among a group of peers than one-on-one with a stranger.[11]

TABLE 1
Characteristics of the Sample

Patient	Treatment	Age	Years brace wear OR years since surgery	Age of oldest parent in attendance	Education level of parent
1	Brace	14	3	43	Some college
2	Brace	14	3	41	College grad
3	Brace	13	1.5	43	Some college
4	Brace	13	1	42	College grad
5	Brace	14	3	48	College grad
6	Brace	16	4	n/a	n/a
7	Brace	17	6	45	High school grad
8	Brace and Surgery	15	3/1.5	51	College grad
9	Brace and Surgery	18	2/3	n/a	n/a
10	Surgery	15	2	n/a	n/a
11	Surgery	16	1.5	n/a	n/a
12	Surgery	15	3	51	College grad

Informed consent was obtained from both parent and patient, and confidentiality and anonymity were assured. Focus groups were held with the patients, with the exception of one patient with whom an individual interview was conducted. That patient and parent data for that individual were dropped from the analysis because of the difference in data collection methods. Therefore, a total of 12 patients participated in the focus groups. Focus groups were moderated by the first author, who has undergone formal training in focus-group methods. The assistant moderator monitored the audiotaping, took extensive notes, and observed the participants and moderator. Methods for moderating the group and data collection were based on the methods of Krueger and Morgan.[12]

Two focus groups of approximately one hour each were conducted around tables in rooms with minimal distractions. The first focus group was comprised of five younger patients in the beginning or middle of their brace treatment; the seven patients in Group 2 were nearing the end of bracing treatment, or had undergone surgery. A topic guide with semi-structured questions was used. Topics included the decision-making process for treatment; perceived effectiveness of the intervention (parents only); impact of treatment on daily life; and difficulties encountered when following treatment. Probes were guided by the discussions and responses in each group.

TABLE 2
Ice Breaker Response: "What do you think are the best and worst things about your treatment?"

Group number and treatment	Best part of treatment	Worst part of treatment
Brace	"Not having surgery" and being able to play sports	Brace is uncomfortable and "taking it on and off at school"
Brace	"Not having surgery"	"my friends don't have it and its hard when people ask what it is"
Brace	"It is helping my back and I don't have to get metal locks in my back"	"very uncomfortable" "looks weird"
Brace	Helps my back a lot	"can't do much in it"
Brace	"If I wear it I won't have to have the surgery most likely"	"I can't find great clothes with it"
Brace	"Helps back when it's really hurting, a little"	Had to wear it during day so didn't leave house after school
Brace	"My back feels better"	"getting made fun of" "hard emotionally"
Brace and Surgery	Not needing to wear brace anymore	"missing school"
Brace and Surgery	Not in pain after surgery	Limitations on sports right after surgery
Surgery	"I did not even realize I had scoliosis before so . . . I can't say this really helped me out"	Surgery experience was "hard"
Surgery	"Getting better"	"being put to sleep"

Group interviews were conducted with the parents, separately from the patients. Interviews were conducted by two registered nurses with experience in pediatrics. Interviews took approximately one hour each. A total of ten parents (eight mothers, two fathers) of eight girls participated.

Post-focus group and post-interview surveys were sent out so participants could comment on their experience during the study.

Data Analysis

Focus groups and interviews were audiotaped and transcribed. The transcripts were compared with notes taken to insure accurate transcription. The transcripts were then coded using content analysis techniques. Content not relevant to the questions being studied were not included in the analysis.

RESULTS

Participants

Table 1 lists the participants of the focus groups and interviews and some of their demographic characteristics. All patients and parents were Caucasian and lived in the Midwest.

As an icebreaker for each focus group, participants were asked to describe the best and worst things about their treatments for AIS. These results are presented in Table 2.

DECISION MAKING

Braced Patients and Parents

Quotations in Table 3 reflect the patients' and parents' perceptions that the patient has little say in their treatment decision for bracing. Parents felt it was incumbent upon them to choose the least invasive method of treatment first, and in their minds, that was the brace.

". . . obviously we preferred the noninvasive treatment. . . ."

". . . the brace was really, you know, a necessity and so we went ahead and proceeded from that point. . . . We follow the doctor's recommendation on what to do . . . We more or less trusted the doctor to do the right thing . . . "

". . . it's not like we were saying 'do you want to wear this?' I mean it was a necessity. This is what we are going to do. I don't think my daughter had a lot of input."

The results also revealed the misconceptions Group 1 had regarding the surgery for AIS. Parents felt that bracing was the only option for their child and believed it was a necessity for their health. They believed they should follow the doctor's recommendation. One parent believed that they were able to give their daughter some choice by allowing her to choose which 16 hours a day she would wear the brace.

For parents who had chosen a brace for their child, went through years of bracing treatment, and found that their daughters still needed surgery, there was a strong sense of disappointment:

"I think she knew she had to wear it. There were some days we fought over it. There were tears going

TABLE 3
Quotations Concerning the Decision-Making Process

Group	Quotation
Patients	"I would say since I was so young my mom basically decided for me."
	"I chose the brace over the surgery because they made it sound bad."
	"I wanted surgery because I wasn't thinking straight and I just thought it would be a lot easier. . . .they told me about how an 8 year old boy who had the surgery was playing soccer, and he fell over, and the rods came out of his back. I just didn't want to think about that . . . I did not want to deal with that because I know at some point in your life they would probably come out of your back. . . "
	"It [rod] attracts lightning, and it's like, no, I'm not doing that."
	". . . they just said you have to have surgery. We did not really have a choice but it was fine with me."
Parents	". . . .the brace was really, you know, a necessity and so we went ahead and proceeded from that point . . . we follow the doctor's recommendation on what to do. . . we more or less trusted the doctor to do the right thing. . . "
	". . . it's not like we were saying 'do you want to wear this?' I mean it was a necessity. This is what we are going to do. I don't think my daughter had a lot of input."
	". . . obviously we preferred the noninvasive treatment . . . "

out to the car to be driven to school. To be honest, I wish now I would have said 'just sling that in the back seat and let's go.' I mean, the outcome having to be surgery anyway, I wish I hadn't been so 'you have to wear it'. . . ."

SURGERY PATIENTS

Patients who had surgery as either primary treatment or following bracing felt that they had no other option based on the degree of their curve and potential for improvement. One patient felt that she had a lot of say in her treatment and made an informed decision to undergo surgery with her mother. She used the Internet to gather information and then decided that she had to undergo surgery to get better.

ANTICIPATED EFFECTIVENESS OF BRACE

Most parents understood that the evidence for bracing in AIS was inconclusive; however, they felt compelled to try the treatment because of its noninvasive nature. They also figured that since they would have to wait for surgery until their daughter was finished growing that they may as well try something in the interim.

" I heard it might work, it might not work. It could stay the same, it could get worse."

TABLE 4
Quotations Concerning the Effect of Treatment on Life

Group	Quotation
Patients	"I could not wear the clothes that I wanted, like, I could not wear tighter stuff. You know it had to be really baggy. I hated that."
	"My mom and I would fight about it [brace] sometimes. She would say you need to wear that. It is very important, and I would just be like, well, you never had to wear it. You don't know what it is like. So, we would fight a lot."
	"If you're one of those people who is self-conscious about your weight or something, and then you add the brace on, you feel like you are 200 pounds or something. It makes you feel fatter."
	"You don't want to wear it to the mall and to a movie, its just like I'm not wearing it."
	"People always feel sorry for me . . . "
	". . . school desks are so uncomfortable to sit at in a brace."
	"The school lunchroom tables that have the benches, those are the hardest thing to get in . . . with a skirt on you have to throw your leg over . . . or walk to the end of the table and then slide over, it is really funny."
	". . . people I did not know would come up and like knock on it and like make little jokes about it."
	"They treat you like, are you sure you can do this: Do you need help carrying that. And it is just kind of annoying."
Parents	"Even though she wanted to wear it, there were still those daily fights."
	"Oh, we had a lot of tears. I would always kind of joke 'well you got to put your turtle shell on'"
	"Oh, she cried and cried and cried. When we came here for the first time she cried and stopped when the doctor came in, but as soon as he walked out the door she burst into tears again . . . She did not want her friends to know she was wearing the brace . . ."
	"Then when she went to get casted, that was a surprise for her but she handled it like a trooper . . ."
	". . . but I think the most difficult time we had was when she was being fitted for the brace. . . she had been laughing and joking and all of the sudden she was just in tears . . . it was a horrible moment there that we did not know . . ."
	"They want to wear clothes like their friends, and with the brace they cannot do that."

"Why wait all those years [until surgery] when the brace might work?"

Parents and patients also were confused by the difference in effectiveness presented by the doctor and the orthotics company. That was especially difficult since, often times, patients spend more time with the orthotists than the doctor.

"You get a very conservative opinion from the doctor . . . and there are no promises given. . . . Then you

got a prosthetic company and they say if you wear the brace like you are supposed to there is a 98% success rate with it. . . . I think that is overly optimistic . . . "

EFFECT ON LIFE

Braced Patients

Patients also reported that they fought a lot with their parents over wearing the brace, as evidenced by some of the quotes in Table 4. Patients also felt self-conscious wearing their brace. They thought others might be talking about their brace, and they reported that fellow students treated them differently:

"People always feel sorry for me . . . "

". . . school desks are so uncomfortable to sit at in a brace."

"The school lunchroom tables that have the benches, those are the hardest thing to get in. . . .with a skirt on you have to throw your leg over . . . or walk to the end of the table and then slide over, it is really funny."

". . . people I did not know would come up and like knock on it and like make little jokes about it."

Most patients in the focus groups report that they were able to participate in sports and just remove the brace. Two participants, however, were not able to continue their activities because they felt they couldn't go without the brace during those time periods and couldn't play their respective sports with the brace on.

SURGERY PATIENTS

For the year following surgery, patients felt they had many limitations on their activities, although they also felt they had been well informed about these limitations and expected them. However, after that year most patients felt that very little of their life was impacted by their surgery. Some patients felt that people still treated them differently because of the surgery.

PARENTS

Almost every parent brought up fights over brace-wear. There were many arguments and tears shed over when and where their daughters were to wear the brace. Finding clothing to fit was another difficulty parents had with their child.

Parents had mixed views on how the brace affected their child's activity level. That seemed to be more patient dependent. Some said their girls maintained their previous level of activity, whereas others felt that their child became more sedentary because they did not want to be seen in public with their brace or couldn't perform activities in their brace.

Regarding sleeping in the brace, parents felt that their daughters had difficulty sleeping in a brace at first, but that eventually their daughters overcame that discomfort. One parent talks about how they dealt with that issue:

"It was awful the first week. . . but we bought a feather bed and she did that for awhile and she has transitioned out of that now."

Parents also report that the fitting of the brace for their daughters was more involved and traumatic than they or their child expected.

"Then when she went to get cast, that was a surprise for her but she handled it like a trooper. . . "

". . . but I think the most difficult time we had was when she was being fitted for the brace. . . she had been laughing and joking and all of the sudden she was just in tears. . . it was a horrible moment there that we did not know. . . "

The parents of patients who had undergone surgery as a treatment commented on the difficult and long recovery from surgery. They hired tutors for their child and usually took a few weeks off work to help their daughters at home.

COMPLIANCE-BRACED PATIENTS ONLY

Table 5 lists quotes on compliance from braced patients and their parents. Patients reported difficulty adhering to the recommended brace-wear schedule. The focus group of younger patients (12 and 13 years) reported conflicting information. When asked outright about their compliance with brace wear most reported that they were able to wear their brace the recommended 16 to 18 hours each day. However, upon further discussion it became clear that they were having much difficulty complying:

"You just tell them [doctor] what they want to hear . . . I would lie . . . Of course I am wearing it 18 hours a day."

One girl reported that she does not have weekend breaks and must strictly follow the 16-18 hour rule.

"I'm not allowed to take it off unless I'm bleeding. It's just when you take it off early it's very hard to make up the hours."

Although not a practical solution, most patients would feel better about their brace if others in their schools or friends were wearing a brace. They felt that would make it easier for them to comply with the recommended hours of treatment with a brace.

PARENTS

Parents had a lot to say about the difficulty of getting their children to comply with 16 to 18 hours of brace wear each day. Parents reported that they often compromised with their child and ended up with less than the desirable number of hours of brace wear a day. Two parents felt that their daughters were extremely compliant with the recommended hours of wear.

TABLE 5
Quotations Concerning Brace Wear Compliance

Group	Quotation
Patients	"Over the weekend I usually don't wear it because that's like my time off, so my mom doesn't really get on me about it . . . they know I'm going through a lot of pain . . . "
	"On the weekends I probably wear it 2 hours a day because it hurts and you wanna have fun with your friends on the weekend."
	". . . be able to do everything everybody else is doing . . . "
	"I put the brace on to go to school and take it off at school and put it in my locker until the end of the day. I just hated wearing it."
	"Last year they said you can wear it at night now. My mom says you are going to have to come upstairs and show me that you are wearing it to bed. It was just really stupid because I would go up, show her, go down, and take it off . . . I sleep in the basement so nobody knows. So, I am like, not wearing it."
	"I mostly wore it for the first 2 years but then I would take it off at night and hide it in my closet. No one would know that I was not wearing it. But I always had to wear it to school and she would be able to tell if I was not wearing it . . . but after awhile I was just like that is enough. You know, they cannot really do anything to me if I do not wear it. So then I just did not and I had surgery . . . That was not so bad."
	"You just tell them [doctor] what they want to hear . . . I would lie . . . Of course I am wearing it 18 hours a day."
	"I tried hard to get her to wear it for 16 hours a day. I think the best we could get was 14-15 hours a day . . . it is only going to be about 12 to 14 hours a day if we can really push it."
	"I'm wearing it because if I didn't wear it and I refused to have the surgery I would be one of those people with a humped back."
Parents	"She is in a stage right now where it is difficult to get her to wear the brace. She functions fine without it . . . now she had agreed to wear it anytime but at school. However, more often than not we check on her in the early morning and it is laying on the floor in the room . . . so I do not really think she is wearing it more than 6 hours a day."

"She does wear it. She was wearing it 24 hours a day and now she is down to 18, but she does wear it most of the time."

"I think my daughter is one of those rare obedient kids . . . so we really didn't battle with it too much."

DISCUSSION

Bracing appears to involve a relatively simple decision for most families. Generally, the patient has little input into the decision, and the parents follow the physician's recommendation to use the brace. In this decision, it is the physician's presentation of the options that primarily dictates the parents' decision. While parents who chose surgery report weighing the risks of the treatment, parents who chose bracing believed bracing is a noninvasive treatment with no perceived associated risks.

Adolescence is a time when children are developmentally preparing to become adults. Eliason and Richman[2] describe the developmental tasks of adolescence and how they believe these are affected by scoliosis and treatment for scoliosis. They point out that adolescents seek independence from adults and peer conformity. These tasks are interrupted as the adolescent is "forced to extend (their) period of dependence on parents and physicians for medical care" and as they rebel via nonadherence to their treatment regimen. Patients with AIS should be included in all treatment decisions in a meaningful way in order to endorse the development of autonomy and independence of the adolescent, and to allow the patient a chance to "buy-in" to their treatment. If the patient is not as committed to the treatment as the parent, the result is much time, money, and effort spent on a treatment that is doomed to failure. Adolescent patients with Type I diabetes face similar issues when dealing with treatment for their disease. Interviews with adolescent diabetics demonstrated that motivating actions included the physician discussing the treatment with the patient and including them in planning their self-care regimen.[13] For braced patients, this means setting brace schedules with the doctor or nurse and balancing the needs of the patient with the necessity of the treatment. To accomplish that goal, Litt and Cuskey[14] suggest creating a contract between patient and physician. This contract would outline the goals of therapy and require each party to change their behavior in some way, or to modify the treatment schedule in some way. For example, the patient could agree to wear the brace overnight and for X number of hours during school all week in exchange for one night and morning off for a sleepover or other special activity.

Although the patients in the bracing group did not perceive much voice in treatment decisions, the acceptability of the brace was enhanced by patients' understanding and misunderstanding of the potential surgery. It is clear from these focus groups that the girls who

were braced, especially the young ones, have a distorted view of surgery for AIS. It is not clear where they were exposed to these stories, but what is clear is that their fear of potential surgery was reinforced over and over again. Since conservative estimates place brace failure rates at 30%,[15] it can be anticipated that some of these girls will need surgery one day. At that time these fears will become an issue. One way to deal with this problem is for the physician and nurse to address the issue of surgery at the same time they discuss the brace. This would allow patients to be exposed to the realities of treatment options from a reliable source at the initiation of treatment. It also provides an opportunity for patients to ask any questions they have about the treatments and discuss rumors they have heard about the surgery.

While the psychosocial effects of bracing may not be pathological, clearly these girls felt the brace greatly influenced their lives. Previous studies have found the initial period of brace wear is stressful. Common stressors reported have included soreness, difficulty breathing and eating and moving in the brace, torn clothing and sheets, discomfort with sitting or undertaking physical activity, difficulty finding clothes, and difficulties in relationships with others.[3,6] One study estimated that activities such as school attendance, sleepovers, and sports participation affected almost half of patients wearing a brace.[3] The conflicts discussed by patients and parents regarding brace wear were significant to them. There are pressures among peers to conform and pressures from parents to wear a brace and thus be different. Yet we know that during this time in development it is important for adolescents to develop independence from parents and gain conformity with their peer group.[2] These developmental tasks present clear challenges to the issues which arise when bracing is prescribed. These girls are feeling singled out not just because of their illness but also because of their outward appearance.

Although specific schedules of brace wear were not elicited from the group, it was apparent that there is inconsistent adherence to brace-wear schedules. This finding is in agreement with past studies that have found low adherence to recommended brace-wear schedules.[6-8] Weekend breaks are common. In fact, only two of the girls wore their braces to the weekend focus group session. Weekend breaks are a chance for the girls to go out with friends and be like everybody else. The difficulties with adhering to the brace schedule seemed to be most related to the way the brace impacts their lives. Girls cited many reasons for not wearing the brace and all of them had to do with comfort, fitting in with their peers, and activities.

Making the brace more acceptable to peers was accomplished by one patient when her science teacher made the issue of AIS a science unit. This type of intervention may improve peer "silent support," which includes things such as peers changing their behavior patterns to match the patient's lifestyle and thereby adapting the same limitations. Once classmates understand the disease and treatment, they may also be more likely to encourage the patient in self-care. This encouragement may have a significant impact on adherence.[13] Patients reported they would like to have someone else in their class with a brace so that they wouldn't be the only one. Parents and patients spoke about how useful they believed a support group would be for AIS families. The involvement in support groups has been identified as an effective strategy to improve adherence to long-term treatments.[16] One patient and parent felt that viewing the disfiguring consequences of curve progression would improve adherence. However, this strategy is not appropriate or effective as it depends upon the patient's level of fear and their coping mechanisms. It has been shown that high levels of "fear arousal" are actually counterproductive.[14] Linking severe disfigurement with non-adherence is also not ethical due to difficulty predicting the degree of future deformity for individual patients.

Many parents believed that raising brace wear requirements to 24 hours per day, seven days a week, would improve compliance by their children. They believed this schedule would simplify their job and eliminate the bargaining that they do with their children over when and where to wear the brace. One parent felt that prescribing the brace for 24 hours a day was the only way his child would end up wearing the brace 16 to 18 hours a day. However, the patients felt that 24 hours per day was an unachievable goal. It has been shown that the simpler the long-term treatment regimen, the more likely patients are to adhere to the regimen [16], however it is difficult to predict how compatible that type of schedule would be with a normal adolescent lifestyle.

The sample for this study was a convenience sample comprised of consenting patients and parents. The study likely attracted a group of motivated patients who have had good experiences with their healthcare. They also may have been those who were seeking out other families to share their experiences with regarding scoliosis. Therefore, these results and discussion may not be generalizable to the larger population of patients and parents. Furthermore, little identifying information was collected regarding the sample and no effort was made to connect patient and parent data.

The focus group and interview methods are ideal for the exploratory purpose of this study. This study's strengths were the words of its participants. These words provide the foundation for the next level of investigation into this area. Content analysis of these discussions suggestions several specific research questions. First, what is the relationship between knowledge of AIS, its natural history, research and patient experiences with treatment and the consequent decision to accept bracing? Addressing this question could involve randomizing families to an arm where they received extensive education and time outside the clinic to make a decision, or to an arm resembling the typical setting where the physician generally discusses the situation with the family and they immediately make a decision. A second question suggested by this work involves the relationship between the degree of decision control perceived by the patient and its impact on subsequent compliance and satisfaction with treatment. Degree of control and satisfaction could be measured using a simple questionnaire, and compliance measured through the use of an embedded electronic monitor. Family stress, satisfaction and brace compliance could also be assessed as a function of brace wear schedule. True wear time could be measured for patients who were assigned to 24-hour-per-day schedules compared to those under shorter prescriptions. It could be that a 24-hour schedule decreases stress and increases satisfaction, while at the same time resulting in longer actual wear time despite non-compliance than with a shorter schedule.

ACKNOWLEDGMENTS

Support for this study was received by The Doris Duke Foundation and Childrens' Miracle Network. Dr. Toni Tripp-Reimer provided guidance with the design and analysis portions of this study. Dorothy Doolittle provided help with group interviews.

REFERENCES

1. **Clayson, D.; Luz-Alterman, S.; Cataletto, M. M.; and Levine, D. B.:** Long-term psychological sequelae of surgically versus nonsurgically treated scoliosis. *Spine,* 12(10): 983-6, 1987.
2. **Eliason, M. J., and Richman, L. C.:** Psychological effects of idiopathic adolescent scoliosis. *Dev Behav Pediatr,* 5(4): 169-172, 1984.
3. **MacLean, W. E., Jr.; Green, N. E.; Pierre, C. B.; and Ray, D. C.:** Stress and coping with scoliosis: psychological effects on adolescents and their families. *Journal of Pediatric Orthopedics,* 9(3): 257-61, 1989.
4. **Noonan, K. J.; Dolan, L. A.; Jacobson, W. C.; and Weinstein, S. L.:** Long-term psychosocial characteristics of patients treated for idiopathic scoliosis. *Journal of Pediatric Orthopedics,* 17(6): 712-7, 1997.
5. **Angst, D. B., and Deatrick, J. A.:** Involvement in health care decisions: Parents and children with chronic illness. *Journal of Family Nursing,* 2: 174-187, 1996.
6. **Vandal, S.; Rivard, C. H.; and Bradet, R.:** Measuring the compliance behavior of adolescents wearing orthopedic braces. *Issues in Comprehensive Pediatric Nursing,* 22(2-3): 59-73, 1999.
7. **DiRaimondo, C. V., and Green, N. E.:** Brace-wear compliance in patients with adolescent idiopathic scoliosis. *Journal of Pediatric Orthopedics,* 8(2): 143-6, 1988.
8. **Takemitsu, M.; Rahman, T.; Bowen, J. R.; and Scott, C. B.:** Brace treatment compliance for patients with idiopathic scoliosis. In *Pediatric Orthopaedic Society of North America*. Edited, Amelia Island, FL, 2003.
9. **Cossrow, N. H. F.; Jefferey, R. W.; and McGuire, M. T.:** Understanding weight stigmatization: a focus group study. *Journal of Nutrition Education,* 33: 208-214, 2001.
10. **Ginsburg, K. R.; Slap, G. B.; Cnaan, A.; Forke, C. M.; Balsley, C. M.; and Rouselle, D. M.:** Adolescents' perceptions of factors affecting their decisions to seek health care. *JAMA,* 24: 1913-1918, 1995.
11. **Horner, S. D.:** Using focus group methods with middle school children. *Research in Nursing and Health,* 23: 510-517, 2000.
12. **Krueger, R., and Morgan, D.:** Focus Group Kit. Edited, Newbury Park, Sage Publications, 1998.
13. **Kyngas, H.; Hentinen, M.; and Barlow, J. H.:** Adolescents' perceptions of physicians, nurses, parents and friends: Help or hindrance in compliance with diabetes self-care? *J Advanced Nursing,* 27: 760-769, 1998.
14. **Litt, I. F., and Cuskey, W. R.:** Compliance with medical regimens during adolescence. *Pediatric Clinics of North America,* 9: 257-261, 1980.
15. **Goldberg, C. J.; Dowling, F. E.; Hall, J. E.; and Emans, J. B.:** A statistical comparison between natural history of idiopathic scoliosis and brace treatment in skeletally immature adolescent girls. *Spine,* 18(7): 902-8, 1993.
16. **Haynes, R. B.; McDonald, H. P.; and Garg, A. X.:** Helping patients follow prescribed treatment. *JAMA,* 24: 1913-1918, 2002.

AUTOSOMAL DOMINANT TRANSMISSION OF ACCESSORY NAVICULAR

Matthew B. Dobbs, M.D.*#+
Tim Walton, R.N., B.S.N.*#

ABSTRACT

The accessory navicular bone is one of the most symptomatic bones of the foot. Although it has been reported to be present in various members of the same family, there is a lack of knowledge about its inheritance pattern. We report two large pedigrees in which accessory navicular is inherited in an autosomal dominant fashion with incomplete penetrance.

INTRODUCTION

Accessory navicular is a separate ossification center for the tuberosity of the navicular that is present in approximately 5 to 14% of the general population.[2,8] The accessory navicular produces a firm prominence on the plantar-medial aspect of the midfoot. There may be a coexistent flexible flatfoot[7], but there is no conclusive evidence of a cause-and-effect relationship between the two conditions. Individuals with an accessory navicular may present for evaluation because of the prominence, but more commonly they present because of pain at the site. The accessory navicular has been classified into three types.[3] Type I is a rarely symptomatic, pea-sized sesamoid bone located within the distal portion of the posterior tibial tendon; type II, the most frequently symptomatic type, is an accessory bone united to the navicular by a syndesmosis or synchondrosis; and type III is a large accessory bone that results from fusion of a type II with the body of the navicular.

The inheritance of accessory navicular was first reported to occur in an autosomal dominant fashion by McKusick[6], but there was no published data at that time to support this claim. More recently, Kiter et al.[4] described the inheritance of accessory navicular in three families to occur in an autosomal dominant pattern with incomplete penetrance. The ethnicity of these families was not reported. We describe vertical transmission of accessory navicular in two families and confirm that autosomal dominant inheritance should be considered in the differential diagnosis of accessory navicular.

MATERIALS AND METHODS

A retrospective review was conducted for the years 1980 to 2003 to identify patients treated surgically for a painful accessory navicular at Saint Louis Shriners Hospital for Children and Saint Louis Children's Hospital. Institutional Review Board approval was obtained for the retrospective chart review. A total of 123 patients with 164 painful accessory navicular bones met the inclusion criteria. Charts were reviewed for documentation of the presence of an accessory navicular. A total of 60 patients were contacted by phone to obtain information regarding whether any first-degree relatives were also affected with a painful accessory navicular.

RESULTS

Of the 60 patients we were able to contact by phone, 20 reported that at least one first-degree relative had the diagnosis of an accessory navicular. An additional 20 patients reported other family members that were treated for foot pain, but they were uncertain of a diagnosis. We were able to examine clinically and radiographically 19 and 12 members of two separate families and found accessory navicular in 10 and 4 members respectively. All had type II accessory navicular. Their ages ranged from 10-74 years (mean, 32.4 years).

The pedigrees of the families were consistent with an autosomal dominant inheritance pattern with incomplete penetrance (Figure 1).

DISCUSSION

Accessory navicular is one of the most symptomatic accessory bones of the human skeleton. Though it has been observed in multiple family members, data are lacking about the mode of its inheritance. The first re-

Study conducted at Washington University School of Medicine, St. Louis Children's Hospital, and St. Louis Shriners Hospital for Children, St. Louis, Missouri, U.S.A.

Address correspondence and reprint requests to:
Matthew B. Dobbs, M.D.
St. Louis Children's Hospital
Washington University School of Medicine
Department of Orthopaedic Surgery
One Children's Place, Suite 4S20
St. Louis, MO 63110
Phone: 314 454-4814
Fax: 775 593-4760
E-mail: mattdobbs@earthlink.net

From: Washington University School of Medicine, # Department of Orthopaedic Surgery, St. Louis, Missouri, U.S.A.; St. Louis Children's Hospital*, St. Louis, Missouri, U.S.A.; + St. Louis Shriners Hospital for Children, St. Louis, Missouri, U.S.A.

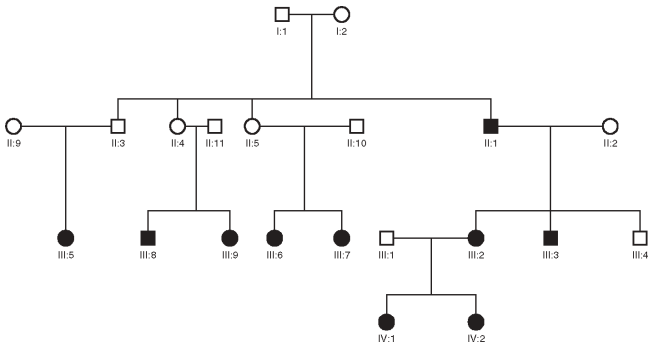

Figure 1. Pedigree of the first family demonstrating autosomal dominant transmission of accessory navicular with incomplete penetrance.

port in the literature demonstrated an autosomal recessive pattern, based on only one family pedigree.[1] Macnicol et al.[5] reported accessory navicular in three members of the same family, but they did not speculate on an inheritance pattern. McKusick found the inheritance to be autosomal dominant, without referring to any family studies.[6] Finally, Kiter et al.[4] reported on the autosomal dominant transmission of accessory navicular with incomplete penetrance based on three pedigrees, one with three generation involvement.

Based on our report of vertical transmission of accessory navicular in two large pedigrees of Scandinavian descent (Figure 1) and the findings of Kiter et al.[4], we support the theory that accessory navicular can be transmitted as an autosomal dominant trait with incomplete penetrance. In all patients with accessory navicular, a family history should be obtained to look for affected family members. Appropriate counseling should be provided to families in regards to the inheritance pattern.

Since this disorder follows a Mendelian inheritance pattern, it is likely that a single gene is responsible; this makes a search for this gene an attractive proposition. We are currently performing a genome-wide scan to localize the gene for this disorder. Once chromosomal localization is made, candidate genes will be identified in that area based on their known or probable role in limb development. Mutational analysis studies will then be performed on these chosen genes in the hopes of identifying the one responsible for this disorder.

BIBLIOGRAPHY

1. **Cobey MC, Cobey JC.** A true prehallux. *J Bone Joint Surg Am*. 1966;48:953-954.
2. **Geist E.** The accessory scaphoid bone. *J Bone Joint Surg Am*. 1925;7:570-574.
3. **Grogan DP, Gasser SI, Ogden JA.** The painful accessory navicular: a clinical and histopathological study. *Foot Ankle*. 1989;10:164-169.
4. **Kiter E, Erduran M, Gunal I.** Inheritance of the accessory navicular bone. *Arch Orthop Trauma Surg*. 2000;120:582-583.
5. **Macnicol MF, Voutsinas S.** Surgical treatment of the symptomatic accessory navicular. *J Bone Joint Surg Br*. 1984;66:218-226.
6. **McKusick VA:** *Mendelian inheritance in man*, The John Hopkins University Press., 1994
7. **Ray S, Goldberg VM.** Surgical treatment of the accessory navicular. *Clin Orthop*. 1983:61-66.
8. **Shands AJ, Wentz I.** Congenital anomalies, accessory bones and osteochondritis in the feet of 850 children. *Surg Clin North Am*. 1953;33:1643-1648.

SURGICAL TREATMENT OF SOLITARY PLASMOCYTOMA OF THE SPINE: CASE SERIES

Sergio Mendoza, M.D.,* Julio Urrutia, M.D.,† Dennis Fuentes, M.D.†

ABSTRACT

The mean survival of patients with skeletal solitary plasmocytoma is 75% at 5-year follow-up.[2] This highly osteolytic tumor may compromise spinal stability. Radiotherapy is effective in local control of the disease, however, it is not effective in restoring spinal stability. Fracture risk and progressive vertebral collapse persist. For this reason, we must consider the need to establish the probability of progressive vertebral collapse, based on the degree of involvement of the vertebral body at the time of diagnosis. We used parameters described by Taneishi and Kaneda, as well as those of Heller and Boden to predict progressive vertebral collapse.[4] Three cases are presented and their treatment is described.

INTRODUCTION

Solitary plasmocytoma (SP) of bone is a localized plasma-cell tumor that comprises 5% of all malignant plasma-cell tumors. Of these, 69% are osseous and the remaining 31% are extra-medullary, involving soft tissue. In SP of bone, the most frequent location is the spine (68.5%).[1]

Diagnosis

Diagnosis is obtained by a combination of several elements. Keys to diagnosis are a histological demonstration of plasma-cell tumor by bone biopsy, and the demonstration of a monostotic location. To rule out systemic tumor involvement, a bone marrow aspirate must be performed in both sternal and iliac locations. Laboratory work-up should include white blood cell count and differential, erythrocyte sedimentation rate (ESR), serum calcium level, serum alkaline phosphatase isoenzymes, serum creatinine, serum protein electrophoresis and urinalysis with Bence-Jones protein inspection.

Imaging studies should include CT scan of the chest, abdomen and pelvis to search for primary or secondary tumor locations (metastases). An MRI of the affected vertebra is important to determine the degree of tumoral compromise of the vertebra, and to quantify vertebral canal occupancy and spinal cord compression by neoplastic tissue. A CT scan of the affected vertebra demonstrates the degree of architectural compromise, as well as the presence of any bone fragments occupying the spinal canal. Technetium-99 bone scanning is also useful, but this may be positive only after a pathological fracture. Pathologic fracture is highly probable if the patient complains of pain on initial consultation.

The mean delay for diagnosis is one year. The chief complaint upon presentation is pain, which is secondary to neoplastic infiltration and/or structural loss and instability. Most cases of SP are purely osteolytic lesions. In the Delauche-Cavallier[2] series, 71% of patients had symptoms secondary to neurological compression at initial diagnosis. In contrast, patients with multiple myeloma presented with neurological involvement in 7.4 to 16% of the cases. Pain and/or paralysis impair the ability of these patients to ambulate, and also impair their quality of life.[4]

Long-term outcomes

In 1989, Frassica[3] described the outcome for 46 patients treated for SP with a mean follow-up of 90 months: 54% turned into multiple myeloma, 33% were disease-free, 11% had a local recurrence, and 2% presented with a new SP in a different location. 50% of local recurrences were diagnosed during the first 18 months, and 23% appeared after 60 months. The overall survival of patients with SP of bone is 75% at 5 years, and 45% at 10 years. Table 1 depicts actuarial disease-free survival.[2]

Treatment

The goals of treatment for SP of the spine are local control of the disease and preservation or re-establishment of spinal stability.[4] These help with pain management and can improve or prevent neurological deterioration. Treatment options today include radiotherapy, surgery, radiotherapy combined with surgery, and vertebroplasty or kyphoplasty.

Corresponding Author
*Department of Orthopaedics & Rehabilitation
University of Iowa
Iowa City, Iowa 52242

†Orthopaedic Department
Catholic University Hospital
Santiago, Chile

TABLE 1
Disease-free survival (Kaplan-Meier) for Solitary Plasmocytoma (adapted from Delauche-Cavallier[6]

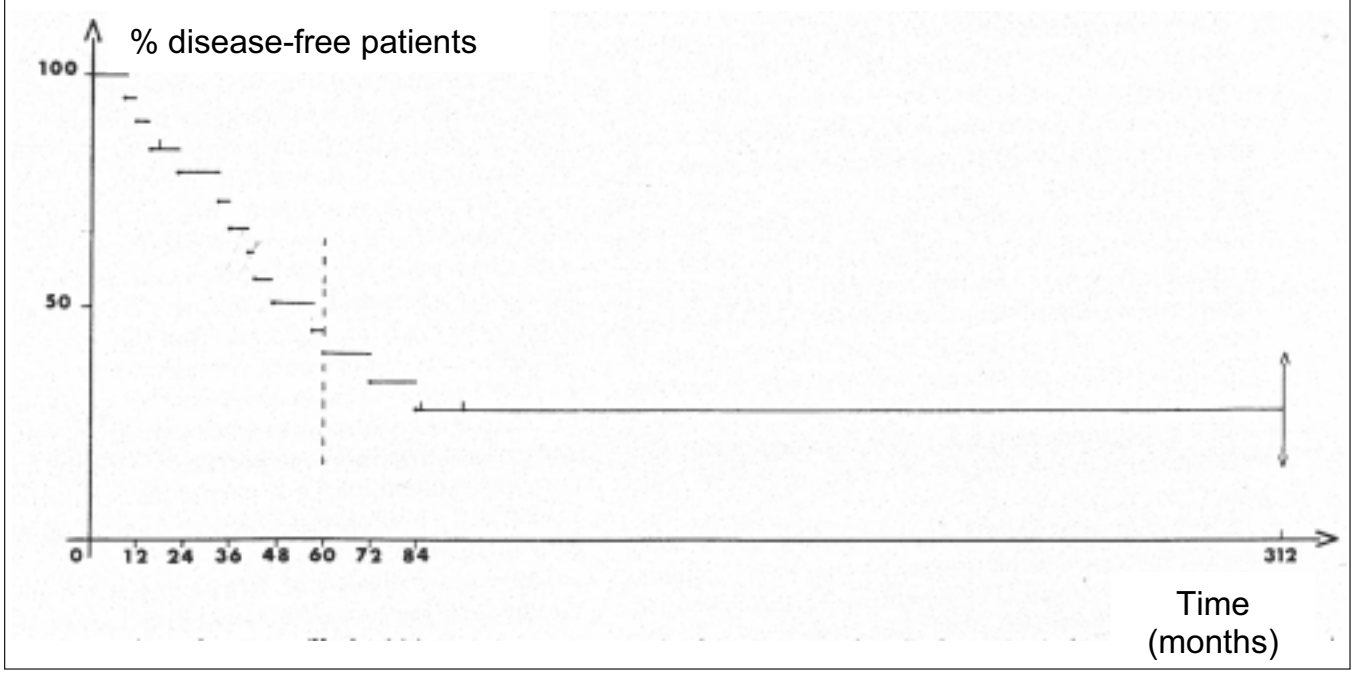

Radiotherapy

SP is a highly radiosensitive tumor, and this treatment modality has proven to be the most effective for local disease control. McLain and Weinstein[5] have established that radiotherapy is also an effective means of controlling neurological deterioration, even with neoplastic epidural involvement. Lecouvet et al.[6] suggested that radiotherapy could diminish the risk for pathologic fracture in the long-term. They observed remodeling and re-ossification of the vertebral body conditioned by the absence of myelomatous infiltration. Nevertheless, other authors have emphasized the lack of immediate stability, with continued risk for pathologic fracture, progressive vertebral collapse and pain.[4,7,20] In our experience, we have observed that the remodeling of bone trabeculae does not reestablish the architecture of the vertebral body in the long term (example presented in Case 1, Figure 4). For this reason, we consider it necessary to establish the probability of vertebral collapse. This is related to the degree of destruction of the vertebral body at initial diagnosis. This has not been studied in any of the published series.[8,9] The timing of radiotherapy is also important if surgery is considered. Among other factors, pre-operative radiotherapy increases peri-operative complications dramatically.[21,22] If surgical stabilization is accompanied by fusion, a 4 to 6 week interval should be allowed for initial osteoblastic differentiation in the bone graft.

Surgery

Surgery can be designed to comply with one or all treatment goals;[8,9]

1. **Local disease control:** An en-bloc excision[10,17,18,19] could achieve this objective, with at least marginal resection of the tumor. It is a highly demanding procedure, including simultaneous anterior and posterior approaches, with prolonged operating periods. In many cases, radiotherapy would still be recommended adjuvant therapy. For this procedure, pre-operative embolization should be considered in light of the abundant vascularity of this tumor. There are no published series that can prove if this procedure offers better results compared to radiotherapy alone.

2. **Spinal stability:** Instrumented posterior spinal fusion can achieve the goals of reestablishing spinal stability and alignment. It must be complemented by radiotherapy for local disease control.

3. **Decompression of neural elements**: In cases of established or progressive neurological dysfunction, we must consider the etiology. The differential diagnosis includes epidural tumor mass or abnormal bony architecture of the vertebral canal such as bone fragments within the canal or angular kyphosis. In most cases when epidural tumor mass is the compressive element, this may be treated by radiotherapy alone.

TABLE 2
Risk of pathologic vertebral collapse for thoracic vertebrae (adapted from Taneichi et al.[16])

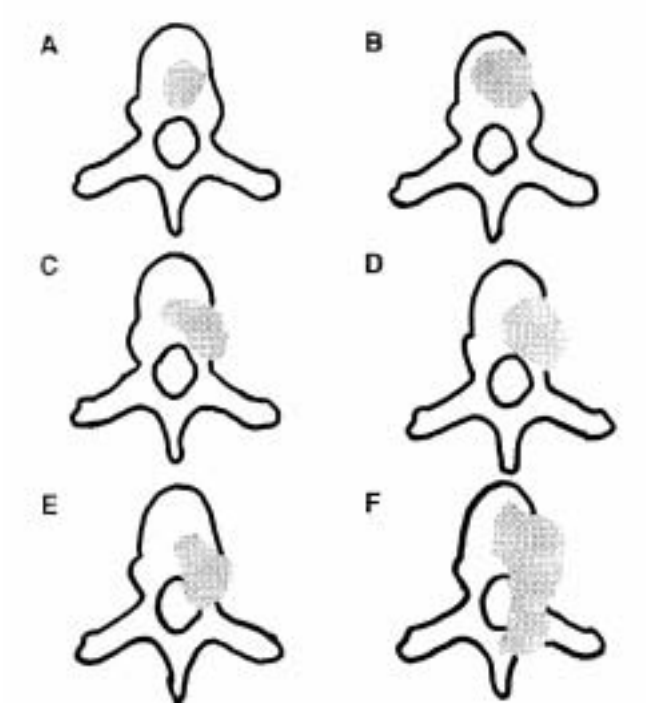

Shaded areas represent osteolytic metastases.

	A	B	C	D	E	F
%TO	30	60	30	60	30	60
Costo-vertebral joint	-	-	+	+	+	+
Pedicles	-	-	-	-	+	+
Posterior elements	-	-	-	-	-	+
Probability of collapse	**0.13**	**0.68**	**0.57**	**0.96**	**0.71**	**0.98**

TABLE 3
Risk of pathologic vertebral collapse for lumbar vertebrae (adapted from Taneichi et al.[16])

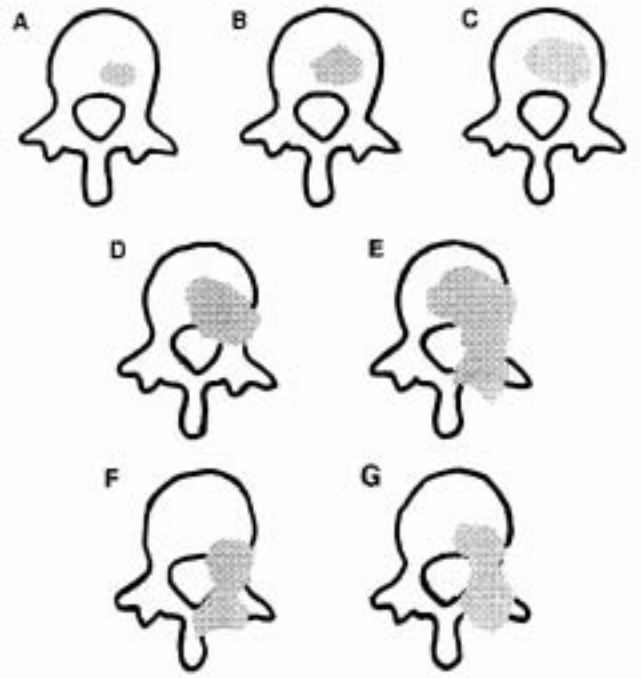

Shaded areas represent osteolytic metastases.

	A	B	C	D	E	F	G
% TO	20	30	40	40	60	5	20
Pedicles	-	-	-	+	+	+	+
Posterior elements	-	-	-	-	+	+	+
Probability of collapse	**0.07**	**0.25**	**0.60**	**0.99**	**0.99**	**0.06**	**0.38**

Criteria for Surgical Intervention: Risk for Immediate Vertebral Collapse

Risk criteria have been established to predict the likelihood of a pathological vertebral fracture. Taneishi et al[4] have established probability criteria for vertebral collapse for predominantly osteolytic metastatic disease, based on the morphology of vertebral destruction at initial diagnosis. The compromised area of the vertebral body, as well as the presence of destruction of the posterior elements and costovertebral joints (in the thoracic spine), can be correlated to a probability of collapse. This is depicted in Tables 2 (thoracic spine) and 3 (lumbar spine). In a similar fashion, Harrington[11] has established that patients who have a >50% vertebral body destruction would require posterior stabilizing surgery. Additional criteria for considering a stabilization procedure are patients with established pathological fractures, and those with angular kyphosis. Neurological deterioration is also a factor.

Considering the above, we propose the following criteria for surgical decision-making in vertebral solitary plasmocytoma: Instrumented posterior spinal fusion and radiotherapy after 6 to 8 weeks is indicated if the probability of pathologic vertebral collapse exceeds 50% according to Taneishi, if there is a local kyphosis with a Farcy corrected kyphosis of > 20˚, and if there is an associated translational deformity. If there is an established or progressive neurological deficit, it must first be determined if this is secondary to epidural tumoral infiltration, or to abnormal bony architecture. In the latter case, decompressive surgery is also indicated, anterior or posterior, according to the direction of the canal encroachment. Kyphotic or translational deformity may allow for indirect decompression by realignment of the vertebral canal.

Vertebroplasty / Kyphoplasty

These minimally invasive techniques are gaining increasing popularity for the treatment of osteoporotic vertebral compression fractures.[7,12,13,14,15,23] Some series include multiple myeloma pathologic fractures.[12,13,23] The theoretical benefit of these procedures is based on recovering structural integrity and thereby reducing deformity. Nevertheless, these techniques are not exempt from complications, including radiculopathy and spinal cord compression. These complications are especially relevant in myeloma/metastasis patients.[24]

CLINICAL CASES

Case #1: A 62-year-old male presented with a 9-month history of low back pain. Initial x-rays show a right "winking owl" sign in L1 (Figure 1). An MRI was performed which showed severe destruction of this vertebral body, extending into the right pedicle (Figure 2). The diagnosis of SP was confirmed by percutaneous transpedicular biopsy, and metastatic work-up was negative.

We estimated the probability of progressive vertebral collapse, considering the 90% body involvement and destruction of the right pedicle and posterior arch, to be 99% (Table 3). There was no significant epidural invasion. Posterior stabilization with Harrington-Luque rods from T10 to L4 (Figure 3) was performed. The patient was then treated with radiotherapy. At 2-year follow-up, there was evidence of trabecular remodeling, but without real structural recovery of the vertebral body (Figure 4). There was no evidence of local or systemic recurrence.

Case #2: A 56-year-old male presented with a 2-month history of low back pain that radiated into the right thigh. Exam revealed weakness of both hip flexors and the right knee extensor. Plain films showed an osteolytic lesion of L2 (Figure 5) and an MRI showed tumoral invasion of the spinal canal (Figure 6). The diagnosis of SP was confirmed by percutaneous transpedicular biopsy, and metastatic work-up was negative.

The probability of progressive vertebral collapse, according to Taneichi, with 90% body involvement and destruction of the left pedicle and posterior arch, was 99%. He was treated with posterior stabilization of T12 to L4 (Figure 7) and subsequent radiotherapy. His pain improved and his neurological dysfunction recovered completely. At 18-month follow-up, there were no signs of local or systemic recurrence.

Case #3: A 59-year-old male presented with a 6-month history of thoracolumbar back pain. Plain films showed a "winking owl" sign of T12 (Figure 8). Exam revealed weakness of his left quadriceps and long-tract signs. A CT scan and MRI identified lesions in T12, L1, L2, L4 and L5, and epidural invasion was seen at T12 (Figures 9 and 10).

Percutaneous biopsy of T12 identified plasma cell tumor, and metastatic work-up was negative.

The probability of progressive vertebral collapse, according to Taneichi, with 90% body involvement and destruction of the left costo-transverse joint, pedicle, and posterior arch, is 99% (Table 2). There was no evidence of encroachment into the spinal canal. Considering the magnitude of destruction of the adjacent vertebral bodies, surgery consisted of posterior stabilization of T9 to L3.

The patient was subsequently treated with radiotherapy and chemotherapy. Pain relief and neurological improvement occurred. However, at 2 months after surgery, the patient presented with febrile neutropenia, and died of pulmonary sepsis.

CONCLUSION

In the above cases, posterior spinal stabilization was performed because of a high probability of vertebral collapse. "Prophylactic" surgery has been an effective means of managing pain secondary to instability and may contribute to the recovery of neurological deficits.

Figure 1. Osteolytic involvement of L1 with destruction of the right pedicle.

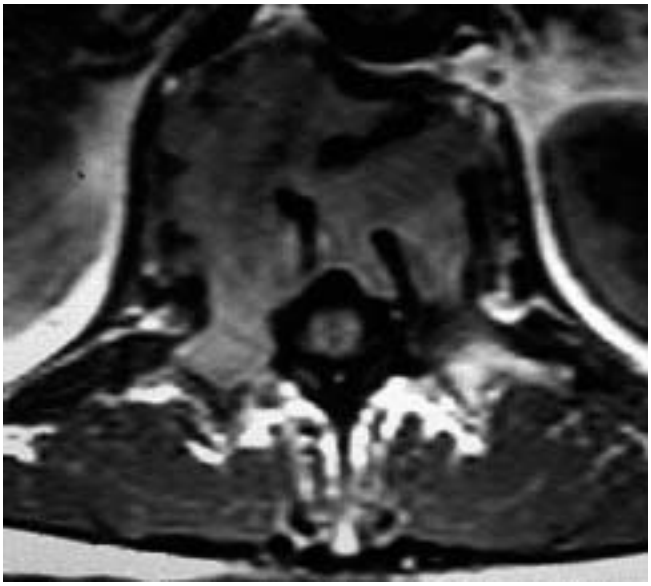

Figure 2. Destruction of the L1 vertebral body and right pedicle.

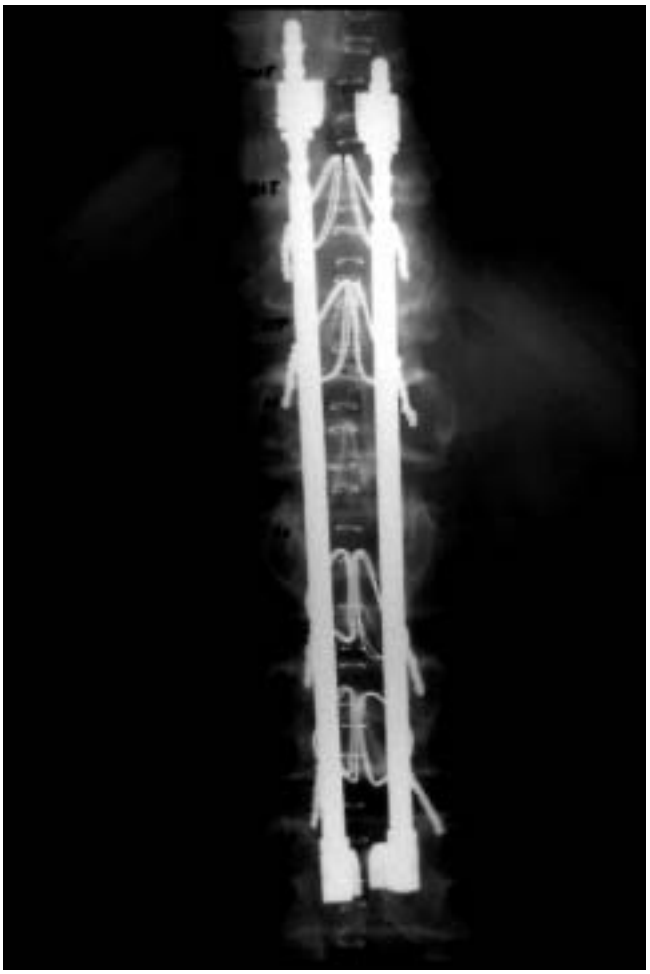

Figure 3. Harrington-Luque instrumentation T10-L4.

Figure 4. Remodeling of the vertebral body trabeculae at 2 years.

Figure 5. Osteolytic involvement of the body of L2.

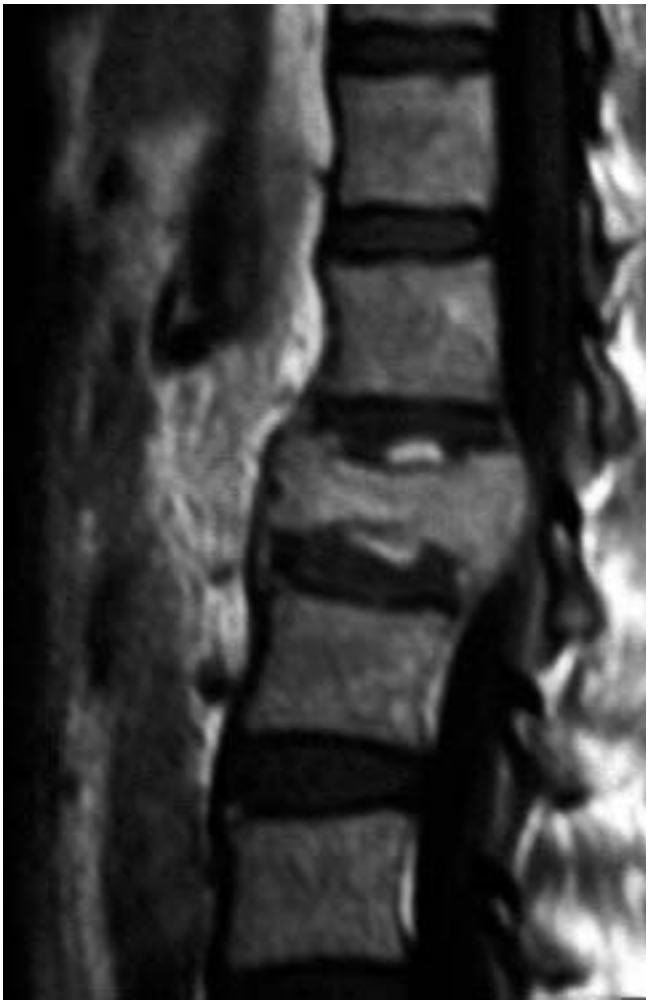

Figure 6. Invasion of the spinal canal at L2.

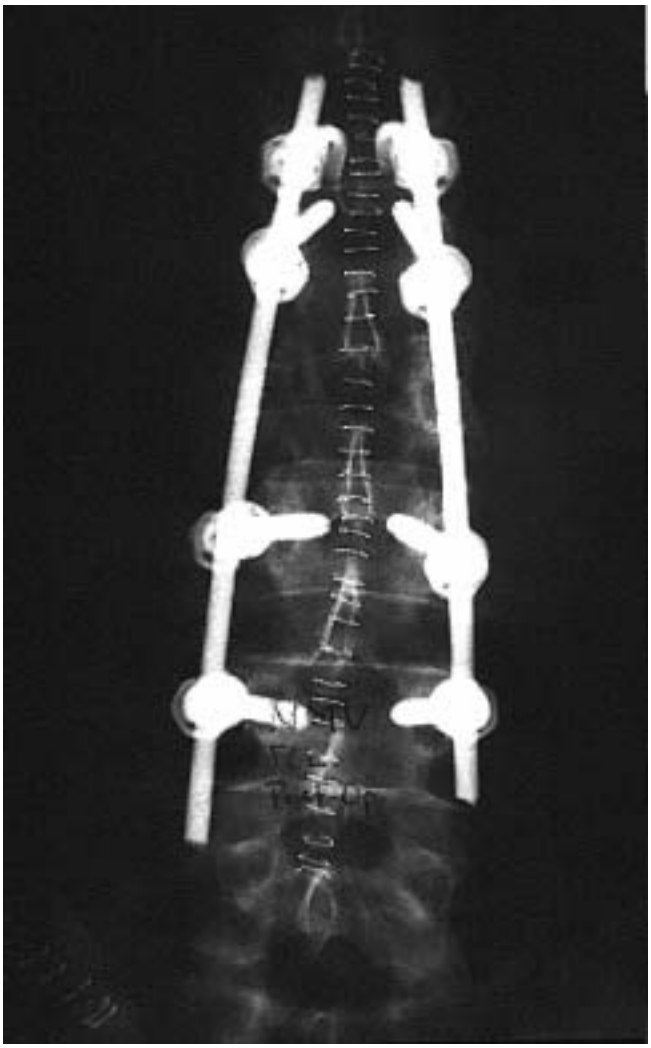

Figure 7. T12-L4 posterior instrumentation.

Figure 7.

Figure 8. Osteolytic destruction of the T12 body and left pedicle.

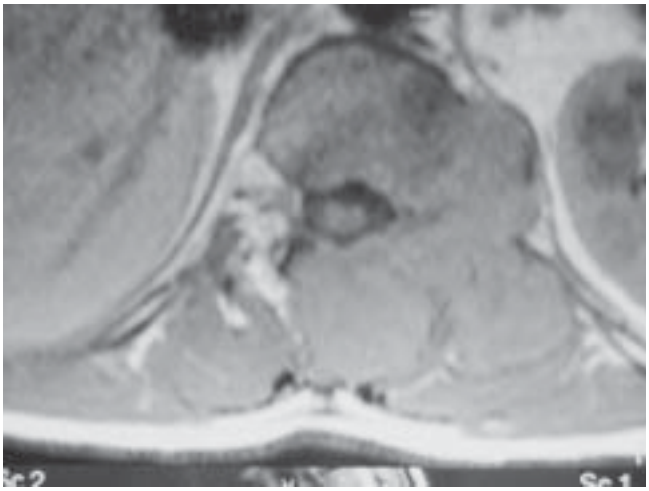

Figure 9. Tumoral involvement of T12, with destruction of the left costo-transverse joint, pedicle and posterior arch.

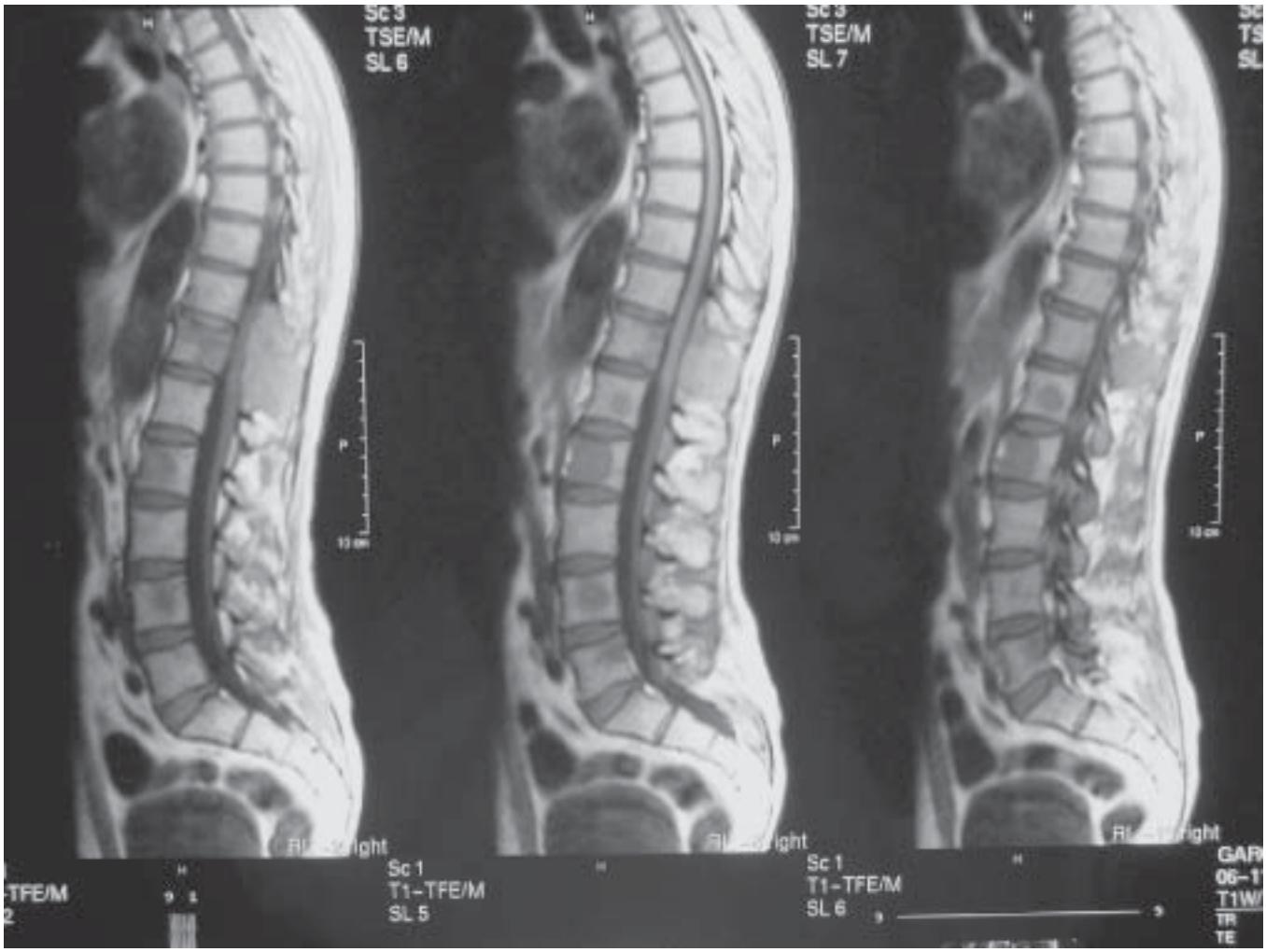

Figure 10. Tumoral compromise of T12, L1, L2, L4 and L5.

BIBLIOGRAPHY

1. **Galieni P., Cavo M., Avvisati G., Pulsoni A., Falbo R., Bonelli MA., Russo D., Petrucci MT., Bucalossi MA.,** Turas: Solitary Plasmocytoma of Bone and Extramedullary Plasmocytoma: Two different Entities? *Ann. Oncol.* 6(7): 687-91, 1995.
2. **Delauche-Cavallier M.C., Laredo J.D., Wibier M., Bard M., Mazabraudt A., Le Bail, Darne JL., Kuntz D., Ryckewaert A :** Solitary Plasmocytoma of the Spine: Long-Term Clinical Course. *Cancer* 61: 1707-14, 1988.
3. **Frassica D.A., Frassica F.J., Schray MF., Sim FH., Kyle RA.:** Solitary Plasmocytoma of Bone: Mayo Clinic Experience. *Int. J. Radiat. Oncol. Biol. Phys.* 16(1): 43-8, 1989.
4. **Taneichi H., Kaneda K., Takeda N., Abumi K., Satoh S:** Risk Factors and Probability of Vertebral Body Collapse in Metastases of the Thoracic and Lumbar Spine. *Spine* 22:239-245, 1997.
5. **McLain R.F., Weinstein J.N.:** Solitary Plasmocytomas of the Spine: A Review of 84 Cases. *J. Spinal Disord.* 2(2): 69-74, 1989.
6. **Lecouvet F., Richard F., Vardeberg B., Malghin J., Maldague B., Jamart J., Fenant A., Michaux J:** Long-term Effects of Localized Spinal Radiation Therapy on Vertebral Fractures and Focal Lesions Appearance in Patients with Multiple Mieloma. *Br. J. of Haemathology* 96: 743-5, 1997.
7. **Asdourian P.L., Mardjetko S., Rauschning W., Jonsson Hjr., Hammerberg KW., Dewald RL:** An Evaluation of Spinal Deformity in Metastatic Breast Cancer. *J. Spinal Disord.* 3(2): 119-34, 1990.
8. **Kivioja A.H., Karaharju E.O., Elomaa I, Bohling TO:** Surgical Treatment of Mieloma of Bone. *Eur. J. Cancer* 28A(11): 1865-9, 1992.
9. **Smith S.R., Saunders P.W.G., Todd N.V.:** Spinal Stabilisation in Plasma Cell Disorders. *Eur. J. Cancer* 31A(9): 1541-4, 1995.
10. **Boriani S., Biagini R., De Iure F., Bertoni F., Malaguti MC., Di Fiore M., Zanoni A:** En Bloc Resection of Bone Tumors of the Thoracolumbar Spine. *Spine* 21: 1927-31, 1996.
11. **Harrington K.D.:** Metastatic tumors of the spine: Diagnosis and treatment. *Jour. A.A.O.S.* 1: 76 - 86, 1993.
12. **Cortet B., Cotten A., Boutry N., Dewatre F., Flipo RM, Duquesnoy B., Chaetanet P., Delcambre B:** Percutaneous vertebroplasty in patients with osteolytic metastases or multiple mieloma. Rev Rhum Engl Ed 64(3): 177-83, 1997.
13. **Cotten A., Dewatre F., Cortet B., Assaker R., leblond D., Duquesnoy B., Chaetanet., Clarisse J:** Percutaneous vertebroplasty for osteolytic metastases and mieloma: effects of the percentage of lesion filling and the leakage of methyl methacrylate at clinical follow-up. *Radiology* 200(2): 525-30, 1996.
14. **Feydy A., Cognard C., Miaux Y, Sola Martinez MT., Weill A., Rose M., Chiras J:** Acrylic Vertebroplasty in Symptomatic Cervical Vertebral Hemangiomas: Report of 2 Cases. *Neuroradiology* 38(4): 389-91, 1996.
15. **Cotten A., Boutry N., Cortet B., Assaker R, Demondion X., Leblond D., Chaetanet P, Duquesnoy H., Deramond:** Percuteneous Vertebroplasty: State of the Art. *Radiographics* 18(2): 311-20, 1998.
16. **Takahashi T., Koshu K., Tomminaga T., Takahashi A., Yoshimoto T:** Solitary Plasmocytoma in the Thoracic Spine: 2 Case Reports. *Neurosurgical Review* 21(2-3): 121-5, 1998.
17. **Tomita K., Kawahara N., Baba H., Tsuchiya H, Fujita T, Toribatake Y:** Total En Bloc Spondylectomy: A new surgical technique for primary malignant vertebral tumors. *Spine* 22(3): 324 – 333, 1997.
18. **Sundaresan N, DiGiacinto GV, Krol G, Hughes JEO:** Complete spondylectomy for malignant tumors. In: Sundaresan N, Schmidek HH, Schiller AL, Rosenthal DI, eds. Tumors of the Spine. Diagnosis and Clinical Management. Philadelphia: W.B. Saunders, 1990:438-45.
19. **Boriani S, Weinstein JN, Biagini R:** Primary Bone Tumors of the Spine: Terminology and Surgical Staging. *Spine* 22(9): 1036 – 1044, 1997.
20. Multiple Myeloma: Surgery of the Spine—Retrospective Analysis of 27 Patients. *Spine* 27(3): 320 – 326, 2002.
21. **Ghogawala Z, Mansfield FL, Borges LF:** Spinal Radiation Before Surgical Decompression Adversely Affects Outcomes of Surgery for Symptomatic Metastatic Spinal Cord Compression. *Spine* 26: 818 – 824, 2001.
22. **McPhee IB, Williams RP, Swanson CE:** Factors Influencing Wound Healing After Surgery for Metastatic Disease of the Spine. *Spine* 23: 726 732, 1998.
23. **Lieberman IH, Dudeney S, Reinhardt MK, Bell G:** Initial Outcome and Efficacy of “Kyphoplasty” in the Treatment of Painful Osteoporotic Vertebral Compression Fractures. *Spine* 26(14): 1631 – 1638, 2001.
24. **Garfin SR, Yuan HA, Reiley MA,** New Technologies in Spine: Kyphoplasty and Vertebroplasty for the Treatment ofr Painful Osteoporotic Compression Fractures. *Spine* 26 (14): 1511 – 1515, 2001.

OPERATIVE TREATMENT OF CERVICAL SPONDYLOTIC MYELOPATHY AND RADICULOPATHY: A COMPARISON OF LAMINECTOMY AND LAMINOPLASTY AT FIVE YEAR AVERAGE FOLLOW-UP

S.B. Kaminsky, MD, C.R. Clark, MD+, and V.C. Traynelis, MD#

ABSTRACT

Background: The natural history of cervical spondylotic myelopathy is frequently one of slow, progressive neurological deterioration. The operative treatment for patients with moderate to severe involvement is decompression of the spinal cord. Laminectomy has been a traditional approach and laminoplasty has developed as an attractive alternative. The purpose of this study was to examine and compare the outcomes of these two procedures in similar groups of patients at a five year average follow-up.

Methods: A consecutive series of twenty patients who underwent open-door laminoplasty for multi-level cervical spondylotic myelopathy or radiculopathy was compared to a similar group of 22 matched patients who underwent multi-level laminectomies. Patients were similar in age, gender, number of operative levels, and length of follow-up. At the latest examination, each patient underwent a comprehensive neurological evaluation. A modification of the Nurick classification was used to assess the degree of myelopathy. Radiographs at latest follow-up were assessed for instability, and measurements of the space-available-for-the-cord and Pavlov ratio were made at involved levels.

Results: Myelopathy, as determined by our modified Nurick scale, improved from a preoperative average of 2.44 to 1.48 in laminoplasty patients and from an average of 3.09 to 2.50 in laminectomy patients. Pain improved 57 percent and 8 percent in laminoplasty and laminectomy groups, respectively. Subjective neck stiffness was not significantly different based on the numbers available, although laminoplasty patients demonstrated some loss of range of motion on examination. The only variable that predicted the postoperative degree of myelopathy in both groups was the preoperative degree of myelopathy.

Conclusions: Laminectomy and laminoplasty patients demonstrated improvements in gait, strength, sensation, pain, and degree of myelopathy. Laminoplasty was associated with fewer late complications. Based on this analysis, we believe that laminoplasty is an effective alternative to laminectomy in patients with multi-level cervical spondylotic myelopathy or radiculopathy.

INTRODUCTION

Several procedures are available for the operative management of multi-level cervical spondylotic myelopathy or radiculopathy.[16] Laminectomy has proven to be successful,[6,22,36] but several inherent risks have been recognized. Postoperative instability and deformity, in particular kyphosis, is a well-documented problem.[2,4,5,17,23] Development of postoperative hematoma and peridural scar formation has also been documented. Expansive open-door laminoplasty, introduced by Hirabayashi in 1977,[18,20] decompresses the spinal cord with two theoretical advantages: 1) preservation of some posterior elements minimizes the possibility of postoperative instability or deformity while expanding the room available for the cord; 2) it may limit the formation of hematoma and postoperative membranes.

The purpose of this study was to examine and compare the outcomes of these two procedures in similar groups of patients at a five year average follow-up. In addition, we wished to examine preoperative variables and determine their association, if any, with postoperative recovery. We are aware of no previously published

Investigation performed at the University of Iowa Hospitals and Clinics
Department of Orthopaedics and Rehabilitation
Iowa City, IA

+Department of Orthopaedics and Rehabilitation
University of Iowa Hospitals and Clinics
Iowa City, IA

Department of Neurosurgery
University of Iowa Hospitals and Clinics
Iowa City, IA

Correspondence author:
Charles R. Clark, MD
Department of Orthopaedics and Rehabilitation
University of Iowa Hospitals and Clinics
200 Hawkins Drive/JPP
Iowa City, IA 52246
319-356-2332

TABLE 1
Preoperative Comparison of Laminoplasty and Laminectomy Patients

	Laminoplasty	*Laminectomy*
Age (yrs.)	53.5 (41-75)	54.3 (33-73)
Length of Follow-up (mos.)	65.4 (36-112)	64.8 (53-76)
Female/Total	2/20	3/22
Avg. # Operative Levels	4.3 (3-5)	4.6 (3-6)
SAC (mm)	14.1 (10-17)	15.2 (13-18)
Pavlov ratio	.64 (.46-.75)	.71 (.54-1.09)

SAC= Space Available for the Cord

TABLE 2
Modified Nurick Classification[39]

Grade 0	No root or cord symptoms
Grade I	Root signs or symptoms. No evidence of cord involvement.
Grade II	Signs of cord involvement. Normal gait.
Grade III	Mild gait abnormality. Able to be employed.
Grade IV	Gait abnormality prevents employment.
Grade V	Able to ambulate only with assistance.
Grade VI	Chair bound or bedridden.

TABLE 3
Prolo Anatomic-Economic-Functional Rating System (1-10)[41]

Economic status

E1	Complete invalid
E2	No gainful occupation (including ability to do housework or continue retirement activities)
E3	Able to work but not at previous occupation
E4	Working at previous occupation on part-time or limited status
E5	Able to work at previous occupation with no restrictions of any kind

Functional status

F1	Total incapacity (or worse than before operation)
F2	Mild to moderate level of pain (or pain same as before operation but able to perform all daily tasks of living)
F3	Low level of pain and able to perform all activities except sports
F4	No pain, but patient has had one or more recurrences of neck or radicular pain
F5	Complete recovery, no recurrent episodes of pain, able to perform all previous activities

study of this length follow-up that excludes the diagnosis of ossification of the posterior longitudinal ligament (OPLL) and compares laminectomy and laminoplasty. Our hypothesis is that both of these procedures provide adequate decompression of the spinal cord, however, laminoplasty may avoid the postoperative problem of instability.

MATERIALS AND METHODS

A consecutive series of twenty patients who underwent open-door laminoplasty by a single surgeon (CRC) for multi-level cervical spondylotic myelopathy or radiculopathy was compared to a similar group of 22 patients who underwent multi-level laminectomies. Each patient had a minimum three-year follow-up with an average of approximately five years (range 36 to 112 months). Laminectomy patients were matched in terms of age, length of follow-up, gender, and number of operative levels.

The selection of the procedure was at the discretion of the individual surgeon. All patients but one from the laminoplasty group had recent radiographic follow-up.

Indications for the procedures included patients with cervical spondylotic myelopathy or myeloradiculopathy who had progressive neurological symptoms, bowel or bladder alterations, failure of non-operative management, and multilevel (greater than two) involvement. Patients with ossification of the posterior longitudinal ligament, post-traumatic injuries, tumorous conditions, and underlying instability were excluded.

The two groups were similar in age, length of follow-up, number of involved levels, and gender (Table 1). The average age of the patients in the laminoplasty group was 53.5 years (range 41 to 75 years), and the average age in the laminectomy group was 54.3 years (range 33 to 73 years). Follow-up averaged 65.4 months (range 36 to 112 months) in the laminoplasty group, and 64.8 months (range 53 to 76 months) in the laminectomy group. An average of 4.3 levels (range 3 to 6 levels) were involved in the laminoplasty group and 4.6 levels (range 3 to 5 levels) in the laminectomy group. Two of twenty patients in the laminoplasty group, and three of 22 patients in the laminectomy group were women. Five patients had prior neck operations in the laminoplasty group, and one patient in the laminectomy group. Among laminoplasty patients, one had a three-level procedure, 12 had four-level procedures, and 7 had five-level procedures. Three laminectomy patients had three-level procedures, 7 had four-level procedures, 7 had five-level procedures, and 5 had six-level procedures. Cervical 2 was an operative levels in 8 laminectomy patients and in none of the laminoplasty patients.

At latest follow-up, each patient underwent a complete evaluation including neurological examination. The examination was performed by a surgeon (SBK) not involved with the operative procedures. One

laminoplasty patient had his most recent follow-up at an outside facility. All patients had had preoperative cervical anteroposterior and lateral flexion and extension cervical spine radiographs and either magnetic resonance imaging or computer tomography scans with myelography, or both. The evaluation included the location and degree of preoperative and postoperative pain using an analog scale, subjective and objective alteration in sensation and weakness, presence of hyperreflexia, clonus, Babinski sign, Hoffman sign, walking difficulty, bowel or bladder changes, neck stiffness, cervical range-of-motion, use of pain medication postoperatively, occupation, smoking habits, prior neck operations, and pertinent medical history. The evaluation also included assessment of the degree of myelopathy based on a modification of the Nurick classification[38] (Table 2). An additional category, no cord *or* root symptoms, was added. The Prolo anatomic-economic-functional score was calculated for each patient (Table 3).[40]

The preoperative space-available-for-the-cord (SAC) was determined for both laminoplasty and laminectomy patients. To control for variation in radiograph magnification, the Pavlov ratio (comparison of anteroposterior canal diameter to the anterior-posterior vertebral body diameter in the sagittal plane) was also calculated.[46] The postoperative space-available-for-the-cord and Pavlov ratios were determined for laminoplasty patients only since it was not possible to determine these values in the laminectomy patients. Evidence of pre- and postoperative deformity or instability was evaluated on postoperative dynamic films. Radiographic analysis was then repeated to assess intra-observer reliability.

In the laminoplasty group, preoperative pain was solely in the neck, shoulders, or both in 3 patients, in the neck and extremities in 10, and in extremities alone in 7. Five patients had neck or shoulder pain only preoperatively in the laminectomy group, 4 in the neck and extremities, and 5 in extremities alone, and 9 had no or minimal discomfort. On a visual analog scale of 1 to 10, from least to most, the average pain level was 7.7 in the laminoplasty patients and 4.7 in the laminectomy patients. This difference was significant ($p=.018$).

Neck stiffness was subjectively graded on a three point scale as follows: 1—no or occasional neck stiffness, 2—intermittent or frequent neck stiffness, but no difficulties with activities of daily living, and 3- neck stiffness causing difficulty or interfering with activities of daily living (ADL's). The average score preoperatively was 1.73 and 1.68 in the laminoplasty and laminectomy groups, respectively.

Preoperatively, 16 of 20 laminoplasty patients described subjective sensory changes including numbness or tingling in the upper extremities, lower extremities, or both. Seventeen of 22 laminectomy patients described similar sensory changes. Sixteen laminoplasty patients believed that weakness in the upper extremities, lower extremities, or both was a problem, and 17 laminectomy patients also believed weakness was a problem. Sixteen laminoplasty patients and 17 laminectomy patients described gait changes that affected their ability to walk, or the distance they walked, or required them to use some support or walking aide. Two laminoplasty patients and 6 laminectomy patients described the acute onset of bowel changes, bladder changes, or both.

Preoperative physical examination revealed 11 laminoplasty patients with sensory changes, and 16 laminectomy patients with alterations in sensation. Objective motor weakness in any muscle group of the upper or lower extremities during manual motor testing was identified in 13 laminoplasty patients and in 14 laminectomy patients. Gait abnormalities were observed in 11 laminoplasty and 16 laminectomy patients. Hyperreflexia was demonstrated in 13 laminoplasty and 18 laminectomy patients. A Hoffman sign was elicited in 11 laminoplasty patients, clonus in 8, and Babinski in 6. Nine laminectomy patients had a Hoffman sign, 9 had clonus of more than 2 beats, and the presence of a Babinski sign was seen in 8.

Using the modified Nurick classification, the average preoperative score for laminoplasty patients was 2.44 (range 1 to 5) and 3.09 (range 1 to 6) for laminectomy patients ($p<.0001$). Eighteen laminoplasty patients were diagnosed with myelopathy or myeloradiculopathy, and 2 had radiculopathy only. 19 laminectomy patients were diagnosed with myelopathy or myeloradiculopathy and 3 with radiculopathy alone.

Nine laminectomy patients were working preoperatively in jobs requiring moderate to heavy labor (for example, mechanic, carpet layer, or construction work). One was unemployed, 3 were retired, and 2 were disabled. Six laminoplasty patients were involved in jobs requiring moderate to heavy labor. One was unemployed, one retired, and 5 disabled. Smoking pack-years averaged 51 in laminoplasty patients and 33 in laminectomy patients.

Preoperative radiographs demonstrated an average space-available-for-the-cord at the most involved level of 14.1 millimeters (range 10 to 17 millimeters) in the laminoplasty group. The average space-available-for-the-cord for all involved levels was 15.2 millimeters (range 11.8 to 17 millimeters) and the Pavlov ratio averaged .64 (range .46 to .75) preoperatively in the laminoplasty group. The space available for the cord averaged 15.2 millimeters (range 13 to 18 millimeters) at the narrowest level and 16.5 millimeters (range 13.7 to 19.6 millimeters) at all operative levels in laminectomy patients. The Pavlov ratio averaged .71 (range .54 to 1.09) preoperatively in laminectomy patients.

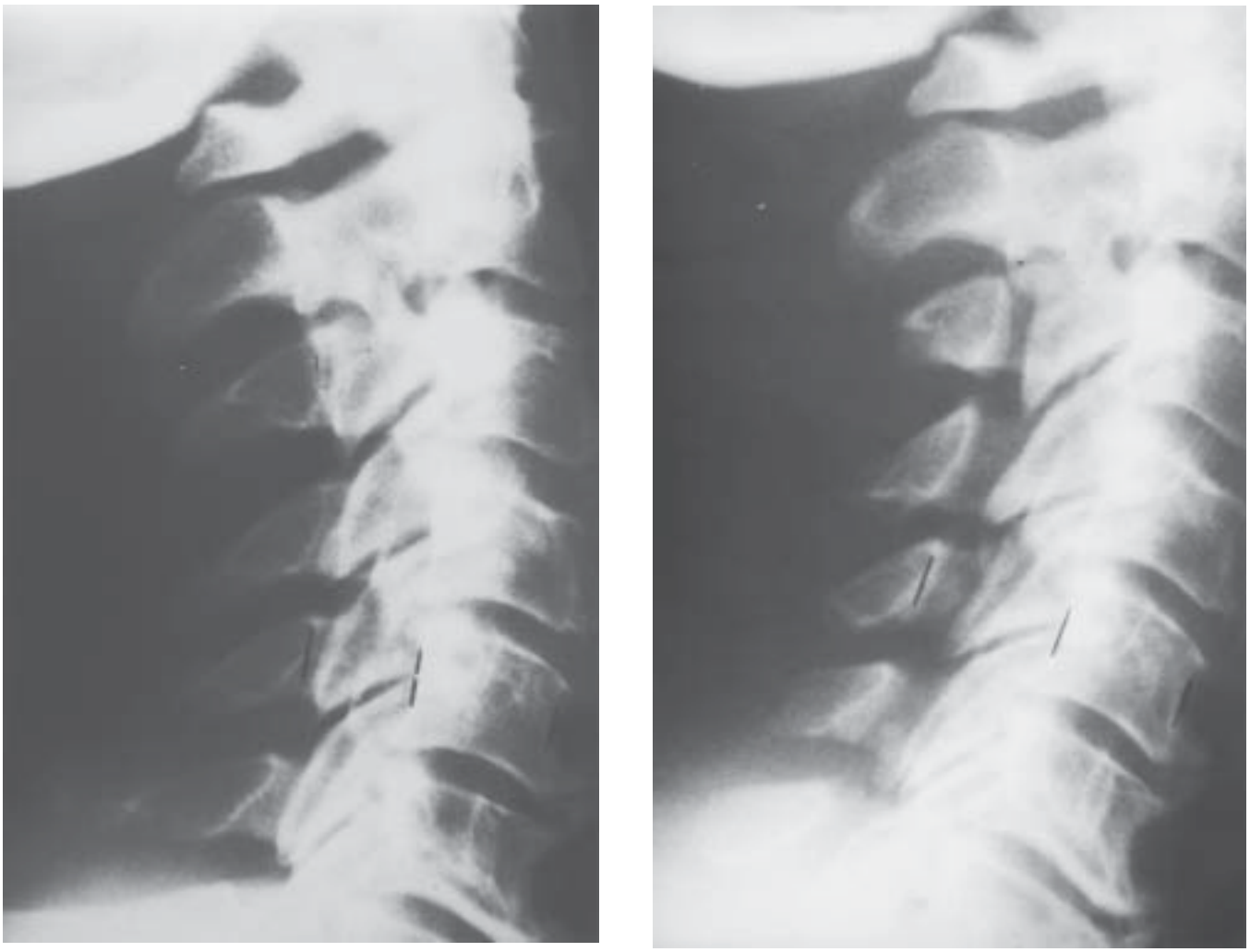

Figures 1-A and 1-B. Pre-and postoperative radiographs of a 65 year-old man with progressive myelopathy at the time of laminoplasty. Fig. 1-A: Preoperative lateral radiograph demonstrating notable canal stenosis. Fig. 1-B: Postoperative lateral radiograph showing a 7 millimeter expansion of the space-available-for-the-cord following laminoplasty using Hirabyashi's open-door technique.

OPERATIVE TECHNIQUE OF LAMINOPLASTY

A standard midline posterior approach is performed, and the posterior elements are exposed. The interspinous and supraspinous ligaments are left intact. Decompression begins at the least involved levels and then proceeds to the more stenotic levels. A cutting burr is then used to make a gutter through the outer cortex of the bone at the lamina-facet junction. A diamond burr then deepens the gutter through the inner cortex. The opened side is selected according to the most symptomatic side. A channel through the outer table only on the hinged side is made next with the cutting burr. The supraspinous and interspinous ligaments and the ligamentum flavum are transected at the levels immediately above and immediately below the laminoplasty. A thin Kerrison ronguer is used to complete the trough, and dural adhesions from the undersurface of the lamina are gently removed. The so-called laminar door is opened slowly to prevent excessive traction on spinal nerve roots (Figure 1). Foraminotomies are performed as needed in patients with radiculopathy. When rib allograft is used, a segment is cut into appropriate sized wedges and a trough made on either end with the cutting burr. This is then fitted between the articular processes and the edges of the lamina, propping the laminar door open (Figure 2). A hard collar is used for the first eight weeks after the operation, followed by a soft collar for an additional 4 to 8 weeks.

In the laminoplasty group, the first 10 patients underwent the standard Hirabayashi open-door technique.[20] In the next ten patients rib allograft was used to secure the opening of the laminoplasty. In the standard procedure, stay sutures, which are placed to prevent the door from closing, are placed through the deep

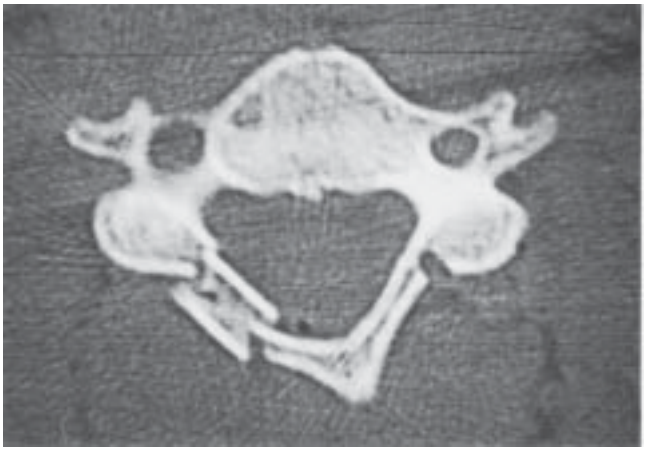

Figure 2. Postoperative computer tomography scan of laminoplasty patient using rib allograft supplementation. Note notching of rib allograft to secure laminar "door" and burred channel on hinged side through outer table only.

muscles and capsules around the facet joints of the hinged side. The stay sutures are tied to the spinous processes through the ligamentum flavum to keep the laminar door open. In the modified technique, a segment of rib allograft is obtained and a trough burred at both ends. The grooved allograft is then fitted into the opening, hinging the open-door. Laminectomies were performed in standard fashion. The amount of facet resection, if any, was dictated by the abnormal findings on preoperative neurodiagnostic studies and at operation. Intraoperative monitoring of the spinal cord was used with few exceptions.

STATISTICAL ANALYSIS

The relationship between preoperative variables including age, smoking, space-available-for-the-cord, Pavlov ratio, and degree of myelopathy and outcome variables of postoperative modified Nurick classification, residual pain, Prolo score, postoperative weakness, sensation, and gait changes were examined. Postoperative space-available-for-the-cord and Pavlov ratio in laminoplasty patients was analyzed to see if they correlated with these postoperative variables. Multiple regression analysis, Fisher's exact test, Wilcoxon sign-rank test, Wilcoxon two-sample test, paired t-test, Pearson, and Spearman coefficients were among the statistical tools used.

RESULTS

Operative time averaged 201 minutes for the laminoplasty procedures and 165 minutes for laminectomy procedures. Blood loss averaged 505 milliliters (range 100 to 1500 milliliters) in laminoplasty cases and 310 milliliters (range 40 to 1450 milliliters) in laminectomy procedures.

TABLE 4
Postoperative Improvement in Outcome Variables

	Laminoplasty	*Laminectomy*
Objective weakness	12/13	7/14
Objective sensation	7/11	7/16
Subjective weakness	10/17	9/18
Subjective sensation	10/20	7/17
Gait	7/11	7/16
Bowel/bladder	2/2	4/6
Hyperreflexia	7/11	3/18
Hoffman sign	7/11	2/22*
Clonus	3/8	2/9
Babinski	1/6	3/22*

*New clinical findings in two patients identified during the latest postoperative examination

Based on the numbers available, neither the preoperative space-available-for-the-cord at the narrowest sagittal dimension, average space-available-for-the-cord of all involved levels, nor the preoperative Pavlov ratio predicted or correlated with the outcome variables of degree of myelopathy using the postoperative modified Nurick classification, residual pain, Prolo score, or postoperative weakness, sensation, and gait changes in both laminoplasty or laminectomy groups. Age had no statistical correlation with these outcome parameters, and smoking habits as determined by number of pack-years had no relationship either.

Overall, the level of pain postoperatively correlated with the level of pain preoperatively ($P<.001$, $r=.71$). However, when the individual groups were analyzed this correlation was present only for the laminectomy group and not the laminoplasty group. Laminectomy patients with a higher degree of pain preoperatively were more likely to have a higher degree of pain postoperatively.

The only variable that predicted the degree of myelopathy postoperatively in both groups, as measured on the Nurick scale, was the degree of myelopathy preoperatively. Those with a lesser degree of myelopathy or lower Nurick scores had better outcomes than those patients with advanced myelopathy and higher Nurick grade ($r=0.74$ and 0.84, $p<.0001$, in laminoplasty and laminectomy patients, respectively).

Among laminoplasty patients, a higher postoperative space-available-for-the-cord and Pavlov ratio were associated with an improved level of motor strength (20 millimeters versus 16.8 millimeters, $p=.04$). The postoperative space-available-for-the-cord was not associated with postoperative Nurick grade, postoperative pain, Prolo score, sensory improvements, or objective findings of clonus, Hoffman sign, and Babinski sign.

The postoperative Pavlov ratio was related to muscle strength, gait, and postoperative Nurick grade. Those with improvement in motor grades had an average

TABLE 5
Changes in Pain, Modified Nurick Grade, and Neck Stiffness

	Laminoplasty	*Laminectomy*	*p value*
Pain level Pre-op (1-10)	7.7	4.7	.018
Pain level Post-op (1-10)	3.2	4.4	.14
Pain % Change	-57%	-8.0%	.0036
Modified Nurick Pre-op	2.44	3.09	<.0001
Modified Nurick Post-op	1.48	2.50	<.0001
Modified Nurick % Change	-43.6%	-17.8%	<.0001
Neck Stiffness Pre-op (1-3)	1.7	1.7	.76
Neck Stiffness Post-op (1-3)	2.0	1.9	.365

Pavlov ratio of .90 versus 0.68 for those that did not improve (p=.009). Those patients with improved or normalized gait had an average Pavlov ratio of .90 versus 0.68 with those with continued gait difficulties (p=.0072). The postoperative Pavlov ratio was inversely correlated to Nurick grade (r=.-49, p=.036). Intraobserver reliability demonstrated a high level of agreement and minimal variability in evaluation of space-available-for-the-cord and Pavlov ratios.

Postoperative improvement in outcome variables are detailed in Table 4. Seven laminoplasty patients and 7 laminectomy patients had objective improvements in sensory deficits. Partial or complete recovery from motor weakness occurred in 12 laminoplasty patients and in 9 laminectomy patients. Gait improvement was seen in 7 laminoplasty patients and in 7 laminectomy patients. Bowel or bladder symptoms improved in all 6 of the laminoplasty patients with preoperative symptoms and in 4 laminectomy patients. Hyperreflexia, Hoffman sign and clonus resolved in 6, 7, and 3 laminoplasty patients, respectively, and resolution of hyperreflexia and clonus occurred in 3 and 2 laminectomy patients, respectively. At the latest postoperative examination, a Hoffman sign was a new clinical sign in two laminectomy patients. Subjectively, 10 laminoplasty patients and 7 laminectomy patients perceived improvements in sensation. Ten laminoplasty patients and 9 laminectomy patients had subjective improvement in motor strength. With the numbers available, these differences did not reach statistical significance.

Pain scores improved 57 percent to an average of 3.2 in the laminoplasty patients and improved 8 percent in laminectomy patients to an average of 4.4 (p=0.0036). At latest follow-up, 10 laminoplasty patients were taking pain medications, either acetaminophen or an nonsteroidal anti-inflammatory, on a regular basis for pain. Thirteen laminectomy patients were taking pain medications. Four of them were taking narcotic medications, and the remainder taking acetaminophen or nonsteroidal anti-inflammatories. Five laminoplasty patients had neck pain only, 4 with neck and extremity pain, and 4 with extremity pain only. Four laminectomy patients had neck pain only, 3 with neck and extremity pain, and 7 with extremity pain only.

Neck stiffness scores increased to an average of 2.0 in the laminoplasty group and 1.9 in the laminectomy group, from an average of 1.7 preoperatively in both groups. This difference was not statistically significant.

Myelopathy, as graded with the modified Nurick scale improved 44 percent among laminoplasty patients to an average of 1.48 and 18 percent in laminectomy patients to an average of 2.50. This difference was significant (p<.0001) (Table 5).

The Prolo scores averaged 7.2 in each group. Ten laminoplasty patients had good or excellent results (Prolo score of 8-10) and 10 laminectomy patients had good or excellent results. Postoperatively, one patient was involved in moderate to heavy labor among laminoplasty patients. Nine were disabled and 4 were retired. Four laminectomy patients had occupations requiring moderate to heavy labor. Seven patients were disabled and 5 retired.

Postoperative radiographs revealed an average space-available-for-the-cord of 19.3 millimeters (14 to 24 millimeters) in laminoplasty patients at the narrowest level in the spinal cord. This sagittal diameter improved an average 5.2 millimeters or 27 percent (p<.0001). The Pavlov ratio improved to an average of 0.85 (range .58-1.21) or 33 percent (p<.0001). Range of motion for laminoplasty patients averaged 27 degrees in extension and 42 degrees in flexion. This compares to 43 degrees in extension for laminectomy patients (p=.0002) and 45 degrees of flexion. Right and left bending averaged 34 degrees and 45 degrees for laminoplasty and laminectomy groups respectively (p=.009). Right and left rotation averaged 48 and 58 degrees in laminoplasty and laminectomy patients respectively (p=.069).

COMPLICATIONS

Three complications occurred in the laminoplasty group. One patient had closure of the open door. He had been treated with the original Hirabayashi technique of suturing the laminar door open. Two patients had transient C5 paresis occurring one and five days after the operation. Both patients had eventual resolution of this new weakness—one by 11 months and one by 32 months.

One early and 5 late complications occurred in the laminectomy group. One patient had a wound dehiscence that was treated with an irrigation and debridement and secondary healing. Five patients demonstrated radiographic signs of instability as defined by

Panjabi and White.[48] Two patients had C 4/5 subluxation of 4-5 millimeters. These two also had a kyphosis measuring 19 and 33 degrees on dynamic films. Three other patients also demonstrated a kyphosis measuring 28, 31, and 38 degrees. One of these patients eventually underwent anterior decompression and arthrodesis.

DISCUSSION

Cervical spondylotic myelopathy and radiculopathy is often a progressively debilitating condition, and operative intervention is frequently warranted to alter the natural history.[6,7,9,12,33,38,44] Anterior and posterior procedures have been developed to halt further deterioration and ameliorate present symptoms. Anterior decompression, corpectomy and arthrodesis is an excellent treatment alternative, but not without substantial complications.[1,8,10,19,49] The anterior approach may be particularly difficult in patients with multi-level involvement and underlying congenital or developmental stenosis. However, the anterior approach is the senior author's (CRC) preferred approach for the operative management of the majority of patients with cervical spondylotic myelopathy and radiculopathy.

The posterior approach offers simplicity, less potential operative risk, and allows decompression away from the offending abnormalities including osteophytes, ossified or buckling ligaments, and disc protrusions. Laminectomy is the most commonly performed operation, but laminoplasty is gaining acceptance. Both procedures allow for dorsal cord migration, decreasing axial tension and improving vascular perfusion. Late complications, in particular post-laminectomy kyphosis or instability in multi-level procedures, are well-known complications, although the prevalence varies. Open door laminoplasty, introduced by Hirabayashi, attempts to avoid these complications. Decompression of the spinal cord and preservation of supporting structures could minimize the potential for iatrogenic instability and expand the sagittal dimension of the spinal canal. This procedure is not without criticism. Axial pain, limitation of range-of-motion, and limited long-term data are among the areas of concern.

The two groups of patients, laminectomy and laminoplasty, were similar with respect to age, length of follow-up, gender ratio, and number of operative levels. With the numbers available, no statistically significant difference could be demonstrated between the groups preoperatively with respect to the number of patients with subjective or objective alterations in sensation or weakness, gait disturbance, hyperreflexia, Hoffman sign, clonus and presence of a Babinski sign. Several differences, however, are with noting. Although the space-available-for-the-cord on preoperative radiographs was, with the numbers available, not significantly different (15.2 millimeters versus 16.5 millimeters), the Pavlov ratio was (.64 versus 0.71). Of importance was the degree of myelopathy at the time of operation. Using our modified scale of Nurick grading, the laminectomy group demonstrated significantly worse degree of myelopathy preoperatively (3.1 vs. 2.4, $p<.0001$). The higher Nurick grades among laminectomy patients may have indicated a fixed component of myelopathy and led to a poorer outcome.

Although laminectomy patients were worse at presentation based on myelopathy classification, laminoplasty patients, who were worse by radiographic criteria preoperatively had better improvement of their neurological signs. The average Nurick score improved almost by a full grade, from 2.44 to 1.48 among laminoplasty patients, while laminectomy patients improved approximately one-half a Nurick grade from 3.09 to 2.5 ($p<.0001$).

Although the postoperative Pavlov ratio did demonstrate a significant correlation with the final Nurick grade, this association was weak ($p=.036$, $r=-.49$). The only factor that predicted the postoperative degree of myelopathy in both groups was the preoperative degree of myelopathy as designated by the Nurick grade ($p<.0001$, $r=.74$ for laminectomy group, $p<.0001$, $r=.84$ in laminoplasty group). In addition, a Pavlov ratio of 0.94 and 0.91 or greater correlated with improvements in gait and muscle strength, respectively. Conversely, patients with a Pavlov ratio of less than 0.74 and 0.68 did not demonstrate objective improvements in gait and motor strength, respectively. A space-available-for-the-cord of 20 millimeters or more postoperatively was associated with improvements in motor grades in laminoplasty patients.

Clinical signs of myelopathy such as gait abnormality, Hoffman sign, clonus, and presence of a Babinski sign resolved more often in laminoplasty patients. Subjective and objective symptoms and signs of weakness and sensory deficits also demonstrated more substantial improvements in laminoplasty patients. With these small numbers, however, statistical significance could not be determined.

Initial average pain scores of 7.7 and 4.7 in laminoplasty and laminectomy groups, respectively, improved to 3.2 and 4.4 for 57 percent and 8 percent improvements, respectively. Thus, although laminoplasty patients had worse pain symptoms preoperatively, they demonstrated more substantial improvements and a lower overall level of pain postoperatively. Additionally, the strongest predictor of pain postoperatively among laminectomy patients was the preopera-

tive level of pain. There was not a similar association in the laminoplasty group.

Although the Nurick grade, pain symptoms, and signs of myelopathy such as weakness, sensation, and gait change improved more among laminoplasty patients, the Prolo economic-functional outcome scores demonstrated similar results with 10 of 20 patients and 10 of 22 patients with good or excellent outcome in the laminoplasty and laminectomy groups, respectively. We believe these outcomes are due to the high proportion of individuals either retired or disabled in both groups (laminoplasty, 13 of 20 and laminectomy, 12 of 22), dramatically lowering the Prolo scores. Those disabled were more likely to be older and in labor-intensive jobs.

Neck stiffness has been frequently cited as a postoperative problem in laminoplasty. Hirabayashi and Yoshida found a limitation of approximately 50 percent in range-of-motion.[19,52] Thus, we were not surprised to find that neck range-of-motion was limited in laminoplasty patients in our series. Extension and bending were affected the most (p=.0002 and p=.009, respectively, compared to laminectomy), although there were also reductions in flexion and rotation. The degree of limitation of activities, however, was not found to be functionally limiting and subjectively neck stiffness was not a frequently cited problem. Only one patient believed that neck stiffness interfered with his daily activities.

Neck stiffness following laminoplasty may serve a protective function. The stability of the spine following laminoplasty has been examined in biomechanical studies comparing cervical laminoplasty with laminectomy.[38,51] Nowinski et al. examined nine cadaveric specimens after multilevel laminoplasty or laminectomy had been performed.[37] Cervical spine levels 2 to 7 were tested with physiologic loading. Cervical laminectomy with 25 percent or more facetectomy resulted in highly significant increase in cervical motion for all motions compared to the intact controls. With the numbers available, cervical laminoplasty was not significantly different from the intact control, except for a marginal increase in axial torsion. This limitation of mobility can prevent late instability and neurological deterioration.

Neck and shoulder pain have been reported to occur at a higher rate postoperatively in laminoplasty patients. The difference in axial symptoms between our groups, however, was not significant.

Transient neurological worsening occurred in 2 laminoplasty patients and none of the laminectomy patients. Cervical 5 and 6 neuropraxia occurred in these two patients. One patient demonstrated complete recovery within 11 months, and another by 32 months. This phenomenon of post operative nerve root palsy occurring within several days of the operation is a well-documented problem. Cervical 5 and 6 appear to be the most commonly affected, and the injury usually motor-dominant. In Hirabayashi's series of 90 laminoplasties, seven patients had transient weakness in cervical 5 and 6 motor elements- four on the open side and three on the hinged side.[20] Transient paresis in the cervical 5 distribution, cervical 6 distribution, or both has also been noted by Yoshida (3 of 40 cases)[52], Yonenobu (3 of 42)[51], and O'Brien's (1 of 10).[39] The cause of this problem has not been elucidated, although tethering of the nerve roots with posterior migration of the cord has been suggested.[51] We slowly elevate the laminar door during the laminoplasty in order to avoid excessive traction of the nerve roots as recommended by Aita et al.[1]

Post-laminectomy instability or kyphosis occurred with alarming frequency among laminectomy patients. One required an operation and two were planning for operative intervention. The prevalence of post-laminectomy kyphosis, a challenging problem to treat because of the lack of posterior elements, varies in the literature.[25,27,28,43,53] No instances of instability occurred among laminoplasty patients. The etiology of post-laminectomy deformity is primarily mechanical, from loss of posterior support. As little as 25 percent facetectomy significantly increases motion in all directions[37], and 50 percent facetectomy allows visualization of 3-5 millimeters of the nerve root.[41] The amount of facet resection could have played a critical determinant in those cases with instability. Those with instability or deformity tended to have higher pain scores and Nurick grade, but a statistical correlation with outcome could not be determined from these small numbers.

Recurrence of myelopathy may occur with closure of the laminar door. We have switched to using rib allograft after closure of a laminar door in one patient. Half of our patients were treated with this method and this complication has not occurred. A variety of methods to stabilize the open-door have been described, and we recommend supplementing the standard open-door technique with additional modifications.[24,32,36,39,45]

Currently the senior author (CRC) secures the rib allograft with a suture which is threaded through a hole in the lateral mass, the medullary canal of the rib graft, and through a hole in the lamina and then tied. Additionally, laminoplasty does have the disadvantage of making decompression along the facet joint along the hinged side more difficult. This may be a consideration in patients with bilateral radiculopathy, although a keyhole foraminotomy may be performed to decompress a particular nerve root on the hinged side. We have not performed this procedure and believe that decompression alone is usually adequate.

Of the many reports of laminoplasty outcome, most have demonstrated substantial neurological recovery.[3,13-15,18-20,29-31,35,42,47] These studies have included or have been composed entirely of patients with ossification of the posterior longitudinal ligament. Some studies have indicated a different natural history and operative outcome in patients with ossification of the posterior longitudinal ligament,[26,36] and thus these patients were excluded. Additionally, the Japanese Orthopaedic Association scoring system for myelopathy, often present in the laminoplasty literature, is difficult to apply to Western patients. Herkowitz, using his own grading system, compared anterior cervical arthrodesis, laminectomy, and laminoplasty for multi-level spondylotic radiculopathy in 45 patients with a minimum 2 year follow-up and concluded that laminoplasty was an effective alternative to anterior cervical fusion and laminectomy.[14] The complications of anterior arthrodesis and laminectomy could be avoided with laminoplasty. Patients with laminectomy had the poorest results.

Our series, too, demonstrated superior results with laminoplasty. We believe that laminoplasty is a safe and efficacious procedure in the management of selected patients with multiple level cervical spondylotic myelopathy or radiculopathy. Modified Nurick grades of myelopathy, pain scores, subjective and objective return of sensation and motor strength, and gait alterations demonstrated more substantial improvements in laminoplasty patients, with fewer late complications, than laminectomy. This must be balanced with the potential loss of cervical range-of-motion, neck stiffness, and the potential for transient neurologic injury encountered with laminoplasty. Additionally, several variables including preoperative Nurick grade, level of pain, postoperative Pavlov ratio, and space-available-for-the-cord can potentially indicate postoperative outcome and neurological recovery.

BIBLIOGRAPHY

1. **Aita I, Hayashi K, Wadano Y, Yabuki.** Posterior Movement and Enlargement of the Spinal Cord After Cervical Laminoplasty. *Spine*., 80B: 33-37, 1998.
2. **Alvisi C, Borromei A, Cerisoli M, and Giulioni M.** Lomg-term Evaluation of Cervical Spine Disorders Following Laminectomy. *J of Neurosurgical Sciences*., 32(3): 109-112, 1988.
3. **Baba H, Uchida K, Maezawa Y, Furusawa N, Wada M, Imura S.** Three-dimensional Computed Tomography for Evaluation of Cervical Spinal Canal Enlargement After En-bloc Open-door Laminoplasty. *Spinal Cord*., 35(10):674-679, 1997
4. **Callahan RA, Johnson RM, Margolis RN, Keggi KJ, Albright JA, Southwick WO.** Cervical Facet Fusion for Control of Instability Following Laminectomy. *J Bone Joint Surg*., 59A: 991-1002, 1977.
5. **Cattell HS, Clark GL.** Cervical Kyphosis and Instability Following Multiple Laminectomies in Children. *J Bone Joint Surg*., 49A: 713-20, 1967.
6. **Clark CR.** Indications and Surgical Management of Cervical Myelopathy. *Sem Spine Surg*., 1(4): 254-261, 1989.
7. **Clark E, Robinson PK.** Cervical Myelopathy: A Complication of Cervical Spondylosis. *Brain*., 79: 483-487, 1956.
8. **Emery S, Bohlman HH, Bolesta M, and Jones P.** Anterior Cervical Decompression and Arthrodesis for the Treatment of Cervical Spondylotic Myelopathy: Two to Seventeen-Year Follow-up. *J Bone and Joint Surg*., 80-A: 941-951, 1998.
9. **Emery SE, Smith MD, Bohlman HH.** Upper-airway Obstruction After Multiple Level Corpectomy for Myelopathy. *J Bone Joint Surg*., 73-A: 544-551, 1991.
10. **Farey ID, McAfee PC, Davis RF,** et al. Pseudoarthrosis of the Cervical Spine After Anterior Arthrodesis: Treatment by Posterior Nerve-root Decompression, Stabilization, and Arthrodesis. *J Bone and Joint Surg*., 72-A: 1171-1177, 1990.
11. **Fernyhough JC, White JI, LaRocca H.** Fusion Rates in Multilevel Cervical Spondylosis Comparing Allograft Fibula with Autograft Fibula in 126 Patients. *Spine*., 16: s561-564, 1991.
12. **Gregorius FK, Estrin T, Crandall PH.** Cervical Spondylotic Radiculopathy and Myelopathy. A Long-term Follow-up Study. *Arch of Neurology*., 33(9): 618-625, 1976.
13. **Hase H, Watanabe T, Hirasawa Y,** et al. Bilateral Open Laminoplasty Using Cervical Laminas for Cervical Myelopathy. *Spine.*, 16(11): 1269-1276, 1991.
14. **Herkowitz HN.** A Comparison of Anterior Cervical Fusion, Cervical Laminectomy, and Cervical Laminoplasty for the Surgical Management of Multiple Level Spondylotic Radiculopathy. *Spine*., 13: 774-780, 1988.
15. **Herkowitz HN.** Surgical Management of Cervical Disc Disease: "Open-Door" Laminoplasty. *Seminars in Spine Surgery*., 1(4): 245-253, 1989.
16. **Herkowitz HN.** The Surgical Management of Cervical Spondylotic Radiculopathy and Myelopathy. *Clin. Orthop*., 239: 94-108, 1989.
17. **Herman JM, Sonntag VKH.** Cervical Corpectomy and Plate Fixation For Post-laminectomy Kyphosis. *J Neurosurg*., 80: 963-970, 1994.
18. **Hirabyashi K.** Expansive Open-Door Laminoplasty for Cervical Spondylotic Myelopathy. *Shujutu.*, 32: 1159-1163, 1978.

19. **Hiarabayashi K, Bohlman HH.** Multilevel Cervical Spondylosis. Laminoplasty Versus Anterior Decompression. *Spine*., 20(15): 1732-1734, 1995.
20. **Hirabyashi K, and Satomi K.** Operative Procedure and Results of Open-Door Laminoplasty. *Spine*., 13: 870-876, 1988.
21. **Hosono N, Yonenobu K, Ono K.** Neck and Shoulder Pain After Laminoplasty: a Noticeable Complication. *Spine*., 21(7): 1969-1973, 1996.
22. **Hukudu S, Ogata M, Mochizuki T, and Sichikawa K.** Laminectomy Versus Laminoplasty for Cervical Myelopathy: Brief Report. *J Bone Joint Surg*., 70B:325-326, 1988.
23. **Inoue A, Ikata T, and Katoh S.** Spinal Deformity Following Surgery for Spinal Cord Tumors and Tumorous Lesions: Analysis Based on an Assessment of Spinal Functional Curve. *Spinal Cord*., 34(9): 53-62, 1996.
24. **Itoh T, Tsuji H.** Technical Improvements and Results of Laminoplasty for Compressive Myelopathy in the Cervical Spine. *Spine*., 10: 729-736, 1985.
25. **Kamioka Y, Yamamoto H, Tani T, Ishida K, and Sawamoto T.** Postoperative Instability of Cervical OPLL and Cervical Radiculomyelopathy. *Spine*., 14(11);1177-1183, 1989.
26. **Kawai, Sunago K, Doi k, Saik M, Taguchi T.** Cervical Laminoplasty (Hattori's Method): Procedure and Follow-up Results. *Spine*., 13:1245-1250, 1998.
27. **Lonstein JE.** Postlaminectomy Kyphosis. *Clin. Orthop*., 128: 93-100, 1977.
28. **Lonstein JE, Winter RB, Moe JH, Bradford DS, Chou SN, Pinto WC.** Neurologic Deficits Secondary to Spinal Deformity: A Review of the Literature and Report of Forty-Three Cases. *Spine*., 5: 551-555, 1980.
29. **Kimura I, Oh-Hama M, Shingu H, Yonago K.** Cervical Myelopathy Treated by Canal-Expansive Laminoplasty. *J Bone Joint Surg*., 66-A: 914-920, 1984.
30. **Kimura I, Shingu H, Nasu Y,** et al. Long-term Follow-up of Cervical Spondylotic Myelopathy Treated By Canal-Expansive Laminoplasty. *J Bone Joint Surg*., 77B: 956-961, 1995.
31. **Kohno K, Kumon Y, Oka Y, Matsui S, Ohue S, Sakaki S.** Evaluation of Prognostic Factors Following Expansive laminoplasty for Cervical Spinal Stenotic Myelopathy. *Surg Neurology*., 48(3): 237-245, 1997.
32. **Lee TT, Manzano GR, Green BA.** Modified Open-door Cervical Expansive Laminoplasty For Cervical Spondylotic Myelopathy: Operative Technique, Outcome, and Predictors for Gait Improvement. *J Neurosurg*., 86(1): 64-68, 1997.
33. **Lees F, Aldren JW.** Natural History and Prognosis of Cervical Spondylosis. *Br Med J*., 95: 1607-1610, 1972.
34. **Mikawa Y, Shikara J, Yamamuro T.** Spinal Deformity and Instability After Multilevel Cervical Laminectomy. *Spine*., 12: 6-11, 1987.
35. **Nagata K, Ohashi T, Abe J, Morita M, Inoue A.** Cervical Myelopathy in Elderly Patients: Clinical Results and MRI Findings Before and After Decompression Surgery. *Spinal Cord*., 34(4): 220-226, 1996.
36. **Nakano N, Nakano T, Nakano K.** Comparison of the Results of Laminectomy and Open-Door Laminoplasty for Cervical Spondylotic Myeloradiculopathy and Ossification of the Posterior Longitudinal Ligament. *Spine*., 13: 792-794, 1988.
37. **Nowinski GP, Vesarius H, Dipl-Ing, Nolte LP,** et al. A Biomechanical Comparison of Cervical Laminaplasty and Cervical Facetectomy with Progressive Facetectomy. *Spine*., 18: 1995-2004, 1993.
38. **Nurick S.** The Natural history and the Results of Surgical Treatment of the Spinal Cord Disorder Associated with Cervical Spondylosis. *Brain*., 95: 101-108, 1972.
39. **O'Brien MF, Petersen D, Casey AT, Crockard H.** A Novel Technique for Laminoplasty Augmentation of Spinal Canal Area Using Titanium Miniplate Stabilization: A Computerized Morphometric Analysis. *Spine*., 21(4): 474-483, 1996.
40. **Prolo DJ, Oklund SA, Butcher M.** Toward Uniformity in Evaluating Results of Lumbar Spine Operations. A Paradigm Applied to Postoperative Lumbar Interbody Fusions. *Spine*., 11(16): 601-606, 1986.
41. **Raynor RB, Pugh J, Shapiro I.** Cervical Faccetectomy and its Effect on Spine Strength. *J Neurosurg*., 63: 278-282, 1985.
42. **Satomi K, Nishu Y, Kohno T, Hirabyashi K.** Long-Term Follow-up Studies of Open-Door Expansive Laminoplasty for Cervical Stenotic Myelopathy. *Spine*., 19: 507-510, 1994.
43. **Sim FH, Svien HJ, Bickel WH, Janes JM.** Swan-neck Deformity Following Extensive Cervical Laminectomy. *J Bone Joint Surg*., 56-A: 564-580, 1974.
44. S**ymon L, Lavender P.** The Surgical Treatment of Cervical Spondylotic Myelopathy. *Neurology*., 17: 117-127, 1967.
45. **Tomita K, Nomura S, Umeda S,** et al. Cervical Laminoplasty to Enlarge the Spinal Canal Multilevel Ossification of the Posterior Longitudinal Ligament With Myelopathy. *Arch Orthop Trauma Surg*., 107: 148-153, 1988.

46. **Torg JS, Pavlov H, Genuario SE,** et al. Neuropraxia of the Cervical Spinal Cord with Transient Quadriplegia. *J Bone and Joint Surg*., 68-A: 1354-1370, 1969.
47. **Tsuji H.** Laminoplasty for Patients With Compressive Myelopathy Due to So-called Spinal Canal Stenosis in Cervical and Thoracic Regions *Spine*., 7: 28-34, 1982.
48. **White AA, Panjabi MM.** Biomechanical Considerations in the Surgical Management of Cervical Spondylotic Myelopathy. *Spine*., 7: 856-860, 1988.
49. **Yonenobu K, Hosono N, Iwasaki M,** et al. Laminoplasty Versus Subtotal Corpectomy. *Spine*., 17: 1281-1284, 1992.
50. **Yonenobu K, Hosono N, Iwasaki M, Masatoshi A, Ono K.** Neurologic Complications of Surgery for Compressive Myelopathy. *Spine*., 16: 1277-1282, 1991.
51. **Yonenobu K, Fuji T, Okada K, Fujiwara K, Yamashita K, Ono K.** Causes of Neurologic Deterioration Following Surgical Treatment of Cervical Myelopathy. *Spine*., 11: 818-822, 1986.
52. **Yoshida M, Otani K, Shibasaki K, and Ueda S.** Expansive Laminoplasty with Reattachment of Spinous Process and Extensor Musculature for Cervical Myelopathy. *Spine*., 17: 491-497, 1992..
53. **Zdelblick TA, Bohlman HH.** Cervical Kyphosis and Myelopathy. *J Bone and Joint*., 71-A: 170-182, 1989.

HIGH-GRADE SARCOMAS MIMICKING TRAUMATIC INTRAMUSCULAR HEMATOMAS: A REPORT OF THREE CASES

Pablo Gomez MD and Jose Morcuende MD, PhD

ABSTRACT

We reported on three patients with high-grade soft-tissue sarcomas mimicking traumatic intramuscular hematomas. Patients had an episode of trauma to the extremity, and after initial clinical and imaging evaluations they were considered to have muscular hematomas. The lesions increased in size over time, leading to further evaluations that demonstrated the actual diagnosis. We conducted a retrospective review of the clinical findings, magnetic resonance images, and computed tomography scans to assess characteristics that will help in the differential diagnosis.

We conclude that intramuscular hematomas following trauma should be approached with a high degree of clinical suspicion. MRI analysis can be used as an important diagnostic tool, but the results must be seen in the context of the clinical history. MRI is not sensitive or specific enough to rule out malignancy. The diagnosis of a high-grade sarcoma must be considered in these patients and any doubt should be resolved with a biopsy.

INTRODUCTION

Sarcomas comprise approximately one percent of malignant tumors and represent a significant diagnostic and therapeutic challenge.[14] The incidence of soft-tissue sarcomas in the United States ranges from 20 to 30 per 1,000,000 persons, approximately 6,000 new cases per year.[13] Soft-tissue sarcomas are a heterogeneous group of tumors that arise from tissue of mesenchymal origin and are characterized by infiltrative local growth. The metastatic spread of sarcomas is mainly hematogenous to the lungs, although lymphatic spread may occur. Soft-tissue sarcomas can occur at any site throughout the body.[5] Almost 45 percent of all soft tissue sarcomas are found in the extremities, especially in the lower limb.[15]

Department of Orthopaedics and Rehabilitation
University of Iowa, Iowa City, Iowa

Address correspondence to:
Jose A. Morcuende, MD, PhD
20 Hawkins Drive
Iowa City, IA 52242
(319) 384-8041 Tel
(319) 353-7919 Fax
jose-morcuende@uiowa.edu

Patients usually present with a complaint of a lump or growth, with or without pain. However, there are some instances in which the patient will present after moderate trauma to the extremity. These cases are very challenging since the injury symptoms and imaging studies could mask the underlying tumor. We present the cases of three patients with high-grade sarcomas who initially suffered moderate traumas to their extremities and were initially diagnosed with intramuscular hematomas by clinical and imaging studies.

CASE REPORTS

Case 1

A 53-year-old white female fell on the lateral aspect of her right thigh while working. The next morning she noticed discomfort in the medial aspect of her thigh, near the groin area. She consulted a local family physician who diagnosed a "pulled muscle" and treated her with pain medication and local heat. This treatment protocol did not relieve her discomfort and she consulted again four days later. At that time, clinical examination demonstrated pain to palpation and slight swelling of the upper medial thigh without evidence of soft-tissue mass. Continuation of the same treatment was recommend.

Five weeks later the patient worsened and a radiograph and a CT scan of the thigh were ordered. The CT was reported as showing a bulky mass involving all adductor magnus compartments, suspicious for an organized hematoma without clear evidence of ossification or calcification. An MRI was then ordered which was read as showing a 6 x 8 centimeter soft-tissue mass partially replacing the adductor musculature proximally and medially, with moderately high T2 signal and generally low T1 signal with scattered areas of increased signal intensity. This MRI was interpreted as a sub-acute hematoma (Figure 1). A vascular Doppler study to rule out an aneurysm was performed and interpreted as normal. Resting and local heat were again recommended, but there was no improvement in the pain or swelling.

Symptoms continued to worsen and the pain became uncontrollable even with morphine administration. The patient consulted again and was then referred to radiology for angiography, which demonstrated a highly vascularized mass with malignancy characteristics. Four

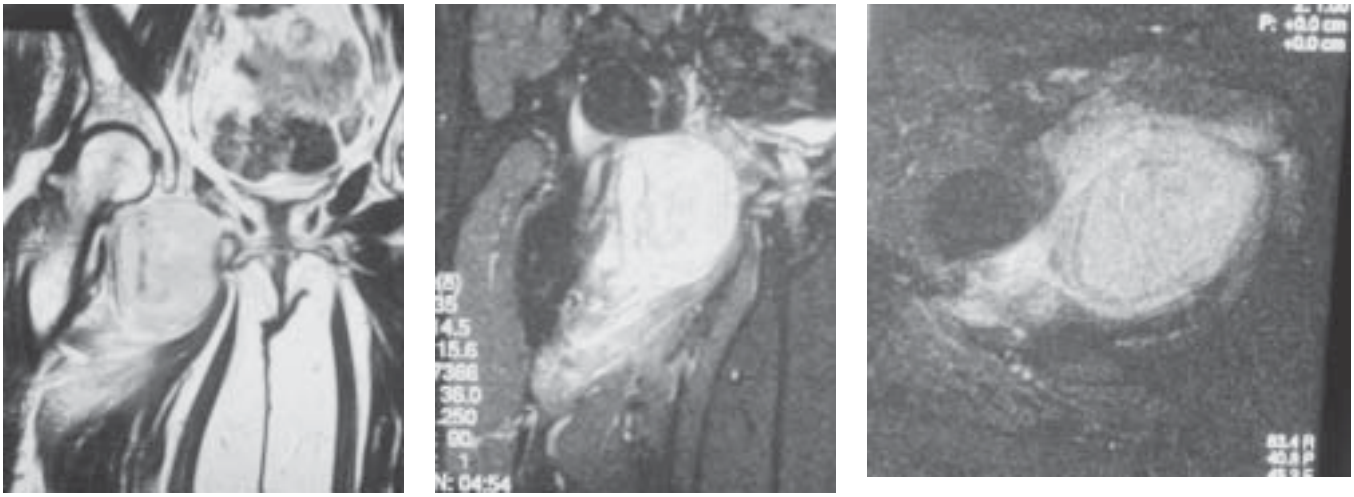

Figure 1. MRI coronal and axial images of the upper thigh—note a 6x8 centimeter soft tissue mass in the medial aspect of the upper thigh, replacing part of the adductor musculature, in contact with the hip joint capsule and obturator foramen. It shows moderately high T2 signal, with low T1 signal, and scattered areas of increased T1 signal. The mass is well circumscribed and there is edema in the musculature surrounding it. The sciatic nerve and vascular structures are spared.

months after the initial trauma she was referred to our institution for evaluation and further management.

Physical exam revealed a 15 x 10 centimeter, firm, immobile mass in the medial aspect of the right thigh, very painful to examination, with no evidence of neurovascular compromise of the extremity. An MRI was obtained that showed an 11.9 x 9.1 x 4.5 centimeter mass in the proximal medial thigh with extension to the obturator foramen. She underwent wide surgical resection of the tumor. At surgery, a 20 x 16 x 9 centimeter encapsulated mass containing thick gelatinous gray material was found. The mass was adherent to the medial aspect of the hip joint capsule and to the obturator foramen. The resected specimen was sent for pathologic analysis and demonstrated a tumor with moderate cellular proliferation of spindle-shaped cells, extremely pleomorphic. The histological diagnosis was a leiomyosarcoma. The surgical procedure resolved the pain. The patient received postoperative radiation therapy and her recovery was good, without documented metastasis by the time of this writing.

Case 2

A healthy 44-year-old female suffered trauma to her left arm, falling on her outstretched hand while working. After an initial evaluation by her local physician she was diagnosed with a "muscle strain with a concomitant hematoma." The patient started physical therapy, however there was no improvement of her symptoms and she again consulted the physician a week later. An MRI was then ordered which showed a well-circumscribed mass not attached to the humerus along the lateral border of the left biceps brachii muscle, measuring 14.5 x 6.5 x 5 centimeters, with an intermediate signal in T1, and a high signal in T2. The radiologist and the attending physician interpreted the MRI as a muscular hematoma. Conservative care was ordered with continued physical therapy.

Six months after the traumatic episode she had no improvement, and the patient was referred to an orthopedic surgeon in another institution for evaluation. A new MRI was interpreted as being compatible with a soft-tissue sarcoma, and the patient was referred for treatment to our institution.

When the patient arrived, she presented with mild pain in her left upper arm, with numbness in the hand when outstretched. The physical examination showed a 15 centimeter, firm, non-tender soft-tissue mass in the left upper arm along the biceps muscle that adhered to the subcutaneous tissue. The motor and sensory functions of the left upper extremity were normal. We performed a wide excisional biopsy and found a well-circumscribed soft-tissue mass located in the left biceps brachii muscle. The pathology sections showed a high-grade sarcoma with a fine vascular background. After the surgical resection, the patient recovered well and received radiation therapy with no relapses or documented metastases at the time this report was made.

Case 3

A 33-year-old male, without previous relevant medical or surgical history, kicked a vehicle with his left lower extremity and developed mild pain in his left thigh. Five months later, without improvement in his

symptoms and after noticing swelling in his thigh, he consulted an orthopaedic surgeon. Based on the trauma history and minimal swelling with no other significant findings, the physician diagnosed an "adductor and hamstring muscular sprain." He also ordered an MRI that was performed three days later. The findings reported by the radiologist were of a 9 x 9.8 x 6.8 centimeter mass isointense to muscle in T1, hyperintense to muscle in T2-weighted signal, within the region of the adductor magnus with some extension into the adjacent biceps femoris, and some increased T2 signal within the vastus medialis. The radiologist also reported a hemorrhagic component to the lesion and areas of hemosiderin with low T1, low T2 signal characteristics. Based on the MRI images and the history of trauma the patient was referred to physical therapy, with ultrasound and massage.

Fifteen days later the patient returned with worsening in his symptoms and a new MRI was performed. At that time, the mass measured 11 x 11.9 centimeters and the radiologist reported the same previous findings, but recommended a biopsy since the MRI could not exclude aggressive sarcomatous lesions. The patient was then referred for treatment to our institution.

In the physical examination we found a very large, tender mass extending from the medial to the posterior aspect of the left thigh, along with left inguinal adenopathy. Gross sensory function distal to the knee was diminished. Vascular examination was normal. CT survey of the chest, abdomen and pelvis was performed and multiple soft-tissue nodules in the lungs and mediastinum were found. Subsequently an ultrasound-guided needle biopsy of the left thigh mass reported a poorly differentiated sarcoma. An excisional biopsy was then done with the diagnosis of a pleomorphic rhabdomyosarcoma. The patient started chemotherapy with four cycles of Adriamycin and cisplatin, with mild response. She was changed to a regimen of doxorubicin, ifosfamide, dicarbazine (DTIC) and mesna.

Seven months after the diagnosis a wide, limb-sparing resection of the tumor was performed. A large, encapsulated mass involving the medial and posterior compartment of the thigh was found along with severe compression of the sciatic nerve. The patient responded to chemotherapy, and at the time of this report the size of the lung metastases was subsiding.

DISCUSSION

Imaging provides the clinician with crucial information in the diagnosis, staging, treatment planning, treatment evaluation, and post-treatment assessment of patients with soft-tissue sarcoma.

Thanks to high-contrast tissue resolution and multiplanar imaging capability, MRI remains the gold standard for evaluation of most soft-tissues lesions. However, the sensitivity for diagnosis and grading remains controversial in the literature. MRI is not able to predict malignancy, and the findings commonly associated with malignant lesions frequently overlap with those seen in benign tumors.[4] Furthermore, a significant percentage of malignant lesions may appear deceptively benign with the currently used criteria.[9,10] MRI also performs poorly in the histological classification of soft-tissue tumors.[10] This is because MRI images provide only indirect information about tumor histology by showing signal intensities related to some physicochemical properties of the tumor components, and consequently reflect gross morphology of the lesion rather than underlying histology. Finally, the time-dependent changes of the tumors (as a consequence of intratumor necrosis and/or bleeding), makes the differentiation process even more difficult.

Differentiating between malignant and benign soft-tissue lesions has proven to be a difficult task even with the advantage of MRI. Soft-tissue tumors grow in a centrifugal manner until resistance is met. The barriers in soft tissues consist of major fibrous septa and the origins and insertions of muscles. Growth tends to occur in the plane of least resistance, which in soft-tissue tumors occurs in a longitudinal fashion (i.e., in the compartment of origin). The host responds to tumor growth by creating a reactive fibrovascular tissue that forms a limiting capsule in benign lesions. Aggressive lesions, however, compress the host reactive tissue into a pseudocapsule containing finger-like or nodular tumoral foci called satellite lesions. In highly aggressive lesions, tumoral foci (skip metastases) are found beyond the reactive zone within the compartment of origin.[3]

As we mentioned, MRI usefulness as a valid predictor of malignancy in soft-tissue lesions is debatable. However there are some individual parameters for predicting malignancy in MRI images: 1) Intensity and homogeneity of the MR signal on different pulse sequences; 2) High-signal intensity on T2-weighted images; and 3) Homogeneity on T1-weighted images. These are sensitive parameters but present with an unacceptably low specificity. Indeed, high-grade malignant soft-tissue tumors may show low-to-intermediate signal intensity on T2-weighted images because of an increased nucleocytoplasmic index and an altered cellular and interstitial components proportion, both resulting in a decrease of intra- and extra-cellular water.[1,2] Hermann et al. reported that changes in homogeneity (from homogeneous on T1- weighted images to heterogeneous on T2-weighted images) and the presence of low-signal intratumoral septations have a sensitivity of 72 and 80 percent and a specificity of 87 and 91 percent, respectively, in predicting malignancy.[7] Other signs

TABLE 1
Signal Intensities on T1- and T2-weighted Images

High signal intensity on T1-weighted images plus intermediate signal intensity on T2-weighted images	Lipoma Liposarcoma Lipoblastoma Hibernoma Elastofibroma Fibrolipohamartoma Metastasis of melanoma (melanin) Clear cell sarcoma (melanin)
High signal intensity on T1-weighted images plus high signal intensity on T2-weighted images	Hemangioma Lymphangioma Subacute hemangioma Small arteriovenous malformation
Low signal intensity on T1-weighted images plus high signal intensity on T2-weighted images	Cyst Myxoma Myxoid liposarcoma Sarcoma
Low to intermediate signal intensity on T1-weighted images plus low signal intensity on T2-weighted images	Desmoid and other fibromatoses Pigmented villonodular synovitis Morton's neuroma Fibrolipohamartoma Giant cell tumor of tendon sheath *Acute hematoma (few days)* *Old hematoma* Xanthoma High-flow arteriovenous malformation Mineralized mass Scar tissue Amyloidosis Granuloma annulare *High-grade malignancies*
Intermediate signal intensity on T1-weighted images plus high signal intensity on T2-weighted images	Neurogenic tumor Desmoid

related to malignancy include the presence of tumor necrosis, bone or neurovascular involvement, mean diameter of more than 66 millimeters, and irregular or partially irregular margins.[4] Finally, no predominant enhancement pattern is characteristic of benign or malignant lesions. Unfortunately, as deduced from the previous data, none of these parameters is reliable enough to precisely assess the benign or malignant condition of a lesion on MRI images.

MRI images of acute hematomas show low-to-intermediate signal intensity on T1, and low signal on T2. These same findings are seen in desmoids and other fibromatoses, pigmented villonodular synovitis, fibrolipohamartomas, giant cell tumors of the tendon sheath, xanthomas, high-flow arteriovenous malformations, mineralized masses, scar tissue, amyloidosis, granuloma annulare and high-grade sarcomas. Intratumoral hemorrhage is a rare finding that can be observed in benign and malignant lesions, and is difficult to differentiate from non-tumoral soft-tissue hematoma. Moulton et al.[11] evaluated 23 benign and 5 malignant tumors with hemorrhage in a total of 225 masses. Hemorrhage was diagnosed on the basis of high signal on T1-weighted images, coupled with low or high signal on T2-weighted images, provided the tissue was not isointense to fat in all sequences. A low-signal hemosiderin rim was interpreted as evidence of prior hemorrhage. In Table 1 we show the MRI image characteristics of some of the more common soft-tissue lesions and hematomas.

There are three reports in the literature of high-grade sarcomas mimicking hematomas in the extremities. Ogose et al.[12] reported an extra-skeletal Ewing sarcoma mimicking a traumatic hematoma in a 16-year-old boy with a history of recurrent hematoma in the thigh. Imaizumi et al.,[8] reported the cases of six patients with soft-tissue sarcomas who were diagnosed with traumatic hematomas. These lesions were characterized by rapid growth. Interestingly, the cytology of percutaneous aspiration was negative for malignancy in five of the six patients, and the final diagnosis was only made after an open biopsy several weeks later. Finally, Engel et al.,[6] reported on a young man who received trauma to his thigh that was initially diagnosed as an organizing hematoma of the adductor compartment. At surgery, evidence of a tumor was found that was histologically identified as a synovial sarcoma.

In their study[8], Imaizumi et al. retrospectively reviewed the history and imaging studies and concluded that MRI was a reliable diagnostic tool for the differentiation between hematoma and sarcoma. However, as presented in this report, the MRI images can be very similar in both pathologies, and high-grade soft-tissue sarcoma cases presenting after some degree of trauma could easily be mistaken initially as hematomas related to that recent injury.

We conclude that intramuscular hematomas following trauma should be approached with a high degree of clinical suspicion. MRI analysis can be used as an important diagnostic tool, but the results must be seen in the context of the clinical history. MRI is not sensitive or specific enough to rule out malignancy. The diagnosis of a high-grade sarcoma must be considered in these patients and any doubt should be resolved with a biopsy.

BIBLIOGRAPHY

1. **Berquist TH, Ehman RL, King BF, Hodgman CG, Ilstrup DM.** Value of MR imaging in differentiating benign from malignant soft-tissue masses: study of 95 lesions. *AJR Am J Roentgenol* 1990; 155(6): 1251-5.
2. **De Schepper A,** Grading and characterization of soft tissue tumors. Imaging of soft tissue tumors, ed. De Schepper A, (1997), Berlin Heidelberg New York: Springer. 127-139.
3. **De Schepper A, De Beuckeleer L.** Imaging of soft tissue tumors in the pediatric patient. *Semin Musculoskeletal Radiol* 1999; 3: 59-79.
4. **De Schepper AM, De Beuckeleer L, Vandevenne J, Somville J.** Magnetic resonance imaging of soft tissue tumors. *Eur. Radiol* 2000; 10: 213-222.
5. **Eilber FC, Rosen G, Nelson SD, Selch M, Dorey F, Eckardt J, Eilber FR.** High-grade extremity soft tissue sarcomas: factors predictive of local. *Annals of surgery* 2003; 237(2): p. 218.
6. **Engel C, Kelm J, Olinger A.** Blunt trauma in soccer. The initial manifestation of synovial sarcoma. *Zentralbl Chir.* 2001; 126(1):68-71.
7. **Hermann G, Abdelwahab I, Miller T, Klein M, Lewis M.** Tumour and tumour-like conditions of the soft tissue: magnetic resonance imaging features differentiating benign from malignant masses. *Br J Radiol* 1992; 65: 14-20.
8. **Imaizumi S, Morita T, Ogose A, Hotta T, Kobayashi H, Ito T, Hirata Y.** Soft tissue sarcoma mimicking chronic hematoma: value of magnetic resonance imaging in differential diagnosis. *J Orthop Sci.* 2002; 7(1): 33-7.
9. **Kransdorf M.** Benign soft tissue tumors in a large referral population: distribution of specific diagnoses by age, sex and location. *Am J Roentgenol* 1995; 164: 395-402.
10. **Kransdorf M.** Malignant soft tissue tumors in a large referral population distribution of specific diagnoses by age, sex and location. *Am J Roentgenol,* 1995; 164:129-134.
11 **Moulton JS, Blebea JS, Dunco DM, Braley SE, Bisset GS III, Emery KH.** MR imaging of soft-tissue masses: diagnostic efficacy and value of distinguishing between benign and malignant lesions. *AJR Am J Roentgenol* 1995;164(5):1191-9.
12. **Ogose A, Hotta T, Yamamura S, Shioya Y, Yazawa T.** Extraskeletal Ewing's sarcoma mimicking traumatic hematoma. *Arch Orthop Trauma Surg;* 118(3):172-3.
13. **O'Sullivan B, Pisters PW.** Staging and prognostic factor evaluation in soft tissue sarcoma. *Surg Oncol Clin N Am* 2003; 12(2):333-53.
14. **Rougraff B.** The diagnosis and management of soft tissue sarcomas of the extremities in the adult. *Current Problems in Cancer.* 1999;23:1-50.
15. **Weitz J, Antonescu CR, Brennan M.** Localized extremity soft tissue sarcoma: improved knowledge with unchanged survival over time. *J Clin Oncol,* 2003; 21 (14): p. 2719-25.

PARTICULATE DEBRIS OSTEOLYSIS SIMULATING MALIGNANT TUMOR

Richard A. Brand*, J. Lawrence Marsh†

ABSTRACT

Osteolysis induced by particulate debris from total joint implants is typically confined to bone and benign in radiographic appearance even when extensive. However, they can extend well beyond bone in which case they can simulate malignancies owing either to mass effects and pressure on adjacent tissues or owing to the radiographic appearance. We report two cases which presented as possible malignancy, and review the literature on extensive osteolysis. Recognition of this possibility may aid in interpretation of the clinical presentation and imaging studies.

INTRODUCTION

Harris et al. perhaps first described the appearance of osteolysis in association with total joint arthroplasty, and suggested that while the amount and location of the bone loss suggested tumor or infection, the radiographic appearance was not that of tumor.[4] They postulated the process might be caused by fragmented cement, although they recognized the cause was unknown. Since Willert, in 1977, established the existence of bone resorption from particulate debris[13], osteolysis has been progressively recognized as a long term complication from fragmented cement[6,11,14], high density polyethylene[11,15], and metal.[2,3]

The cases of osteolysis illustrated by Harris et al.[4] appeared entirely confined to bone. Huddleston reported a number of cases of femoral osteolysis in which there was expansion of the endosteal canal, but with a more or less distinct rim of surrounding bone.[5] Typically, osteolysis has been limited to bone even when extensive[7,8], although in some cases large cysts have formed adjacent to the implant.[9,10] In the vast majority of cases, distinguishing between typical osteolysis and tumor has been quite easily based upon the clinical presentation and radiographic appearances. However, in a rare case, these distinctions are not straightforward. We present two cases of particulate osteolysis, one of which presented with symptoms consistent with colon cancer and a large intrapelvic mass, and the other with radiographic signs consistent with malignancy.

CASE REPORT I

A 44 year old male machinist and farmer presented with a long history of right hip problems. At the age of 10 he had been kicked by a horse in the right hip. After recovery, he did well until his late twenties when he had increasing pain, leading to a total hip arthroplasty at age 29 in 1979. He initially did well, but began having increasing pain and in 1986 underwent a revision for loosening. He continued working at both occupations, but by 1994 experienced a return of groin pain limiting his heavy work. He then began having severe perirectal pain which resulted in his referral to a general surgeon. A large mass was discovered on colonoscopy. A CT scan was unrevealing owing to metal artifact, so the mass was biopsied transrectally. The biopsy revealed straw colored fluid rather than a solid mass, and about 150 cc was aspirated. This provided nearly immediate relief of the perirectal pain. However it recurred, so a repeat aspirate was performed, again with pain relief. The pain again returned, as well as groin pain, and he was referred to our institution. Rectal exam revealed large, tender mass on the right side. Plain radiographs revealed a loose threaded acetabular component with osteolysis about the femoral component (Figure 1A). Pelvic ultrasound revealed a large cystic mass approximately 7 cm in diameter. Hip aspiration with contrast revealed no evidence of infection but demonstrated the joint communicated with the intrapelvic cyst (Figure 1B). At the time of revision arthroplasty the patient had a large (approximately 6 cm diameter) medial acetabular wall defect communicating with the intrapelvic cyst. The cyst was decompressed through the medial wall defect but was not surgically approached from the pelvis. The wall defect was grafted behind a cage

*Clinical Orthopaedics and Related Research
Philadelphia, PA 19104
Work performed at The University of Iowa

†Department of Orthopaedic Surgery
The University of Iowa
Iowa City, IA 52242

Correspondence to:
Richard A. Brand, M.D.
Editor-in-Chief
Clinical Orthopaedics and Related Research
3550 Market St., Suite 220
Philadelphia, PA 19104
215-349-8375
dick-brand@clinorthop.org

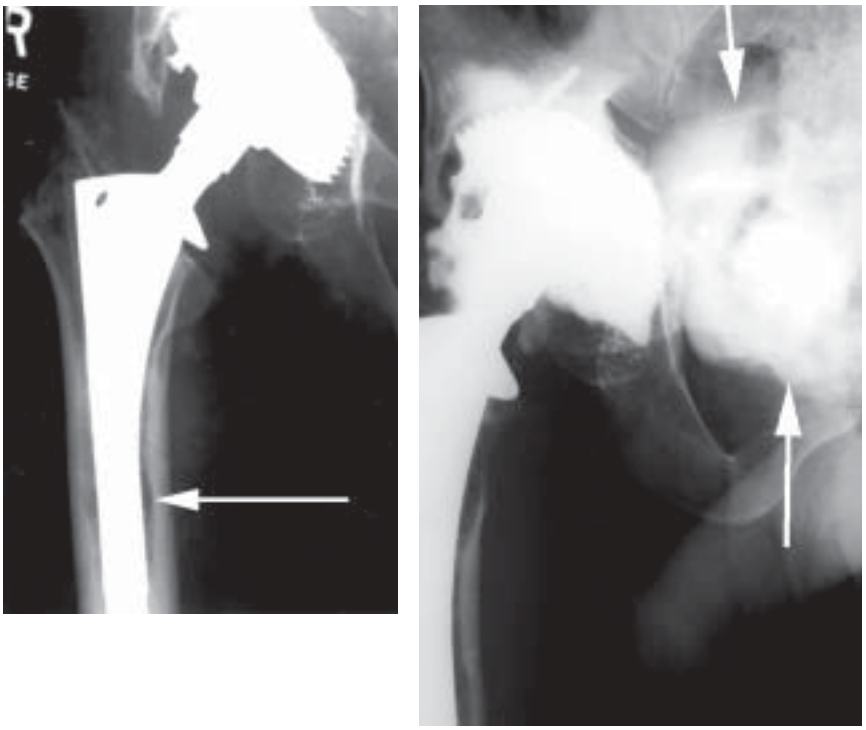

Figures 1A-B. Osteolytic lesion with intrapelvic mass. A: AP radiograph showing loose threaded acetabular component with medial migration and femoral endosteal osteolysis; B: Arthrogram showing communication with large intrapelvic cyst (arrows).

and a new polyethylene acetabular component cemented into the cup. The femoral component was not disturbed. Postoperatively, the patient's perirectal and groin pain disappeared. Cultures were negative. At four-year follow-up, he complained of modest groin pain not requiring walking assists, but had no recurrence of the perirectal pain.

CASE REPORT II

A 56 year old male presented with a long history of right hip pain which had worsened markedly in the previous two weeks with radiation down the leg to the foot and associated with tingling in the dorsum of the foot. He had a history of ankylosing spondylitis for which he had had a total hip replacement in 1982. A periprosthetic fracture in 1987 required an extensive revision of the femoral component with grafting, but he had done reasonably well walking with a cane until a few weeks prior to presentation. Within a few weeks, rapidly increasing buttock and radiating leg pain had forced him to use a walker, and then shortly thereafter a wheelchair. He was uncertain whether the buttock pain or the leg and foot pain was worse. Examination revealed an inability to walk owing to pain, non-localized but substantial tenderness about the buttock, lateral and anterior hip regions, and pain on very limited range of motion of the hip. He had a decreased right knee reflex, but symmetric ankle reflexes. Motor strength was believed symmetric although difficult to examine owing to pain. His sensation was intact to light touch. Radiographs revealed severe osteolysis along the extent of a long-stemmed femoral component. In addition, at the distal end of the stem he had an outer cortical lesion medially which did not appear to arise from the endosteal canal and which was associated with periosteal elevation simulating a Codman's triangle (Figure 2A) and soft tissue extension (Figure 2B). This lesion was separate from the other signs of osteolysis. Owing to the malignant appearance of this lesion, we performed a workup for malignancy including chest and abdominal CT. The chest CT was negative, but the abdominal CT revealed a renal mass and a large intrapelvic mass (Figure 2C) on the right side at the level of the quadrilateral plate and extending to the level of the body of S1. Ultrasound confirmed the former to be a renal cyst, and a CT-guided biopsy revealed the latter to be a cystic lesion with serosanguinous fluid. An open biopsy of the distal femoral lesion revealed a histiocytic reaction with polarizable debris. The patient was treated by femoral revision utilizing an allograft femoral composite combined with distal impaction grafting. The acetabular component was well fixed. The intrapelvic mass was decompressed through an extensive posterior column defect. The defect was grafted and reinforced with a pelvic reconstruction plate. The surgery immediately relieved his radicular pain, and he remained pain-free through three months of follow-up.

DISCUSSION

The typical case of osteolysis associated with particulate debris in total joint arthroplasty is confined to the bone, and the scalloped lytic endosteal lesions within the femoral canal or within the innominate bone but without surrounding bony reaction are readily diagnosed. Rarely, however, the lesion will present with findings which raise suspicion for malignancy either because of a large pelvic[7] or intrapelvic[10] mass, or because of a radiographic appearance consistent with malignancy.[1,12] In the case of Mak et al.[10] the patient presented with a pelvic mass presumed to be an ovarian tumor,

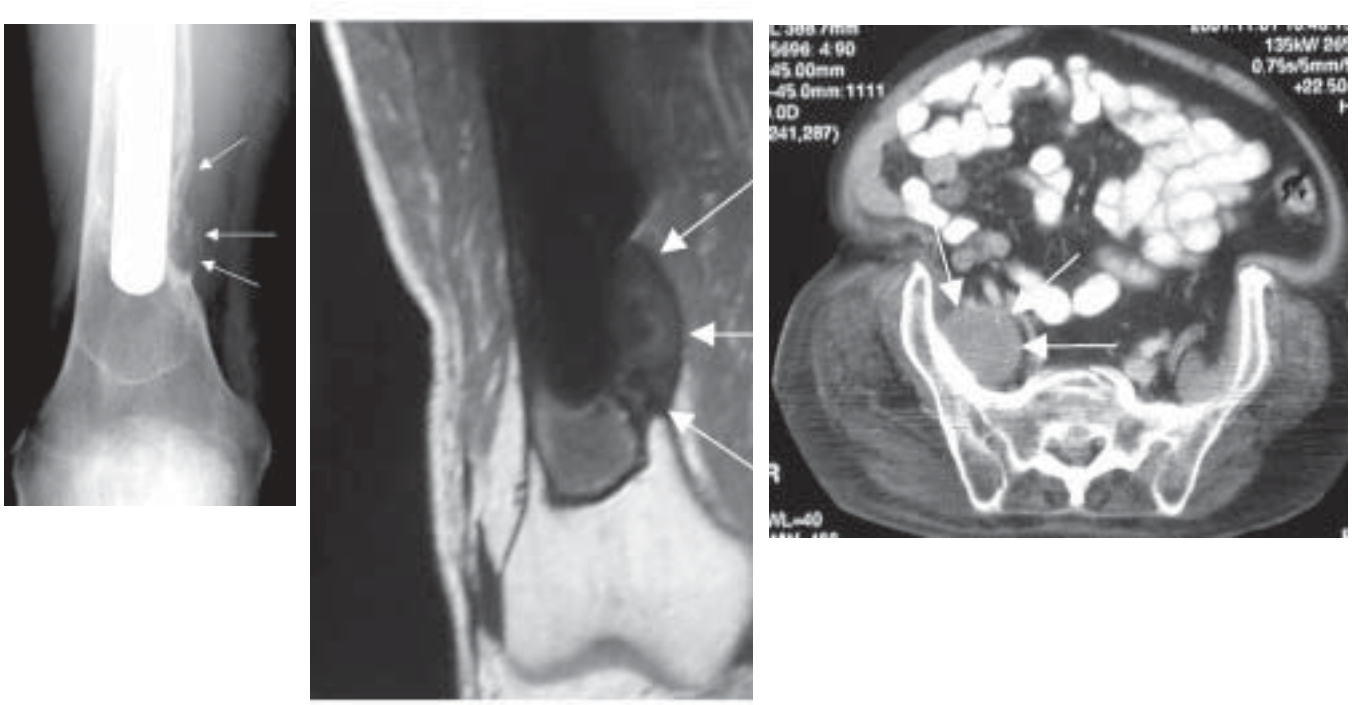

Figures 2A-C. Osteolytic lesion simulating malignant tumor. A: Outer cortical defect with periosteal elevation (arrows). B: Soft tissue extension (arrows) of lesion. C: Intrapelvic mass (arrows) adjacent to S1 and proximal to the artificial hip replacement displacing lumbar plexus.

while in the case of Jeanrot et al.[7] the patient presented with hip pain and a limb which was shortened by 5 cm and externally rotated owing to proximal intrapelvic migration of the socket. Osteolysis around total knee replacements has also rarely been suspected as a sign of malignancy. A pathologic fracture with non-union of a fibular neck fracture resulted in a differential diagnosis including malignancy in the case of Nadlacan et al[12]. The patient reported by Benevenia et al. had a pathological fracture associated with a large expansile lesion in the distal medial femur.[1]

Our first patient experienced severe perirectal pain for which he sought surgical consultation, and the large mass was detected on colonoscopy. Following two transrectal aspirations, the patient's symptoms abated following revision arthroplasty. The transrectal procedures were likely a risk for disastrous infection in a process that unknowingly was communicating with the hip arthroplasty, and illustrates a danger of not being aware of the potential of particulate-induced osteolysis to simulate malignancy. The patient of Korkala et al.[9] presented with pain and swelling in the inguinal region, and as in our case, a large intrapelvic cyst was demonstrated on arthrography. Our second patient had radiating symptoms consistent with nerve involvement, in addition to a radiographic appearance in the distal femur suggesting malignancy. The appearance of the distal femur in our second case most closely resembles that reported by Nadlacan[12] in which there was total cortical destruction. However, unlike that case, the destruction in ours was limited to the outer cortex, did not appear to arise from the endosteal canal, and was associated with a worrisome periosteal reaction. These cases illustrate the potential to confuse particulate-induced osteolysis with malignancy. While in these cases malignancy must be ruled out, osteolysis should be a part of the differential diagnosis in patients with total joint arthroplasty who present with pelvic masses, radicular pain and/or unusual cortical destruction and periosteal elevation.

REFERENCES

1. **Benevenia J, Lee FY, Buechel F,** et al: Pathologic supracondylar fracture due to osteolytic pseudotumor of knee following cementless total knee replacement. *J Biomed Mater Res* 43:473-477, 1998.
2. **Dobbs HS, Minski MJ:** Metal ion release after total hip replacement. *Biomaterials* 1:193-198, 1980.
3. **Gruen TA, Amstutz HC:** A failed vitallium/stainless steel total hip replacement: a case report with histological and metallurgical examination. *J Biomed Mater Res* 9:465-477, 1975.
4. **Harris WH, Schiller AL, Scholler JM,** et al: Extensive localized bone resorption in the femur following total hip replacement. *J Bone Joint Surg Am* 58:612-618, 1976.

5. **Huddleston HD:** Femoral lysis after cemented hip arthroplasty. *J Arthroplasty* 3:285-297, 1988.
6. **Jasty MJ, Floyd WE, 3rd, Schiller AL,** et al: Localized osteolysis in stable, non-septic total hip replacement. *J Bone Joint Surg Am* 68:912-919, 1986.
7. **Jeanrot C, Ouaknine M, Anract P,** et al: Massive pelvic and femoral pseudotumoral osteolysis secondary to an uncemented total hip arthroplasty. *Int Orthop* 23:37-40, 1999.
8. **Kilgus DJ, Funahashi TT, Campbell PA:** Massive femoral osteolysis and early disintegration of a polyethylene-bearing surface of a total knee replacement. A case report. *J Bone Joint Surg Am* 74:770-774, 1992.
9. **Korkala O, Syrjanen KJ:** Intrapelvic cyst formation after hip arthroplasty with a carbon fibre-reinforced polyethylene socket. *Arch Orthop Trauma Surg* 118:113-115, 1998.
10. **Mak KH, Wong TK, Poddar NC:** Wear debris from total hip arthroplasty presenting as an intrapelvic mass. *J Arthroplasty* 16:674-676, 2001.
11. **Mirra JM, Amstutz HC, Matos M,** et al: The pathology of the joint tissues and its clinical relevance in prosthesis failure. *Clin Orthop*: 221-240, 1976.
12. **Nadlacan LM, Freemont AJ, Paul AS:** Wear debris-induced pseudotumour in a cemented total knee replacement. Knee 7:183-185, 2000.
13. **Willert HG:** Reactions of the articular capsule to wear products of artificial joint prostheses. *J Biomed Mater Res* 11:157-164, 1977.
14. **Willert HG, Bertram H, Buchhorn GH:** Osteolysis in alloarthroplasty of the hip. The role of bone cement fragmentation. *Clin Orthop*: 108-121, 1990.
15. **Willert HG, Bertram H, Buchhorn GH:** Osteolysis in alloarthroplasty of the hip. The role of ultra-high molecular weight polyethylene wear particles. *Clin Orthop*: 95-107, 1990.

USE OF BETA-2-TRANSFERRIN TO DIAGNOSE CSF LEAKAGE FOLLOWING SPINAL SURGERY: A CASE REPORT

Geoffrey F. Haft, M.D.*, Sergio A. Mendoza, M.D.*, Stuart L. Weinstein, M.D.*, Toru Nyunoya, M.D.+, and Wendy Smoker, M.D.#

INTRODUCTION

The spine surgeon is often confronted with a draining operative wound and/or deep-lying fluid collection. The most frequently ascribed diagnoses are seroma, infection, and cerebrospinal fluid (CSF) leakage. The diagnosis is determined by review of clinical data, the appearance of the wound, and laboratory tests such as white blood cell count, erythrocyte sedimentation rate, C-reactive protein, and microbiology specimens. MRI can show fluid collection but does not necessarily differentiate between diagnoses. Often, a percutaneous needle aspiration is necessary for fluid analysis.

Beta-2-transferrin is a protein found only in CSF and perilymph. Meurman[1] first described its use in the detection of CSF leakage in 1979. Since that time, beta-2-transferrin has been used extensively by otolaryngologists in the diagnosis of CSF rhinorrhoea and skull-base cerebrospinal fluid fistulas. With sensitivity of 94%-100% and specificity of 98%-100%[5], this assay has become the gold standard in detection of CSF leakage. While the beta-2-tranferrin assay has been briefly mentioned in an orthopaedic review article[16] as a useful test in the postoperative diagnosis of CSF leakage, its broad potential in helping spine surgeons deal with postoperative complications has not been adequately emphasized. The following case demonstrates the utility of the beta-2-transferrin assay in identifying CSF within a postoperative fluid collection.

* Department of Orthopaedics and Rehabilitation
University of Iowa Hospitals and Clinics
Iowa City, Iowa

Department of Radiology
University of Iowa Hospitals and Clinics
Iowa City, Iowa

+ Division of Pulmonary
Critical Care, and Occupational Medicine
University of Iowa Hospitals and Clinics
Iowa City, Iowa

Corresponding author:
Sergio A. Mendoza, M.D.
Department of Orthopaedics and Rehabilitation
University of Iowa Hospitals and Clinics
200 Hawkins Drive, Iowa City, Iowa 52242
Sergio-Mendoza@uiowa.edu

CASE REPORT

A forty-seven year-old female schoolteacher presented with a two-week history of diffuse bilateral leg numbness, greatest on the anterior aspect of both thighs. She complained of progressive bilateral leg weakness and loss of balance, which limited her gait capacity to distances less than one hundred meters. These symptoms were significantly relieved with rest. She had no bowel or bladder incontinence and no constitutional symptoms. There was no history of previous trauma or back pain. The patient was otherwise feeling well and had no other known medical problems.

On physical exam, the patient's spine was well aligned both on the coronal and sagittal planes. The range of motion of her back was within normal limits, and her gait was also normal. On neurological examination, she had normal motor strength in all four extremities. She had diffuse hypoesthesias in an L2 to S1 distribution bilaterally, most profound in the L2-3 distribution. Hyperactive deep tendon reflexes were noted in both lower extremities. She had two to three twitches of clonus, and absent Babinski reflex. Rectal tone examination was normal.

Plain radiographs of the thoracic spine demonstrated a bony spur projecting posteriorly into the spinal canal, at the T10-T11 interspace. A CT scan revealed a calcified T10-T11 disk space and a calcified mass, which occupied at least 50% of the AP diameter of the spinal canal. The posterior longitudinal ligament (PLL) was ossified at the level of the T10-T11 disk space, and both proximally and distally, extending posterior to most of the T11 vertebral body (Figure 1). The MRI revealed marked posterior displacement of the cord at this level with signal changes on T2-weighed images within the cord (Figure 2). The differential diagnoses were calcified thoracic disk herniation versus ossification of the posterior longitudinal ligament (OPLL). The patient's symptoms were compatible with spinal intermittent claudication, as described by Jellinger.[9,10] This represents a vascular compromise of the spinal cord[10], and as described in the OPLL literature, once clinical manifestations begin, the course may be rapidly progressive.[11] For this reason, anterior canal decompression and spinal fusion were indicated.

The patient underwent a left tenth rib thoracotomy, T10-11 corpectomy, and spinal cord decompression.

Figure 1. A: CT-scan axial cut and B: sagittal reconstruction at T10–T11. Bony spur and ossification of the PLL occupying a significant amount of spinal canal diameter.

Figure 2. T2-weighed MRI sagittal image reveals severe spinal cord compression and posterior displacement of the cord.

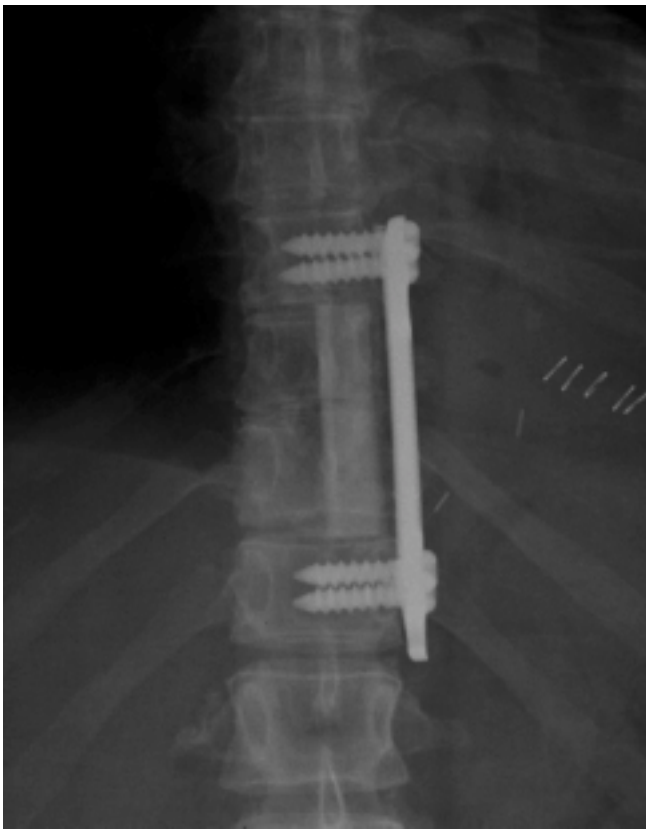

Figure 3. Post-operative plain films show T9 – T12 anterior spinal fusion with structural graft and low-profile titanium implant.

Decompression was very challenging, due to significant adhesion of the dural sac to the bony prominence. Once adequate decompression had been obtained, the spine was reconstructed with allograft fibula, autograft rib, and a low profile titanium plate (Figure 3).

Intraoperatively, the offending bony prominence was intimately pushed against the dura and, in some areas, adhered. Removal of the mass provoked some CSF leak, although no discrete tear in the dura was identified. Once the cord had fallen anterior to its normal position, the leak appeared to resolve spontaneously. Upon closure, the parietal pleura could not be completely closed due to the prominent hardware. The wound was closed without difficulty around two chest tubes.

On postoperative day four, the chest tubes were pulled. On postoperative day five, the patient developed orthostatically induced vertigo, headache, and nystagmus. The chest x-ray revealed only a small residual left-

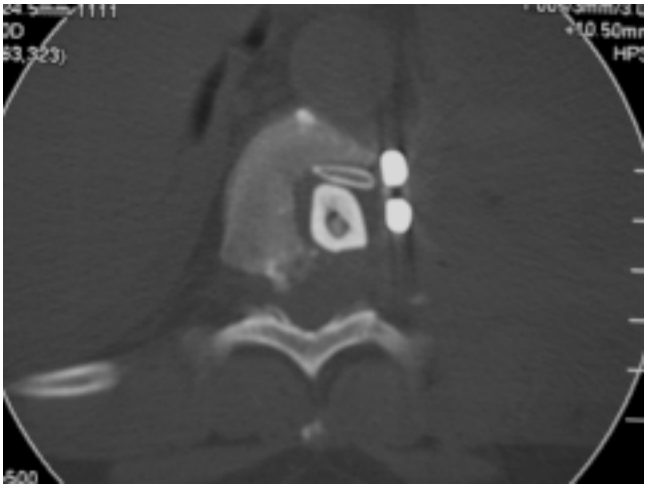

Figure 4. Post-operative CT-scan shows significant decompression of the spinal canal.

sided pleural effusion. With the clinical suspicion of symptomatic CSF leakage, the patient was placed on seven days of flat bed rest, and subsequently, slowly mobilized without any further orthostatic problems. On postoperative day fourteen, she was discharged to home without any dizziness, headaches, or respiratory difficulty. Her preoperative neurological symptoms had dramatically improved. A follow-up CT-scan revealed significant decompression of the spinal canal (Figure 4).

One week after discharge, the patient presented to clinic with progressive dyspnea and orthopnea. She had a mild, non-productive cough, but she had no fevers, chills, or night sweats. On exam, she was afebrile with normal vital signs. Her respiratory rate was sixteen, but she was visibly uncomfortable at rest. With mild exertion, she became tachypneac and clearly dyspneic. Pulmonary exam revealed significantly diminished breath sounds in the entire left lung field and dullness to percussion. The surgical scar was healing well without signs of infection. Her neurological exam was normal, except for two beats of clonus, predominantly on the right. The remainder of physical exam was normal. Complete blood count and blood chemistries were within normal limits. Chest X-ray demonstrated a large left pleural effusion with mediastinal shift to the right (Figure 5).

The differential diagnosis of this fluid collection included subarachnoid pleural fistula, pleural fluid accumulation, hemothorax, chylothorax, and empyema. A thoracentesis was performed removing one liter of straw colored fluid. The patient's respiratory symptoms improved immediately. Analysis of the fluid revealed a pleural to serum creatinine ratio less than one, suggesting a transudate. The patient's postoperative symptomatic CSF leak strongly suggested that the transudate was a

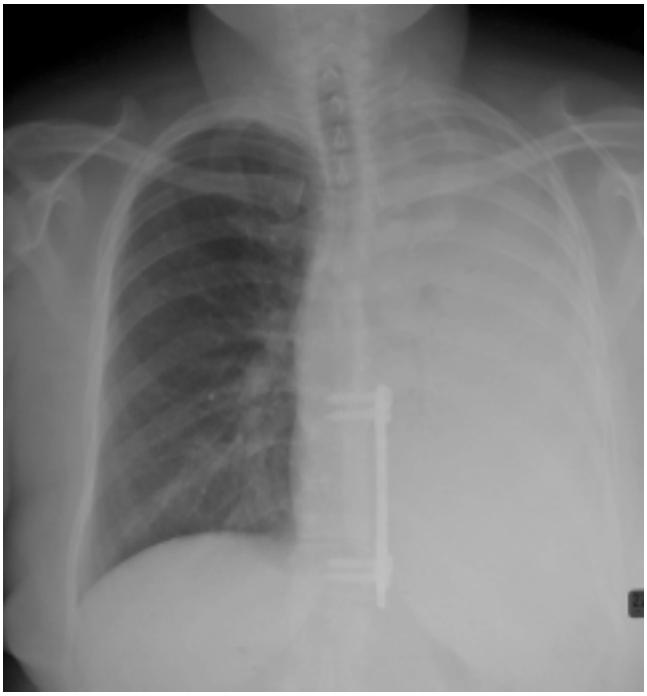

Figure 5. Post-operative x-ray on post-op day 20 reveals massive fluid collection in the left chest field with mediastinal shift to the right.

result of a subarachnoid pleural fistula. A beta-2-transferrin test of the fluid was performed and proved comfirmatory.

The patient remained asymptomatic, but her chest x-ray still demonstrated a massive effusion one week later. An additional 1.6 liters of fluid were removed. The patient was followed with regular chest x-rays over ensuing weeks, and the effusion slowly resolved without further intervention. She returned to work two months after surgery. Six months after surgery, she remained symptom free and returned to all regular activities. The neurological evaluation was completely normal, and her chest x-ray revealed completely clear chest fields.

DISCUSSION

The presence of a subarachnoid pleura fistula (SPF) upon the patient's presentation to clinic on her first post-operative visit is not surprising given that she had a known intraoperative CSF leak as well as concordant symptoms in the immediate post-operative course. When confronting a massive hydrothorax, the knowledge gained with the beta-2-transferrin assay was very useful. The ability to rule out empyema, chylothorax, and pleural fluid accumulation allowed us to focus our potential treatment modalities upon the CSF leakage. Heller[12] reported on two cases, which required transdiaphragmatic pedicled greater omental flaps. Ido[13] reported on three cases, which were repaired by either surgical closure with substitute dura mater and fibrin

adhesive sealant or cyanoacrylate adhesive, or percutaneous intrapleural administration of OK-432, which has been shown to decrease pleural effusions in carcinoma patients through a local inflammatory response. The difficulty posed by our patient was the pressure gradient between the intrathecal and intrapleural space, which facilitates CSF leakage.[12] We were preparing to attempt a direct repair when spontaneous resolution occurred. A possible explanation for the spontaneous resolution would be migration of the spinal cord towards the dural defect, which tamponaded the flow of CSF. This may have allowed the defect to heal. A follow-up MRI taken at six months post-op showed the spinal cord to be completely centered in the spinal canal and surrounded by CSF, as well as absence of pseudomeningocele.

While this case illustrates a dramatic CSF leak into a large cavity, the pleural space, the beta-2-transferrin assay will likely be of more common use in posterior spinal surgery complications, such as deep lying fluid collections or wound drainage. In lumbar decompression surgeries, Wang[14] reported a dural tear incidence of 14%, and in a review of 412 primary open discectomies, Stolke[15] reported a 5.3% incidence of tears. This rate was over three times greater for revision procedures. In posterior spinal fusions with pedicle screw placement, West[16] has described 5.6% incidence of dural tears.

The vast majority of these tears are identified intraoperatively and repaired. However, an unknown number of tears will persist, creating fluid collections, wound healing problems, and sometimes may even form subarachnoid-cutaneous fistulas. Persistent CSF leakage can lead to meningitis, epidural abscess, and pseudomeningocele.

When faced with treating a postoperative wound complication that involves persistent fluid drainage or fluid accumulation in the subcutaneous or submuscular planes, the beta-2-tranferrin assay and its ability to confirm that the fluid is CSF helps the surgeon plan the appropriate intervention. If the assay is negative, the surgeon can treat the wound with appropriate incision, debridement, and closure. However, if the assay is positive, the site of leakage should be sought out and repaired in an appropriate manner.

In summary, the beta-2-transferrin assay is a highly sensitive and specific test for the presence of CSF in body fluids. This test has been employed successfully by otolaryngologists in the diagnosis of skull-base CSF leaks. To our knowledge, the usefulness of the beta-2-transferrin assay has only been mentioned once in the spine surgery literature.[16] Orthopedic spine surgeons are encouraged to take greater advantage of this method in appropriate clinical scenarios.

REFERENCES

1. **Meurman OH, Irjala K, Suonpaa J, Laurent B.** A new method for identification of cerebrospinal fluid leakage. *Acta Otolaryngol* 1979;87(3 – 4):366-69.
2. **Nandapalan V, Watson ID, Swift AC.** Beta-2-transferrin and cerebrospinal fluid rhinorrhea. *Clin Otolaryngol* 1996;21(3):259-64.
3. **Jones NS.** Editorial: Advances in the management of CSF leaks. *BMJ* 2001;322:122-3.
4. **Skedros DG, Cass SP, Hirsch BE, Kelly RH.** Beta-2-transferrin assay in clinical management of cerebral spinal fluid and perilymphatic fluid leaks. *J Otolaryngol*. 1993;22(5):341-4.
5. **Marshall AH, Jones NS, Robertson JJ.** An algorithm for the management of CSF rhinorrhea illustrated by 36 cases. *Rhinology*. 1999;37(4):181-5.
6. **Ryall RG, Peacock MK, Simpson DA.** Usefulness of beta-2-transferrin assay in the detection of cerebrospinal fluid leaks following head injury. *J Neurosurg* 1992;77(5):737-9.
7. **Marshall AH, Jones NS, Robertson JA.** CSF rhinorrhea: The place of endoscopic sinus surgery. *Br J Neurosurg*. 2001;15(1):8-12.
8. **Bradbury MW.** Transport of iron in the blood-brain-cerebrospinal fluid system. *J Neurochem*. 1997;69(2):443-54.
9. **Jellinger K, Neumayer E.** Claudication of the spinal cord and cauda equine. *Handbook of Clinical Neurology*. Vol 12. Vinken PJ, Bruyn GW, eds. Amsterdam: North Holland. 1972:507-47.
10. **Kikuchi S, Watanabe E, Hasue M:** Spinal Intermittent Claudication due to Cervical and Thoracic Degenerative Spine Disease. *Spine*. 1996 Feb 1;21(3): 313-8.
11. **Fujimura Y** et al. Long-term follow-up study of anterior decompression and fusion for thoracic myelopathy resulting from ossification of the posterior longitudinal ligament. *Spine*. 1997;22:305-11.
12. **Heller JG, Kim HS, Carlson GW.** Subarachnoid-Pleural Fistulae—Management with a Trans-diaphragmatic pedicled greater omental flap. *Spine*. 2001 Aug 15;26(16):1309-13.
13. **Ido K, Shimizu K, Nakamura T:** Management of cerebrospinal fluid leakage complicating anterior procedures through thoracotomy: report of three cases. *Neurosurg Rev*. 2002 Jun;25(3):174-6.
14. **Wang JC, Bohlman HH, Riew KD.** Dural tears secondary to operations on the lumbar spine. *J Bone Joint Surg Am*. 1998;80A:1728-32.
15. **Stolke D, Sollmann W, Seifert V:** Intra- and postoperative complications in lumbar disc surgery. *Spine*. 1989;14:56-9.
16. **Bosacco SJ, Gardner MJ, Guille JT.** Evaluation and treatment of dural tears in lumbar spine surgery: A review. *Clin Orthop*. 2001;389:238-47.

TRANSITORY INFERIOR DISLOCATION OF THE SHOULDER IN A CHILD AFTER SHOULDER INJURY: A CASE REPORT AND TREATMENT RESULTS

Twee Do, M.D. and Kim Kellar

INTRODUCTION

Transitory inferior subluxation of the humeral head is a well documented phenomenon that can occur after shoulder trauma or surgery in adults.[1, 2, 6, 7] The etiology is either from a large joint effusion, or more likely, from temporary atony of the deltoid and rotator cuff muscles secondary to axillary neuropraxia. This subluxation is characterized by a mid point of the humeral head which lies at the inferior lip of the glenoid, rather than at its center. In adults, the incidence of inferior shoulder subluxation ranges from 10% to 60%, depending on the mechanism of injury.[6]

To date, however, inferior subluxation of the humeral head has not been reported in children. Furthermore, transitory inferior dislocation of the humeral head as a sequela to trauma has not been described. This article is a case report of a 14 year old girl who developed a transitory inferior shoulder dislocation after sustaining a proximal humerus fracture. Unlike true traumatic fracture-dislocations, it required only support of the arm in order to "reduce" the joint and maintain its position within the glenoid.

CASE REPORT

A 14-year-old African-American female was involved in a motor vehicle accident impacting the right side where she was a belted passenger. She sustained a right proximal humerus fracture with angulation and displacement. Her neurovascular status demonstrated a slight decrease in sensation in the axillary nerve distribution. With an open physis, her fracture position was considered acceptable (Figure 1) and she was placed into a coaptation splint.

She returned for follow-up 5 days later and repeat radiographs showed inferior dislocation of the humeral head (Figure 2). She was taken to the fluoroscopic suite, where the fracture was examined and noted to be unstable with manipulation, while the "dislocation" could be "reduced" by mere support of the arm. She underwent percutaneous pin stabilization of the shoulder the following day, with intraoperative images demonstrating a stable, located shoulder joint to all ranges of motion (Figure 3A).

In the PACU, postoperative radiographs again demonstrated inferior dislocation (Figure 3B) and she was placed into a two-arm shoulder spica cast with good support under the right elbow. This completely reduced the glenohumeral joint (Figure 3C). She maintained reduction of the humeral head within the glenoid fossa with the cast and was kept in the shoulder spica for a total of six weeks.

The pins were removed in the operating room without complications after complete healing, and postoperative radiographs demonstrated maintenance of the reduced position of the humeral head. She was stiff in the shoulders as anticipated and was started on physical therapy. At final follow-up 10 months later, she has full range of motion and strength. She also has a well reduced shoulder joint without delayed sequelae (Figures 4A-D).

DISCUSSION

Trauma to the shoulder may result in injuries that can range from rotator cuff strain and glenohumeral subluxation to proximal humerus fractures and joint dislocations. The most common direction for traumatic shoulder dislocations is anterior, however, luxatio erecta may rarely occur.[3, 5] The incidence of luxatio erecta, or inferior shoulder dislocation, is less than 1% of all shoulder dislocations, but it has a pathognemonic history and presentation with the shoulder in abduction, the elbow flexed and the forearm held behind the head. Luxatio, as with any traumatic shoulder dislocations, requires a closed reduction under sedation or anesthesia in order

Cincinnati Children's Hospital Medical Center
Department of Pediatric Orthopaedic Surgery
3333 Burnet Avenue
Building C, MLC 2017
Cincinnati, Ohio 45229

Cincinnati Children's Hospital Medical Center
Department of Pediatric Orthopaedic Surgery
3333 Burnet Avenue
Building C, MLC 2017
Cincinnati, Ohio 45229

Corresponding Author
Twee Do, MD
Cincinnati Children's Hospital Medical Center
Department of Pediatric Orthopaedic Surgery
3333 Burnet Avenue
Building C, MLC 2017
Cincinnati, Ohio 45229
513-636-4785 telephone
513-636-3928 fax
twee.do@chmcc.org

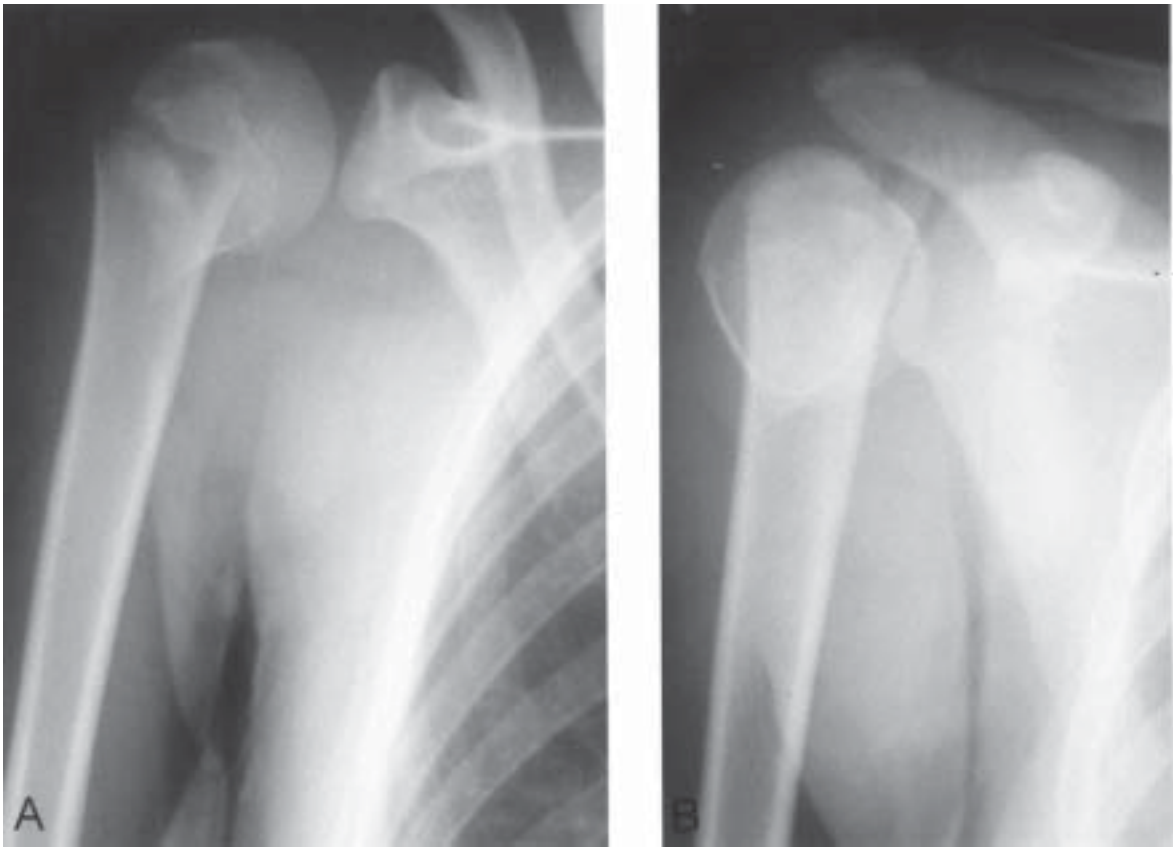

Figures 1A & B. (A) AP and (B) lateral radiographs of the proximal right humerus showing a fracture with an acceptable amount of displacement in a skeletally immature individual. Note the reduced position of the humeral head within the glenoid.

Figure 2. Follow-up radiograph 5 days later showing a dislocated right shoulder joint.

to obtain alignment and avoid complications, such as avascular necrosis.

Transitory inferior dislocation is an even more rare condition that can also occur after shoulder trauma in patients of any age. We report a case occurring in a 14-year-old girl. In contrast to the traumatic fracture-dislocation, transitory inferior dislocation is not likely to result in an unstable joint or any other complications if properly supported. This is a more exaggerated presentation of the well know transient inferior subluxation phenomenon that can occur after proximal humerus trauma or rotator cuff surgery in adults.

The etiology of this transient subluxation or dislocation at the glenohumeral joint is hypothesized to be either from a large joint effusion or, more likely, from partial atony of the deltoid and rotator cuff muscles.[4, 7] The weakened muscles are subjected to a stretching force which they may be unable to withstand. The result is subluxation, or to the extreme, complete dislocation out of the glenohumeral joint.

Transient subluxation or dislocation of the shoulder may exist without giving rise to symptoms. This subluxation or dislocation usually does not occur immedi-

Figures 3A-C. A: Intraoperative image of the shoulder immediately after pinning of the fracture with a reduced glenohumeral joint. B&C: Immediate PACU radiographs again showing inferior dislocation of the shoulder. "Reduction" of the joint with a 2 arm spica cast only.

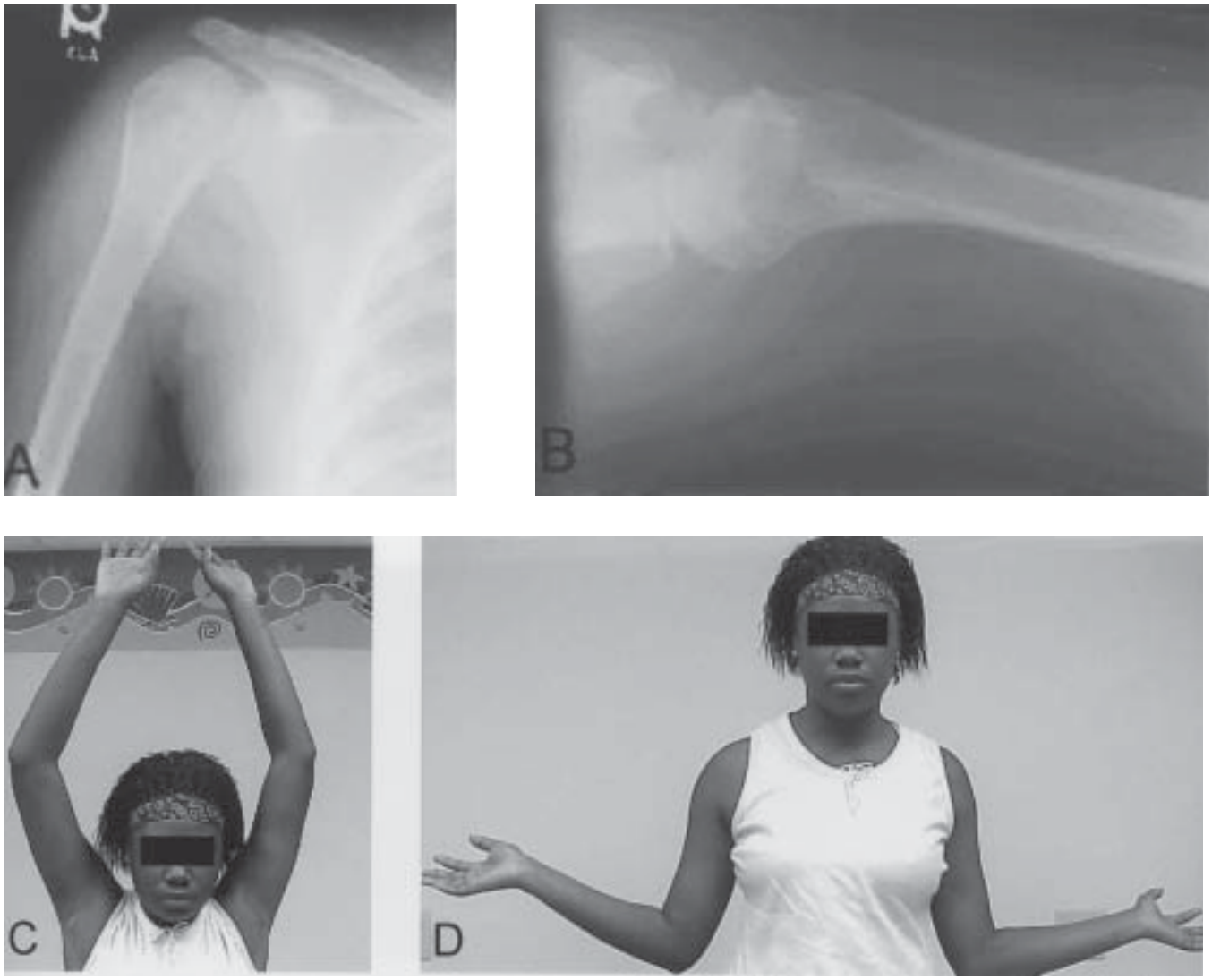

Figures 4 A-D. Final follow-up 10 months later. A & B show a well-healed fracture with a well-reduced joint. C & D are clinical photographs showing full range of motion.

ately following the injury. It typically occurs a few days or weeks following the injury. In this case, it was noted on the patient's first follow-up 3 days after the injury. When mildly subluxed, the shoulder recovers on its own after the muscle tone is restored. This usually takes 4 to 6 weeks. Even when overlooked, mild subluxation usually will not result in persistent subluxation or loss of function directly attributable to this lesion. With complete, although transient, inferior dislocations, the shoulder should be more aggressively treated with support to maintain reduction for the duration of the 4 to 6 weeks. This may be in the form of a sling or shoulder spica cast. End results are uniformly good.

In summary, we present a case of an adolescent with an extreme form of transitory inferior subluxation, (i.e., transitory inferior dislocation), after a proximal humerus fracture with axillary neuropraxia. Unlike traumatic fracture dislocations of the proximal humerus, it occurred a few days after the initial injury and required only the support of the arm for 6 weeks in order to "reduce" the dislocation. This is a phenomenon that can happen after injury and an awareness of its presence may avoid more aggressive "reductions" and anesthesia than is really necessary.

REFERENCES

1. **Aufranc OE, Jones WN, Turner RH:** Humeral neck fracture with inferior subluxation of the shoulder joint. *JAMA* 1966;195(5):380-2.
2. **Connolly JF:** Inferior shoulder subluxation associated with a surgical neck fracture of the humerus. *Nebr Med J* 1982;67(1):11-2.
3. **Grate I, Jr.:** Luxatio erecta: a rarely seen, but often missed shoulder dislocation. *Am J Emerg Med* 2000;18(3):317-21.
4. **Hall FM:** Inferior subluxation of the shoulder. *Skeletal Radiol* 1993;22(2):104.
5. **Pirrallo RG, Bridges TP:** Luxatio erecta: a missed diagnosis. *Am J Emerg Med* 1990;8(4):315-7.
6. **Pritchett JW:** Inferior subluxation of the humeral head after trauma or surgery. *J Shoulder Elbow Surg* 1997;6(4):356-9.
7. **Shibuta H, Tamai K:** Rotator cuff tearing and inferior subluxation of the humeral head: report of two cases. *J Shoulder Elbow Surg* 1995;4(3):219-24.

BONE AND BRAIN: A REVIEW OF NEURAL, HORMONAL, AND MUSCULOSKELETAL CONNECTIONS

Kevin B. Jones, M.D., Anthony V. Mollano, M.D., Jose A. Morcuende, M.D., Ph.D.,
Reginald R. Cooper, M.D., Charles L. Saltzman, M.D.

ABSTRACT

Nerves have been identified in bone. Their function has recently become the focus of intense study. Metabolic control of bone is influenced by the nervous system. Potential transmitters of this influence include glutamate, calcitonin gene-related protein (CGRP), substance P, vasoactive intestinal peptide (VIP), pituitary adenylate cyclase activating polypeptide (PACAP), leptin, and catecholamines. Disorders of nerves – central or peripheral—can have substantial influence on bone health and repair. Specifically considered are the potential neural influences at work in such conditions as osteoporosis, fracture healing, Charcot osteoarthropathy, musculoskeletal pain syndromes, heterotopic ossification, skeletal growth and development, and obesity-related increased bone density. In this article, we review the current state of experimental and clinical evidence implicating the role of nervous tissue in regulating bone biology and discuss the current understanding of molecular signaling between nervous and osseus tissue in the homeostatic maintenance of the skeleton.

INTRODUCTION

From the time of his or her first fracture reduction in the emergency room, no orthopaedic surgeon has ever doubted that bone was innervated. However, the assumption was always that only the periosteum, and not the bone tissue itself, was innervated. Conditions such as Sudeck's atrophy in association with chronic regional pain syndrome, heterotopic ossification in the setting of head injury, and Charcot diabetic neuroarthropathy extend the general consideration that nervous and musculoskeletal systems must interact.

The first documentation of an anatomic relationship between nerves and bone was made via woodcut, by Charles Estienne in Paris in 1545. His diagram demonstrated nerves entering and leaving the bones of a skeleton. More specific study of bone innervation awaited the availability of technology that could microscopically view bone in sufficient detail. Reginald Cooper published his findings from electron microscopy that cortical bone is densely innervated (Figures 1 and 2), in his landmark 1966 report in the *Journal of Bone and Joint Surgery*[1] and subsequent report in 1968 in *Science*.[2] The next year Calvo and Fortez-Vila differentiated myelinated and non-myelinated fibers associated with the arterial vessels and venous sinusoids in bone.[3] Histofluorescence of noradrenaline identified sympathetic nerve fibers a decade later.[4] Finally, in 1986, Hohmann et al. reported on immunohistochemical localization of vasoactive intestinal peptide (VIP) containing sympathetic fibers in bone.[5] This began a steady flow of studies of various nerve types in bone by a number of different groups.

The field has recently been reinvigorated by interest in what was initially thought to be an obesity hormone, leptin. As the story of leptin and its effects on body mass as well as bone mass has slowly unfolded, the implications of neural control of many aspects of bone metabolism that were once thought to be exclusively hormonal, have come more sharply into focus.

NEURO-OSSEUS SIGNAL TRANSMISSION

Nerves are found throughout the periosteum and accompany nutrient vessels in the perivascular spaces of Haversian canals. They have been demonstrated to be especially dense near more metabolically active parts of bones, such as in the epiphysis and metaphysis, especially surrounding the growing physis.

Most nerve-to-nerve signal transmissions along with many nerve-to-end organ communications occur via synapses. While neural synapses represent special cell-to-cell signaling areas isolated from the surrounding interstitial space, they nonetheless utlimately depend on receptor-ligand interactions, just as hormonal endocrine, paracrine, and autocrine functions. Neural transmission ligands include such molecules as catecholamines, glutamate, and a number of small polypeptides formed by alternative RNA splicing from larger genes.

To date, no classical synapses have been found to involve osteoblasts, osteoclasts, or osteocytes. However, nerve fibers with active expression of various neural transmission ligands have been demonstrated to be in close spatial association with bone cells. Further, recep-

Department of Orthopaedics and Rehabilitation
University of Iowa Hospitals and Clinics
200 Hawkins Drive
Iowa City, Iowa 52242

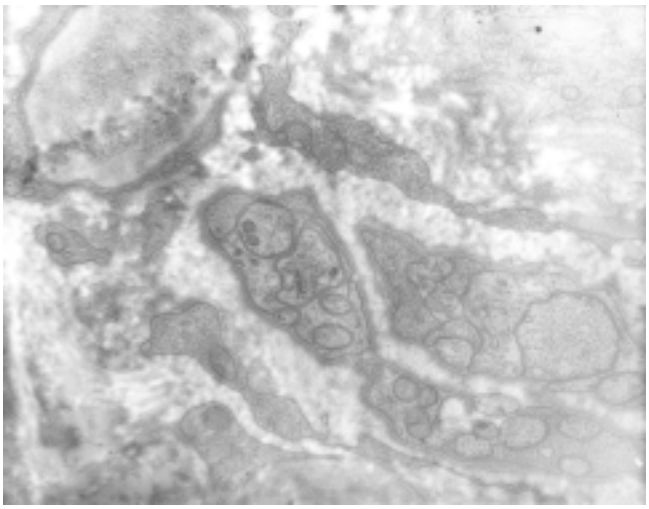

Figure 1. Unmyelinated nerves in bone. Electron microscopy of a human femoral osteon reveals multiple unmyelinated nerves with their neurofilaments within. The nerve cells appear invaginated into the recesses in the Schwann cell plasma membrane. Multiple nerve fibers appear ensheathed in each Schwann cell. Nerve fibers vary from 0.25 to 0.6 micrometers in diameter. They contain mitochondria, and neurofilaments, measuring in diameter about 600 Angstroms and 115 Angstroms, respectively.

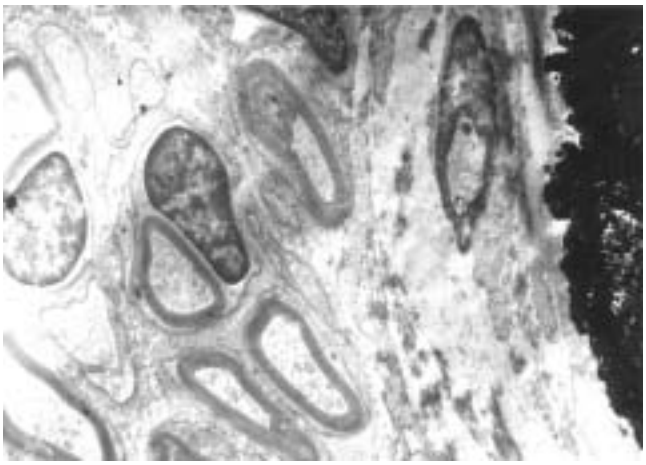

Figure 2. Myelinated nerves in bone. Electron microscopy of a human femoral osteon reveals multiple myelinated nerves adjacent with two nearby osteoblasts. Dark mineralized matrix is visible on one border of the micrograph. The osteoblasts appear to have some electron dense endoplasmic reticulum, more dense than adjacent cytoplasm. One of the osteoblasts has an apparent nucleus with a nucleosome within.

tors for these neural ligands are expressed by bone cells, and administration of these neural transmission molecules has potent effects on bone cells.

We will review the roles of the following neural ligands in bone metabolism: glutamate, calcitonin-gene related peptide (CGRP), substance P, vasoactive intestinal peptide (VIP), and catecholamines.

Glutatmate

Glutamatergic synaptic transmission dominates internervous signaling in the central and peripheral nervous systems. There are both ionotropic, or ion channel gating, and metabotropic, or G-protein-coupled, cell protein expression modulating, receptors for glutamate. Among ionotropic glutamate receptors is the NMDA receptor, thought to be responsible for memory and synaptic plasticity in the central nervous system.

Recently, glutamate has been identified in bone both in association with other nerve markers in proximity to bone cells and blood vessels, and as a product released by osteoblasts themselves.[6,7] Osteoblasts, osteoclasts, and osteocytes express the NMDA and other glutamate receptors and induce patch-clamp-demonstrable currents (the standard measure of ion channel controlled currents in nerves) in response to glutamate signaling.[8-12]

Osteoblasts decrease alkaline phosphatase and calcific nodule formation (known in-vitro markers of osteoblast activity) when exposed to NMDA receptor antagonists in culture. Bone marrow stromal cells preferentially differentiate into adipocytes rather than osteoblasts when they are exposed to such antagonists.[13] These findings suggest that glutamate, an NMDA agonist, should play a role in encouraging osteoblastic differentiation and activity.

Osteoclasts are halted in bone resorption when exposed to NMDA receptor antagonists.[8] This may indicate an expansion of glutamate NMDA-agonist effects to upregulate bone remodeling in general, with increased osteoclastic function as well.

Glutamate function in paracrine signals between bone cells is suspected to be at work when expression of transporters of glutamate is downregulated in response to mechanical loading of osteocytes.[14] Glutamate antagonists injected into rats prior to bone loading decrease the responsive bone remodeling that would otherwise result.[15]

While the signaling is not yet fully understood, glutamate is thought to play a major role in nerve-to-bone signaling, as well as bone-to-bone paracrine signaling to control anabolic and catabolic activities, especially as they relate to responsive remodeling after mechanical loading.[16]

Calcitonin Gene-Related Protein (CGRP)

CGRP is a 37 amino acid neuropeptide generated by alternative splicing of the calcitonin gene. In the peripheral nervous system, it is expressed in finely myelinated A-delta fibers and unmyelinated C fibers, the major peripheral sensory nerve fibers. In bone, nerve fibers

immunostaining for CGRP are found in the periosteum[17,18], bone marrow[19], and preferentially in the epiphyseal trabecular bone.[20] There, the fibers have many varicosities or bulges, which are scarcely covered by Schwann cells and richly loaded with secretory vesicles.[21] These varicosities, as well as the free nerve endings, are often closely associated with osteoblasts and osteoclasts. These findings have led to the suspicion that in addition to sensory transmission toward the central nervous system, sensory fibers may also transmit signals to the periphery, specifically to the milieu surrounding bone cells.

Cultured osteoblasts from multiple species demonstrate a characteristic rise in cyclic AMP concentration when exposed to CGRP directly.[22,23] CGRP exposure increases insulin-like growth factor expression dramatically[24] and interleukin-6 expression weakly.[25] It decreases tumor necrosis factor alpha expression.[26] These findings suggest that CGRP should increase bone formation and decrease resorption. The bone marrow of mice pretreated with CGRP has increased osteogenic activity in subsequent culture; direct exposure of marrow culture to CGRP also leads to increased bone colony formation. Interestingly, osteoblasts can express CGRP, perhaps as part of an autocrine or paracrine pathway.[27] Transgenic mice expressing CGRP driven by the osteocalcin (unique osteoblast gene) promoter have increased bone formation and bone volume;[28] this strengthens the supposition that CGRP expressed by osteoblasts themselves can affect osteoblastic activity similar to CGRP signaling from nerves. Interestingly, CGRP staining fibers have been shown to increase during fracture healing[29] and bone defect repair.[30]

Similar to calcitonin itself, CGRP inhibits osteoclast resorption directly in culture[31] and decreases serum calcium *in vivo*.[32,33]

Substance P

Nerve fibers staining for substance P, a well known nociceptive signaling molecule typically associated with sensory nerves, enter the bone marrow in association with vessels[21], but then dissociate and terminate as free nerve endings. Substance P has been shown to increase osteoblast differentiation, bone colony formation, and osteoblast cyclic AMP production. At least one of its receptors, neurokinin-1 is expressed by osteoclasts. Neurokinin-1 drives osteoclast resorption activity in vitro when osteoclasts are exposed to substance P.

Vasoactive Intestinal Peptide (VIP)

VIP is a neuropeptide usually associated with parasympathetic nerve fibers; it is also expressed in postganglionic sympathetic nerve fibers. Fibers immunoreactive for VIP were first demonstrated in bone by Hohmann et al. in 1986.[5] They were shortly thereafter localized to the periosteum and epiphysis, and only occasionally with blood vessels.[34,35] VIP is a ligand for three known receptors, VIP-1R, VIP-2R, and the receptor for pituitary adenylate cyclase activating polypeptide (PACAP). All of these are 7-trans-membrane G-coupled receptors from the VIP/secretin/PTH receptor family. Although results vary as to the timing of specific VIP receptor expression along the differentiation chronology, both VIP receptors have been shown to be expressed on osteoblasts and osteoclasts.[36-38]

VIP effects on osteoblastic activity have received only limited study. Lundberg et al. in 1999 demonstrated increased osteoblast activity in culture with VIP; however, this was not associated with either osteoblast proliferation or an increase in osteoid production.[39] They concluded that VIP induced further differentiation of already committed osteoblasts.

Better studied have been the effects of VIP on osteoclasts, some of which are mediated through osteoblast signaling. VIP downregulates osteoclastogenesis by decreasing RANK and RANK ligand expression in osteoclasts and osteoblasts, respectively, and by increasing osteoblast expression of osteoprotegerin, a RANK antagonist.[40] Regarding already present osteoclasts, VIP initially decreases their bone resorptive activity with a late reversal of this effect and stimulation of bone resorption. It is thought that this late osteoclast stimulation is mediated by increased expression of IL-6 by either osteoblasts or surrounding stromal cells.[41]

PACAP is a polypeptide related to VIP, formed by alternative splicing of the calcitonin gene. Its two known forms are PACAP 27 and PACAP 38. Its effects on osteoblasts are thought to be identical to VIP as it acts as a potent ligand to the same receptors.[42,43] However, nerve fibers immunostaining for PACAP also stain for substance P and CGRP, suggesting sensory, as opposed to sympathetic origin.[44]

Catecholamines

Tyrosine hydroxylase (TH) is the rate-limiting enzyme in catecholamine synthesis, which takes place near the nerve terminus of sympathetic nerves. Immunolocalization of TH is the means by which sympathetic adrenergic nerve fibers have been identified in bone.[21] Most of these fibers are associated with blood vessels in the bone marrow, but some are found as free nerve endings in the periosteum and bone adherent ligaments.[21]

Osteoblasts have been demonstrated to express β-2 adrenergic receptors.[45] Further, noradrenaline acting at α-1 receptors increases alkaline phosphatase activity in

TABLE 1
Summary of neurotransmitters characterized in bone

Neurotransmitter	Receptor	Putative intermediary mechanism	Putative action
Glutamate	NMDA	ion-gated channels	▲ bone remodeling
Calcitonin gene-related peptide	CGRP-R1, CGRP-R2	▲ cAMP	▲ bone formation ▼ bone resorption
Substance P	Neurokinin-1	▲ cAMP	▲ bone formation ▲ bone resorption
Vasoactive Intestinal Peptide	VIP-1R, VIP-2R, PACAP-R	▼ RANK ▼ RANKL ▲ OPG ▲ IL-6	▲ bone formation? ▼ osteoclast formation ▲ osteoclast resorption?
Catecholamines	ß-2, α-1 adrenergic receptors	▲ cAMP, ▲ PGE-2	▲ bone formation ▲ bone resorption

and proliferation of osteoblasts.[46] Others have demonstrated increased cyclic AMP and prostaglandin E2 production in response to noradrenaline.[22,47,48]

The interest in adrenergic innervation of bone has recently been specifically amplified by the same experiments that have truly re-opened the entire field of neuro-osseus transmission in the twenty-first century. Leptin, an obesity and body mass control hormone, has also been shown to induce both osteopenia and cachexia. Central resistance to, or underproduction of leptin results in the clinically frequent combination of obesity and greater than normal bone density. These characteristics, so long thought to be more hormonally related, are now shown to be regulated by the nervous system, as the most powerful effects of leptins are actually in the hypothalamus, and not at peripheral receptors in bone.[49] In rather elegant animal experiments, the Karsenty group in Houston demonstrated that adrenergic signaling mediates the bone density reduction resulting from leptin signaling in the hypothalamus.[50] While the peripheral pathophysiology at work is not entirely understood, the phenotypic osteopenia of increased central leptin signaling was reversed with systemic administration of beta-blockers. Some groups are now investigating beta-blockers as potential therapeutic options for osteoporosis.

EXPERIMENTAL DENERVATION

Although much of the experimental evidence for varied aspects of the understanding of neuro-osseus interaction comes from in vitro studies, these suggest potential pathways for interaction. The combined effects of multiple nerve-types and their multiplied signals can only begin to be worked out amidst the complex in vivo environment. A number of researchers have attempted to study neuro-osseus control with in vivo models of musculoskeletal denervation.

Neurectomy

The effects of surgically sectioning the sciatic nerve have been studied extensively, but nearly serendipitously. Sciatic neurectomy has been used by many as a standard model of disuse osteopenia, as loss of musculature from denervation effectively stops active motion in the limb. So recent is the prevalence of the thought that nerves may interact with bone metabolism directly, that most of the papers do not even recognize that neurectomy may have direct effects on bone cells from lost bone innervation, above and beyond denervation of muscle and disuse of the limb.[51]

When measured by DEXA, bone mineral density following rat sciatic neurectomy decreased progressively for 4 weeks post-section, then stabilized, but ceased to recover.[52] Interestingly, the contralateral limb with intact innervation also lost bone density—despite lack of apparent disuse.

An ex vivo culture study of bone marrow from neurectomized limbs demonstrated reduced osteoblastic activity markers, increased osteoclast-precursor differentiation after 2 weeks and increased osteoclast number and rate of osteoclastogenesis after 4 weeks.[53] The increased marrow osteoclast precursors and osteoclastogenesis may contribute to the contralateral loss in density.

Recently, Ito and colleagues have shown that neurectomy-induced osteopenia has a microstructure distinctly different from ovariectomy-induced osteopenia in the tibia.[54] While both show perforation and removal of trabeculae due to accelerated resorption, post-neurectomy trabeculae are flake-like in morphology as opposed to just diffusely absent. In addition, neurectomy more powerfully affects cortical bone density. Similar differences were found in comparison of neurectomy to orchiectomized male rats.[55]

The effects of neurectomy on osteopenia have been partly prevented experimentally with application of electrical stimulation[56] and bisphosphonate therapy.[57] In contrast, a substance P receptor antagonist was shown to enhance the bone loss following neurectomy. Substance P was reduced in both tibiae after unilateral sciatic nerve section. This led to the hypothesis that substance P may function systemically to maintain bone mass after denervation.

Sciatic neurectomy has been used to study pathophysiology other than osteopenia. Dietz demonstrated that complete and partial denervation after limb differentiation but before complete ossification and growth in tadpoles yield increased retained cartilaginous anlagen and decreased bone length, cross-sectional area, and foot size.[58]

Fracture repair has specifically been studied as a setting for sciatic neurectomy in the rat. Tibia fractures with intramedullary fixation showed decreased free and perivascular CGRP containing nerve fibers within a more voluminous callus compared to non-neurectomized, but still immobilized, limbs.[59] Another experiment found increased bone mineral content and increased bending moment and energy absorption after sciatic neurectomy concomitant to tibia fracture and intramedullary nailing.[60]

Deafferentation via dorsal root ganglionectomy of a limb with superimposed ACL transection resulted in knee instability and joint breakdown within weeks. This was interpreted to be a model for Charcot osteoarthropathy.[61]

Chemical Sympathectomy

Guanethidine is a sympathetic neurotoxin that can be administered intraperitoneally. In rats, TH and VIP staining fibers are dramatically decreased and CGRP and substance P fibers slightly increased in response. Treatment at birth[62] has demonstrated increased osteoclast resorption; but administration to adult rats has demonstrated reduced osteoclast numbers, and presence of pre-osteoclasts in the bone.[63]

Chemical Sensory Denervation

Capsaicin, a sensory nerve specific neurotoxin has also been studied in in vivo bone resorption models. CGRP and substance P containing nerve fibers are reduced significantly after treatment. When rats were treated at birth, resorption induction later in life yielded less resorption than in neurointact, untreated controls.[62] Adult rats treated also have decreased osteoclast recruitment and decreased attachment via the ruffled border to the bone surface.[64]

CLINICAL CORRELATION AND RELATED RESEARCH

While recent neuroscience discoveries have shed light on clinical neurological conditions, the role of neural pathophysiology in musculoskeletal disorders has been largely ignored. The obvious clinical problems with neural-bone pathology include bone pain from non-union/fracture/joint degeneration, Charcot neuroarthropathy, Sudeck's atrophy from complex regional pain syndrome (reflex sympathetic dystrophy), and heterotopic bone formation (ossification) following severe head injury. Evidence now suggests roles for neural control in fracture healing, bone development, bone mass control, and osteoporosis. These and other clinical scenarios of altered bone growth and metabolism require orthopaedic scientists to re-think underlying basic orthopaedic pathophysiology in light of recent insight of a neuro-osseus axis.

Immobilization

Functional immobilization by varied means (bed rest, cast immobilization, extremity trauma) results in what is termed disuse osteopenia. Although this phenomenon has been appreciated for some time, the mechanisms of remodeling due to load are not entirely understood. With the new appreciation of glutamate signaling changing with variation in load history, it has surfaced as one of many possible mediators of this bone loss due to immobilization.

Central Nerve Lesions

A hemiplegic stroke victim may be osteoporotic in both involved extremities, but interestingly, this osteoporosis is totally independent of pre-existing body muscle composition or weight.[65] This implies that effects from more than muscle inactivity alone are at play.

Spinal Cord Injury

Early after spinal cord injury (SCI), a rapid onset of bone loss occurs. This is clearly detectable in the first three months by serum and urinary type I collagen C-telopeptide assays,[66] and by six months by standard bone density measurement techniques.[67] With quadripalegia, bone mineral loss occurs throughout the entire skeleton, except the skull.[68] The time course and location of these changes suggests that more than simple disuse osteoporosis is at play. A bone maintenance role for peripheral nerves may be implicated. Supporting this concept of a neurologically mediated effect rather than disuse osteporosis, is the data that shows that electromyostimulation to promote muscle mass and bone mass has failed.[69] More than lack of

mechanical bone loading is at work in the osteopenia following SCI.[70] We suspect that nerve lesions, central and peripheral, contribute directly to abnormal bone metabolism through direct peripheral nerve signaling in bone.

Heterotopic Bone Formation

Heterotopic ossification (HO) is another sequelum from a range of "neurologic" injuries, including SCI, head injury, and brain tumors. HO is estimated to occur in up to 50% of SCI patients, in whom the hip is most often involved, followed by the knee.[71] It affects 20% of traumatic brain-injured patients, with hip, shoulder, and elbow being the most common sites. Beyond its experimental reproduction by bone morphogenic protein administration in muscle, HO etiology is poorly understood. Interestingly, limb spasticity, joint trauma, decubitus ulcers, and complete spinal cord lesions have all been correlated with increased risk of HO in SCI.[72,73] Is it possible that some inflammatory signal in and between muscles defaults differentiation of mesenchymal progenitors toward bone formation when not suppressed by some peripheral nerve signal?

Charcot Osteoarthropathy

In the developed countries, the most common cause of neuropathy in adults is diabetes mellitus. A special musculoskeletal complication of diabetic neuropathy in the extremities is Charcot neuroarthropathy, a slowly progressive inflammatory joint destruction. Disastrous complications of infection and frequent amputation make it a major concern for those involved in the care of the over 100 million patients with diabetes in the world.[74]

The pathophysiology is unclear. Charcot's personal etiological theory has come to be known as the French theory that without any obvious trauma history, some primary underlying neurological problem exists. A counter German theory has advocated that recurrent trauma is the culprit.

Insensate foot trauma coupled to abnormal neuro-osseus signals from neuropathy may together result in Charcot, proving the French and German theories each partially correct. It has been demonstrated that abnormal bone metabolism is at work in at least some patients with Charcot.[75-77] Whether Charcot arthropathy causes, is caused by, or results from a common etiologic factor along with altered bone metabolism has yet to be determined.

Growth and Development

Clinical disorders such as idiopathic leg length discrepancy, hemihypertrophy, and clubfoot, all represent focal abnormalities of bone development and morphology, but essentially normal resultant bone quality and properties. This suggests that an influence with local effects, but anatomically separate origin has been brought to bear. The nervous system is an obvious potential source for such an influence given its organization to deliver geographically specific signals from a central origin.

Musculoskeletal Pain

Orthopaedists have always appreciated that bone is richly supplied with pain sensitive fibers, thus explaining the pain associated with fractures, nonunions, inflammatory bone conditions, and neoplastic bone lesions. Perhaps, nerve pathophysiology may cause or worsen these clinical conundrums more than simply relay pain from them. For example, some of the pain in osteoarthritis has been attributed to vascular engorgement response to perivascular autonomic nerve dysfunction. Some neural pain phenoma in extremities have been associated with abnormal regional bone density. Regional osteopenia is one of the hallmarks of chronic regional pain syndrome or reflex sympathetic dystrophy. Transient osteoporosis is another painful bone lesion, associated with MRI evidence of marrow hyperemia. Such poorly understood disease processes, along with osteolytic syndromes like pubic osteolysis and acroosteolysis, may present unique opportunities to understand nerve-bone interaction.

Obesity and Bone Mass

Many theories have been proposed to explain why obese individuals are frequently protected from osteoporosis. Little is actually understood about the complex mechanisms of bone maintenance in obesity. Is it mechanical loading, among a relatively non-active population? Is it peripheral conversion of estrogen due to increased adipocytic metabolic tissue volumes? A large body of research regarding obesity and bone mass now centers around the effects of the adipocyte hormone leptin. But leptin does not seem to affect bone metabolism as an endocrine hormone. Instead via the hypothalamus and the sympathetic nervous system, leptin signals centrally and results in systemic peripheral bone loss. Clinical studies in this area are controversial and active. In a recent national study of over 5,000 U.S.

adults, serum leptin concentration did not appear to directly effect bone mineral density. Curiously, in younger men who are at lower risk of osteoporosis, this study showed a consistent inverse association of lower leptin levels and higher bone mineral density.[78] What are the implications? Do obese patients with supranormal leptin levels develop a centrally mediated resistance for both anorexic and antiosteogenic pathways? Will orthopaedic surgeons indicating obese patients (with theoretically better bone growth potential) for total joint replacement consider them to be better candidates for bone ingrowth prostheses rather than cemented prostheses, as has been suggested?[79] Much clinical investigation is still pending, but it is clear that the past maxims that obesity protects against osteoporosis through increased bone loading is too simple, given the current complex relationship between fat, the brain, and bone.

FUTURE DIRECTIONS

Nerve signals to bone are not necessarily the master controllers, but are now recognized as part of a vastly complex system for metabolic regulation in bone. The evolution of these findings are noteworthy, and at each step it has required scientists to recognize the importance of unexpected biological findings. First, nerves had to be recognized in bones. Then, the concept of neurons as one-way wires had to be challenged. Only now can we permit the thought that efferent and afferent may not be mutually exclusive descriptions.

To autocrine (self-signaling), paracrine (neighbor-cell signaling), and endocrine (systemic signaling via blood supply), perhaps neurocrine or axonocrine should be terms added to the vocabulary of hormone delivery. Nerves, even sensory efferents, clearly deliver signaling molecules in a unique way to the immediate milieu around bone cell surface receptors.

Given this newly conceived notion, the challenge is before us all. Much remains to be done. Basic scientists will remain diligent in the search for signals and their effects on cellular metabolic function, but enough information is now available that clinicians must begin to get involved in directing this science toward important questions of pathophysiology and disease.

REFERENCES

1. **Cooper RR, Milgram JW, Robinson RA.** Morphology of the osteon. An electron microscopic study. *J Bone Joint Surg Am* 1966; 48:1239-71.
2. **Cooper RR.** Nerves in cortical bone. *Science* 1968; 160:327-8.
3. **Calvo W, Forteza-Vila J.** On the development of bone marrow innervation in new-born rats as studied with silver impregnation and electron microscopy. *Am J Anat* 1969; 126:355-71.
4. **Duncan CP, Shim SS.** J. Edouard Samson Address: the autonomic nerve supply of bone. An experimental study of the intraosseous adrenergic nervi vasorum in the rabbit. *J Bone Joint Surg Br* 1977; 59:323-30.
5. **Hohmann EL, Elde RP, Rysavy JA,** et al. Innervation of periosteum and bone by sympathetic vasoactive intestinal peptide-containing nerve fibers. *Science* 1986; 232:868-71.
6. **Bhangu PS, Genever PG, Spencer GJ,** et al. Evidence for targeted vesicular glutamate exocytosis in osteoblasts. *Bone* 2001; 29:16-23.
7. **Serre CM, Farlay D, Delmas PD,** et al. Evidence for a dense and intimate innervation of the bone tissue, including glutamate-containing fibers. *Bone* 1999; 25:623-9.
8. **Chenu C, Serre CM, Raynal C,** et al. Glutamate receptors are expressed by bone cells and are involved in bone resorption. *Bone* 1998; 22:295-9.
9. **Espinosa L, Itzstein C, Cheynel H,** et al. Active NMDA glutamate receptors are expressed by mammalian osteoclasts. *J Physiol* 1999; 518 (Pt 1):47-53.
10. **Gu Y, Genever PG, Skerry TM,** et al. The NMDA type glutamate receptors expressed by primary rat osteoblasts have the same electrophysiological characteristics as neuronal receptors. *Calcif Tissue Int* 2002; 70:194-203.
11. **Laketic-Ljubojevic I, Suva LJ, Maathuis FJ,** et al. Functional characterization of N-methyl-D-aspartic acid-gated channels in bone cells. *Bone* 1999; 25:631-7.
12. **Peet NM, Grabowski PS, Laketic-Ljubojevic I,** et al. The glutamate receptor antagonist MK801 modulates bone resorption in vitro by a mechanism predominantly involving osteoclast differentiation. *Faseb J* 1999; 13:2179-85.
13. **Dobson KR, Skerry TM.** The NMDA-type glutamate receptor antagonist MK801 regulates differentiation of rat bone marrow osteoprogenitors and influences adipigenesis. *J Bone Miner Res* 2000; 15:S272.
14. **Mason DJ, Suva LJ, Genever PG,** et al. Mechanically regulated expression of a neural glutamate trans-

porter in bone: a role for excitatory amino acids as osteotropic agents? *Bone* 1997; 20:199-205.
15. **Taylor AF, Brabbs AC, Peet NM,** et al. Bone formation/resorption and osteoblast/adipocyte plasticity mediated by AMPA/Kainate receptors in vitro and in vivo. *J Bone Miner Res* 2000; 14:S37.
16. **Skerry TM, Taylor AF.** Glutamate signalling in bone. *Curr Pharm Des* 2001; 7:737-50.
17. **Bjurholm A, Kreicbergs A, Brodin E,** et al. Substance P- and CGRP-immunoreactive nerves in bone. *Peptides* 1988; 9:165-71.
18. **Hill EL, Elde R.** Calcitonin gene-related peptide-immunoreactive nerve fibers in mandibular periosteum of rat: evidence for primary afferent origin. *Neurosci Lett* 1988; 85:172-8.
19. **Hukkanen M, Konttinen YT, Rees RG,** et al. Innervation of bone from healthy and arthritic rats by substance P and calcitonin gene related peptide containing sensory fibers. *J Rheumatol* 1992; 19:1252-9.
20. **Imai S, Matsusue Y.** Neuronal regulation of bone metabolism and anabolism: calcitonin gene-related peptide-, substance P-, and tyrosine hydroxylase-containing nerves and the bone. *Microsc Res Tech* 2002; 58:61-9.
21. **Imai S, Tokunaga Y, Maeda T,** et al. Calcitonin gene-related peptide, substance P, and tyrosine hydroxylase-immunoreactive innervation of rat bone marrows: an immunohistochemical and ultrastructural investigation on possible efferent and afferent mechanisms. *J Orthop Res* 1997; 15:133-40.
22. **Bjurholm A, Kreicbergs A, Schultzberg M,** et al. Neuroendocrine regulation of cyclic AMP formation in osteoblastic cell lines (UMR-106-01, ROS 17/2.8, MC3T3-E1, and Saos-2) and primary bone cells. *J Bone Miner Res* 1992; 7:1011-9.
23. **Michelangeli VP, Fletcher AE, Allan EH,** et al. Effects of calcitonin gene-related peptide on cyclic AMP formation in chicken, rat, and mouse bone cells. *J Bone Miner Res* 1989; 4:269-72.
24. **Vignery A, McCarthy TL.** The neuropeptide calcitonin gene-related peptide stimulates insulin-like growth factor I production by primary fetal rat osteoblasts. *Bone* 1996; 18:331-5.
25. **Sakagami Y, Girasole G, Yu XP,** et al. Stimulation of interleukin-6 production by either calcitonin gene-related peptide or parathyroid hormone in two phenotypically distinct bone marrow-derived murine stromal cell lines. *J Bone Miner Res* 1993; 8:811-6.
26. **Millet I, Vignery A.** The neuropeptide calcitonin gene-related peptide inhibits TNF-alpha but poorly induces IL-6 production by fetal rat osteoblasts. *Cytokine* 1997; 9:999-1007.
27. **Drissi H, Hott M, Marie PJ,** et al. Expression of the CT/CGRP gene and its regulation by dibutyryl cyclic adenosine monophosphate in human osteoblastic cells. *J Bone Miner Res* 1997; 12:1805-14.
28. **Ballica R, Valentijn K, Khachatryan A,** et al. Targeted expression of calcitonin gene-related peptide to osteoblasts increases bone density in mice. *J Bone Miner Res* 1999; 14:1067-74.
29. **Hukkanen M, Konttinen YT, Santavirta S,** et al. Rapid proliferation of calcitonin gene-related peptide-immunoreactive nerves during healing of rat tibial fracture suggests neural involvement in bone growth and remodelling. *Neuroscience* 1993; 54:969-79.
30. **Aoki M, Tamai K, Saotome K.** Substance P- and calcitonin gene-related peptide-immunofluorescent nerves in the repair of experimental bone defects. *Int Orthop* 1994; 18:317-24.
31. **Zaidi M, Chambers TJ, Gaines Das RE,** et al. A direct action of human calcitonin gene-related peptide on isolated osteoclasts. *J Endocrinol* 1987; 115:511-8.
32. **Roos BA, Fischer JA, Pignat W,** et al. Evaluation of the in vivo and in vitro calcium-regulating actions of noncalcitonin peptides produced via calcitonin gene expression. *Endocrinology* 1986; 118:46-51.
33. **Struthers AD, Brown MJ, Macdonald DW,** et al. Human calcitonin gene related peptide: a potent endogenous vasodilator in man. *Clin Sci* (Lond) 1986; 70:389-93.
34. **Bjurholm A, Kreicbergs A, Terenius L,** et al. Neuropeptide Y-, tyrosine hydroxylase- and vasoactive intestinal polypeptide-immunoreactive nerves in bone and surrounding tissues. *J Auton Nerv Syst* 1988; 25:119-25.
35. **Hill EL, Elde R.** Distribution of CGRP-, VIP-, D beta H-, SP-, and NPY-immunoreactive nerves in the periosteum of the rat. *Cell Tissue Res* 1991; 264:469-80.
36. **Lundberg P, Lundgren I, Mukohyama H,** et al. Vasoactive intestinal peptide (VIP)/pituitary adenylate cyclase-activating peptide receptor subtypes in mouse calvarial osteoblasts: presence of VIP-2 receptors and differentiation-induced expression of VIP-1 receptors. *Endocrinology* 2001; 142:339-47.
37. **Ransjo M, Lie A, Mukohyama H,** et al. Microisolated mouse osteoclasts express VIP-1 and PACAP receptors. *Biochem Biophys Res Commun* 2000; 274:400-4.
38. **Togari A, Arai M, Mizutani S,** et al. Expression of mRNAs for neuropeptide receptors and beta-adrenergic receptors in human osteoblasts and human osteogenic sarcoma cells. *Neurosci Lett* 1997; 233:125-8.

39. **Lundberg P, Bostrom I, Mukohyama H,** et al. Neuro-hormonal control of bone metabolism: vasoactive intestinal peptide stimulates alkaline phosphatase activity and mRNA expression in mouse calvarial osteoblasts as well as calcium accumulation mineralized bone nodules. *Regul Pept* 1999; 85:47-58.
40. **Mukohyama H, Ransjo M, Taniguchi H,** et al. The inhibitory effects of vasoactive intestinal peptide and pituitary adenylate cyclase-activating polypeptide on osteoclast formation are associated with upregulation of osteoprotegerin and downregulation of RANKL and RANK. *Biochem Biophys Res Commun* 2000; 271:158-63.
41. **Cai Y, Xin X, Shim GJ,** et al. Pituitary adenylate cyclase activating polypeptide (PACAP) and vasoactive intestinal peptide (VIP) stimulate interleukin-6 production through the third subtype of PACAP/VIP receptor in rat bone marrow-derived stromal cells. *Endocrinology* 1997; 138:2515-20.
42. **Lerner UH, Lundberg P, Ransjo M,** et al. Helodermin, helospectin, and PACAP stimulate cyclic AMP formation in intact bone, isolated osteoblasts, and osteoblastic cell lines. *Calcif Tissue Int* 1994; 54:284-9.
43. **Winding B, Wiltink A, Foged NT.** Pituitary adenylyl cyclase-activating polypeptides and vasoactive intestinal peptide inhibit bone resorption by isolated rabbit osteoclasts. *Exp Physiol* 1997; 82:871-86.
44. **Strange-Vognsen HH, Arnbjerg J, Hannibal J.** Immunocytochemical demonstration of pituitary adenylate cyclase activating polypeptide (PACAP) in the porcine epiphyseal cartilage canals. *Neuropeptides* 1997; 31:137-41.
45. **Moore RE, Smith CK, 2nd, Bailey CS,** et al. Characterization of beta-adrenergic receptors on rat and human osteoblast-like cells and demonstration that beta-receptor agonists can stimulate bone resorption in organ culture. *Bone Miner* 1993; 23:301-15.
46. **Suzuki A, Palmer G, Bonjour JP,** et al. Catecholamines stimulate the proliferation and alkaline phosphatase activity of MC3T3-E1 osteoblast-like cells. *Bone* 1998; 23:197-203.
47. **Kusaka M, Oshima T, Yokota K,** et al. Possible induction of fatty acid cyclooxygenase in mouse osteoblastic cells (MC3T3-E1) by cAMP. *Biochim Biophys Acta* 1988; 972:339-46.
48. **Oshima T, Yoshimoto T, Yamamoto S,** et al. cAMP-dependent induction of fatty acid cyclooxygenase mRNA in mouse osteoblastic cells (MC3T3-E1). *J Biol Chem* 1991; 266:13621-6.
49. **Ducy P, Amling M, Takeda S,** et al. Leptin inhibits bone formation through a hypothalamic relay: a central control of bone mass. *Cell* 2000; 100:197-207.
50. **Takeda S, Elefteriou F, Levasseur R,** et al. Leptin regulates bone formation via the sympathetic nervous system. *Cell* 2002; 111:305-17.
51. **Zeng QQ, Jee WS, Bigornia AE,** et al. Time responses of cancellous and cortical bones to sciatic neurectomy in growing female rats. *Bone* 1996; 19:13-21.
52. **Kingery WS, Offley SC, Guo TZ,** et al. A substance P receptor (NK1) antagonist enhances the widespread osteoporotic effects of sciatic nerve section. *Bone* 2003; 33:927-36.
53. **Sakai A, Nakamura T, Tsurukami H,** et al. Bone marrow capacity for bone cells and trabecular bone turnover in immobilized tibia after sciatic neurectomy in mice. *Bone* 1996; 18:479-86.
54. **Ito M, Nishida A, Nakamura T,** et al. Differences of three-dimensional trabecular microstructure in osteopenic rat models caused by ovariectomy and neurectomy. *Bone* 2002; 30:594-8.
55. **Iwamoto J, Takeda T, Ichimura S,** et al. Comparative effects of orchidectomy and sciatic neurectomy on cortical and cancellous bone in young growing rats. *J Bone Miner Metab* 2003; 21:211-6.
56. **Brighton CT, Tadduni GT, Pollack SR.** Treatment of sciatic denervation disuse osteoporosis in the rat tibia with capacitively coupled electrical stimulation. Dose response and duty cycle. *J Bone Joint Surg Am* 1985; 67:1022-8.
57. **Iwamoto J, Takeda T, Katsumata T,** et al. Effect of etidronate on bone in orchidectomized and sciatic neurectomized adult rats. *Bone* 2002; 30:360-7.
58. **Dietz FR.** Effect of peripheral nerve on limb development. *J Orthop Res* 1987; 5:576-85.
59. **Hukkanen M, Konttinen YT, Santavirta S,** et al. Effect of sciatic nerve section on neural ingrowth into the rat tibial fracture callus. *Clin Orthop* 1995:247-57.
60. **Madsen JE, Aune AK, Falch JA,** et al. Neural involvement in post-traumatic osteopenia: an experimental study in the rat. *Bone* 1996; 18:411-6.
61. **O'Connor BL, Palmoski MJ, Brandt KD.** Neurogenic acceleration of degenerative joint lesions. *J Bone Joint Surg Am* 1985; 67:562-72.
62. **Hill EL, Turner R, Elde R.** Effects of neonatal sympathectomy and capsaicin treatment on bone remodeling in rats. *Neuroscience* 1991; 44:747-55.
63. **Cherruau M, Morvan FO, Schirar A,** et al. Chemical sympathectomy-induced changes in TH-, VIP-, and CGRP-immunoreactive fibers in the rat mandible periosteum: influence on bone resorption. *J Cell Physiol* 2003; 194:341-8.
64. **Adam C, Llorens A, Baroukh B,** et al. Effects of capsaicin-induced sensory denervation on osteoclastic resorption in adult rats. *Exp Physiol* 2000; 85:62-6.

65. **Ramnemark A, Nyberg L, Lorentzon R,** et al. Hemiosteoporosis after severe stroke, independent of changes in body composition and weight. *Stroke* 1999; 30:755-60.
66. **Maimoun L, Couret I, Micallef JP,** et al. Use of bone biochemical markers with dual-energy x-ray absorptiometry for early determination of bone loss in persons with spinal cord injury. *Metabolism* 2002; 51:958-63.
67. **Warden SJ, Bennell KL, Matthews B,** et al. Quantitative ultrasound assessment of acute bone loss following spinal cord injury: a longitudinal pilot study. *Osteoporos Int* 2002; 13:586-92.
68. **Garland DE, Stewart CA, Adkins RH,** et al. Osteoporosis after spinal cord injury. *J Orthop Res* 1992; 10:371-8.
69. **Bickel CS, Slade JM, Haddad F,** et al. Acute molecular responses of skeletal muscle to resistance exercise in able-bodied and spinal cord-injured subjects. *J Appl Physiol* 2003; 94:2255-62.
70. **Frost HM.** From Wolff's law to the Utah paradigm: insights about bone physiology and its clinical applications. *Anat Rec* 2001; 262:398-419.
71. **Singh RS, Craig MC, Katholi CR,** et al. The predictive value of creatine phosphokinase and alkaline phosphatase in identification of heterotopic ossification in patients after spinal cord injury. *Arch Phys Med Rehabil* 2003; 84:1584-8.
72. **Bravo-Payno P, Esclarin A, Arzoz T,** et al. Incidence and risk factors in the appearance of heterotopic ossification in spinal cord injury. *Paraplegia* 1992; 30:740-5.
73. **Lal S, Hamilton BB, Heinemann A,** et al. Risk factors for heterotopic ossification in spinal cord injury. *Arch Phys Med Rehabil* 1989; 70:387-90.
74. **Myerson MS, Henderson MR, Saxby T,** et al. Management of midfoot diabetic neuroarthropathy. *Foot Ankle Int* 1994; 15:233-41.
75. **Childs M, Armstrong DG, Edelson GW.** Is Charcot arthropathy a late sequela of osteoporosis in patients with diabetes mellitus? *J Foot Ankle Surg* 1998; 37:437-9; discussion 49.
76. **Herbst SA, Jones KB, Saltzman CL.** Pattern of Diabetic Neuropathic Osteoarthropathy Associated With Peripheral Skeletal Bone Mineral Density. *J Bone Joint Surg Br* 2004; In Press.
77. **Jirkovska A, Kasalicky P, Boucek P,** et al. Calcaneal ultrasonometry in patients with Charcot osteoarthropathy and its relationship with densitometry in the lumbar spine and femoral neck and with markers of bone turnover. *Diabet Med* 2001; 18:495-500.
78. **Ruhl CE, Everhart JE.** Relationship of serum leptin concentration with bone mineral density in the United States population. *J Bone Miner Res* 2002; 17:1896-903.
79. **Einhorn TA.** Brain, bone, and body mass: fat is beautiful again. *J Bone Joint Surg Am* 2001; 83-A:1782.

"KEEPING UP WITH THE JONESES"—THE STORY OF SIR ROBERT JONES AND SIR REGINALD WATSON-JONES

Mark Hagy, M.D.

Hugh Owen Thomas was born in 1834 in Liverpool, the son of a professional bonesetter. He was considered by many to be the father of British orthopaedics. Thomas' father sent Hugh Owen and his brothers to medical school, and in 1857 he qualified as a doctor in Edinburgh. He was considered a dynamic, eccentric, and exceptionally hard-working gentleman. In addition, he was extremely free-thinking and novel in his approach to fracture management. Because of his controversial nature and unique ideas, he was not accepted by the medical establishment and never received a hospital appointment.

Thomas performed operations in his own small hospital and fabricated all of his braces and appliances. He was loved by the people for caring for the underprivileged of Liverpool. Each Sunday he provided free medical care for the poor. In 1875, he published a book entitled *Diseases of the Hip, Knee and Ankle Joints.* The book described the use of braces in fracture management, including a splint that he used for treatment of femur fractures. Interestingly, this device persists today as the Thomas Splint used by Emergency Medical Personnel to temporarily stabilize femur fractures. In addition, he described the use of an ischial-bearing splint to treat tuberculosis of the knee (Figure 1). Both of these devices were innovative approaches to common problems. He also described a way in which hip flexion contractures could be assessed on physical exam, now known as the "Thomas test" Figures 2 a-b).

Figure 1. Thomas' ischial-bearing splint.

Figures 2A-B. Demonstration of the "Thomas test."

University of Iowa

Figure 3. Sir Robert Jones.

Figure 4. Sir Robert Jones and Agnes Hunt at Oswestry.[6]

SIR ROBERT JONES

Hugh Owen Thomas' nephew Robert Jones was born in 1857 (Figure 3). Robert's father was an architect who gave up his career to write, and consequently the family became quite poor. At 16, he left London and went to live with his uncle in Liverpool. He learned about fracture care and how to make the braces that Thomas utilized. He began his medical education in 1873 and finished in 1878. He continued to work with Thomas until Thomas' death in 1891. Robert preserved his uncle's legacy and enhanced his ideas of immobilization and fracture care. He worked hard as well, seeing approximately 7,000 patients a year working two Sundays a month. Jones was known for his especially strong Victorian work ethic combined with an extremely attractive personality. These traits laid the foundation for his career success.

HOW HIS LEGACY BEGAN

In 1888, Robert Jones was appointed surgeon to the Manchester Ship Canal Project, a seven-year project involving 20,000 workers. He organized a series of hospitals along the canal to receive and house the injured workers. He also had each of these facilities staffed by medical personal trained in fracture care. He personally dealt with 3,000 cases and carried out approximately 300 operations from his canal site alone. The canal provided the ideal setting for him to practice new techniques, expand the English medical establishment's knowledge of fracture care, and improve fracture management efficiency.

In 1899, he was appointed general surgeon to the Royal Southern Hospital in Liverpool. The following year, he met Agnes Hunt, who changed his life and the care of children in England forever. Agnes Hunt was a strong-willed woman who became a nurse after spending her childhood in Australia. Having suffered from a hip infection as a child, she used assistive devices to ambulate. In 1900, she developed a home for crippled children called the Base Church Home. Once weekly she took the children on a two-hour train ride from her facility to see Sir Robert Jones. He was impressed by

her strong will and the care she gave to the children. Moreover, she was enamored by his personality and his patient care skills. In 1903, she sought his care for her own chronic hip problems. He performed an irrigation and debridement followed by an eight month period of immobilization. His interest in caring for her children on a long-term basis increased, and in 1904 he began traveling to Base Church Home to care for the children on a weekly to bi-weekly basis. This relationship ultimately led to the development of the Robert Jones and Agnes Hunt Orthopaedic Hospital at Oswestry in 1921, which served Wales in the center of England (Figure 4).

ESTABLISHING THE SPECIALTY

At the end of the 19th century, orthopaedics was focused on the care of crippled children. Robert Jones, more than anyone else, was responsible for widening its scope to include the treatment of adults with disorders of the musculoskeletal system and the management of acute injuries. Robert Jones and Alfred Tubbe formed the British Orthopaedic Society on November 3rd, 1894. At that time, general surgeons carried out most fracture management. Because of the lack of participation by the general surgeons, the society ceased to function after four years. Most of the general surgeons had no interest in recognizing orthopaedics as a subspecialty or caring for fractures solely as a part of their practice. Nevertheless, Robert Jones was committed to improving orthopaedic care and fostering the specialization of orthopaedics.

His progressive attitude was exemplified by his incorporation of roentnograms into his practice. After hearing about the development of the roentgenogram in 1896, he went to Germany and returned with his own radiographic apparatus. He later wrote "the first x-ray in this country was taken by Thurston Holland and myself with a little tube and we were able to develop a photograph of a small bullet which was embedded in a boy's wrist."[3]

In 1905, he restricted his care to orthopaedics. Thereafter, he began to publish heavily on a wide variety of orthopaedic topics. In 1916, he published a book entitled *Injuries of Joints*, which was a textbook of orthopaedic surgery that dealt systematically with the diagnosis and treatment of acute fractures. Jones was profoundly interested in the treatment of fractures and he felt that they were being treated inadequately. He criticized the way in which fractures were treated in what he called "big teaching hospitals." He was quoted as saying, "If I were made dictator, I would have an accident center in each large city, where cases would be properly treated and I would have beds for adults in each orthopaedic hospital and a small hospital to act as a casualty clearing station."[3] Today these ideas seem straightforward, but in his era they were groundbreaking. It was many years before they were completely accepted.

He organized a similar scheme for disabled servicemen at Shepard's Bush Hospital in London at the beginning of World War I. It was during this time that he introduced the Thomas splint for fractures of the middle and lower third of the femur. This splint alone was said to reduce the morality of gunshots to the thigh from 80% to 20%. Later he was asked by the British government to become Major General Inspector for orthopaedics in the military, an appointment that outraged many general surgeons in London. His expertise in the management of musculoskeletal injuries was necessary as World War I brought on a significant number of bone and soft tissue injuries. Jones set up numerous orthopaedic centers throughout the country. In 1917, he wrote *Notes on Military Orthopaedics*, which at the time was indispensable to other surgeons throughout the United Kingdom who were not as proficient at fracture care.

Sir Robert Jones' accomplishments during the war facilitated his establishment of other societies, and in 1918 he founded the British Orthopaedic Association. His position as director of orthopaedics in the military meant that all orthopaedists trained at the time were taught by him. Following this period he was widely respected in the United States for his principles in fracture management and his mechanisms for dealing with a large volume of injuries, but he was actually less respected in Britain due to the opinions of the existing medical establishment.

END OF THE CAREER

At the end of his career, Sir Robert Jones published a paper entitled "Cure of the Crippled Children" with Robert Girdlestone from the University of Oxford. This paper was a critical analysis of the poor care of crippled children throughout England and proposed a scheme to deal with its shortcomings. This publication resulted in the founding of the Central Council for the Care of Cripples, an organization that built homes that housed crippled children. These facilities were equipped with operating rooms, gymnasiums, schoolrooms, play rooms and equipment shops. Sir Robert Jones died in 1933 at the age of 76. By 1935, England had 40 hospitals with a total of 6000 orthopaedic beds and 400 orthopaedic clinics.

SIR REGINALD WATSON-JONES

Sir Robert Jones served as an early mentor to Sir Reginald Watson-Jones, who was born in 1902 (Figure 5). Not of the same family, he was both a student of Robert Jones early in his career and his advocate fol-

Figure 5. Sir Reginald Watson-Jones.

lowing Sir Robert's death. Sir Reginald described himself as a "physician" designed to be a surgeon.[3] He was considered to be one of the most outstanding orthopaedic surgeons in the mid-twentieth century and is responsible for bringing the treatment of fractures to the specialized position it holds today.

Watson-Jones became interested in medicine after suffering from typhoid, and he ultimately chose orthopaedics after having a hemangioma removed from his leg. Early in his medical career Robert Jones recognized Reginald's talent and, in 1926, persuaded the Royal Liverpool Infirmary to appoint Watson-Jones as honorary assistant surgeon in charge of a new orthopaedic department and fracture clinic. In the early 1930's he hyphenated his name with his mother's maiden name in order to distinguish himself from all the other Jones' in his home city of Liverpool.

In the early 1930's he published his first paper in the *Journal of Bone and Joint Surgery* and thereafter published at least three manuscripts a year. However, he became most famous for his instructional course lectures on fractures that were held in the early 1930's. These sessions were so successful and so well attended that he was asked to write his notes into a fracture text. *Fractures and Joint Injuries* was published just prior to World War II.

Most surgeons at the time found the text to be concise and "non-academic," which was refreshing and enabled them to better understand the concepts. The

Figure 6. Airmen with fractured cervical spines playing cricket.[7]

text served as a guiding hand for all military surgeons during World War II. Prior to this, there had never been a fracture text that dealt as comprehensively with fracture management. This remained a standard reference for decades in dealing with fractures and was translated into many languages. Still today it is a highly demanded book in areas of the world where operative treatment is not practical. Ultimately, this text was usurped by the AO manual in the late 1950's and early 60's.

Following the publication of his book, he became a consultant orthopaedist of the rural Air Force, but remained a civilian. He felt that as a civilian he would have more influence on the advancement of orthopaedic care. He established ten units of 100-150 beds for the Royal Air Force throughout the country. Each unit was staffed by 2-3 surgeons. In addition, he was one of the first surgeons to prescribe rehabilitation as an essential part of care in order to assist soldiers in returning to war. He believed that injured airmen could return to battle following vigorous rehabilitation. His model ensured many men were able to fly again and participate in the war effort (Figure 6).

In 1942, he was asked to establish the Department of Orthopaedics and Accidents at the London Hospital. It was agreed that all fractures and trauma to the musculoskeletal system would be referred to the Department. This broke a long-standing tradition within the London teaching hospital and opened the door for other institutions to establish orthopaedic departments of their own. In 1945 he was knighted for his work with the Royal Air Force.

Sir Watson-Jones was also well known for his immaculate record keeping which was not common at the time due to the poor penmanship of most physicians. He had a secretary who went with him from each of his consulting rooms who kept record of what was said

Figure 7. Sir Reginald Watson-Jones pictured with Adrian Flatt while visiting the University of Iowa.[5]

and organized his notes to facilitate follow-up. Furthermore, he was a technically demanding surgeon who insisted on a complete "no touch surgical technique." He kept pristine operative fields. His assistants "often could expect a brisk and painful rap across the knuckles if any blood got on the surgical drapes."[3]

Experiences of physicians in England during the war translated into a huge volume of information worth publishing. As a result, he believed that an expansion of the *Journal of Bone and Joint Surgery* was needed. This led to an independent publication, the *Journal of Bone and Joint Surgery (British)*, which maintained close ties with the original journal. The first issue of the British JBJS was published in February 1948. Watson-Jones traveled and lectured extensively, and included the University of Iowa as one of his stops (Figure 7). He remained as editor until his death in 1972.

The Sir Watson-Jones philosophy on fracture management can be summarized in one sentence, "The cause of nonunion of fractures is inadequate immobilization and nonunion of fractures is due to failure of surgeons much more than the failure of osteoblasts."[3] He never agreed with Swiss philosophy that advocated primary internal fixation in order to avoid the "fracture disease" of prolonged immobilization.

Sir Robert Jones and Sir Reginald Watson- Jones laid the foundation for a strong history of British orthopaedics. They developed and expanded novel ideas for fracture management during the time of war. In addition, both published numerous papers that helped other physicians improve their knowledge and become more proficient in orthopaedic management. We are all indebted to Sir Reginald Watson-Jones and Sir Robert Jones for their vision and quest for excellence.

BIBLIOGRAPHY

1. The Newsletter of the British Orthopaedic Association, Issue #25, Spring 2002, p22-25.
2. The Newsletter of the British Orthopaedic Association, Issue #26, Autumn 2002, p 14-16.
3. WorldOrtho: History of Orthopaedics, p3-5. *www.worldortho.com/pg3.html*.
4. *Evolution of Orthopaedic Surgery*. Ed. Leslie Klenerman, London, England, Royal Society of Medicine Press, Champaign, Ill, Balogh International distributor, 2002. p 1-9.
5. **Buckwalter, J.A.** *Iowa Orthopaedic Journal*, Vol 14. 1994. p22-30.
6. **Peltier, Leonard F.** *Orthopedics: A History and Iconography.* Norman Publishing 1993 p152-158.
7. **Watson-Jones, Reginald.** *Fractures and Joint Injuries.* Vol I and II. 3rd edition. Baltimore, Williams and Wilkins Company, 1952.