VOLUME 25 2005

The Iowa Orthopaedic Journal

25th Anniversary Edition

Published by the Residents and Faculty of the Department of Orthopaedics, The University of Iowa

Editors: Kirk D. Clifford, M.D., and Anthony V. Mollano, M.D.

THE IOWA ORTHOPAEDIC JOURNAL

VOLUME 25, 2005

THE IOWA ORTHOPAEDIC JOURNAL

2005 • Volume 25
ISSN 1541-5457

EDITORS
Kirk D. Clifford, M.D.
Anthony V. Mollano, M.D.

STAFF ADVISERS
Joseph A. Buckwalter, M.D.
Jose A. Morcuende, M.D.

Editors' Note i
Editors Emeriti ii
Dedication—Lawrence D. Dorr, M.D. iii
2005 Graduating Orthopaedic Residents and Fellows vi
New Orthopaedic Faculty x
2004-2005 Schedule of Lectureships and Conferences xi
Bonfiglio Award and Iowa Orthopaedic Society Award xii

UNIVERSITY OF IOWA ORTHOPAEDIC RESIDENCY RESEARCH PROGRAM
Orthopaedic Residency Research Program Update
Charles L. Saltzman, M.D. xiii
Impact of Iowa Orthopaedic Resident Research Projects from 25 Years Ago
Joseph A. Buckwalter, M.D. xiv
A Look Back at Alumni Research Projects
George Brown, M.D. xv
Jack Lindstrom, M.D. xvi
Sterling Laaveg, M.D. xviii

TRIBUTE TO DR. IGNACIO PONSETI
Speeches at 90th Birthday for Ignacio V. Ponseti
Joseph A. Buckwalter, M.D. xix
Stuart L. Weinstein, M.D. xx
Ignacio V. Ponseti, M.D. xxiv

ARTHROPLASTY
Development of Imageless Computer Navigation for Acetabular Component Position in Total Hip Replacement
Lawrence D. Dorr, M.D.; Yuji Hishiki, R.N.; Zhinian Wan, M.D.; Deanne Newton, PA-C; Andrew Yun, M.D. 1
The Clinical Performance of Metal-on-Metal as an Articulation Surface in Total Hip Replacement
William T. Long, M.D. 10
Does Smoking Affect Implant Survivorship in Total Hip Arthroplasty? A Preliminary Retrospective Case Series
Russell D. Meldrum, M.D.; L. Daniel Wurtz, M.D.; Judy R. Feinberg, Ph.D.; William N. Capello, M.D. 17
Early Attempts at Hip Arthroplasty—1700s to 1950s
Pablo F. Gomez, M.D.; Jose A. Morcuende, M.D., Ph.D. 25
A Historical and Economic Perspective on Sir John Charnley, Chas F. Thackray Limited, and the Early Arthroplasty Industry
Pablo F. Gomez, M.D.; Jose A. Morcuende, M.D., Ph.D. 30
Total Hip Arthroplasty and Rehabilitation in Ambulatory Lower Extremity Amputees—A Case Series
Edward J. Nejat; Amy Meyer, PT; Pamela M. Sánchez; Sarah H. Schaefer; Geoffrey H. Westrich, M.D. 38
Case Report: Salmonella Infection following Total Hip Arthroplasty
Paul Y. Chong; Scott M. Sporer, M.D., M.S. 42

FOOT AND ANKLE
Epidemiology of Ankle Arthritis: Report of a Consecutive Series of 639 Patients from a Tertiary Orthopaedic Center
Charles L. Saltzman, M.D.; Michael L. Salamon, M.D.; G. Michael Blanchard, M.D.; Thomas Huff, M.D.; Andrea Hayes; Joseph A. Buckwalter, M.D.; Annunziato Amendola, M.D. 44

Salvage of Diffuse Ankle Osteomyelitis by Single-Stage Resection and Circumferential Frame Compression Arthrodesis
Charles L. Saltzman, M.D. 47
Systemic Blastomycosis with Osseous Involvement of the Foot: Case Report
Anthony V. Mollano, M.D.; Hala Shamsuddin, M.D.; Jin-Soo Suh, M.D. 53

PEDIATRICS
Significant Scoliosis Regression following Syringomyelia Decompression: Case Report
Anthony V. Mollano, M.D.; Stuart L. Weinstein, M.D.; Arnold H. Menezes, M.D. 57
Evaluation, Imaging, Histology and Operative Treatment for Dysplasia Epiphysealis Hemimelica (Trevor Disease) of the Acetabulum: A Case Report and Review
Dennis R. Wenger, M.D.; Mark J. Adamczyk, M.D. 60

ONCOLOGY
Case Report: Unusual Tibia Intramedullary Osteoid Osteoma in a Two-Year-Old
Matthew Halanski, M.D.; David C. Mann, M.D. 66
Unicameral Bone Cysts of the Pelvis: A Study of 16 Cases
Sommer Hammoud, B.S.; Kristy Weber, M.D.; Edward F. McCarthy, M.D. 69
Severe Periprosthetic Cortical Atrophy in the Skeletally Immature: A Report of Three Cases
Kevin B. Jones, M.D.; Joseph A. Buckwalter, M.S., M.D. 75

MUSCULOSKELETAL BASIC SCIENCES
Joint Contact Stress: A Reasonable Surrogate for Biological Processes?
Richard A. Brand, M.D. 82
***In Vivo* Healing after Capsular Plication in an Ovine Shoulder Model**
B. T. Kelly; A. S. Turner; M. Bansal; M. Terry; B. R. Wolf, M.D.; R. F. Warren; D. W. Altchek; A. A. Allen 95
Use of a Novel Joint-Simulating Culture System to Grow Organized Ex-Vivo Three-Dimensional Cartilage-like Constructs from Embryonic Epiphyseal Cells
Ilan Cohen, M.D.; Dror Robinson, M.D., Ph.D.; Eitan Melamed, M.D.; Zvi Nevo, Ph.D. 102
A Three-Dimensional Finite Element Model of the Radiocarpal Joint: Distal Radius Fracture Step-Off and Stress Transfer
Donald D. Anderson, Ph.D.; Balachandra R. Deshpande, Ph.D.; Thomas E. Daniel, M.S.; Mark E. Baratz, M.D. 108
Quantification of the Microstructural Anisotropy of Distraction Osteogenesis in the Rabbit Tibia
Kevin B. Jones, M.D.; Nozomu Inoue; John E. Tis; Edward F. McCarthy; Kathleen A. McHale; Edmund Y. S. Chao 118
***In Vivo* Longitudinal Assessment of Bone Resorption in a Fibular Osteotomy Model using Micro-computed Tomography**
Kimerly A. Powell; Larry Latson; Michael O. Ibiwoye; Alan Wolfman; Mark D. Grabiner; Maciej Zborowski; Yoshitada Sakai; Ronald J. Midura 123
Effects of Recombinant Hematopoietins on Blood-loss Anemia in Mice
Kevin B. Jones, M.D.; David W. Anderson, Ph.D.; Gregory D. Longmore, M.D., M.S. 129
Cytogenetics of Swarm Rat Chondrosarcoma
Jeff W. Stevens, Ph.D.; Shivanand R. Patil, Ph.D.; Diane K. Jordan, Ph.D.; James H. Kimura, M.D.; Jose A. Morcuende, M.D., Ph.D. 135
Limitations of Isokinetic Testing to Determine Shoulder Strength after Rotator Cuff Repair
David Yen, M.D. 141

SPORTS AND ARTHROSCOPY
ACL Tears in Collegiate Wrestlers: Report of Six Cases in One Season
Andrew J. Lightfoot, B.S.; Todd McKinley, M.D.; Matthew Doyle, M.S., ATC; Annunziato Amendola, M.D. 145
Direct Arthroscopic Distal Clavicle Resection: A Technical Review
Gregory N. Lervick, M.D. 149
Rare Bilateral Femoral Shaft Stress Fractures in a Female Long-Distance Runner: A Case Report
Kirsten L. Weind, Ph.D.; Annunziato Amendola, M.D. 157
Patellofemoral Realignment: Dynamic Intraoperative Assessment
Matthew Lavery, M.D.; John Bell, M.D.; Theresa Rickelman, D.O.; Andre Boezaart, MBChB, FFA(CMSA), Ph.D.; John P. Albright, M.D. 160
Treatment of Anterior Femoroacetabular Impingement with Combined Hip Arthroscopy and Limited Anterior Decompression
John C. Clohisy, M.D.; J. Thomas McClure, M.D. 164

A Review of Hip Arthroscopy and Its Role in the Management of Adult Hip Pain
Christopher M. Larson, M.D.; Jennifer Swaringen, M.D.; Grant Morrison, M.D. 172

SPINE AND REHABILITATION

A Future Model of Musculoskeletal Rehabilitation at the University of Iowa Hospitals and Clinics: Spanning the Continuum of Care
Joseph J. Chen, M.D. 180

Gluteus Medius Tendon Rupture as a Source for Back, Buttock and Leg Pain: Case Report
Dennis Bewyer, P.T.; Joseph Chen, M.D. 187

TRAUMA

Bigelow's Wire Technique for a Humeral Shaft Fracture: Brief Case Report and Historical Perspective
Twee Do, M.D.; Mack Clayton, M.D. 190

A Case Series and Review of Salvage Surgery for Refractory Humeral Shaft Nonunion following Two or More Prior Surgical Procedures
Todd A. Borus, M.D.; Edward H. Yian, M.D.; Madhav A. Karunakar, M.D. 194

Normal Leg Compartment Pressures in Adult Nigerians using the Whitesides Method
Johnson D. Ogunlusi, FMCS (Ortho); Lawrence M. Oginni, FMCS, FWACS; Innocent C. Ikem, FMCS (Ortho), FICS 200

HAND & WRIST

Scapholunate Instability following Dorsal Wrist Ganglion Excision: A Case Report
Hossein Mehdian, M.D.; Michael D. McKee, M.D., F.R.C.S.(C) 203

Familial Bilateral Carpal Tunnel Syndrome in a Nigerian Family: Case Report
Johnson D. Ogunlusi, FMCS (Ortho); Lawrence M. Oginni, FMCS, FWACS 207

INSTRUCTIONS FOR AUTHORS, 2006

Any original article, review article, case report, or essay relevant to clinical orthopaedic surgery, or the basic orthopaedic sciences will be considered for publication in *The Iowa Orthopaedic Journal*. Articles will be enthusiastically received from alumni, visitors to the department, members of the Iowa Orthopaedic Society, residents, and friends of the University of Iowa Hospitals and Clinics Department of Orthopaedics and Rehabilitation. The journal is published every June. The deadline to receive articles for the 2006 edition is Friday, February 4, 2006.

Published articles and illustrations become the property of *The Iowa Orthopaedic Journal*. The journal is peer reviewed and referenced in *Index Medicus*. Articles previously published will not be accepted unless their content has been significantly changed.

When submitting an article, it is essential to include:

1. The **original manuscript complete with illustrations**. The corresponding author must be clearly identified with mailing address, telephone/fax numbers and e-mail address. Manuscripts for accepted articles will not be returned.

2. A **structured abstract of no more than 300 words**. The abstract will precede the text of the published paper. An abstract is not needed for case reports. Original papers should have the following additional sections: **Introduction, Materials and Methods, Statistical Methods, Results, and Discussion.**

3. **References,** presented in the text by superscript numbers. The **bibliography** should list references in the order of their appearance in the text and be double-spaced. Abstracts or meeting transactions more than three years old should not be cited. The references should be numbered according to the sequence of citation in the text (not alphabetically) and should be in PubMed/Index Medicus format (for an example of this format, go to the National Center for Biotechnology Information [NCBI] web site www.ncbi.nlm.nih.gov/entrez/query.fcgi and search for specific reference citations).

4. **Legends** for all illustrations, listed in order of appearance and double-spaced. Explain what each illustration shows. Give magnification of all photomicrographs. Define all arrows and other such indicators appearing on the illustration. If an illustration is of a patient who is identified by a case number, include that case number in the legend.

5. **Illustrations**:
   a. One set of 5 x 7-inch, black-and-white, glossy prints of all photographs.
   b. Original drawings or charts.
   c. Color illustrations may be used if they convey information not available in black and white.
   d. In accordance with HIPAA, remove any writing that could identify the patient (e.g., names, initials, patient numbers, etc.) from radiographs and photographs.

6. **Electronic copies of all items one through four above**. These should be sent to diana-johannes@uiowa.edu. Special illustrations and photographs are exempt from this electronic requirement and should be mailed to the address listed below.

Preparation of manuscripts: Manuscripts must be typewritten and double spaced using wide margins. Write out numbers under 10 except percentages, degrees or numbers expressed as decimals. Direct quotations should include the exact page number on which they appeared in the book or article. All measurements should be given in SI metric units. In reporting results of surgery, only in rare instances can cases with less than two years of follow-up be accepted.

Preparation of photographs/illustrations: On the back of each photo and illustration, write the figure number, author's name and indicate the *top*. Send prints unmounted—paste or glue will damage them. Drawings, charts and lettering on prints should be done in black using white backgrounds. Put dates or initials in the legends, not on prints. Make lettering large enough to be read when drawings are reduced in size. When submitting an illustration that has appeared elsewhere, give full information about previous publication and credit to be given and state whether or not permission to reproduce it has been obtained.

+-+-+-+-+-+-+-+

Additional copies of these instructions may be obtained by writing to Diana Johannes, University of Iowa Hospitals and Clinics, Department of Orthopaedics and Rehabilitation, 200 Hawkins Drive, 01006 JPP, Iowa City, Iowa, 52242-1088 or by emailing diana-johannes@uiowa.edu, or you may refer to the Internet site www.uihealthcare.com/depts./med/orthopaedicsurgery/reearch/ioj.html.

Printed on acid-free paper effective with Volume XV, 1995.

EDITORS' NOTE

2005 represents a milestone for the *The Iowa Orthopaedic Journal (IOJ)*. We are pleased and honored to present an anniversary twenty-fifth edition.

This special edition symbolizes 25 years of excellence in orthopaedic research publications. We feel privileged to follow previous editors who have set high standards that we hope to emulate.

This 25th edition of the *IOJ* is the largest and most diverse edition to date, with collaboration from authors around the world. In keeping with the tradition of the *IOJ*, we have publications of scientific articles, reviews, case reports, and essays of both historical and philosophic interest. We foremost wish to acknowledge the time and dedication of those who have submitted manuscripts. We hope those who read this special edition will come away with increased knowledge and enthusiasm for the field of orthopedics.

We are pleased to have a large contribution from our own Orthopaedic Department (with submissions from residents, faculty and alumni) and from outside clinicians and scientists worldwide with close ties to Iowa.

The *IOJ* would not be possible without the dedicated support of our faculty and residents. Foremost, we would like to thank Diana Johannes, who has worked tirelessly to coordinate manuscripts, corporate advertisements, and department photos, and keep us on track (which in itself is a full-time job). We would like to recognize Dr. Jose Morcuende and Dr. Joseph Buckwalter for their continued support and leadership as faculty advisors for the *IOJ*.

A journal of this size and quality could not be possible without the tremendous support of our corporate sponsors. We thank them for their generosity and continued support, both in the care of patients and educational forums.

We hope you find this 25th anniversary edition of the *IOJ* as rewarding and stimulating as in years past. Congratulations to all who have had a part in making *The Iowa Orthopaedic Journal* a lasting icon.

Kirk D. Clifford, M.D.
Anthony V. Mollano, M.D.

IOWA ORTHOPAEDIC JOURNAL
EDITORS EMERITI

1981
Frederick R. Dietz
Randall F. Dryer

1982
John J. Callaghan
Randy N. Rosier

1983
Don A. Coleman
Thomas J. Fox

1984
Fred G. McQueary
Nina M. Njus

1985
Patrick M. Sullivan
Mark D. Visk

1986
John J. Hugus
Randall R. Wroble

1987
Thomas C. Merchant
Mark C. Mysnyk

1988
Richard A. Berger
David M. Oster

1989
James L. Guyton
Peter M. Murray

1990
Craig G. Mohler
Joseph E. Mumford

1991
Devon D. Goetz
Thomas K. Wuest

1992
Robert L. Bass
Brian D. Mulliken

1993
Kenneth J. Noonan
Lacy E. Thornburg

1994
George J. Emodi
James C. Krieg

1995
Steven M. Madey
Kristy L. Weber

1996
Jay C. Jansen
Laura J. Prokuski

1997
James S. Martin
Todd M. Williams

1998
R. Dow Hoffman
Darron M. Jones

1999
Matthew B. Dobbs
Dennis P. Weigel

2000
Gregory N. Lervick
Jose Morcuende
Peter D. Pardubsky

2001
Daniel Fitzpatrick, M.D.
Erin Forest, M.D.
Rola Rashid, M.D.

2002
Karen Evensen, M.D.
Stephen Knecht, M.D.

2003
Mark Hagy, M.D.
Christopher Sliva, M.D.

2004
Timothy Fowler
Michael Sander

DR. LAWRENCE D. DORR
IOWA ORTHOPAEDIC JOURNAL DEDICATION

We are thrilled to dedicate the 2005 *Iowa Orthopaedic Journal*, the 25th anniversary edition, to Dr. Lawrence D. Dorr of the Dorr Arthritis Institute of Centinela Hospital in Ingelwood, Calfornia. Dr. Dorr is dedicated to patient care, teaching, leadership, surgical innovation, research, worldwide humanitarian work, and philanthropy.

Dr. Dorr is a child of Iowa. The formative years for his creativity, work ethic, personality, and love of medicine and research all were lived in Iowa. His Methodist minister father and Christian educator mother were constant role models. He grew up in Iowa and lived at various times in Verina, Dayton, Osage, and Des Moines. He was in Iowa for high school, college, and medical school—at Des Moines Roosevelt High School, Cornell College in Mt. Vernon, and The University of Iowa School of Medicine in Iowa City, respectively. While in Iowa City, he met his wife Marilyn. She grew up in Toledo, Iowa. They have three children and one grandchild, none of whom have had the benefit of an education in Iowa or living in Iowa.

Dr. Dorr reflects, "My choice to become an orthopedic surgeon came after my experience in the military following my internship. I had spent my elective time at The University of Iowa with Dr. Hans Ehrenhaft and had planned to be a heart surgeon! I had rotated through the orthopedic service and recognized the greatness of the faculty at that time, which included Drs. Larson, Ponseti, Bonfiglio and Flatt. Each of these men clearly had a presence about them and they were very confident of what they did. I clearly remember Dr. Bonfiglio's pathology sessions at night, and I remember Dr. Flatt giving us a discussion on the hand. However, it was just another learning experience for me at that time.

"While I was in the military, I did anesthesia because I had obtained a master's degree in pharmacology when I was at Iowa. This was during the Vietnam War, and the military was short of anesthesiologists, so I was offered and accepted a position doing anesthesia. When I was doing anesthesia, I realized that orthopedics was more fun than any other surgery. I had been accepted for a general surgery residency, but I rescinded that prior to starting. I had to sit out one year, and then I began my orthopedic residency at USC-LA County Hospital.

"In the third year of my residency, I realized that I wanted to continue with an academic career in orthopedics, and so I wanted to do a fellowship. The chairman of my department was Dr. J. Paul Harvey, who had come to Los Angeles from the Hospital for Special Surgery in New York City. He called Special Surgery and arranged an interview and following that interview I was accepted to the Comprehensive Arthritis Fellowship there. I really had no experience with joint replacement during my residency, so I thought that this would be, if nothing else, a great learning adventure."

That fellowship was a career changing event for Dr. Dorr. He worked with Drs. Chitranjan Ranawat, and Allan Inglis at the Hospital for Special Surgery in New York City. During his residency at USC, almost no total joint replacements were done. Thereafter, total joint replacement became his passion. His career has focused on teaching, innovation, and performance of total hip and knee arthroplasty. He has been a pioneer in the design of porous-coated hip replacements. He helped introduce the use of hydroxyapatite-coated hip stems, and modern metal-on-metal hip arthroplasty in the United States. He has also worked to refine the posterior mini-incision hip exposure and has developed computer navigation systems for hip replacement.

Dr. Dorr is the only person who will have been president of all three United States joint replacement societies: The Knee Society (1990-1991), American Association of Hip and Knee Surgeons (1993-1994) and the Hip Society (2007). In 2000, the Lawrence and Marilyn Dorr Chair for Hip Research was endowed by the Dorr family for their gratitude to The University of Iowa Department of Orthopaedics for enabling his career.

The religious background of his family, his commitment to community learned in Iowa, and his desire to "give back" to medicine culminated in Dr. Dorr's formation of Operation Walk. Operation Walk is an orthopaedic medical mission organization that performs gratis total hip and total knee replacements in poorer countries worldwide, and for disadvantaged people in Los Angeles. In 2005, he received the Humanitarian Award from the American Academy of Orthopedic Surgeons for this work.

Dr. Dorr is deeply thankful for his upbringing in Iowa, the "Iowa values" ingrained in him, and the opportunity to contribute to the research endeavor of the Department of Orthopedics at The University of Iowa. He is thrilled that his legacy will be founded on being a graduate of the University of Iowa School of Medicine.

Department of Orthopaedics

Jin-soo Suh
2004-present

Brian Wolf
2003-present

Michael O'Rourke
2003-present

Sergio Mendoza
2003-present

Jose Morcuende
2001-present

Annunziato Amendola
2001-present

Joseph Chen
2000-present

Todd McKinley
1999-present

R. Kumar Kadiyala
1998-2004

Leon Grobler
1996-1999

Brian Adams
1993-present

Charles Saltzman
1991-present

John Callaghan
1990-present

David Tearse
1989-2000

Ernest Found
1987-present

Lawrence Marsh
1987-present

Curtis Steyers
1985-present

James Nepola
1984-present

Fred Dietz
1984-present

James Weinstein
1983-1996

Barbara Campbell
1982-1984

Charles Clark
1980-present

William Blair
1980-1997

William Pontarelli
1980-1984,
1999-2004

Joseph Buckwalter
1979-present

Thomas Lehmann
1978-1987

Arthur Steindler
1912-1949

Theodore Willis
1917-1918

Joseph Milgram
1926-1932

Ernest Freund
1932-1936

Thomas Waring
1932-1939

James Vernon Luck
1936-1939

Ignacio Ponseti
1946-present

Eberly Thornton
1946-1952

Robert Newman
1948-1956

Michael Bonfiglio
1950-1995

Carroll Larson
1950-1978

Adrian Flatt
1956-1979

Reginald Cooper
1962-present

Howard Hogshead
1964-1965

Maurice Schnell
1964-1965

Richard Johnston
1967-1970,
1998-present

Donald Kettelkamp
1968-1971

Gerald Laros
1968-1971

Richard Stauffer
1970-1972

John Albright
1971-present

Doug Mains
1972-1973

Bruce Sprague
1972-1979

Richard Brand
1974-2002

Mike Mickelson
1976-1981

Stuart Weinstein
1976-present

The University of Iowa
Roy J. and Lucille A. Carver College of Medicine

DEPARTMENT OF ORTHOPAEDICS AND REHABILITATION
STAFF, FELLOWS AND RESIDENTS 2004-2005

Row 1: Matthew Anderson (fellow), Teresa Mosqueda (res I), Phinit Phisitkul (res V), Joseph Buckwalter, Reginald Cooper, John Albright, Brian Adams

Row 2: J. Lawrence Marsh, Mohana Amirtharajah (res III), Anthony Mollano (res IV), Anthony Frisella (res IV), Timothy Fowler (res V), Michael Sander (res V), Aaron Altenburg (res III), Robert Kadoko (res V)

Row 3: Stuart Weinstein, Ned Amendola, Ajay Aggarwal (res III), Jin-soo Suh, Jose Morcuende, Christina Ward (res III), Sergio Mendoza, Michael Daines (res II), Kevin Jones (res III), Matthew DeWall (res III)

Row 4: Neil Segal, Brian Wolf, Michael Blanchard (fellow), Ernest Found, Matthew Lavery (res II), Evan Hermanson (res IV), Kirk Clifford (res IV), Fred Dietz, John Bell (res V)

Row 5: Morgan Jones (fellow), Michael Salamon (fellow)

2005 GRADUATING ORTHOPAEDIC RESIDENTS

John-Erik Bell, M.D.

John Bell was born in Chicago and has lived in South Dakota, Wisconsin, New Jersey, and Maryland. He received his A.B. in molecular biology from Princeton University and then went on to complete his M.D. at Johns Hopkins University School of Medicine. He met his wife, Jessica, during his first year at Johns Hopkins, and they were married just before moving to Iowa City. They now have a one-year-old son, Charles. John's hobbies include music, playing the cello, spending time with his family, and sleep. He will train next year at Columbia Presbyterian Hospital in New York City as a fellow in shoulder, elbow, and sports medicine. John and Jessica have enjoyed their time in Iowa greatly. John is grateful to have had the privilege of training under such outstanding faculty, alongside outstanding resident colleagues, and within a program of such rich tradition. He would like above all to thank Jessica for her support and patience through the past five years.

Timothy P. Fowler, M.D.

Tim was born and raised in Rockford, Illinois, and received his undergraduate degree at the University of Illinois in Champaign. Thereafter he attended medical school at the University of Chicago. Tim has known his wife, Lori, since high school, and they now share two wonderful children—Abby and Josh. Hobbies include parenting, running, movies, and drinking coffee. Upon completion of residency, Tim will begin a one-year fellowship at the Philadelphia Hand Center. He hopes to find work in the northern Illinois/southern Wisconsin area as a general orthopaedist with an interest in hand and upper extremity.

Robert Kadoko, M.D., M.S.

Robert was born and raised in a small town in Uganda, the last of nine children, in a strict home. After receiving a bachelor's degree in mechanical engineering, he emigrated to New York City where he went to City College and received a Master of Science in Engineering. Robert then worked for two years as a control systems engineer. He then entered medical school at Yale University where he received an M.D. in 2000. Robert came to Iowa City in June of 2000 and found it to be a very sophisticated cosmopolitan town. Upon completion of his residency, Robert plans to practice general orthopaedics in the outskirts of New York, where his American journey started many years ago. Robert would like to thank the faculty for their excellent guidance, as well as the residents for their support in times of need.

2005 GRADUATING ORTHOPAEDIC RESIDENTS

Phinit Phisitkul, M.D.

Phinit was born in Bangkok, the capital of Thailand. His father is a dermatologist who studied in Liverpool, England. His mother received her doctorate in chemistry in Nottingham, England. His older and younger brothers are also physicians training in the United States. In 1996, Phinit was awarded his medical degree with high honors from Chulalongkorn University. He completed his internship in Prajaksillapakom Army Hospital, where he became a 1st Lieutenant in the Royal Thai Army. He then completed a four-year orthopaedic residency at Phramongkutklao Hospital, one of the renowned orthopaedic institutions in Thailand. There, he received the top score on the orthopaedic-in-training examinations in 1999, 2000, and 2001, as well as the orthopaedic basic science examination in 1999. After completing his residency, Phinit became a staff physician at the Phramongkutklao Hospital and the Sulprasittiprasong Hospital. Dr. Keokarn, President of the Royal College of Orthopaedics, helped Phinit arrange to come to The University of Iowa for further specialized orthopaedic training. Phint completed two years as a senior resident in the Orthopaedics residency here. Next year, he will work as a fellow with Dr. Charles Saltzman and the foot, ankle, and sports services. Ultimately, Phinit plans to return to Thailand to share his new fund of orthopaedic knowledge garnered at The University of Iowa. Phinit, his wife, and their baby son are enjoying Iowa City. They appreciate all that the Orthopaedics Department has done for them.

Michael D. Sander, M.D.

Michael was born in Harlingen, Texas, to Mike and Claudia Sander. He was raised in Weslaco, Texas, with his two younger brothers and a sister. He left the Rio Grande Valley and headed north to Austin for an undergraduate degree in biology at The University of Texas. He met Jennifer at U.T. and they were married in 1999. After receiving his M.D. from Baylor College of Medicine in Houston, he and Jennifer moved to Iowa City for his residency. Jennifer is an R.N. in the Pediatric ICU at UIHC. They have one son who will always be part Hawkeye, Henry, and another son on the way. Next year Michael will do a fellowship in Sports Medicine with Dr. Jesse DeLee in San Antonio, Texas. Michael and Jennifer wish to express their gratitude to everyone in the Orthopaedics Department and the PICU who have helped make their stay in Iowa City a great experience.

2004-2005 FELLOWS

Matthew Anderson, M.D.

Matt grew up in Wakefield, Nebraska. He attended the University of South Dakota in Vermillion where he earned a Bachelor of Science degree in Mathematics and Biology. He then attended the University of South Dakota School of Medicine, earning his medical degree in 1999. Matt came to Iowa for fellowship training in hand surgery after graduating from the orthopaedic residency program at the University of Kansas-Wichita. Matt has enjoyed his time at the University of Iowa. Attending Hawkeye football games has eased the pain of being a Nebraska Cornhusker and Denver Bronco fan. After fellowship, Matt plans to practice in the Midwest.

Michael Blanchard, M.D.

Mike was born and raised in Baton Rouge, Louisiana. He attended Louisiana State University, where he earned a bachelor's degree in zoology. He received his medical degree from Louisiana State University Medical Center in New Orleans, Louisiana, and completed his orthopaedic residency at Vanderbilt University Medical Center in Nashville, Tennessee. He is currently one of the Foot and Ankle / Sports Medicine fellows at the University of Iowa. Mike, his wife Tricia, and their children have enjoyed their time in Iowa City. At the completion of his fellowship, they will be moving back home to Baton Rouge, Louisiana, where Mike will be joining the Baton Rouge Orthopaedic Clinic.

Morgan Jones, M.D.

Morgan was born and raised in Columbus, Ohio. He received his bachelor's degree at The Ohio State University where he was a member of the varsity swimming team, and where he met his wife, Molly. He stayed at Ohio State for medical school and then moved to the Bronx, New York, for his orthopaedic residency at the Montefiore Medical Center and Albert Einstein College of Medicine. Morgan is excited to be at the University of Iowa for his fellowship training in sports medicine and looks forward to pursuing an academic career next year.

Michael Salamon, M.D.

Mike was born in Madison, Wisconsin and grew up in Stockton, California. He graduated with a Bachelor of Science degree from the University of Michigan. He received his M.D. degree from Jefferson Medical College in Philadelphia, PA. Mike completed a residency in orthopaedic surgery at University of California—Davis in Sacramento, California. After completing his fellowship in foot and ankle reconstruction/sports medicine at the University of Iowa, he will begin private practice in Louisville, Kentucky. Mike and his wife, Beth, have two children, Alex (3 yrs) and Jack (8 mos).

DORIS DUKE CLINICAL RESEARCH FELLOWSHIP

Matthew Lovell

Matthew grew up in Tremont, Illinois.

He attended Wheaton College where he earned his Bachelor of Science degree in chemistry and met his wife, Alyssa.

Matthew is currently a student in the University of Iowa Carver School of Medicine and was accepted to the Doris Duke Clinical Research Fellowship. The fellowship allows medical students to spend a year doing clinical research during their medical school career. Matthew is spending his research year at The University of Iowa where he is doing research in the orthopaedics department on the treatment of clubfoot. After his year of research, he will head back to medical school to finish his clinical years. He will be graduating in May 2007 and is looking forward to seeing where the match takes him for residency.

NEW ORTHOPAEDIC FACULTY

Jin-soo Suh, M.D.

Jin-soo was born and raised in Taeieon in the center of South Korea. He received his medical degree from Seoul National University and completed his orthopaedic residency at Seoul Paik Hospital. He then served three years as a military surgeon, including one year in the Western Sahara as an officer in a United Nations force. In 1998, he entered a year-long hand and microsurgery fellowship in Seoul Paik Hospital. He then went to Austria as an AO Hand Fellow at University Clinic in Innsbruck, and to Bologna, Italy as a hand fellow at the Instituto Rizzoli. On his return to Korea, he worked mostly in hand and trauma surgery as a staff physician. In 2000, his interests broadened to include foot and ankle surgery, which was a new field in orthopaedics in Korea at the time. In 2003, he came to Iowa to further his clinical and research study of foot and ankle surgery with Dr. Charles Saltzman. He is now joining our faculty with an interest in foot and ankle surgery. Jin-soo's wife studied with Dr. El-Khoury in Radiology for about one-and-a-half years before returning to Korea for work. Jin-soo and his daughter remain in Iowa and have enjoyed Iowa life and the kindness of so many people here. When time allows, he and his family enjoy skiing.

2005-2006
DEPARTMENT OF ORTHOPAEDICS AND REHABILITATION
SCHEDULE OF LECTURESHIPS AND CONFERENCES

(Larson Conference Room, 01090 JPP)

Carroll B. Larson Shrine Memorial Lecture
April 29-30, 2005
James Beaty, M.D.
Chief of Staff
Campbell Clinic
Memphis, Tennessee

Iowa Orthopaedic Alumni Meeting
October 27-29, 2005
Ken Yamaguchi, M.D.
Washington University
St. Louis, MO

Jo Hanafin, M.D.
2nd Ruth Jackson Memorial Lecturer
Hospital for Special Surgery
New York, New York

21st Annual Hawkeye Sports Medicine Symposium
December 2-3, 2005
Sheraton Hotel, Iowa City, IA
Scott F. Dye, M.D.
Associate Clinical Professor of Orthopaedic Surgery
University of California
San Francisco, California

Tim Hewett, Ph.D.
Director, Sports Medicine Research
Cincinnati Children's Hospital
Cincinnati, Ohio

Reginald R. Cooper Orthopaedic Leadership Lectures
April 2006*

2006 Senior Residents and Fellows Day
June 2-3, 2006*

Eighth Biennial Johnston Lectureship in Hip Reconstruction
October 2006*

*Please check with us at a later time for exact dates, times and speakers.

The Michael Bonfiglio Award for Student Research in Orthopaedic Surgery

The Iowa Orthopaedic Society Medical Student Research Award for Musculoskeletal Research

The University of Iowa Department of Orthopaedics and Rehabilitation, along with the Iowa Orthopaedic Society, sponsors two research awards involving medical students.

The first, the Michael Bonfiglio Award, originated in 1988 and was named in honor of Mike, who had an avid interest in students, teaching and research. The award is given annually at a medical convocation. It consists of a plaque and a stipend to be used for the purchase of an orthopaedic text. It is awarded to a senior medical student in the College of Medicine who has done outstanding orthopaedic research during his or her tenure as a medical student. The student often has an advisor in the Orthopaedic Department; however, the student must have played a major role in the design, implementation and analysis of the project. They must also be able to defend the manuscript in public forum. The research project may have been either clinic or basic science, and each study is judged on the basis of originality and scientific merit. The winner presents their work at the April meeting of the Iowa Orthopaedic Society.

The second award is the Medical Student Research Award for Musculoskeletal Research for students in the College of Medicine who provide a research project involving orthopaedic surgery during one of their first three years. The award consists of a $2000 stipend, $500 of which is designated as a direct award to the student and $1500 of which is designated to help defray continuing costs of the project and its publication. The student must provide an abstract and a progress report on the ongoing research. The aim of this award is to stimulate research in the field of orthopaedic surgery/musculoskeletal problems.

This year, the committee consisting of a member of the Iowa Orthopaedic Society (Dr. Devon Goetz) as well as members of the Orthopaedics and Rehabilitation Department (Drs. Charles Clark, Curtis Steyers, Brian Wolf, Jose Morcuende and Joseph Buckwalter) recommended that the award be given to the two following students: Jeremy Gardner won the Michael Bonfiglio Award for Student Research for 2005 and Andrew Lightfoot won the Iowa Orthopaedic Society Medical Student Award for Musculoskeletal Research.

The Michael Bonfiglio Award and the Iowa Orthopaedic Society Medical Student Research Award for Musculoskeletal Research are very prestigious, recognizing student research on the musculoskeletal system. These awards have indeed attained their goal of stimulating such research and have produced many fine projects over the years.

Charles R. Clark, M.D.
Michael Bonfiglio Professor of Orthopaedic Surgery

ORTHOPAEDIC RESIDENCY RESEARCH PROGRAM UPDATE

Charles L. Saltzman, M.D.

Resident research is a cornerstone of the Iowa orthopaedic training program. The current program has evolved over the years with the input of many devoted faculty. Dr. Richard A. Brand administered the program for many years with excellent productivity. For the last few years, I have been able to help with the program and now realize the enormous effort from the faculty, residents and support staff that goes into each project.

The goals of the program are several, and include: 1) to make meaningful contributions to the field of orthopaedic surgery, 2) to stimulate independent scientific thinking, 3) to help residents recognize the intrinsic value of performing laboratory or clinical research, and 4) to familiarize residents with research methodologies.

The Iowa Orthopaedic Resident Research Program involves all five years of residency. In the first two years, the resident identifies a project and a faculty mentor, and defines the project with the help of his "committee." This is then presented to the entire department. After modifications are made, the project is scheduled for execution. In the third or fourth year, each resident completes their project. In general, these are presented during the fifth year at national meetings. More than half have been published in our top journals.

All projects cost money. The current resident group has been incredibly successful in obtaining external funding—especially from the Orthopaedic Research and Education Foundation. Although this helps, it does not cover all the costs. With personal money, the faculty has established a new fund to specifically finance resident research projects. We hope to grow this fund to be able to cover the essential costs inherent in all projects in the future.

We believe that resident research is as important an educational experience as any in orthopaedic training. This is equally true for either academic or private-practice-bound surgeons. The accompanying "long-term follow-up" reports of our distinguished alumni are testimony to the critical importance of a vibrant resident research experience. With the generous financial support of our grateful patients, alumni and faculty to the Iowa Orthopaedic Resident Research Fund, I hope that this great tradition will continue as a cornerstone of our training program.

IMPACT OF IOWA ORTHOPAEDIC RESIDENT RESEARCH PROJECTS: A LOOK AT THREE PROJECTS FROM 25 YEARS AGO—A COMMENTARY

Joseph A. Buckwalter, M.D.

Resident research has long been a hallmark of the University of Iowa Hospitals and Clinics Department of Orthopaedics and Rehabilitation. The graduates of the Iowa program and faculty appreciate well that participating in a rigorous research makes an individual a better physician and surgeon. It prepares them to understand how new knowledge affects practice, how that knowledge is developed, and how to critically analyze new procedures, approaches and ideas. The three individuals whose commentaries are included in this issue of the *Iowa Orthopaedic Journal* had the opportunity to work with Dr. Ponseti as part of their research.

George Brown left The University of Iowa for Alaska where he enjoyed a demanding and challenging practice before returning to academic medicine at the University of New Mexico. More recently, George moved to an academic position at Oregon Health Sciences University. During his resident years, George's exceptional talent, enthusiasm, and love of teaching inspired many of his junior residents, including myself. George is always positive and always striving to improve his clinical skills.

Jack Lindstrom left The University of Iowa for the Air Force and was part of the Air Force health care delivery system for two years before entering private practice in Appleton, Wisconsin. Jack was a role model as a resident and taught many of his junior residents, including myself, the satisfaction that comes from constantly improving your skills and knowledge and providing exceptional care for your patients.

Sterling Laaveg was a classmate of mine in medical school and preceded me in the orthopaedic residency. It was always a pleasure to work with Sterling. He had great ideas, was an excellent teacher, surgeon, and physician and like Jack and George, loved the practice of orthopaedics. Sterling left the University to practice in Mason City where he built a large practice and served as President of the Iowa Medical Society. Sterling recently retired, but he continues to follow events in the department and in orthopaedics with great interest.

As their commentaries indicate, all three of these gifted and committed orthopaedic surgeons were significantly influenced by their research experience and their work with Dr. Ponseti.

DR. GEORGE BROWN—1976 RESIDENT RESEARCH PROJECT

CONGENITAL PSEUDARTHROSIS, FIBROUS DYSPLASIA, AND NEUROFIBROMATOSIS: CLINICAL, PATHOLOGIC, AND ULTRASTRUCTURAL STUDY

Brown, GA; Osebold, WR; Ponseti, IV. "Congenital Pseudarthrosis of Long Bones: A Clinical, Radiographic, Histologic and Ultrastructural Study," *Clinical Orthopedics and Related Research*, Vol. 128, Oct: p228-42, 1977.

One of the exciting things about my residency at The University of Iowa was the opportunity to combine my clinical experience with work in pathology and studies of the ultrastructure of bone. I was very interested in congenital pseudarthrosis of the long bones. Stimulated by Dr. Jerry Maynard, I started working in the orthopaedic ultrastructural laboratory established by Dr. Cooper.

My interest in congenital pseudarthrosis led me to work with Dr. Ponseti, and I found that he had been treating 17 patients in Iowa with this rare condition. By 1975, he had 20- to 30-year follow-up for these patients. In looking at the clinical series, I was impressed that if a patient was under age two when the leg fractured, and the x-ray showed tapering and sclerosis of the bone ends, nonunion universally resulted: operations and any other procedure that attempted to achieve union failed. Amputation of the lower leg and a standard prosthesis allowed these children to continue their lives with few or no further surgeries with good and excellent functional outcomes. This impression was borne out by the observation that only two of the 17 patients had healed their tibial pseudarthroses, despite 59 operations on this group. One of the many things I learned from Dr. Ponseti while working on this project was a sense of when to quit trying to fix the unfixable and instead help the patient achieve the best possible function.

I was very pleased with the results of my basic science and clinical study of congenital pseudarthrosis and had the opportunity to present findings at the International Pediatric Orthopaedic Meeting in Chicago in 1975.

In addition to all I learned during research, I found that this project helped me know Dr. Ponseti and learn from him. He told me that he was once considered an aggressive surgeon because he operated to lengthen the heel cords of patients with clubfeet. He also taught me that patients with idiopathic scoliosis may have less pain than the general population. It is interesting and satisfying to see that Stu Weinstein has pursued this idea with his 50-year follow-up study of patients with idiopathic scoliosis.

There is no question that working with Dr. Ponseti on this research project affected my career. I use what he taught me daily. I am so pleased to see that the Ponseti Technique for clubfeet is now rapidly becoming the standard of care. When I first started in practice, I bought the Turco videotape on comprehensive clubfoot surgery because I was concerned that I did not have enough experience with surgical treatment of clubfeet during my residency. I found that I never needed the Turco tape and that the Ponseti Technique has worked well in all my years of practice. I also enjoyed the opportunity to work closely with Dr. Bonfiglio at Iowa and learned a great deal from him about the importance of studying pathology and pathophysiology. Both Dr. Ponseti and Dr. Bonfiglio taught me to be patient as a teacher.

As I look back on my resident research project and my years at Iowa, I recognize how much both the teaching I received and the research work I did have affected my career for the better. It is great to see the continuation of the Iowa traditions of resident research and teaching that stress critical analysis, combining all available data and questioning established concepts and ideas.

JACK LINDSTROM—1977
RESIDENT RESEARCH PROJECT

ACETABULAR DEVELOPMENT, PROXIMAL FEMORAL DEVELOPMENT, AND FUNCTIONAL IMPLICATIONS

Lindstrom, JR; Ponseti, IV; Wenger, DR: "Acetabular Development after Reduction in Congenital Dislocation of the Hip," *Journal of Bone and Joint Surgery*, American Vol. 61(1), p. 112-8, 1979.

As I recall, my resident research efforts started in the academic year of 1975-76 which I think was Denny Wenger's last year in Iowa City. The idea for the study of acetabular development was not mine: I believe it grew out of discussions between Denny Wenger and Dr. Ponseti. I had some concern about starting this project since it was Dr. Ponseti's opinion that there was great developmental potential for the acetabulum, and that if we found this in our study we would call into question points that had been "well established" by the well-known authority Bob Salter.

Taking advantage of the outstanding facilities in the department and Dr. Ponseti's guidance and private collection of patient radiographs, Denny Wenger and I began to outline the parameters of the study and gather x-rays in order to mark and measure the development of the acetabulum. Needless to say, there were many patients and each patient had numerous x-rays. When we were residents, most of us, with or without our research, felt that our lives were very busy. Looking back, I don't know how we found time to complete this extensive, detailed, meticulous review. I can certainly remember the many hours I spent feeling as though I was drowning in radiographs and wax pencils.

When I started I was totally unfamiliar with computer analysis, but I recall we were able to transfer our data to "IBM cards" in order to initiate the analysis. I think at that time the cards were then placed in an off-the-shelf data analysis program which produced computer print-outs that were nearly as voluminous as the radiographs. The correlations that were generated were sometimes along the lines of our investigational questions, but in other cases they seemed to be correlations that were totally unrelated to any of our questions, or did not make sense clinically.

When I started writing the paper, I had high hopes that it would be accepted for publication; however my major was biology, not English. I expect Dr. Ponseti will readily attest to that fact. I often brought him sections of the paper that I thought were fairly well-written and concise and he would literally take them apart and put them back together word for word, time and time again. I was disappointed not to be able to learn to write as Dr. Ponseti wanted, and the process was at times humbling and frustrating, but he was always patient and I learned how to organize my thoughts and express myself in writing more clearly.

As I had expected, in the spring of 1977 I found myself frantically trying to put the finishing touches on my paper for presentation at the Senior Residents Day conference and also at the Academy meeting in New Orleans. The presentation at the Academy was a thrill. Prior to the presentation, I had visions of Dr. Bob Salter taking me to task on a topic that was clearly well within his level of expertise, but not mine. Fortunately, Dr. Ponseti had arranged for Dr. Bill Smith from Michigan to review the paper and raise some gentle questions in the discussion. I felt lucky to have survived the Academy presentation and the Senior Residents Day presentation in the spring of 1977.

Dr. Ponseti was generous with his praise as well as in encouraging me to continue to work and revise and polish the paper so it could be accepted by the *Journal of Bone and Joint Surgery*. If I thought writing to satisfy Dr. Ponseti's taste and style was a challenge, I was not ready for the even greater challenge of writing in a style that was acceptable to the editors of the *Journal of Bone and Joint Surgery*. My recollection is that some of the comments from the *Journal of Bone and Joint Surgery* editors surprised even Dr. Ponseti, and I think he felt some of the frustration that I was experiencing.

I left Iowa City in the spring of 1977 to start a two-year active duty assignment with the United States Air

Force in Rantoul, Illinois. I had just gotten married in the fall of 1976 and our first child, a son, was born in June 1978. This is pertinent because I will never forget returning to Iowa City to visit with Dr. Ponseti and his wife Helena in their home. They were kind enough to include my wife, Ann and our son, John, who at that point was less than a year old. Our family will always cherish the picture of Dr. Ponseti in one of his British driving caps, with our son John sitting in his lap and basking in the warm glow of Dr. Ponseti's affection.

Looking back, I was very fortunate to have been a resident at Iowa. I gained much more from it than I was able to return during the years I spent in the department. My skills did not then, and do not now, lend themselves toward original research. Along with many others, I have found myself wrapped up in the business of the practice of medicine throughout my career. Nonetheless, I will never forget my experiences in Iowa City in the Department of Orthopaedics. I will always remember my outstanding colleagues who have gone on to distinguish themselves nationally and internationally, and I have always felt privileged to have been able to work with them and share in the remarkable environment in Iowa City. I do look back on my resident research project with great fondness, not just for all I learned about development of the acetabulum, how to write for publication and how to analyze data, but for the close relationship I developed with Dr. Ponseti during the process and the depth of understanding I gained from working with him on this research project.

STERLING LAAVEG—1976
RESIDENT RESEARCH PROJECT

LONG-TERM RESULTS OF CLUBFOOT TREATMENT

Laaveg SJ, Ponseti IV: Long-term results of the treatment of congenital clubfoot. *J Bone Joint Surg* 62A:23-31, 1980.



The opportunity to work with Dr. Ponseti on my long-term clubfoot study was a critical event in my career. Dr. Ponseti continues to be an inspiration to me. His life story of fleeing from Spain when Franco arose to power, then finding his way from Spain to Mexico and then to Arthur Steindler's orthopaedic program in Iowa City still thrills me. His lifelong commitment to the science of musculoskeletal medicine, his clinical and scientific accomplishments and the large number of talented orthopaedists he has taught make him one of the greatest figures in the history of orthopaedics, and I am so pleased that he continues to have the enthusiasm and zeal to pursue new knowledge, teach and improve treatment for orthopaedic patients.

In 1976, I was naive when I began the study of children treated with clubfoot and the changes that may have occurred over time. The tasks of locating adult patients treated as children, arranging follow-up schedules, developing follow-up function questions, selecting physical examination parameters, defining radiographic measurements, collecting raw data, correlating meaningful data and drawing appropriate conclusions were far more formidable than I had imagined in the start. Dr. Ponseti was always gracious, patient and helpful in advising me and encouraging me to continue. At the time I was performing this study it seemed very time consuming, but in retrospect I realize the time was well worth it, and it was not as much of a burden as I may have thought at the time.

Selecting the pertinent data and drawing meaningful conclusions for presentation at my Senior Residents' Day Conference was difficult; but writing a paper, dealing with the multiple revisions, and having it finally accepted for journal publication was truly daunting. Dr. Ponseti was extremely helpful and uniformly positive throughout this process and always gave me thoughtful advice, support and encouragement whenever I hit an impasse.

The opportunity to perform this study of clubfoot treatment taught me that good quality research is difficult and hard to deliver in a meaningful format that contributes to the science and clinical practice of orthopaedic surgery. The effort left me with a much better understanding and appreciation for the work of other clinicians and scientists and gave me throughout my career the critical eye I needed to review scientific work. It was clearly one of the most valuable experiences of my residency.

Dr. Ponseti, always with his dry sense of humor, once told me as I was putting a clubfoot cast on a newborn baby, "Poor baby! Your hands are so big, Dr. Laaveg." Dr. Ponseti was smiling at me, but the mother of the child looked nervous. My opportunity to work so closely with Dr. Ponseti in this program allowed me to come to know him well. He is a rare gem to me as well as to patients, students, residents and physicians.

SPEECH AT 90TH BIRTHDAY FOR DR. IGNACIO PONSETI, JUNE 8, 2004

Joseph A. Buckwalter, M.D.

Welcome to the celebration of the 90th birthday of a friend, colleague, one of the most remarkable faculty members in the history of The University of Iowa, and an inspiration for us all—Dr. Ignacio Ponseti.

Much can and should be said about Dr. Ponseti's skilled and compassionate medical care, his inspirational teaching and his commitment to The University of Iowa Orthopaedics Department. I want to comment on one of his most important contributions to the specialty of orthopaedics—his life-long effort to give orthopaedics a firm foundation in biology, an effort that has benefited millions of patients throughout the world.

Orthopaedics is a very physical specialty—we use cables, saws, hammers, drills, nails, screws, plates and cement, and from time to time, a certain amount of physical force. I recall, several years ago, when I sent a grant proposal to the University Vice President for Research, a very thoughtful and knowledgeable person for whom I have the greatest respect. He made a number of very helpful comments and then said this is a pretty good proposal, I thought you guys were over there pounding nails into people's bones.

If we are doing more than pounding nails into bones, Dr. Ponseti deserves much of the credit. I remember Dr. Ponseti's observation that while orthopaedic surgeons were refining their techniques of joint fusion and tendon transfers for the treatment of limbs paralyzed by polio, others were finding the cause of the disease and, eventually, a method for preventing it.

Dr. Ponseti was born in the Balearic Islands on June 3, 1914. In 1930 he entered the University of Barcelona where he obtained a degree in biology in 1932 and an M.D. degree in 1936. The Spanish Civil War began just two days after Dr. Ponseti graduated from medical school. He worked as a physician and surgeon, providing fracture and wound care for injured soldiers, from 1936 to 1939. During the war he used the "closed plaster treatment" of open fractures, advocated by one of his teachers at the University of Barcelona. His treatment of open fractures consisted of washing and debriding the wound, excising necrotic tissue, denuding bone fragments and foreign matter, followed by manual reduction of the fracture, packing the wound with sterile gauze and immobilization of the limb in a circumferential plaster dressing. The only inconvenience of this method was the bad smell. Trueta reported that the success rate of this biologic treatment was high and stressed that internal fixation by any means was to be avoided. Undoubtedly, this approach saved many limbs.

After the war Dr. Ponseti immigrated to Mexico where he practiced from 1939 to 1941, and in June of 1941 he arrived in Iowa City to work with Dr. Arthur Steindler.

Dr. Ponseti's strong belief in the importance of understanding tissue biology has been a powerful force in shaping The University of Iowa Orthopaedics Department.

Along with Dr. Ernst Freund, he helped establish the orthopaedic pathology program. He developed one of the first connective tissue biology and biochemistry laboratories, with the goal of discovering the causes of skeletal deformities including scoliosis and dwarfism. His pioneering studies of the effect of aminonitriles on collagen cross-linking laid the foundation for much of current understanding of collagen biochemistry and matrix biology. Jerome Gross, the scientist recognized for opening the field of collagen biochemistry, credited Dr. Ponseti as the man who inspired him to study collagen. Dr. Ponseti's commitment to finding a method of non-operative treatment of clubfoot deformity has helped tens of thousands of patients. The success of his method has been confirmed by multiple independent investigators and has spread throughout the world.

I was fortunate that when I was a medical student, Dr. Ponseti was assigned to be my advisor. He helped me see orthopaedics as a field of great opportunity for progress, based on advances in understanding of the biologic processes responsible for disorders of the musculoskeletal system. He has been my advisor, teacher and inspiration since the first day I met him more than 30 years ago, and not a day passes that I do not think of him and rely on much that he taught me.

Dr. Ponseti, thank you very much for all you have done for me and for orthopaedics.

SPEECH AT 90th BIRTHDAY FOR IGNACIO V. PONSETI, JUNE 8, 2004

Stuart L. Weinstein, M.D.
Ignacio V. Ponseti Chair and Professor of Orthopaedic Surgery

Dr. Ponseti, Helena, Bill, friends and admirers of Dr. Ponseti and distinguished guests:

How lucky we all are to be here today to celebrate this wonderful occasion to honor a man who has profoundly affected all of us in one way or another and changed the lives of thousands of patients, not only here in Iowa City or in the Midwest, but around the world.

Each of us in our own way has a special relationship with Dr. Ponseti, which I'm sure all of us are reflecting on tonight. Each of us, as we go through life, is influenced by many people: our parents, our family, our life experiences, our environment, things that happen to us by chance, what college we attend, where we went to medical school, etc. However, most of us can count the one or two people who have profoundly affected us and helped to shape who and what we are. For me that special person is Dr. Ponseti. It is Dr. Ponseti who had the most profound effect on shaping who and what I am.

As we come together tonight to celebrate the anniversary of Dr. Ponseti's birth, it also gives us another unique opportunity. As we go through our lives we often look back on the things that we didn't take time to say to our friends, colleagues and relatives, to those we love and care about, to tell them how we feel about them or to say thank you. We all have that opportunity here tonight and for me it's a unique opportunity to be able to tell Dr. Ponseti what he has meant to me.

I came to the orthopaedic world by a circuitous route. I was bound and determined to be a gastroenterologist. Thanks to my advisors, Drs. Allen Mark and Phil Schmidt, I had already secured a residency post at the University of California, San Francisco, but I decided to do an elective. That elective changed my life and career goals forever. I came into the Orthopaedic Department at Children's Hospital, a department that was built on the foundations laid by Dr. Arthur Steindler and further developed, matured and enhanced by the leadership of Dr. Carroll Larson. Unfortunately, as with many medical students at that time, I had this stereotypic view of an orthopaedic surgeon as a physician who was strong as an ox and half as smart. However, in walking into Children's Hospital in late 1969, I walked into the land of giants, legends in orthopaedics, Dr. Carroll Larson, Dr. Mike Bonfiglio, Dr. Adrian Flatt, Dr. Don Kettlecamp, Dr. Jerry Laros, a young Dr. Dick Johnston, Dr. Reg Cooper and of course, the already legendary Dr. Ponseti. Dr. Ponseti was revered by medical students for his kindness to them and also by the fact that he taught them something, something useful. He had a weekly session on how to apply plaster casts, a skill that most physicians would use in community practice. We also all knew that Dr. Ponseti bridged the history of the department at that time, as he had trained under Dr. Steindler and now was a senior faculty member under the regime of Dr. Larson. As we all know today, Dr. Ponseti has bridged the entire history of our department from Steindler to Larson to Cooper to Buckwalter.

That rotation convinced me that I wanted to be like these men and be an orthopaedic surgeon. So, after one year in San Francisco, I came back to Iowa City to embark on my orthopaedic career. When I came into the department in 1973, I finally got to meet and study with the man who would become my role model. What impressed me most about Dr. Ponseti was his overwhelming concern for the well-being of patients and his sincere desire to provide them with the best possible care. What I saw in Dr. Ponseti was not only a master surgeon, but a scientist and a teacher, and I knew from the beginning that I wanted to be like him: his caring manner; his quixotic quest for the understanding of the fundamentals of disease affecting children; his making certain as we proposed treatments that we had a full knowledge of the pathoanatomy of the condition, its natural history, and how follow-ups of treatments had affected this natural history with respect to outcomes; and how patients and their families perceived this treatment. I think you all realize that what we are talking about is what is today called "evidence-based practice," taking the best evidence available and merging that with the clinical skills of the physician based on careful observational follow-ups of his practice and incorporating patient desires. This "evidence-based practice" had been practiced by Dr. Ponseti and, in fact, by all the members of the Department of Orthopaedic Surgery for a very, very long time.

I was also impressed with Dr. Ponseti's, for lack of a better term, "anti-surgical mentality." Most surgical

training programs, then and now, seemed to have an attitude of "I'm a surgeon, what surgery can I offer this patient" as opposed to looking critically at the disease process, knowing its natural history, knowing the known outcomes of treatment and which of those treatment options had promise for altering natural history in a positive way. I was so deeply impressed by this thoughtful caring for patients that I just wanted to be like him. At the time I never dreamed that I would have a chance to work with him. I think you all should know too, that at the time I was a resident, if you read the pediatric orthopaedic literature, you would realize that no one in pediatric orthopaedics around the world had contributed more to the basic understanding of pediatric orthopaedic musculoskeletal conditions than Dr. Ponseti.

In about October of 1975, the Chairman of the Department of Orthopaedic Surgery, Dr. Reginald Cooper, called me into his office. As any resident will tell you, that usually meant bad news. But much to my surprise and delight, Dr. Cooper offered me the opportunity to join the faculty to help Dr. Ponseti. What did I think about that idea? I could hardly believe what he was saying to me. What a dream! As a baseball fan, it would be the equivalent of asking me if I want to join the 1927 New York Yankees and play alongside Babe Ruth, Lou Gehrig, Bill Dickey and the rest of this dream team. What a thrill and what an unbelievable opportunity.

When I joined the faculty then in 1976 I began a new relationship with Dr. Ponseti. He became my mentor. He was so generous and unselfish in sharing with me his 30 years of experience in pediatric orthopaedics. I was like a sponge trying to absorb everything I possibly could. And I must tell you, I was the envy of all of my pediatric colleagues around the world, for they knew of his great contributions to this specialty. How they would have loved to have this same opportunity, to be starting their career as an apprentice to the master. What I think is important to stress about being mentored by Dr. Ponseti is that he wasn't looking for a disciple, someone just to sing his praises in the orthopaedic community. He was truly interested in the future of the university, the future of our department and the future of this specialty, and I felt that he wanted me to succeed and that he would do anything necessary to help me in my quest.

After several years of working together, my real education began. The Ponseti's had invited us to come out to Colorado with them for their annual summer hiking adventure. So Lynn and I joined Helena, Ignacio and Bill Ponseti and his children for about five or six summer vacations at the Longs Peak Inn in Estes Park, Colorado. In our long hikes through the Rocky Mountain National Park in Indian Peaks Wilderness, both Helena and Ignacio taught us about literature, art, music and wildflowers, in addition to orthopaedics. This was in a sense, like a private two-or-three-week tutorial. From Dr. Ponseti I learned about growing up in Spain, his experiences in the war, his experiences as a general practitioner in Mexico, his wonderful story about coming to America and the changes he noticed immediately as he crossed the border into Texas in June of 1941. He also taught me about the legends of the ever-growing specialty of orthopaedic surgery that he had seen from the 1930's to the 1970's. As many of you know, the orthopaedic surgeons in Dr. Steindler's generation were really the first true orthopaedic surgeons who had separated from general surgery. Most of the great centers were located in Europe until the turn of the century, when men like Steindler, the forefathers of American orthopaedic surgery, established the great departments in the United States. All of those great leaders came through Iowa City and Dr. Ponseti had a chance to meet many of them firsthand. So, I learned a lot about Dr. Arthur Steindler and the giants who passed through the halls of Children's Hospital. I learned about the other great physicians who had been members of the faculty at University Hospital. I learned about childhood diseases and conditions that I would never see. What a priceless education and privilege I had. These little chats are things that I have treasured throughout my 30 years of working with Dr. Ponseti. As my life has gotten busier and busier with orthopaedic and outside orthopaedic activity responsibilities, these are the things that I miss most.

About 20 years ago, in 1984, Dr. Ponseti retired. I know that's a surprise to all of you! We had a celebration, a two-day academic symposium and a banquet held here at the Athletic Club. The participants in that symposium were the household names in orthopaedics, men who had made great contributions to the specialty and who were honored to come and participate in this retirement celebration for Dr. Ponseti. They included Dr. Henry Mankin, Chairman at Harvard, Dr. Alf Nachemson, a noted spine researcher from Goteborg, Sweden, Dr. Sherm Colemen, a world-renown pediatric orthopaedic surgeon who was particularly interested in problems of the pediatric hip, Dr. Jip James, Chief of Orthopaedics at the University of Edinburgh and a renown specialist in spinal deformity, Ruth-Wynne Davies, a researcher also from Edinburgh who was interested in many of the genetic conditions that Dr. Ponseti had written about, and Anthony Catterall, probably the most famous name in Legg-Calve-Perthes disease. The event was attended by hundreds of former residents, fellows, and community leaders, a true attestation to the love and respect that all of them had for Dr. Ponseti because

he had touched their lives in such meaningful ways. I must admit that I viewed this occasion with mixed emotions. It was a wonderful celebration of the contributions by Dr. Ponseti to our specialty, but it also meant what I thought would be the end of our working relationship. For the two years that he was absent from the hospital, I truly missed him. I missed the opportunities to discuss cases with him, talk about totally unrelated matters in the world or in the department and just the comfort of having him across the hall. However, like Michael Jordan, his retirement was short-lived. He came out of retirement rejuvenated and on a crusade like Don Quixote de la Mancha aided by his squire, Sancho, in this case his devoted wife, Helena. I apologize, Helena, for drawing the comparison between you and Sancho Pancha, but I must admit when Dr. Ponseti came out of retirement and started writing his clubfoot book, you were his inspiration, his trainer, and his coach. You kept him on target, motivated, focused, and provided the necessary support to bring this project to fruition. Obviously you all know that Helena is one of the top Cervantes scholars in the world. What you don't know about Helena is that she is probably the second-most knowledgeable person about clubfoot in the world. Dr. Ponseti, our modern day Don Quixote, prepared himself to take on the windmills, not of La Mancha, but of the pediatric orthopaedic world, which had totally dismissed his previous papers which had clearly shown the benefit of the non-surgical management of clubfoot treatment that he developed in Iowa City. Despite the fact that long-term results were published, pathoanatomy was well understood and the treatment had 20- and now 30-year follow-up documenting its success, these surgeons, looking for the magical "surgical bullet", had totally dismissed this treatment saying that it only works in Iowa. At first, like Don Quixote, Dr. Ponseti lost many battles and actually became discouraged, and was beginning to teach the method to the only group who would listen, the podiatrists. But then several things happened. First, the Pediatric Orthopaedic Society of North America was having a pre-annual meeting symposium on clubfoot. Thinking that Dr. Ponseti had now long since retired from active life, they invited me to give a presentation on clubfoot. I immediately called the chairman of the session and suggested to him that he invite Dr. Ponseti. I told him Dr. Ponseti was extremely active running a busy clubfoot service, would have a lot to offer the audience, and that it would be a treat for them to hear him make the presentation. This presentation, although I'm sure it was shocking to most, provided the first crack in this almost impenetrable clubfoot surgical treatment wall. The second and most important breakthrough came when this man born in the second decade of the twentieth century was united with the most significant breakthrough in the last decade of the century, the Internet.

It was the Internet that helped Dr. Ponseti harness the most important force for change in the medical world, patients. One of my clubfoot patients here in Iowa City, noting that there was no information available on the Internet for parents of children with clubfoot, started a web site. Then one of Dr. Ponseti's patients further developed that information and the floodgates were opened. It was essentially a "field of dreams" once again happening in Iowa, a "build it and they will come" mentality. The revolution had begun and pediatric orthopaedic surgeons from around the United States and the world started to come to Iowa City. It was interesting for me to watch these individuals come to Iowa City and almost beg for forgiveness for thirty years of "sinning." Most of them, as I see them today, have been "born again" after their visits to Iowa City and seeing the wonderful results firsthand in this method of clubfoot treatment.

Now, on a weekly basis pediatric orthopaedic surgeons from around the world come to study at the feet of the master. Dr. Ponseti now spends countless hours with these individuals, tutoring them on a one-on-one basis as to the appropriate application of the method, application of the post-treatment splints and follow-up care. How wonderful it is for me to see the patients coming through the clinic, as Dr. Ponseti does most of his castings in one of the rooms in my clinic. I see these parents come to Iowa City with despair and tremendous anxiety, most of them misinformed about treatment of clubfoot. Many of them feel this is their last chance to have a normal child and to prevent them from becoming crippled. To see the love and gratitude that these parents have after the first cast is removed, and their almost-disbelief at the end of treatment as to how normal their children's feet are—what a sight to behold.

All of us who are physicians profoundly affect two groups of people in our lives; we profoundly affect our families and the patients we treat. While all of us make contributions to medicine in different ways, few of us will make contributions that will last a lifetime. But all of us in this room must take great pride in seeing how this one man, Dr. Ponseti, has helped change one aspect of medicine, the treatment of clubfoot, for thousands of patients now and hundreds of thousands of patients in the future.

The only sad commentary about this story is that, thanks to the work of doctors like Shaique Pirani, the treatment of clubfoot was solved in the developing world, in his case, Uganda, prior to it being solved in the first world, here in the United States. But how com-

forting it must be to Dr. Ponseti to realize that he has helped change the world and prevent millions of children from being crippled by this disorder.

One of the side benefits that I have seen from this recent success is the rejuvenation of Dr. Ponseti. To me, he looks younger and spryer now than I think he did twenty years ago when he retired. In fact, recently a reporter from the Des Moines Register called me to do an interview about Dr. Ponseti and the clubfoot treatment. I told him that with each passing day, Dr. Ponseti is getting younger and younger, and in fact it wouldn't surprise me if he outlives me and is someday named the Weinstein Professor of Orthopaedic Surgery.

Finally, on a personal note, of all the wonderful things that have happened to me in my professional life, none has been more meaningful to me than being named the Ignacio V. Ponseti Chair of Orthopaedic Surgery. This wonderful honor, which was bestowed on me 17 years ago, was a tremendous personal honor, but with that honor came a very heavy responsibility. When fundraising for this chair from alumni and friends of the department was begun in 1984, the purpose of the chair was to be able to honor Dr. Ponseti in perpetuity through the actions and deeds of the chair holder. To me, this has been a sacred responsibility.

Dr. Ponseti, I want you to know that I mention your name everywhere I go and in every scientific lecture I present. I thank you publicly for all you have meant to my personal and professional life. Also, as I take care of pediatric orthopaedic patients here at University Hospital, I try to make certain that the patients and families who seek our care get the best possible and most thoughtful care available anywhere in the world. The honor of having a chair in your honor, to me means that you will always be by my side, in my thoughts, my deeds and in my life. As I mentioned earlier in this presentation, life often passes by without our having the opportunity to tell the people we care about how we feel about them. Words really can't express what you have meant to me and to my life. You have been, you are and will always be my hero. I love you very much.

DR. PONSETI'S 90TH BIRTHDAY SPEECH, JUNE 8, 2004

Ignacio V. Ponseti, M.D., Iowa City, Iowa

Thank you, Jody Buckwalter, Stu Weinstein, and the staff for celebrating my birthday among friends and colleagues. My special thanks to Paul Etre for organizing the event and to Naomi Davis and Gavin DeKiwit from England for coming from far away to give distinction to this occasion.

Throughout my life, I have had good luck. When I was a student in the 1930s in the medical school of The University of Barcelona, the school was one of the best in Europe, owing to the fact that following the fall of the monarchy in 1931, the University became autonomous—independent from the central government of Madrid. The faculty was doubled, a large new hospital was added, and a number of promising graduates were sent to Vienna, Berlin, Boston and Chicago to bring back the latest scientific advances in medicine.

Again, I was lucky to finish medical school one day before the Spanish Civil War started in 1936, and to be assigned to work for two years with Jimeno Vidal back from Vienna, where he worked on trauma with Bohler. Then, for one year I worked with Adolfo Ley, back from Boston and Chicago, where he studied neurosurgery with Cushing, Bucy, and Baily.

After my experience during the three years of the Spanish Civil War—the exodus to Beziers in southern France—I spent one-year-and-a-half in the village of Juchitepec, south of Mexico City, where I had to deal with an epidemic of typhoid fever. For me, to come to Iowa City was a stroke of good fortune, for finally I found myself at home.

My choice of coming to the University of Iowa was guided by Dr. Juan Farill, professor of orthopaedic surgery at The University of Mexico, who had trained in the early 1930s with Dr. Steindler. I arrived in Iowa City 63 years ago, on my 27th birthday, a wonderful birthday present.

Dr. Steindler's Orthopaedic Department was considered one of the best in the United States. Dr. Steindler was a refined and cultured man. My first assignment, before the start of residency in July, was to translate into Spanish the 20 lectures he was to deliver at The University of Mexico, and to teach him how to pronounce them correctly.

The State of Iowa had a very progressive program of medical care—the University Hospitals provided free treatment for indigent patients. Twenty years before I came, the Orthopaedic Department occupied the east side of the newly built Children's Hospital, with 100 beds. Children's Hospital had laboratories for biochemical research, bone pathology, clinical research, physical therapy, and a brace shop. All the braces for Iowans were made in this shop. We, the residents, lived on the second floor.

The greatest legacy of Dr. Steindler was to establish the basic principles of a model orthopaedic department in a rising university with teaching, research and patient care as full-time occupations. Health care had to be based on sound scientific and clinical research. Extensive files with records and X-rays of *all* patients, going back to 1920, were available through a full-time secretary for research. I spent many a night studying the natural history and results of many orthopaedic disorders treated in Iowa City. Long-term results of club foot treatment I found to be very bad. Those of congenital dislocation of the hip, and of Legg-Perthes, were better.

When the second world war started 6 months after my arrival, many faculty and residents, as well as young doctors in the state, had to enlist in the military. In Orthopaedics, we were left with one staff and about 4 residents to take care of an increased number of patients. We worked 12 to 14 hours each day for twenty dollars a month for the first year, with room and board. Then, and for many years after, salary was not a symbol of one's status. Health care was not for business. At that time, polio epidemics filled our infectious disease area, and in fall we sometimes had over 600 patients, 40 or so needing iron lungs to breathe. How could the afflicted families pay for this? They didn't have to.

At the end of the war, veterans returned to complete their orthopaedic training. Our time for research increased. With Barry Friedman and the help of pediatricians, neurologists and endocrinologists, we did extensive clinical and laboratory studies of close to 400 patients with idiopathic scoliosis. These studies revealed that the prognosis of the spinal deformity varied according to age at onset and to the site of the curves in otherwise normal patients. This study has been continued by Stu Weinstein and Lori Dolan, bringing us much useful information.

In searching for an animal model for scoliosis, I studied this deformity reproduced in rats and rabbits fed a diet containing sweet pea seed. Early in my experiments, I noticed that the young rats fed the sweet-pea meal

died from dissecting aneurysms of the aorta. The skeletal lesions observed in very young rats occurred in the growth plates, causing slipped epiphyses. Kyphoscoliosis was seen to develop as a result of slippage in the weakened vertebral growth plate and detached intervertebral ligaments.

The sweet pea caused the collagen in rats to be weak and soluble in salt saline. My findings opened a new field of study by biochemists. They discovered the structure of collagen to be formed by a triple helical protein with three polypeptide chains wound around each other. The aminonitrile in the sweet pea disrupted the cross-linking, weakening the collagen. This led to the understanding of the molecular defects in Marfan's, Ehlers-Danlos syndrome, and other genetic deficiencies. Much more work on collagen still lies ahead.

My research was possible because of the unique interdisciplinary setup in this university in the 50s and 60s. I worked with Stan Wazoneck in organic chemistry to identify the poison in the sweet pea, with Witschy in zoology to study the lesion in tadpoles. I worked with Warren Nelson and Nick Halmy in anatomy, with Muir in botany, and with Bob Shepard in physiology as he worked on his Ph.D. under my direction. Later on, the electron microscopy laboratory, established by Reg Cooper, was a basic addition for research. Dr. Bonfiglio was in charge of bone pathology. This university was a working paradise.

The ideals of the founders of our medical school have been maintained by men of vision, thanks to presidents, administrators, deans, chairmen, and colleagues: Howard Bowen, Sandy Boyd, John Colloton, Jack Eckstein, Bob Hardin, Paul Seebom, Jim Clifton, Carol Larson, Reginald Cooper, Jody Buckwalter, Stu Weinstein, and many others.

Personally, I could not have worked without the commitment of residents, nurses and secretaries: Miss Gould, Gwen Rarig, Stella Horst and recently Maria Paulsen, Susan Crimmins, Joyce Roller, Nancy Love, Gloria Yorek and others.

It is this university's setup that has made it possible for our staff to lead the world in orthopaedic surgery. Drs. Steindler, Weinstein and Buckwalter have been presidents of the American Orthopaedic Association. Drs. Larson, Cooper, and now Weinstein have been presidents of the American Academy of Orthopaedic Surgeons, and six members of our department have been presidents of the Orthopaedic Research Society, which I co-founded in 1954 (Ponseti, Bonfiglio, Cooper, Brand, Buckwalter and Brown). A number of us have been advisers to the National Institutes of Health and members of the editorial boards of leading orthopaedic journals. A number of seminal articles have come out of our department.

When I turned 70, I had to comply with the mandatory retirement age. I was named professor emeritus. For two years I found enjoyment in studying Renaissance and modern art in the Art Department. Then, I went back to my laboratory to work on elastin in consultation with Michael Solursh.

I missed my patients, however. Stu Weinstein suggested I help with club foot patients. A 30-year follow-up by Doug Cooper and Fred Dietz of patients I treated with my technique in the 50s and 60s revealed good functional results, whereas club foot surgery throughout the orthopaedic world continued to bring disappointments. My papers on this subject were ignored.

My wife, Helen, suggested that I write a book on my method of treating club feet. She offered to type it for me on the computer. No publisher in the U.S. was interested. Stu Weinstein and Jody Buckwalter, who had contacts since his professorship in Oxford, were instrumental in getting my book published by Oxford University Press in 1996.

John Herzenberg from Baltimore was the first to read my book and promote my method. However, only a few orthopaedic surgeons were willing to give up surgery. Charles Saltzman advised me to summarize my work in our Virtual Hospital on the Internet.

A developer in Las Vegas, Martin Egbert, whose sixth child was born with club feet, was horrified, reading for three months the variety of operations performed on babies with this deformity. After calling Herzenberg and others to inquire about my technique, he called me on the phone several times. Finally, I just told him to stop shopping around and let me fix his baby.

After three weeks in Iowa City, his son's feet were corrected. On the way home with his wife, Allyson, they determined to start a web site to inform parents that surgery is unnecessary to correct club feet. Today, hundreds of web sites by parents here and abroad have been instrumental in turning around club foot treatment. John Mitchell, a master craftsman, and I, constructed a club foot model to show doctors and physician assistants how to move the joints to correct the deformity. Today, John Buchanan, a brilliant adviser on the establishment of new enterprises, is making it possible for John Mitchell to expand the production of his new foot appliances to maintain the club foot correction.

It has been touching to me to witness how parents know from the first manipulation and removal of the first cast, that their baby's feet are on the way to normality. This is in shocking contrast to surgeons who cut ligaments, lengthen tendons, open joints and pin

bones to align the foot, unaware of the irreparable damage they do.

Today, after half a century, I feel vindicated as Shafique Pirani and Norgrove Penny, backed by the Rotarians, are introducing my technique throughout Africa, India, and China. Naomi Davis and Gavin DeKiwit are disseminating the treatment throughout Great Britain and beyond, as have Ernesto Ippolito in Italy, Ana Ey in Spain, Berard in France, Sinclair in Germany, Romanus in Scandanavia, and other doctors in Israel, Turkey, Portugal, Brazil, Uruguay, Argentina, Chile and Japan. Translations of my procedure are being made in seven languages.

I want to express my most profound gratitude to the outstanding leaders, professionals, and friends of this wonderful university for their support and contributions to my work throughout the years. It could not have been done anywhere else. Thank you.

DEVELOPMENT OF IMAGELESS COMPUTER NAVIGATION FOR ACETABULAR COMPONENT POSITION IN TOTAL HIP REPLACEMENT

Lawrence D. Dorr, M.D., Yuji Hishiki, R.N., Zhinian Wan, M.D., Deanne Newton, PA-C, Andrew Yun, M.D.

ABSTRACT

The purpose of this study was to develop an imageless (without preoperative computerized tomography (CT) scans or intraoperative fluoroscopy) computer navigation system for total hip replacement. One-hundred and ninety-five hips were operated with imageless computer navigation. Eighty-five hips were operated prior to obtaining precise results, with precision refined in the subsequent 110 hips. Computer accuracy for cup-adjusted anteversion was achieved in 100% of the final 40 hips, and for adjusted inclination in 96.6%. The factors necessary for accurate measurements are mechanical stability of the tools with the light-emitting diodes, adjusted computer anteversion and inclination for the tilt of the pelvis (tilt in the AP plane), and check-and-balance techniques for confirmation of measurements of tilt, anteversion and inclination.

INTRODUCTION

In 1998, DiGioia et al.[2] won the Aufranc Award of the Hip Society for his pioneering work using computer navigation for cup placement. He used preoperative computed tomography scans to define the desired position of 40 degrees abduction and 20 degrees anteversion for an individual patient, and then use this information intraoperatively to achieve this goal. After DiGioia presented his findings, there was an enthusiasm born for computer navigation methods. DiGioia continued to report his results, which showed precision of cup placement with his image-driven navigation even with small incisions. Jolles et al.[4] had the same precision with plastic pelvis models which had image-driven navigation and the average error of 1.5 degrees anteversion and 2.5 degrees abduction. Nogler et al.[9] used an imageless system in cadavers and found more consistent placement of the cup than with mechanical guides.

Correspondence:
Lawrence D. Dorr, M.D.
The Arthritis Institute
501 E. Hardy Street, 3rd Floor
Inglewood, CA 90301
Telephone: (310) 695-4800
Fax: (310) 695-4802
Email: patriciajpaul@yahoo.com

The necessity for a preoperative CT scan, or even intraoperative fluoroscopy, has been a deterrent to the use of navigation for many surgeons. This technique seems cumbersome and impractical to most surgeons in their busy practice. For this reason, interest in an imageless navigation system for total hip replacement became prevalent among those interested in navigation. This study was initiated with the hypothesis that an imageless computer navigation system could be developed which would be more accurate than manual methods and would be easy and efficient to use with little risk of complication. This system would then be practical for the practicing orthopedic surgeon and would provide the surgeon with "real time" knowledge of the component position. This knowledge would reduce the risk of impingement of the total hip replacement which was being performed.

MATERIALS AND METHODS

In February 2003, with approval of the Institutional Review Board and with informed consent of the patients, a clinical investigation was begun of an imageless computer navigation system. This imageless computer-assisted navigation was approved by the Federal Drug Administration (FDA) in November of 2003. The anticipated complaints were mostly associated with the use of percutaneous pins for placement of the base supports for the antennae which held the light emitting diodes. The operation was performed identical to a surgery without computer assisted navigation. The intraoperative registration of the acetabulum was non-invasive. Component placement could be performed by the surgeon, as needed, if there was mechanical or computer malfunction.

All operations were performed by a single surgeon (LDD). None were performed by residents or fellows. The operations were performed with a posterior mini-incision measuring 8-10 cm as previously described[1]. Implants used were the anatomic porous replacement stem (APR, Zimmer, Warsaw, IN), the Converge cup (Zimmer, Warsaw, IN) with either a Metasul (Zimmer, Warsaw, IN) or Durasul liner (Zimmer, Warsaw, IN). In these patients, the largest femoral head which could be used was used. The only head sizes available for Metasul was 28 mm, so its use was limited to 49-51 mm sockets. For Durasul, 32 mm heads were used for 51-

Figure 1. The AP plane of the pelvis is being registered with the pointer guide on the anterior iliac spine. The pelvic base with the light-emitting diodes on the tracker and the pointer are seen by the optical camera at the head of the table which is attached to the hardware for the navigation system. The computer screen is on a separate piece of equipment.

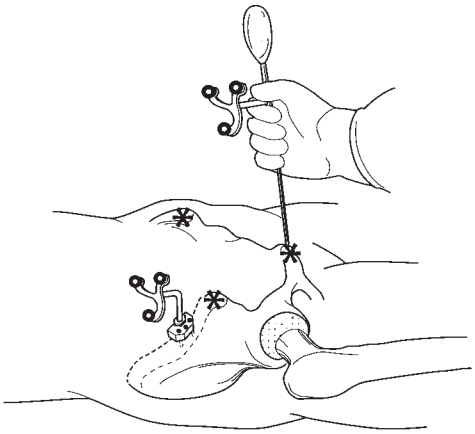

Figure 2. The AP plane of the pelvis is registered with the patient in the supine position by touching the digitizing probe to the bone of the two ASIS and pubis.

55 mm sockets, 38 mm for 57-61 sockets, and above 61 mm a 44 mm head was used. No extended liners were used.

Technical Aspects of Imageless Computer Navigation

The tools to be used during surgery for registration of anatomy and components must be calibrated prior to use. The calibration allows the computer software to identify the tools during use. Calibration is accomplished by the scrub technician and the circulating nurse while the patient is being prepared for anesthesia, and requires approximately 5 minutes.

Navigation data is recorded using a Polaris Optical Localization System (Polaris, Northern Digital Instruments) using light emitting diodes (LED) (Figure 1). Surgical instruments and patient references are equipped with reflective spheres allowing tracking of their location during the surgery. The navigation software is image-free. The coordinate system and other reference points of the patient are digitized using a dedicated instrument, the registration pointer. All landmarks are digitized in relation to a patient reference that is rigidly fixed to the relevant bone of the patient.

The registration of the anteroposterior (AP) plane of the pelvis (anatomic coordinate system) is done after the patient is anesthetized (Figure 2). This can be done while the anesthesiologist is completing the preparation, such as inserting arterial lines. The skin over the pelvis is sterilized with Betadine (Purdue Pharma L.P., Stamford, CT). A metal base plate is attached to the iliac crest with three percutaneous threaded 1/8-inch pins (Zimmer, Warsaw, IN). This metal base holds the pelvis antenna with the light emitting diodes (LED) for registration of pelvic information. The pelvic reference used for navigation is a unique modular design allowing removal of the antenna from its base and placing it back later in the exact same location. The registration pointer guide is touched to each anterior superior iliac spine (ASIS) and the pubis. The pointer touching the ASIS does not need to puncture through skin to the bone, but this should be done if there is fat over the ASIS obscuring the prominent bone. The pointer should always puncture through skin to the pubic bone because of the thickness of fat over the pubis. The cephalad border of the symphysis pubis is palpated and the pointer is directed to the pubic bone just below this border so that it contacts the pubic bone near the left or right pubic tubercle. The pubic tubercle is not palpable in many patients because of the thickness of fat. This process of registration of the AP plane requires no more than ten minutes to accomplish.

The patient is turned to the lateral decubitus position and secured with pelvis and chest supports to minimize pelvis motion during the operation. The long axis of the body in the lateral position is registered by touching the pointer to the posterior pelvic and chest supports (Figure 3). The computer software mathematically computes the tilt of the pelvis (tilt of AP plane) in the lateral position. This process takes one minute of time.

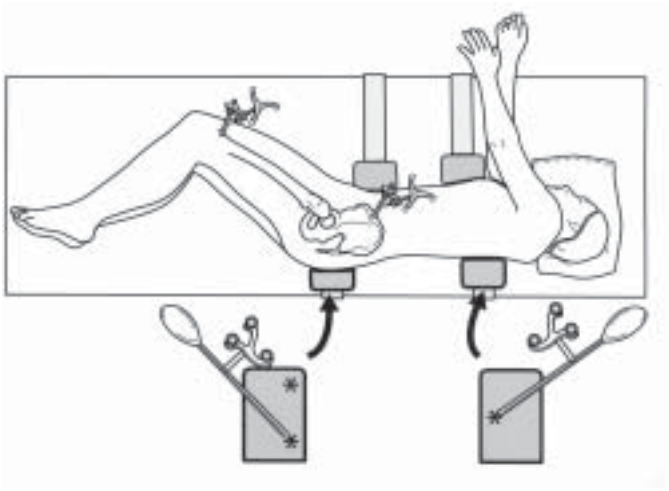

Figure 3. The patient is in the lateral position for the operation and supported by two pelvic and two chest supports. The two posterior supports are those touched by the registration pointer to register the longitudinal axis of the body. The registration of the long axis of the body is done by creating a triangle on the two posts. This figure illustrates the triangle with two points on the pelvic post. A second tilt measurement is done with the triangle reversed with two points on the chest post. The pelvic and femoral antennae with light-emitting diodes are shown.

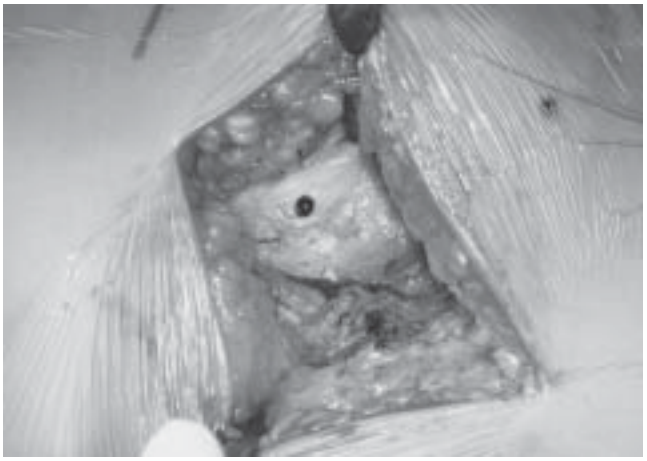

Figure 4a. The point of registration on the greater trochanter is marked with methylene blue so that it can be easily found at the completion of the hip replacement.

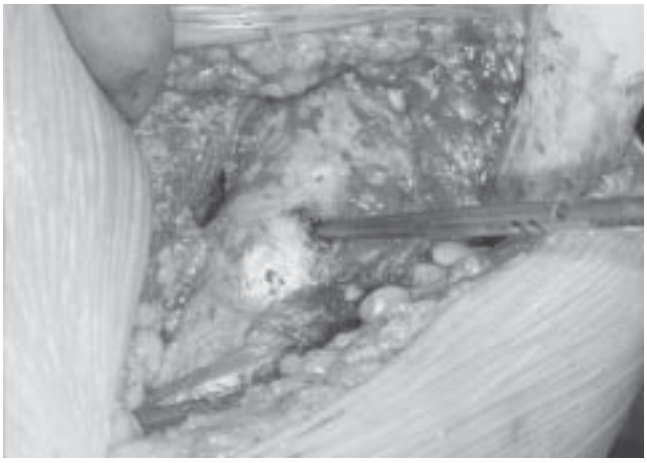

Figure 4b. The change in leg length and offset are measured by touching the same point on the greater trochanter with the registration pointer.

If just the acetabulum is to be navigated (no femoral navigation), the leg length and offset of the hip can still be determined. After incision to the level of the greater trochanter and prior to dislocation, the greater trochanter is touched with the pointer to register the preoperative position. A divot in the trochanter bone is made so the initial site can be located after the reconstruction. When the replacement is completed and the hip relocated, the change in offset and leg length are recorded by touching the same site on the greater trochanter (Figure 4). The software can then compare the preoperative and post-implantation positions.

There are three registrations of the acetabulum done intraoperatively (Figure 5). After exposure of the acetabulum, and removal of the pulvinar to expose the cortical bone of the cotyloid notch that represents the medial wall, the pointer is used to touch the acetabular bone. The first registration locates the center of rotation (CR) of the hip and is performed with 16 touches of the inner wall, avoiding the cotyloid notch. The second registration is named 'the Mosaic.' By touching the periphery of the bone, the medial wall and cotyloid notch, the outline of the acetabular anatomy is obtained. The third set of points is named the 'fit plane' and the data is obtained by six points on the periphery of the acetabulum that defines the inclination and anteversion of the natural bone. Osteophytes and the cotyloid notch need to be avoided with this registration.

Three-dimensional change of the center of rotation during acetabular preparation and implantation is given by numerical changes in the superior-inferior, mediolateral and anterior-posterior planes during reaming (Figure 6). The medialization of the center of rotation can be anticipated from preoperative planning. When the cup is implanted, the inclination and anteversion, adjusted for the tilt of the AP pelvis, are visualized on the computer screen and the surgeon can adjust the cup position to the numerical position required (Figure 7).

The cup position is known because of the LED on the cup holder. If the antenna attachment becomes loose, the values can be wrong. For this reason, we always confirm the reading from the cup holder by performing a fit-plane measurement of the metal edge of

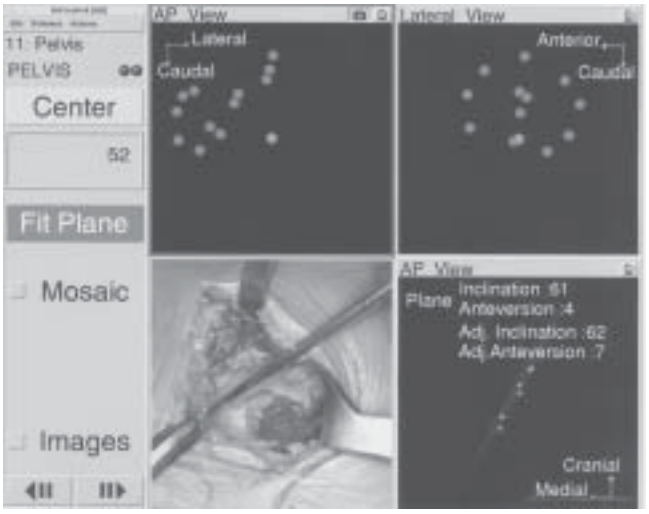

Figure 5. The acetabular bone is touched by the pointer guide as seen in the lower left-hand quadrant. The computer screen shows the outline of the AP and ML dimensions of the acetabulum with the medial bone marked by yellow dots. The lighter central dot measures the center of rotation of the hip. This is seen in the upper two quadrants. The lower right quadrant shows the inclination and anteversion of the native acetabulum as determined by the fit plane.

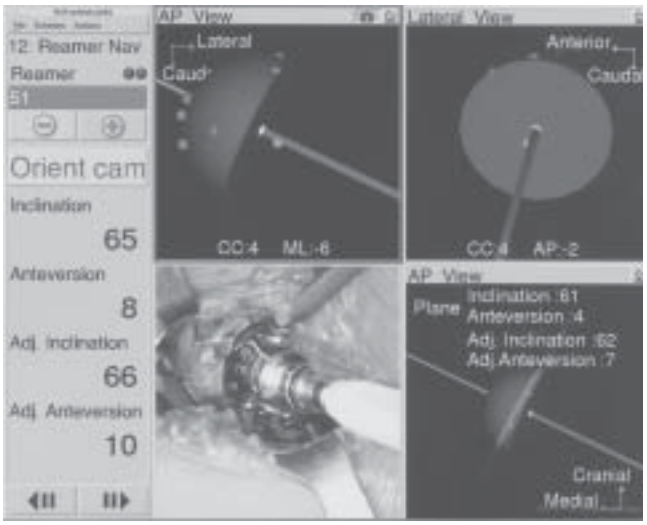

Figure 6. The reamer in the acetabulum is shown in the lower left-hand quadrant. The position of the reamer relative to the acetabular peripheral bone and medial wall is shown in the upper two quadrants. The CC is center of rotation (positive number means superior displacement); ML is mediolateral displacement from the center of rotation by the reaming (negative number means medial displacement); AP is the anterior-posterior position of the reamer (negative number means posterior displacement). The numbers on the left give the angular position of the reamer in the acetabulum both by inclination and anteversion, which is also adjusted.

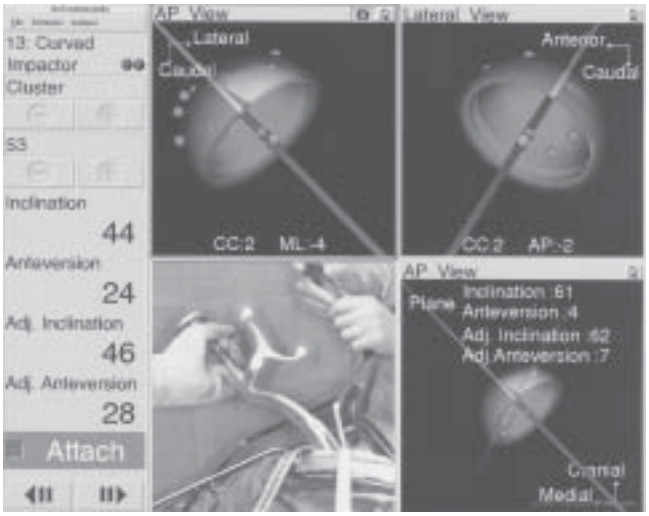

Figure 7. The cup implantation is shown in the lower left quadrant. The upper quadrant shows the position of the cup relative to the acetabular bone including medial wall. The CC, ML and AP numbers provide the center of rotation superior displacement (CC), medialization (ML) and AP displacement (AP). The numbers on the left give the numerical inclination and anteversion, and AdjAV and AdjI. The lower right quadrant gives the native acetabulum values, and the gray lines show what portion of the cup would be uncovered. The amount of coverage is only illustrative.

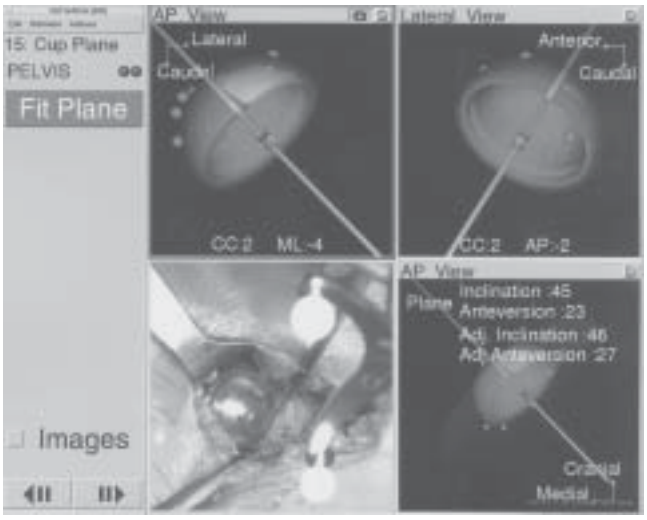

Figure 8. The measurement of the fit plane of the acetabular cup is done by touching the metal edge of the cup at six points with the registration pointer.

the cup after the cup holder is removed (Figure 8). Six points are touched on the circumference of the metal edge to confirm the inclination and anteversion of the cup. Furthermore, if a screw is used, it is possible to change the final position. A fit plane should be done to record any change in position that occurred. The fit plane is also done after the liner is impacted into place to determine any change that occurs with that impaction.

Data Collection

One-hundred and ninety-five total hip replacements were performed with computer navigation between February 2003 and October 2004. Eighty-five hips were operated on in 79 patients in 2003 (group 1), and 110 hips in 100 patients in 2004 (which were divided into 70 patients operated on between January and July 2004, group 2; and 40 patients operated on between July and October 2004, group 3). The demographics of the patients in these groups were not different.

The first 85 hips from 2003 (group 1) included 53 men and 38 women. The 110 hips (groups 2 and 3) in 2004 included 54 men and 56 women. The age averaged 63 $\pm$ 11 years (37-89) versus 63 $\pm$ 13 years (32-90); the body mass index (BMI) was 28 $\pm$ 5 (20-44) versus 26 $\pm$ 5 (17-45). The diagnosis in 85 hips (group 1) versus 110 hips (group 2 and 3) was osteoarthritis in 76 versus 91, post-trauma in three versus one, osteonecrosis in three versus 11, and congenital disease of the hip in three versus seven.

Accuracy of a measurement is comparison of the measured value to the true value (i.e., the computer anteversion vs. the true anteversion of the cup). Precision is the agreement between two measured values to demonstrate reproducibility of a test. If the values tested are the same as the true value, then both values are also accurate. To determine the accuracy of the radiographic technique, and the computer navigation technique, postoperative CT scans were obtained which were considered the true value of cup anteversion.

The radiographic technique used for measurement of anteversion was published in 1996.[12] It requires an AP pelvis radiograph centered over the symphysis pubis, and an AP hip radiograph centered over the hip. Centering the AP hip radiograph was difficult with the immediate postoperative radiograph, so it was only used to confirm anteversion versus retroversion. Data from comparison of 100 radiographs showed an average difference of 3.6 $\pm$ 2.0 degrees, so that the radiographic anteversion used for comparison to the computer anteversion was that of the AP pelvis radiograph plus four degrees.

Postoperative CT scans were obtained from 15 patients in group 2 to validate the radiographic and computer numbers. The CT scan images were segmented using Navitrack CT-based hip software (Orthosoft, Montreal, Canada) to reconstruct the 3-D model of the pelvic bone with the implanted cup. The planning module of the Navitrack CT-based hip software is used to evaluate the implanted cup orientation based on the coordinate system used during the surgery. The coordinate system is defined by aligning the frontal plane to both the ASIS and the pubic tubercles, and the lateral axis through the ASIS. Generic cup models can then be superimposed to the postoperative reconstruction of the implanted cup. The resulting inclination and anteversion angles can then be compared to the navigation data.

Precision of the measurements were given a margin of error of five degrees so that the radiographic and computer values had to be $\pm$ 5 degrees of each other or the computer number was considered an outlier. Five degrees was the margin of error because: 1) The difference between AP pelvis and AP hip radiographs was four degrees; 2) The range of difference between postoperative CT scans of cup position and postoperative radiographs in 15 patients was 0-5 degrees (average 1.8 degrees); 3) The average range between the 15 postoperative CT scans and computer navigation cup position was 0-6 degrees (mean 2.7 degrees); and 4) The standard deviation in postoperative radiographs for inclination and anteversion by this same radiographic technique for 105 hips performed without navigation was 38.4 $\pm$ 6.3 degrees for inclination and 20.1 $\pm$ 5.7 degrees for anteversion. The authors felt the computer must have better accuracy than their data from manual implantation of the identical cup.[1]

Development of Precision of Anteversion and Inclination

Four lessons were learned during the nearly one-year time period during which the first 85 hips were operated. The first 17 hips in this group had 13 (76%) outliers. In these hips, the pins holding the base for the pelvic antenna would loosen with anterior retraction of the femur and/or impaction of the cup. The base was moved to the thickest bone of the iliac crest, about 5 cm posterior to the ASIS, and secured to the bone with horizontal 1/8-inch threaded pins. The pin site was located by marking it with methylene blue through the pin holes on the base plate, a stab wound with a #15 scalpel blade was done, and the pins inserted.

The second lesson was that the tilt of the pelvis must be calculated into the anteversion and this was measured in the next 40 hips (hips number 18-57) with the patient supine on the operating table. Tilt of the pelvis (which reflects tilt of the AP plane) means flexion (anterior tilt) or extension (posterior tilt) to the longitudinal axis of the body (Figures 9A and 9B). The actual anteversion decreases with flexion (anterior tilt) and increases for extension (posterior tilt). The effect on anteversion is not 1:1 for the degree of tilt, so the computer software calculates a true anteversion and this is expressed as the adjusted anteversion (AdjAV). After measurement of tilt in the supine position, the patient was turned to the lateral position for a posterior ap-

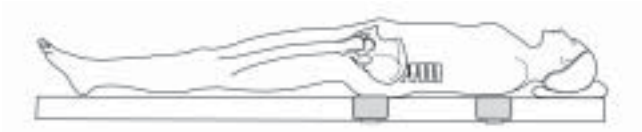

Figure 9a. Anterior tilt of the pelvis means that the pelvis is flexed (forward facing) from the longitudinal axis of the patient.

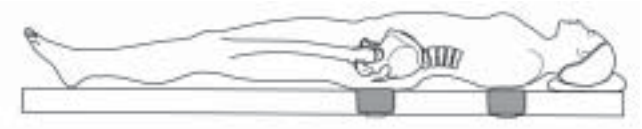

Figure 9b. Posterior tilt of the pelvis means that the pelvis is extended (facing backward from the longitudinal axis of the body).

proach and precision improved with this AdjAV to 50% (20 of 40) outliers. However, in 16 of 40 patients (40%) the tilt value did not make sense, (i.e., anterior tilt resulted in an increase of the anteversion) so the tilt measurement was still not accurate.

The third lesson was that the registration of the AP plane had to be done by contact with the registration pointer to bone. The fat layer over the pubis is always thick so it is necessary to puncture the skin over the pubis and contact the pubic bone with the tip of the registration pointer. If the bone of the ASIS was covered by more than just thin skin, then the probe was punctured through skin to contact this bone also. Precision improved to 30% outliers for AdjAV in the next 13 hips (numbers 58-70), but the tilt was still not accurate.

The fourth lesson was that the precision would not be within five degrees unless the AP plane was registered in the lateral position, so that the correct pelvic tilt in the position of operation was known. However, in the next 15 hips (numbers 71-85) it proved too technically difficult to access the downside ASIS and the pubic bone for accurate registration of the AP plane in the lateral position. The engineers at Orthosoft discovered that the AP plane could be registered supine, the patient turned to the lateral position, and the longitudinal access of the patient registered from the posterior supports (Figure 4).

One-hundred and ten hips (numbers 86-195) had the AP plane of the pelvis registered supine and the tilt of the pelvis registered with the patient positioned laterally. In 51 of these patients, the tilt of the pelvis was registered in both the supine and lateral positions to confirm that there was a change in the tilt. The pelvis was flexed (anterior tilt) in 40 of 51 hips (78%) while supine, and in these 40 hips the pelvis extended when changed to the lateral position. In 30 hips (60%), this extension was more than five degrees and the pelvis was absolutely extended (posterior tilt beyond 0) in 26 of 51 (50%) when laterally positioned.

TABLE 1
Outliers

Cup Position	Group 1 85 hips	Group 2 70 hips	Group 3 40 hips
Inc.	48	16	1*
AV	35	7	1

Inc = inclination

AV = anteversion with AdjAV being for supine tilt for group 1, and in the lateral position for groups 2 and 3.

* In group 3 this data is for 29 hips with AdjI

In the first 70 hips operated with this registration technique, seven (10%) were outliers for computer anteversion and 16 (23%) for inclination (Table 1). Four additional causes of outliers were determined to be: 1) The inclination had to be adjusted for tilt of the pelvis (AdjI); 2) The tilt measurement itself had to be correct 100% of the time; 3) The security of the LED on the cup holder, or the attachment of the cup holder to the cup, could loosen which would distort the measurements; and 4) A change in cup position could occur by placement of a screw, testing the stability of the cup, or hitting the liner into its locked position (all of these being done after the cup holder was removed).

In the final 40 hips (numbers 71-110), the tilt was tested in 23 patients by measuring it on both the posterior pelvic and chest supports (Figure 3). The final position of the cup was measured by the fit-plane measurement (Figure 8) as a confirmatory test for the cup holder after insertion of a screw or insertion of the liner.

Data Evaluation

Data analysis was performed on the 110 hips of groups 2 and 3. The mean inclination and anteversion for the computer and the radiographs was computed for all 110 hips. The first 70 hips (group 2) did not have the fit-plane measurements performed and did not have AdjI, so the effect of these two techniques was measured in the last 40 hips (group 3). The means for AdjAV and AdjI, and the individual match of computer AdjAV and AdjI to radiographic anteversion and inclination were done for each hip.

The fit plane was measured in all 40 hips of group 3 by touching the edge of the cup after the cup holder was removed and nothing else had been done to the cup. This value was used just to confirm the numbers obtained with the cup holder. The fit plane was also done

in all 40 hips after the acetabular liner was malletted into place by touching six points on the periphery of the liner. In 18 hips, a screw was inserted through the cup and a fit plane was performed after the screw insertion to measure any change in position caused by the placement of the screw.

Statistics

SPSS Statistical Software (SPSS Inc., Chicago, IL) was used to analyze the data. Statistical analysis consisted of a descriptive analysis (mean, standard deviation, and range) for inclination, AdjI, anteversion, AdjAV, and fit plane, as well as a paired t-test to evaluate the difference between computer navigation and radiographs. All of these data had normal distribution.

RESULTS

Clinical results have shown no complications with the use of the computer system. There have been no complications with the use of pins in the pelvis and femur. One patient had complaints of a keloid-like scar of the pin sites of the femur. There were no dislocations in the 110 hips and no reoperations.

CT scans in 15 hips showed radiographic and CT anteversion differed by a mean 1.8 degrees (range 0-5 degrees); radiographic and CT inclination differed by a mean 2.0 degrees (range 0-5 degrees). These results validated the accuracy of the radiographic technique. Computer AdjAV had a mean difference from CT anteversion of 2.7 degrees (range 0-6 degrees) and computer versus CT inclination was 2.8 degrees (range 0-10 degrees). Computer variance was one degree greater than radiographic, because AdjI and fit plane were not done in these hips.

The overall group of 110 hips had a mean computer inclination of 39.1 ± 4.4 degrees (range 28-53 degrees), and radiographic inclination of 41.1 ± 5.0 degrees (range 31-51 degrees). The AdjAV was 23.6 degrees ± 3.8 degrees (range 15-35 degrees) and radiographic anteversion was 23.4 ± 4.1 degrees (12-32 degrees). To determine outliers, each computer measurement was matched to its radiographic measurement and was considered an outlier when these measurements were not within five degrees of each other.

Inclination

Computer inclination of the cup in 70 hips (group 2) was a mean 38.0 ± 3.8 degrees (range 28-46 degrees); radiographic inclination was 40.0 ± 5.0 degrees (range 31-51 degrees) ($p = 0.006$). Sixteen of 70 hips (23%) were outliers (range 6-12 degrees).

TABLE 2
Fit Planes

Fit plane	AdjI	AdjAV
(cup holder)*	41.4 ± 3.4 degrees	23.6 ± 3.8
Cup	41.3 ± 3.5 degrees	25.8 ± 4.5
After 1 screw	42.5 ± 3.5	24.2 ± 3.2
After liner	42.7 ± 4.0	25.1 ± 3.5

* The values for cup holder are those obtained with the cup holder and are listed to be able to compare to the values obtained with the fit planes

Computer inclination of the cup in 40 hips of group 3 was a mean 41.0 ± 4.8 degrees (range 33-53 degrees); radiographic inclination was 43.1 ± 4.4 degrees (range 31-51 degrees). Three of 40 hips (7.5%) were outliers. Two of the three did not have AdjI. AdjI in 29 hips was a mean 41.6 ± 4.8 degrees (range 32-48 degrees) versus radiographic AdjI of 43.1 degrees ± 4.2 degrees (range 31-49 degrees) with one outlier (computer 32 degrees, radiograph 43 degrees).

Improvement of outliers by use of AdjI and fit-plane computer inclination was from 23% in group 2, to 3.4% in group 3. The singular inclination outlier with AdjI was considered an incorrect tilt measurement, so computer accuracy was 97%.

Anteversion (AdjAV)

Computer AdjAV of 70 hips (group 2) was a mean 21.5 degrees ± 5.7 degrees (range 15-35 degrees); and radiographic anteversion was 22.4 ± 4.4 degrees (range 12-31 degrees). Seven of 70 hips (10%) were outliers between 6-10 degrees. Computer AdjAV of 40 hips (group 3) was a mean 26.6 ± 3.7 degrees (range 19-30 degrees); and radiographic anteversion of these hips was 25.0 ± 3.0 degrees (range 16-31 degrees). One of 40 (2.5%) hips was an outlier (computer 19 degrees, radiograph 25 degrees). The use of the fit plane as a confirmation of the acetabular AdjAV reduced outliers from 10% in group 2 to 2.5% in group 3. Computer accuracy was considered 100% because the single outlier (computer 19 degrees, radiograph 25 degrees) was deemed a radiographic variation as all four computer values were 19 degrees.

Fit Plane

Fit-plane measurements are listed by mean of AdjAV and AdjI for any maneuver that could change the position of the cup (Table 2). Using one of the fit-plane measurements of inclination allowed the computer/radiographic precision to be within five degrees in three

hips in which the cup holder measurements did not have precision. With AdjAV, the fit plane also corrected three hips. The range of movement of inclination of the cup with placement of a screw was 0-9 degrees (mean 2.5 degrees); with insertion of the liner after screw placement, it was 0-6 degrees (means 2.0 degrees). Change in AdjAV after screw placement was 0-6 degrees (mean 2.3 degrees); with liner impaction after screw placement the range was 0-5 degrees (mean 2.4 degrees). A solidly press-fit cup moves on average 2-3 degrees with a range of 0-6 degrees for any maneuver done to the cup after implantation. This movement can affect the correlation between computer and radiograph when the precision is five degrees or less.

DISCUSSION

This study was performed to determine if an imageless computer-navigated acetabular cup position would be more accurate than our experience with manual implantation of 11% outliers with inclination and 8% with anteversion as measured on radiographs.[1] By the criteria for this study, the final 40 computer cup placements had 2.5% outliers from the radiographic measurement for inclination and anteversion. The CT scans verified the accuracy of the radiographic and computer techniques for inclination and anteversion within 2-3 degrees. The precision for outliers with the computer was five degrees whereas with the radiographic study,[1] the precision was 15 degrees. If a precision of 15 degrees was used for this computer study, then the precision would have been 0 outliers. This imageless computer navigation reduced the outliers even while improving the range to 5 degrees within which the acetabular component was implanted. DiGioia et al[3] reported that with a CT-image planned navigation, they also achieved acetabular cup alignment within five degrees of the preoperatively planned position. Therefore, the first hypothesis of this study proved that an accurate imageless computer system for acetabular component placement could be developed.

The precision with this computer program can be compared to the results of mechanical guides of DiGioia el al[3] who had 78% outliers, of Hassan et al.[5] who had 42% outliers, and our own experience[1] of 11% inclination and 8% anteversion outliers. This computer program can eliminate outliers for even the most experienced hip surgeon and is accurate in its expression of the cup position. All surgeons would benefit by use of this computer program because it provides "real time" intraoperative information that reduces the variables the surgeon must consider when making judgment decisions within the time and stress constraints of the operating room.

The computer number cannot be accurate unless mechanical and computer variables are controlled. Mechanical factors that must be insured are: 1) The pins that secure the base to the pelvis (or the femur) are secure and remain so during the operation. The quality of bone into which these are placed is important so that the pin fixation can withstand the vibration of the retraction of the femur and the malleting of the trial and cup into the pelvis; 2) The tools used must have secure fixation of the antennae, which hold the light emitting diodes, because a loose antenna will give incorrect information to the computer and thus there also needs to be a "check and balance system" for the accuracy of the tools (such as the fit plane for the cup holder).

The computer factors that can affect the precision of measurement are: 1) the registration of the AP plane. The thickness of fat over a bone can distort the measurement, so the registration pointer must always be punctured through skin to the pubic bone and likewise through the skin to the ASIS when this bone is not prominent; 2) the fit plane must be measured to confirm the numbers from the cup holder. The fit plane must be measured after any technical maneuver that can change the cup position, particularly if the computer position is to be compared to the radiographic position; 3) The most important factor which improved accuracy was the tilt of the pelvis in the position the operation is performed. Precision of the computer within 5 degrees of the radiographic numbers—and particularly accuracy of the computer to the true position of the cup—cannot be known without knowledge of the flexion/extension tilt of the pelvis. The registration of tilt must be confirmed by two measurements. When all these mechanical and computer variables are controlled, the accuracy of the computer is near 100% for anteversion and inclination.

Another lesson learned was the importance of the software, which has to be mathematically correct and provide three-dimensional measurements. This is particularly evident with measurement of inclination of the cup. Several studies have suggested that 30 to 50 degrees of inclination was a safe range for stability and impingement.[7,8,10,11] However, this study defined inclination according to the center of rotation and medialization of the cup. The finite element studies assume a normal osseous acetabulum, but this is seldom so with arthritic hips. Most common is superior-lateral subluxation of the femoral head which enlarges the acetabulum and requires a larger cup, the implantation of which elevates and medializes the cup position.

Reaming of the abnormal acetabular anatomy cannot be predicted preoperatively and may be more supe-

rior or medial than anticipated. The reamed position for the acetabular component must provide osseous coverage without anterior-superior protrusion of the metal of the cup (to prevent cup-neck impingement in flexion). Medialization may be necessary for osseous coverage of the cup in many hips because the native acetabulum has a mean inclination of 60 degrees.[5] Therefore, inclination with proper osseous coverage was related to the elevation and medialization of the CR by reaming. AdjI ranged from 33-48 degrees according to the center of rotation and medialization of the cup. Intraoperative technical adjustment of inclination requires three-dimensional measurements in the software of the imageless computer navigation system.

This imageless computer navigation for total hip replacement will be accurate at 97-100% if the following factors are done: 1) Mechanically, the fixation of the pins to the pelvis must be secure and fixation of the antenna for the light emitting diodes to the cupholder is secure; 2) The computer registration of tilt has a check and balance of two measurements on two posts; 3) The fit plane is measured after the removal of the cup holder to provide a check and balance of any manipulation of the cup and the mechanical stability of the tools; 4) The tilt of the pelvis is known in the position of operation.

An important requirement for successful use of the computer is a knowledgeable, trained operating room team. Use of the computer in the operating room requires dedication by a circulating nurse (YH) who thoroughly understands the system. The scrub technician must calibrate the tools correctly or all values are in error. With a dedicated team, and using the checks and balance listed in this study, the learning curve for a surgeon should not be more than 5-10 operations. Trust in the accuracy in any operating room can be validated by insuring that the precision of the computer measurements to the radiographic technique used by us is within five degrees for those 5-10 operations.

ACKNOWLEDGMENTS

The authors would like to acknowledge the support of Louis Amiot, M.D., and Herbert Janssen (hip engineer) at Orthosoft in Montreal, Canada. The work of Leighellen Sirianni, OPA-C, Director of Clinical Research at the Arthritis Institute is appreciated, as was the preparation of the manuscript by Patricia J. Paul. Financial Disclosure: Zimmer for research support, and Orthosoft for research support.

REFERENCES

1. **Berry DJ, Berger RA, Callaghan JJ et al:** Minimally invasive total hip arthroplasty. Development, early results and a critical analysis. *J Bone Joint Surg* 85A:2235-2246, 2003.
2. **DiGioia AM, Jaramaz B, Blackwell M, et al:** Image guided navigation system to measure intraoperatively acetabular implant alignment. *Clin Orthop* 355:8-22, 1998.
3. **DiGioia AM, Jaramaz B, Plakseychuk, AY et al:** Comparison of a mechanical acetabular alignment guide with computer placement of the socket. *J Arthroplasty* 17:359-364, 2002.
4. **Jolles DM, Genoud P, Hoffmeyer P:** Computer-assisted cup placement techniques in total hip arthroplasty improve accuracy of placement. *Clin Orthop* 426:174-179, 2004.
5. **Hassan DM, Johnston GH, Dust WN, Watson G, Dolovich AT:** Accuracy of intraoperative assessment of acetabular prosthesis placement. *J Arthroplasty* 13:80-84, 1998.
6. **Maruyama M, Feinberg JR, Capello WN, D'Antonio JA:** Morphologic features of the acetabulum and femur: Anteversion angle and implant positioning. *Clin Orthop* 393-52-65, 2001.
7. **McCollum DE, Gray WJ:** Dislocation after total hip arthroplasty. Causes and prevention. *Clin Orthop* 261:159-170, 1990.
8. **Nishihara S, Sugano N, Nishii T, Ohzono K, Yoshikawa H:** Measurements of pelvic flexion angle using three-dimensional computed tomography. *Clin Orthop* 411:140-151, 2003.
9. **Nogler, M, Kessler O, Prassl, A, et al:** Reduced variability of acetabular cup positioning with use of an imageless navigation system. *Clin Orthop* 426:159-163, 2004.
10. **Robinson RP, Simonian PT, Gradisar, IM, Ching RP:** Joint motion and surface contact area related to component position in total hip arthroplasty. *J Bone Joint Surg* 79-B:140-146, 1997.
11. **Seki M, Yuasa N, Ohkuni K:** Analysis of optimal range of socket orientations in total hip arthroplasty with use of computer-aided design simulation. *J Orthop Res* 16:513-517, 1998.
12. **Wan Z, Dorr LD:** Natural history of femoral focal osteolysis with proximal ingrowth smooth stem implant. *J Arthroplasty* 11:718-725, 1996.

THE CLINICAL PERFORMANCE OF METAL-ON-METAL AS AN ARTICULATION SURFACE IN TOTAL HIP REPLACEMENT

William T. Long, M.D.*

ABSTRACT

The metal-on-metal articulations in total hip arthroplasty (THA) were widely used between 1960 and 1975. The McKee-Farrar and other first-generation prostheses failed at a high rate because impingement caused early component loosening. The problem of early component loosening was corrected by improved component design and better manufacturing quality. Second-generation metal-on-metal total hip replacements have experienced short and medium-term success as assessed by Harris Hip Scores and patient self-assessment. The combined annual linear wear of the metal-on-metal femoral head and acetabular insert is less than 10 mm and osteolysis has only rarely been observed in association with well-fixed metal-on-metal total hip replacements. Hypersensitivity is not a common cause of loosening with second-generation hip replacements and remains to be proven as a definitive diagnosis in unusual cases of unexplained pain. More than 40 years of use has demonstrated no increase in the incidence of renal failure or cancer in patients with metal-on-metal total hip replacements. The scientific evidence of the results using the metal-on-metal articulations would recommend its continued use in any patient who does not have compromised renal function.

INTRODUCTION

A high rate of early component loosening with metal-on-metal total hip replacements and the superior clinical results of the Charnley prosthesis during the 1970s discouraged the continued use of the metal-on-metal articulation. August[1] reported a high loosening rate in patients with the McKee-Farrar total hip arthroplasty and concluded that equatorial bearing and high friction moments contributed to failure at the bone-cement interface. Evans et al.[2] suggested that metal sensitivity caused obliteration of the blood flow to bone and bone necrosis was responsible for aseptic loosening. Walker et al.[3] demonstrated that mechanical failure caused loosening when impingement of McKee-Farrar femoral neck against the rim of the acetabular component compromised component fixation. Retrieved total hip replacement components and periprosthetic tissue provided important information to determine what caused the high rate of aseptic loosening observed with the use of first-generation metal-on-metal hips. Equatorial bearing and jamming was suspected but the study of retrieved implants never demonstrated this mechanism of failure. All of the retrieved total hip prostheses had polar bearing and a diametral clearance of 120 mm or greater between the ball and socket.[4,5] Low wear has been a consistent finding with cobalt-chrome on cobalt-chrome total hip articulations. Anissian et al.[6] found that the metal-on-metal hip prosthesis generates 100-fold less wear debris than metal-on-polyethylene in hip simulator studies. The combined annual linear wear rate for both first and second generation metal-on-metal articulations is reported to be from 1 to 6 mm according to implant retrieval studies.[7,8,9,10] Low in vivo wear rates were measured in both the McKee-Farrar and Metasul retrievals and durability of the bearing surface was established by the study of implants retrieved from patients more than 20 years after the index operation.[11] The histological response of tissues around metal-on-metal hips is different than the response of periprosthetic tissues to polyethylene wear debris.[11,12] Macrophages and giant cells that are associated with osteolysis are not prevalent around retrieved metal-on-metal components.

Periprosthetic tissue specimens around revised metal-on-metal hips demonstrated fibrous tissue and little inflammation in some hips and perivascular lymphocytic infiltrates with plasma cells in others. Hypersensitivity reaction has not caused a high rate of component loosening or a high incidence of unexplained pain with the use of second-generation metal-on-metal total hip replacements.[13,14,15,16] There is growing evidence that the smaller volume of wear debris generated by metal-on-metal bearing couples results in a lower incidence of osteolysis.[17] Bone loss observed in association with well-fixed metal-on-metal hips has been limited to

Correspondence:
*William T. Long, M.D.
The Arthritis Institute
501 E. Hardy Street, 3rd Floor
Los Angeles, CA 90301
Telephone: 310-695-4800
FAX: 310-695-4802
EMAIL: patriciajpaul@yahoo.com

calcar resorption from stress shielding. The radiographic findings with metal-on-metal bearings do not resemble those seen in patients with osteolysis from polyethylene debris.[13] There is one published case report of osteolysis in a patient with a well-fixed metal-on-metal hip.[18]

Zimmer reports that more than 250,000 of the Metasul articulations have been sold worldwide since November 1988 and eight manufacturers currently offer metal-on-metal articulations for hip replacement and surface replacement arthroplasty.[16,17]

The purpose of this review is to describe causes of component loosening and describe the improvements that corrected the problem, review current in vivo wear data, provide evidence that the incidence of overall osteolysis has decreased with the use of metal-on-metal articulations, and show that hypersensitivity is not proven to be a definitive diagnosis in unusual cases of unexplained pain.

We have experience with 582 patients (619 Metasul articulations), and the majority of published data of four years or more are on this articulation couple, so the results of Metasul will be the focus of this review.

LOOSENING

First generation metal-on-metal THAs failed due to acetabular and femoral component loosening at a higher rate than Charnley's prosthesis. Dandy and Theodorou[19] reported the loosening rate in 739 McKee-Farrar THRs with 3.1% for the femoral component and 4.4% for the acetabular component at 2 to 7 year follow-up. In a study of 230 McKee-Farrar prostheses, August[1] reported 50% femoral component loosening, 51% acetabular component loosening, and 67.7% overall loosening at an average follow-up of 13.9 years. Dobbs[20] introduced survivorship to the orthopaedic literature with a study of 273 Stanmore THRs. The Stanmore femoral component had a similar design to the McKee-Farrar and a similar poor survival rate of 53% at 11 years. Despite the similar pattern of early failure reported by each of these investigators, the cause of loosening was poorly understood.

In 1974, Peter Walker[3] suggested that impingement was a reason for loosening and demonstrated that the neck of the femoral component made repeated contact against rim of the acetabular component. The design flaw was the large diameter femoral neck and unfavorable head/neck ratio of the McKee Farrar, Stanmore, and similarly designed total hip prostheses. Szuszczewicz[21] observed that metalosis, component loosening, and progressive bilateral pelvic osteolysis was caused by impingement in one patient with failed bilateral McKee-Farrar hips. During the past two decades, designers of total hip prostheses have come to understand that bearing surface damage, component loosening, and hip dislocation are all potential consequences of hip component impingement.

Second generation metal-on-metal THAs were introduced with more favorable head-neck ratios and the incidence of impingement and aseptic loosening has decreased. Second-generation metal-on-metal hips do not have a high failure rate due to aseptic loosening.[17] Recent studies with second-generation metal-on-metal prostheses show a low rate of aseptic loosening that is not higher than the rate reported with metal-on-polyethylene.[22,23] Improved component design has diminished, but not eliminated impingement as a contributing factor in cases of aseptic loosening.

Inadequate diametric clearance can contribute to loosening by causing equatorial contact, high torque, and jamming. In a hip simulator wear test, Farrar et al.[24] demonstrated that a complete seizure was observed after 20,000 cycles for the samples having a negative diametral clearance (-40 and -74 μm). Semlitsch[25] reported the analysis of six retrieved Huggler and 11 Muller prosthesis and demonstrated diametral clearance in the range 120-200 μm, with one bearing couple having a diametral clearance of 500 μm. McKellop et al.[8] retrieved McKee-Farrar hips and reported a diametral clearance of 127-386 μm, with one outlier with an extreme clearance of 1.75 mm. None of these specimens had equatorial contact and the author is not aware of any report of retrievals with inadequate diametral clearance that caused jamming and loosening.

Jones et al.[26] believed that cobalt toxicity was responsible for component loosening in a series of loose McKee hip arthroplasties. Willert[27] continues to support the possibility of a lymphocyte-dominated immunological response as an uncommon cause of loosening. The experience with second-generation metal-on-metal hip prostheses suggests that if hypersensitivity is a cause of loosening, then its prevalence is low.[17,27] Both first and second-generation metal-on-metal total hip replacements generate a similar volume of wear debris, but the high loosening rate that was observed with first-generation metal-on-metal hips was not been observed with the use of second-generation hips.[7,17] The low loosening rates observed with second-generation metal-on-metal hips suggest that it is unlikely that the high rate of loosening with the use of first-generation implants was caused by an allergic reaction to metal debris. Better component design, including a more favorable head-neck ratio, and a decreased incidence of impingement probably contributed most to the improved loosening rates, and components designed with an unfavorable head/neck ratio are no longer used.

WEAR

Cobalt-chrome bearings demonstrate wear well below the annual linear wear of 100 μm per year that is considered to be the threshold for osteolysis.[16,27,28,29] A combined annual linear wear below 10 μm has been observed in hip simulator wear tests and substantiated by analysis of retrieved first and second-generation hip replacement articulations.[9,31,33] Wear of this magnitude cannot be measured radiographically, so assessment of wear in vivo has been done on implants obtained during revision hip surgery and on autopsy retrievals. The earliest reports of wear from metal-on-metal retrievals were anecdotal in character and based of small numbers of failed implants. Smith[32] described eight patients revised for loosening of Gaenslen cups mated to Austin-Moore femoral prostheses. The retrieved prostheses showed virtually no visible signs of wear and the tissues involved about the metal showed little staining, discoloration, or pathologic changes to indicate wear. Walker et al.[3] analyzed wear of 12 retrieved McKee-Farrar prosthesis using low power microscopy, scanning electron microscopy, and surface profilometry. Three types of wear were described: type 1, a surface with initial scratching, type 2, a surface in which the scratches had been smoothed or polished, and type 3, a smoothed surface (after scratching) showing signs of deterioration. The depth of wear estimated by stylus profilometry was estimated to be 1 μm. When modern techniques to analyze wear were applied to retrieved first-generation implants similar low wear measurements were obtained. Jantsch et al.[31] reported an annual linear wear of 1 μm for three McKee-Farrar hips retrieved 14 years after implantation. Using a coordinate measuring machine Schmalzreid et al.[33] found a combined annual linear wear of 4.2 μm more than 20 years after implantation of five McKee-Farrar hips. The annual linear wear rate was below 5 μm for 11 Mueller, and for six Huggler prostheses that were implanted for an average of 11 years (range 3-20).[25] The consistently low in vivo wear rates established by retrieval studies of first-generation metal-on-metal total hip replacements stimulated interest in reintroducing metal-on-metal as wear resistant articulation.

Second-generation metal-on-metal hip prostheses were manufactured using modern techniques in order to promote lubrication and further decrease wear.[7] The Metasul bearing surface was manufactured as a wrought-forged, high-carbon cobalt-chrome, and the diametral clearance was approximately 100 μm.[7,17] Wrought-forged cobalt chrome alloys are harder, and have better abrasive and adhesive wear characteristics than cast alloys.[7] High-carbon cobalt-chrome (0.20-0.25% C) alloys were developed to induce a lower wear rate than a low-carbon cobalt-chrome (0.05-0.08% C) alloys.[7] Hip simulator studies have shown that a small clearance decreases the wear of metal-on-metal bearings, but clearance must be sufficient to prevent jamming. Seiber et al.[9] reported the wear of 118 retrievals with the Metasul articulation couple as 5 μm 3 to 8 years after implantation. Rieker et al.[7,34] reported the results of 172 Metasul couples with an annual linear wear rate of 6.2 μm. Recent published reports have all shown that the annual linear wear is below 10 μm with the use of second-generation implants. Although laboratory studies indicated that the wear of second-generation metal-on-metal THRs should be lower than that of first-generation devices, retrieval analyses do not indicate superiority in this regard.[34,35]

OSTEOLYSIS

Metal-on-metal articulations were reintroduced to address the emerging problem of osteolysis. August[1] defined bone erosions adjacent to the components and/or a change position of the McKee-Farrar components as loosening. In that study, bone erosions were not considered to be osteolysis. Using those criteria, 67.7% of the patients had radiographic evidence of loosening and none had osteolysis. In a study by Zahiri et al.[11] of 15 hips with McKee-Farrar THAs still in place at 21 to 26 years postoperatively, only 4 of the 15 (25%) had some osteolysis. In that study, 10 periprosthetic tissue specimens were obtained from a group of 15 patients that had revision of a McKee Farrar hip replacement. Chronic inflammation (lymphocytes, and plasma cells) was minimal to absent in all cases. Multinucleated histiocytes (foreign body-type giant cells) were mostly found along the edges of polymethylmethacrylate globules. These radiographic findings and the histological findings demonstrated that the response of the human body to metal debris from the McKee-Farrar total hip replacements could be distinguished from the response to polyethylene wear debris.

Published reports with the use of second-generation metal-on-metal prostheses indicate that osteolysis is only rarely observed in association with well-fixed components. In our report of 156 patients (161 hips),[13] only calcar resorption in nine hips (5.5%) (with no other osteolytic lesions) was observed at an average of seven years follow-up. Calcar resorption was a focal radiolucent area seen immediately beneath the collar of the femoral stem, identified by its location between the calcar cortical bone, and the medial stem.[35] The radiographs of eight of the hips showed radiolucencies that had a maximum size of 2 x 2 mm. One patient had a lesion that grew to 2 x 2 cm five years after the index hip operation. Nine other recent clinical studies with

radiographic follow-up of second-generation metal-on-metal hip replacements report no osteolysis.[13,14,15,23,35,40,41] Beaule[18] reported one case of osteolysis in a patient with a well-fixed, cementless, Zweymuller stem coupled with a Metasul metal-on-metal bearing. In that report, localized osteolysis was identified on the plain radiographs at the tip of the Zweymuller, Ti alloy stem. At the time of revision surgery minimal bearing surface wear was visible and there was no metallic staining of the capsule or acetabular membrane. Specimens of tissue from the hip capsule and the femur in the area of osteolysis showed only small numbers of inflammatory cells, such as macrophages and no lymphocytic infiltrations or granulomas. The authors concluded that this was not a typical case of particulate-induced osteolysis as seen with polyethylene wear debris. Joint fluid pressure within the effective joint space was implicated as the cause of the osteolytic lesion. The predominantly histiocytic inflammation with abundant giant cells that is associated with metal-on-polyethylene debris is a not observed in association metal-on-metal wear debris.

HYPERSENSITIVITY

Evans et al.[2] were recognized as the first to draw attention to the possibility that metal toxicity occurred after total hip replacement using metal-on-metal bearings. They suggested that in certain patients, the release of metal from a prosthesis may resulted in tissue sensitization and that this was detected clinically by a skin patch test in which a soluble salt of the metal was used as the test object. They reported that the release of metal from prostheses in metal-sensitive patients caused obliterative changes in blood vessels supplying the bone into which the prosthesis was implanted. According to this theory, metal sensitivity caused bone necrosis and loosening of the McKee-Farrar prostheses. Jones et al.[26] reported cobalt toxicity in seven patients that had failure due to aseptic loosening after McKee hip arthroplasty from nine months to four years after the index total hip replacement. Six of these patients were cobalt-positive, but nickel- and chrome-negative on patch testing. In patients with McKee-Farrar or Charnley prostheses, these authors suggested that cases of aseptic loosening were caused by sensitivity of the tissues to one of the metals in the alloy of which the prosthesis is composed.

Several authors have reported on the histological appearance of periprosthetic tissues obtained from the area around early metal-on-metal joint replacements and they did not identify any lymphocytic or plasma-cell infiltration of the periprosthetic tissues.[11,26,32] Wilert et al.[30] analyzed tissues that had been retrieved from fourteen hips in which a contemporary metal-on-metal joint replacement had failed after an average of thirty months in vivo. The investigators found a perivascular lymphocytic infiltrate, which they suggested was similar to that found in association with a type-IV hypersensitivity reaction. The histopathological changes in the soft tissue were characterized by few wear particles and granulomas compared to tissues obtained from patients with osteolysis from polyethylene debris. Davies et al.[12] also reported an unusual lymphocytic perivascular infiltration in tissues around contemporary metal-on-metal joint replacements. The lymphocytic infiltration was more pronounced in samples obtained at the time of revision for aseptic loosening than in samples retrieved at the time of autopsy or during arthrotomy for reasons other than aseptic failure. The authors did not know the prevalence or clinical implications of the findings, but suggested that they may represent a novel mode of failure for some metal-on-metal joint replacements.

The diagnosis of hypersensitivity was considered as a possible explanation for the high rate of failure of first-generation metal-on-metal total hip replacements. The low incidence of loosening or clinical symptoms reported with the use of second-generation metal-on-metal prostheses suggests that hypersensitivity is not a common problem that leads to failure and that it should only be considered a diagnosis of exclusion in a small number of patients with unexplained pain. In a study by Dorr et al.[16] of 213 hips with a Metasul articulation, two patients (1%) were explored and had exchange of a metal-on-metal bearing surface with a preoperative diagnosis of hypersensitivity. Tissue and serum samples were sent to the laboratory for examination and neither patient had positive serum levels that indicated allergy to the implant. One patient had perivascular lymphocytes in only one of seven tissue samples, and the other patient had lymphocytes in four of five specimens. Neither patient had relief of pain more than one year after exchange of the metal-on-metal bearing surface for a metal-on-ceramic bearing. Pain was completely relieved in one patient two years the index hip operation following an operation for degenerative disease of the lumbar spine. The authors concluded that neither case qualified as a definitive diagnosis of hypersensitivity. There have never yet been reported cases of hypersensitivity that included a symptomatic patient, positive serologic testing for hypersensitivity, and tissue specimens that substantiated the diagnosis of a hypersensitivity reaction.

DISCUSSION

The clinical results of metal-on-metal have been studied for more than 40 years, including second-generation metal-on-metal results that are approaching 20 years

in Europe and 10 years in the United States. We here review the status of metal-on-metal total hip articulations based primarily on the clinical performance reported in human subjects. It is now generally accepted that the early loss of fixation observed with first-generation metal-on-metal hips was due primarily to poor component design, and this problem was corrected by improved second-generation implants designs. The combined annual linear wear rate for metal-on-metal hip replacements in vivo is well established and it has been consistently reported to be below 10 μm. Osteolysis has been a rare radiographic finding during the first 10 years of reports with the use of second-generation metal-on-metal hips. Tissue specimens demonstrate that the histological response that defines polyethylene induced osteolysis is not found in association with well-fixed metal-on-metal total hip replacements. Hypersensitivity is currently a diagnosis based on pathological findings of lymphocytes adjacent to blood vessels in capsules of retrievals and it is not a common cause of hip pain or component loosening.

For more than three decades, the problem of aseptic component loosening was poorly understood and several theories were proposed. The Charnley prosthesis was referred to as a low friction arthroplasty and the relatively higher friction of metal-on-metal articulations demonstrated by the pendulum that lead some investigators to suspect that high friction was the cause of early loosening.[7] Retrieval studies that examined both first and second-generation metal-on-metal hips did not identify increased friction as a cause of failure. All metal-on-metal specimens retrieved during the past 40 years have demonstrated polar bearing.[7] Polar bearing and increased diametral clearance have been shown in simulator studies and by retrievals to cause higher bearing surface wear rates, however, none of the retrieved couples that had a wide diametral clearance failed as a direct result of excessive wear. The optimal diametral clearance for total hip replacement articulations is reported to be between 50 and 100 μm.[7] Retrieved specimens with diametral clearances greater than 100 μm demonstrated more wear than couples with smaller clearance, however, combined annual linear wear was still below 10 μm. It is now generally accepted that the high rate of early loosening observed with first-generation total hip replacements was not due to clamping or jamming of the articulation couple. The problem of early metal-on-metal component loosening was corrected when implants were redesigned.

The low wear of metal-on-metal articulations was established both in vitro and in vivo. There are no reports of catastrophic failure or wear-through. Based on the published annual linear wear rates established for metal-on-metal, a well-fixed hip replacement could function in an active patient for more than thirty years without wearing out. Attention has turned away from the problems of early failure due to loosening or late failure due to wear. The focus today is on evaluating potential problems that might occur as the result of metal-on-metal wear debris and metal ions. It is well established that small cobalt and chromium particles and ions are generated by the metal-on-metal bearing surface, widely distributed throughout the body through the bloodstream and the lymphatics, and excreted in the urine. Serum, blood, and urine samples consistently demonstrate elevated levels of chromium and cobalt compared to the levels measured in patients with metal-on-polyethylene implants. The clinical significance of these elevated ion levels is unknown. Long-term follow-up of patients with first generation metal-on-metal total hip replacements, and short-term follow-up of patients with second-generation metal-on-metal implants have not demonstrated any unique complications. In spite of the concerns of some authors that complications such as cancer or hypersensitivity would occur, currently none have been reported clinically. It is likely that large, long-term, multi-center studies will be necessary to identify any increased risk of local or systemic disease caused by the use of metal-on-metal bearing surfaces for total hip replacement.

There is no radiographic evidence the wear debris being produced at the metal-on-metal interface leads to the occurrence of osteolysis. In the author's study of 161 total hip arthroplasties (154 patients), the only bone erosion that was measured was calcar resorption.[13] It was not possible to determine whether this calcar resorption was from stress shielding or particulate debris. Other authors have not classified calcar resorption as osteolysis.[42] Small focal radiolucent areas that were seen under the collar of 9 out of 161 hips were not considered in the definition of osteolysis. Maloney et al.[43] defined relatively small punched-out areas of bone loss under the collar as typical zone 7 osteolytic lesions. Goetz's description of osteolysis included only those lesions that caused scalloping of the endosteal cortex. These findings are in agreement with other authors who have reported cementless metal-on-metal hip arthroplasty without any osteolysis at five and six year follow-up. Longer follow-up is necessary to determine if the low incidence of osteolysis will continue beyond the first decade. The Metasul articulation has been implanted in patients in Europe since 1988. The author is not aware of any reports of the incidence osteolysis.

Hypersensitivity has been suggested as a possible unique complication and cause of failure for metal-on-metal hip arthroplasties. Hypersensivitity is a diagnosis described by Willert, based on the occurrence of lymphocytes adjacent to blood vessels in capsules of

retrievals from failed metal-on-metal hip arthroplasties.[27,30] Hallab et al.[44] described a triple assay technique for the evaluation of metal induced, delayed type hypersensitivity responses in patients with total joint arthroplasty. The most conclusive result using this assay would be a strongly positive response to all three aspects of the triple assay technique to both cobalt and chromium ions. To our knowledge, there have been no reports of unexplained pain associated with radiographic evidence of implant loosening, supported by a positive response to the triple assay technique. Reports with the use of second-generation metal-on-metal prostheses indicate that unexplained pain occurs only rarely and loose prostheses are uncommon and therefore the diagnosis of hypersensitivity as a clinical problem remains elusive.

The potential for permanent biological fixation with noncemented components, combined with a bearing surface that does not fail due to wear or osteolysis, makes it conceivable that total hip replacements implants could survive in active patients for more than 30 years. If the clinical results are as good as metal-on-polyethylene articulations, the mechanical complications are no greater, and there is no observed increased incidence of adverse biological reactions, then continued use of metal-on-metal articulation couples is justified.

REFERENCES

1. **August AC, Aldam CH, and Pynsent PB:** The McKee-Farrar hip arthroplasty. A Long term study. *J Bone Joint Surg* 68-B(4) 520-527, 1986.
2. **Evans EM, Swansea, Wales, Freeman MAR, Miller AJ, Vernon-Roberts B:** Metal sensitivity as a cause of bone necrosis and loosening of the prosthesis in total joint replacement. *J Bone Joint Surg* 56B(4): 626-642, 1974.
3. **Walker PS, Salvati E, Hotzler RK:** The wear on removed McKee-Farrar total hip prostheses. *J Bone Joint Surg* 56A(1):92-100, 1974.
4. **Doerig MF, Odstrcilik E, Jovanovic M, et al:** Uncemented Alloclassic-Metasul total hip arthroplasty: early results after 2-6 years. In Rieker C, Wyndler M, Wyss U, editors. *Metasul: a metal-on-metal bearing*. Bern (Switzerland): Hans Huber:157, 1999.
5. **Doerig MF, Kratter R, Ritzler T, et al:** Ceramic-on-polyethylene versus metal-on-metal: a clinical and radiological followup study, five to ten years after implantation. In Rieker C, Oberholzer S, Wyss U, editors. *Word tribology forum in arthroplasty*. Bern (Switzerland): Hans Huber:197, 2001.
6. **Anissian HL, Stark A, Gustafson A, Good V, Clarke IC:** Metal-on-metal bearing in hip prosthesis generates 100-fold less wear debris than metal-on-polyethylene. *Acta Orthop Scand* 70(6):578-582, 1999.
7. **Rieker CB, Schon, R, Kottig, P:** Development and Validation of a second-generation metal-on-metal bearing. Laboratory studies and analysis of retrievals. *J Arthroplasty* Vol 19(Suppl 3): 5-11, 2004.
8 **McKellop H, Park SH, Chiesa R, et al:** In vivo wear of 3 types of metal on metal hip prostheses during 2 decades of use. *Clin Orthop* 329(Suppl):S128, 1996.
9. **Siber HP, Rieker CB, Kottig P:** Analysis of 118 second-generation metal-on-metal retrieved hip implants. *J Bone Joint Surg* A:810B(1): 46-50, 1999.
10. **Rieker CB, Koettig, P, Schoen R, et al:** Clinical wear performance of metal-on-metal hip arthroplasties. In Jacobs JJ, Craig TL, editors. *Alternative bearing surfaces in total joint replacement*. West Conshohocken (Pa): ASTM Spec. Tech. Publ 1346, 144, 1998.
11. **Zahiri CA, Schmalzreid TP, Embramzadeh E, et al:** Lessons learned from loosening of the McKee-Farrar metal-on-metal total hip replacement. *J Arthroplasty* 14:326, 1999.
12. **Davies AP, Willert HG, Campbell PA, Learmonth ID, Case CP:** An unusual lymphocytic perivascular infiltration in tissues around contemporary metal-on-metal joint replacements. *J Bone Joint Surg* 87A(1):18-27, 2005.
13. **Long, WT, Dorr, LD, Gendelman, V:** An American experience with metal-on-metal total hip arthroplasties. A 7 year followup study. *J Arthroplasty*. Vol 19(8), Suppl 3: 29-34, 2004.
14. **Migaud H, Jobin, A, Chantelot C, Giraud F, et al:** Cementless metal on metal hip arthroplasty in patients less than 50 years of age. Comparison with a matched control group using ceramic-on-polyethylene after a minimum 5 year followup. *J Arthroplasty* Vol 19(8), Suppl 3: 23-28, 2004.
15. **Delaunay CP:** Metal-on-metal bearings in cementless primary total hip arthroplasty. *J Arthroplasty*. Vol 19(8), Suppl 3: 35-40, 2004.
16. **Dorr LD, Long WT, Sirianni L, Campana M, Wan, Z:** The argument for the use of Metasul as an articulation surface in total hip replacement. *Clin Orthop* 429:80-85, 2004
17. **Dumbleton JH, Manley MT:** Metal-on-metal total hip replacement. What does the literature say? *J Arthroplasty*, Vol 20(2): 174-188, 2005.
18. **Beaule' PE, Campbell P, Mirra J, Hooper JC, Schmalzried TP:** Osteolysis in a cementless second generation metal-on-metal hip replacement. *Clin Orthop* 386:159-165, 2001.
19. **Dandy DJ, Theodorou BC:** The management of local complications of total hip replacement by the McKee-Farrar technique. *J Bone Joint Surg* 57B(1):30-35, 1975.

20. **Dobbs HS:** Survivorship of total hip replacements. *J Bone Joint Surg* 62-B(2): 168-173, 1980.
21. **Szuszczewicz ES, Schmalzreid TP, Petersen TD:** Progressive bilateral pelvic osteolysis in a patient with McKee-Farrar metal-metal total hip prostheses. *J Arthroplasty*, Vol 12:819, 1997.
22. **Dorr LD, Wan Z, Longjohn DB et al:** Total hip arthroplasty with the use of the Metasul metal-on-metal articulation. *J Bone Joint Surg* Am 82A:789, 2000.
23. **Dorr LD, Wan Z, Heaton K:** Modular Metasul articulation with non-cemented cups: a 2-5 year followup. In Rieker C, Oberholzer S, Wyss U, editors. *World tribology forum in arthroplasty*. Bern (Switzerland): Hans Huber, 227, 2001.
24. **Farrar R, Schmidt MB:** The effect of diametral clearance on wear between head and cup for metal on metal articulations. Presented at the 43rd Annual Meeting. Orthopedic Research Society, San Francisco, CA 1997.
25. **Semlitsch M, Streicher RM, Weber H:** Verschleissverhalten von Pfannen und Kugeln aus CoCrMo-Gusslegierung bei langzetig implantierten Ganzmetall-Huftprothesen. *Orthopade* 18:377,1989.
26. **Jones DA, Lucas, HK, O'Drisccoll, M, Price CHG, Wibberley, B:** Cobalt toxicity after McKee hip arthroplasty. *J Bone Joint Surg* 57B(3):289-296, 1975.
27. **Willert HG, Buchhorn GH, Fayyazi A, Flury R et al:** Metal-on-metal bearings and hypersensitivity in patients with artificial hip joints. A clinical and histomorphological study. *J Bone Joint Surg* 87A(1): 28-36, 2005.
28. **Dowd JE, Sychterz CJ, Young AM, Engh CA:** Characterization of long-term femoral head penetration rates. Association with and prediction of osteolysis. *J Bone Joint Surg* 82A:1102-1107, 2000.
29. **Wan Z, Dorr LD:** Natural history of femoral focal osteolysis with proximal ingrowth smooth stem implant. *J Arthroplasty* 11:718-725, 1996.
30. **Willert HG, Buchhorn GH, Fayyazi A, Lohmann CH:** Histopathological Changes in Tissues Surrounding Metal/Metal Joints—signs of delayed type hypersensitivity? (DTH). *Word Tribology Forum in Arthroplasty*. Bern, Switzerland: Hans Huber: 147-166, 2001.
31. **Jantsch S, Schwager IW, Zenz P, Semlitsch M, Fertschak W:** Long-term results after implantation of McKee-Farrar total hip prostheses. *Arch Orthop Trauma Surg*, 110:230-237, 1991.
32. **Smith RD:** Total hip placement: Metal against metal, *Clin Orthop* 95:43-47, 1973.
33. **Schmalzried TP, Peters PC, Maurer BT, Bragdon CR, Harris WH:** Long duration metal-on-metal total hip arthroplasties with low wear of the articulating surfaces. *J. Arthroplasty* 11:322-331, 1996.
34. **Rieker CB, Kottig P:** In vivo tribological performance of 231 metal-on-metal hip articulations. *Hip International* 12:73, 2002.
35. **Rieker CB, Koettig P, Schoen R, et al:** Clinical tribological performance of 144 metal-on-metal hip articulations. In Rieker C, Wyndler M, Wyss U, editors. *Metasul: a metal-on-metal bearing*. Bern (Switzerland): Hans Huber: 83, 1999.
36. **Korovessis P, Petsinis G, Repanti M, et al:** Short-term results with the Zweymuller-SL metal-on-metal total hip arthroplasty. *Eur J Orthop Surg Traumato* 12:81, 2002.
37. **Wagner H, Wagner M:** German clinical results with Metasul bearings. In Rieker C, Wyndler M, Wyss U, editors. *Metasul: a metal-on-metal bearing*. Bern (Switzerland): Hans Huber: 181, 1999.
38. **Delaunay C:** Metasul bearings in primary total hip arthroplasty: French experience and preliminary results. In Rieker C, Wyndler M, Wyss U, editors. *Metasul: a metal-on-metal bearing*. Bern (Switzerland) Hans Huber: 181, 1999.
39. **Delaunay C:** Metasul bearing survey in primary total hip arthroplasty consecutive series of 100 cementless Alloclassic-Metasul hips. In Rieker C, Oberholzer S, Wyss U, editors. *Word tribology forum in arthroplasty*. Bern (Switzerland): Hans Huber, 189, 2001.
40. **Lombardi AV, Mallory TH, Alexiades MM, et al:** Short-term results of the M^2 a-Taper metal-on-metal articulation. *J Arthroplasty*: 16, 2001.
41. **Korovessis, P, Petsinis G, Repanti M:** Zweymueller with metal-on-metal articulation: clinical, radiological and histological analysis of short-term results. *Arch Orthop Trauma Surg* 123:5-11, 2003.
42. **Goetz DD, Smith EJ, Harris WH:** The prevalence of femoral osteolysis associated with components inserted with our without cement in total hip replacements. *J Bone Joint Surg* 76A(8):1121-1129, 1994.
43. **Maloney WJ, Woolson ST:** Increasing incidence of femoral osteolysis in association with uncemented Harris-Galante Total Hip Arthroplasty. *J Arthroplasty* 11(2):130-134, 1996.
44. **Hallab NJ, Mikecz K, Jacobs JJ:** A triple assay technique for the evaluation of metal induced, delayed type hypersensitivity responses in patients with or receiving total joint arthroplasty. *J Biomed Mater Res* 53(5): 480-9, 2000.

DOES SMOKING AFFECT IMPLANT SURVIVORSHIP IN TOTAL HIP ARTHROPLASTY? A PRELIMINARY RETROSPECTIVE CASE SERIES

Russell D. Meldrum, MD; L. Daniel Wurtz, MD; Judy R. Feinberg, PhD; William N. Capello, MD

Dr. Dorr and I have interacted frequently at major national and international meetings and symposia. I have the utmost respect for Dr. Dorr's many contributions to the field of adult reconstructive surgery, his intellectual integrity, his enthusiasm and curiosity, and, finally, his sincere and on-going effort to help his fellow man. I look forward to many more years of continued academic interaction and friendship with Larry.

Bill Capello, M.D.

ABSTRACT

This retrospective study aimed to explore the effects of smoking on hip implant survivorship. The study included 147 patients (165 hips) from 1985 to 1991 who underwent total hip arthroplasty (THA) with a particular uncemented cup, and either a cemented or uncemented femoral component of the same design. Thirty-one patients (34 hips, 21 percent of study group) smoked at the time of surgery. Of 13 components (seven cups, five cemented and one cementless stem) revised for aseptic loosening, eight (8/68, 11.8 percent) were revised in six smokers, and five (5/262, 1.9 percent) were revised in four nonsmokers (p=0.0012). Multivariate covariate analysis revealed a 4.5 times greater risk of implant loosening in smokers (p=0.0662). Based on this preliminary study, further larger studies should be performed to determine the extent that smoking may contribute to THA survivorship.

INTRODUCTION

Nearly 50 million or 23 percent of people in the United States are smokers.[1] Health risks associated with smoking are numerous and well documented. Smokers are at increased risk of heart attack, stroke, respiratory disease and some cancers. In addition, there is a growing body of evidence of deleterious effects of smoking on the musculoskeletal system.[2] Smoking has been shown to increase the risks of developing osteoporosis,[3-6] hip fracture,[7] and exercise-related injuries.[8-9] In addition, smoking has been shown to have a detrimental effect on fracture and wound healing.[10-12] In one study of 202 total hip and knee arthroplasties, patients who smoked cigarettes had longer surgical and anesthetic times and consumed more health resources.[13] Recently, Møller et al, in a study of 811 consecutive patients who underwent hip or knee arthroplasty, found that smoking was the single most important risk factor for the development of postoperative complications, particularly those relating to wound healing, cardiopulmonary complications, and the requirement of intensive care postoperatively.[14]

Cigarette smoking has been shown to interfere with bone metabolism, revascularization and bone formation.[2,15-16] In particular, nicotine decreases bone healing strength as well as revascularization of bone grafts, and slows the production of osteoblasts or the bone-forming cells necessary for fracture healing.[3,17-18] Willert and Buchhorn recently described a three-phase, overlapping healing process in the osseointegration of cemented and noncemented hip implants in which they describe that primary fixation is achieved during implantation, whereas secondary fixation is a result of repair and bone remodeling during the healing process, comparable to fracture healing.[19] Results from one retrieval study implicated vascular injury and subsequent diminished blood supply at the implant-host interface as a reason for insufficient osseointegration in total hip implants.[20] Since both cemented and cementless hip implants must be stabilized long-term by a bond between living bone and the prosthesis, the question arises about the effect of smoking on hip implant survivorship over time. Therefore, this study aims at examining the effects of smoking on hip implant survivorship for cemented and cementless implants.

MATERIALS AND METHODS

Patients

One hundred eight-seven consecutive patients (205 hips) meeting our inclusion criteria were culled from the database of a single arthroplasty surgeon (WC) at a large midwestern medical center for participation in

Correspondence:
Judy R. Feinberg, PhD
Indiana University School of Medicine
Department of Orthopaedic Surgery
541 Clinical Drive—CL600
Indianapolis, IN 46202-5111
Phone: (317)-274-3173
Fax: (317)-274-3702
E-mail: jfeinbe@iupui.edu

this retrospective study. All patients underwent primary total hip arthroplasty between 1985 and 1991 and had a diagnosis of osteoarthritis or avascular necrosis of the hip. In addition, the implants used were limited to the Omnifit® porous-coated acetabular component and the Omnifit® cemented or porous-coated femoral component (Stryker Howmedica Osteonics Corporation, Allendale, NJ). These components were selected because of their reported low rates of aseptic loosening at an average ten years follow-up.[21,22] The component and diagnostic limitations were intended to diminish the effects of extraneous factors on the primary independent variable in this study, that is, the effect of smoking on implant survivorship.

Of the 187 patients (205 hips), 35 patients (35 hips) died and another five patients (five hips) were lost before five-year minimum follow-up, leaving 147 patients (164 hips), or 80 percent of the total group for participation in the study. Statistical comparisons between those who had less than five-year follow-up (40 patients, 40 hips) versus those in the study group who had a minimum five-year follow-up indicated that those in the lost-to-follow-up group were, on average, eight years older at the time of their THA; had a greater percentage of cemented versus cementless stems; and had more postoperative complications. Average length of follow-up in the dropout group was 20 months (range, one to 61 months), and during that time period there were no component revisions and one reoperation, an incision and drainage secondary to sepsis. The percentage of smokers did not differ between the dropout and study groups.

116 patients (131 hips) were categorized as either smokers or non-smokers at the time of THA. 31 patients (34 hips) or 21 percent of the group were smokers. Of the 147 patients (165 hips) with a minimum of five-year follow-up, 39 patients (42 hips) died at an average of 10.6 years after THA (range, 5.2 to 17.3 years). Attempts to contact a living relative who had first-hand knowledge of the smoking habits, as well as reoperation or revision surgery in the deceased patient group, were futile. Of the 108 patients (123 hips) in living patients, a valid follow-up interview was conducted with 93 patients (106 hips) or 86 percent of the living patients. Within the study group, there were no differences in demographic variables between those who completed the telephone interview and those who did not. All patients who participated in the follow-up aspect of this study gave informed consent to participate. Our Institutional Review Board approved this study.

All patients were routinely treated with prophylactic antibiotics prior to and 48 hours after THA, and with 325mg enteric-coated aspirin post-THA for deep vein thrombosis (DVT) prophylaxis.

Statistical Analysis

Descriptive statistics were calculated on all study variables for the total study group. Comparisons between groups (dropouts versus study group, smokers versus nonsmokers, and revision for aseptic loosening versus stable implants) were performed using a student's t-test for continuous variables and the Fisher exact test for nonparametric variables. A p-value of 0.05 was considered statistically significant. Kaplan-Meier survivorship analyses for two samples (smokers versus nonsmokers) were run using two different endpoints, (1) revision for aseptic loosening of one or both components, or (2) revision for aseptic loosening of one or both components or reoperation for osteolysis. Cox's F test was used to determine statistical differences between survivorship endpoints between smokers and nonsmokers. Multivariate Cox regression modeling, using the variables of age and body mass index at the time of surgery, gender, diagnosis, stem fixation, alcohol use, and smoking was performed to determine the estimated hazard risk regarding the endpoint of component revision for aseptic loosening.

RESULTS

Clinical Outcomes

The study group consisted of 147 patients (165 hips) with a minimum of five-year follow-up. Average age at time of the index arthroplasty was 60.5 years (range, 21 to 83). Fifty-four percent of the hip arthroplasties (89 of 165 hips) were done in females, and sixty-one percent (100 of 165) had cemented femoral components. Seventy-nine percent had a diagnosis of osteoarthritis (131 of 165 hips). Of the remaining 27 patients (34 hips) with a diagnosis of avascular necrosis, six patients (nine hips) were post renal transplant, six patients (seven hips) were steroid-related, five patients (seven hips) were alcohol-related, and the remaining 10 patients (10 hips) were post-traumatic, post femoral neck fracture, post radiation necrosis, or of unknown etiology. Average body mass index at the time of arthroplasty was 28 (range, 18 to 55) with 37 hips (22 percent) in patients having a body mass index greater than 30. Seventy-one hips (43 percent) were done in non-drinkers, with the remaining reporting either occasional or regular use of alcohol socially. Breakdown of demographic characteristics by smoking and nonsmoking is seen in Table 1. As a group, the smokers included more males, more patients with avascular necrosis, and more patients with cementless stems. Smokers were also younger and used alcohol more often than did nonsmokers.

At the time of the primary THA, 28 of the 31 smokers consumed an average 1.2 packs of cigarettes per day (range, 0.25 to two packs per day) for an average

TABLE 1
Comparison of Demographic Characteristics Between Smokers And Nonsmokers

Variable	Nonsmokers	Smokers
Patients/Hips	116/131	31/34
Deceased	34	8
Gender	54 male, 77 female	22 male, 12 female *
Age (years)	62.7	52.2 ***
Diagnosis	110 OA, 21 AVN	21 OA, 13 AVN **
Body Mass Index	28.0	27.9
Stem Type	89 C, 42 CL	11 C, 23 CL ***
Alcohol Use	61 none 40 occasional 21 regular	10 none 9 occasional 13 regular *

OA=Osteoarthritis
AVN=Avascular Necrosis
C=Cemented
CL=Cementless (porous-coated)

*p < 0.05
**p < 0.01
***p < 0.001

34 years (range, two to 60 years). Two patients smoked only cigars or pipes, and one patient chewed tobacco. As part of the follow-up interview, patients were asked to verify their smoking status since the time of their THA. No nonsmokers had taken up smoking, and five smokers had quit smoking between one and 14 years after THA.

Patients representing 50 THAs (30 percent) had no comorbid conditions at the time of surgery. The remaining 70% had comorbid conditions. The most frequently reported condition was hypertension (73 hips, 44 percent), followed by heart disease (32 hips, 19 percent), and gastrointestinal problems (20 hips, 12 percent). Eighteen of 31 (42 percent) smokers had one or more comorbid conditions compared to 77 of 116 (33 percent) of nonsmokers (p=0.26). There were no differences in the number or type of comorbid conditions between the two groups.

Average length of hospitalization for the study group was 9.2 days (range, six to 36 days). Seven patients underwent staged bilateral THA between seven and 11 days apart within the same hospitalization, accounting for the majority of the longer hospitalizations. One patient had a hospitalization greater than 18 days. That patient was a nonsmoker who developed an infection postoperatively and underwent incision and drainage 14 days post-THA and subsequently remained hospitalized for intravenous antibiotics. There was no difference in average number of hospital days between smokers and nonsmokers (8.9 and 9.2 days, respectively, p=0.58).

TABLE 2
Comparison of Reoperations and Revisions Between Smokers and Nonsmokers

Reason for Procedure	Smokers (N=31 patients)	Nonsmokers (N=116 patients)	P value
Infection	2	5	0.456
Dislocation	3	2	0.063
Osteolysis	3	10	0.545
Aseptic Loosening	6	4	0.0063**

**p < 0.01

Twenty-four patients experienced a perioperative complication including three intraoperative fractures, one wound infection, one postoperative dislocation, and one femoral nerve injury. Twenty perioperative complications occurred in nonsmokers and four occurred in smokers. Complications in the smokers included two of the intraoperative fractures, the femoral nerve injury, and postoperative atrial fibrillation. A complication occurred in nine of 34 (26 percent) hips in smokers compared to 24 of 131 (18 percent) of nonsmokers (p=0.20).

Radiographic Outcomes

Radiographic review was completed on the most recent films on all non-revised components. Five-year minimum radiographs were unavailable on 15 hips (nine percent); therefore, the average radiographic follow-up was 10.5 years (range, one to 17 years). One hundred forty-nine (90 percent) cups remained stable. One cup was stable fibrous, and three cups were unstable and unrevised to date. On the femoral side, 150 (91 percent) stems were stable, and five cementless stems were stable fibrous. There were no radiographically loose cemented or cementless stems. Two of the five stable fibrous stems were in smokers. The remaining stable fibrous stems and stable fibrous or unstable cups were in nonsmokers.

Survivorship

Thirty-five patients (24 percent) underwent 45 additional procedures on the index THA. Thirteen patients with cementless stems underwent 15 reoperations for acetabular and/or proximal femoral osteolysis involving exchange of the femoral head and polyethylene liner and bone grafting of accessible bone lesions. Average time to reoperation for osteolysis was 127 months (range, 57 to 189). Ten of the 13 patients were male, and all were under the age of 60 at the time of the index procedure. Twenty-three smokers and 42 nonsmokers had cementless stems. Of that cementless group,

TABLE 3
Mechanical Failure Rates Between Smokers and Nonsmokers

	Smokers	Nonsmokers	p value
Cup Revision for Aseptic Loosening	5	2	
Radiographically Loose Cup	0	3	
Acetabular MFR	5/34 (14.7%)	5/131 (3.8%)	0.032*
Stem Revision for Aseptic Loosening	2 C, 1 CL	3 C, 0 CL	
Radiographically Loose Stem	0	0	
Femoral MFR	3/34 (8.8%)	3/131 (2.3%)	0.103
Cup or Stem Revision for Aseptic Loosening	8	5	
Radiographically Loose Cup or Stem	0	3	
Combined Component MFR	8/68 (11.8%)	8/262 (3.1%)	0.007**

MFR=Mechanical Failure Rate
C=Cement
CL=Cementless (porous-coated)

*$p < 0.05$
**$p < 0.01$

three smokers and ten nonsmokers underwent reoperation for osteolysis with no difference between groups (p=0.30).

There were ten reoperations in seven patients due to sepsis (six incision and drainage, and four component removal). One smoker underwent two incision and drainage procedures and another smoker underwent an incision and drainage and subsequent component removal. The remaining procedures related to sepsis were in nonsmokers with no difference between groups (p=0.59). There were five reoperations secondary to dislocation; three femoral head and polyethylene liner exchanges and two cup revisions. Three patients underwent removal of heterotopic bone due to pain, and one patient had a stem revision secondary to stem fracture. The number of patients in each group (smokers and nonsmokers) who underwent a surgical procedure, either reoperation or revision, are summarized by reason for reoperation or revision procedure in Table 2. Although there was a trend toward a greater number of reoperations for dislocation in the smoking group, there was no difference in the number of patients who suffered a dislocation during the follow-up period. In addition to the five reoperations or revisions due to dislocation, another 11 patients suffered a dislocation treated successfully with closed reduction. In total, five smokers and 11 nonsmokers suffered a dislocation (p=0.23).

Thirteen components in ten patients were revised for aseptic loosening (seven cups, five cemented stems, and one cementless stem). One patient had both the cup and stem revised at a single operation. Another bilateral THA patient had both cups revised at a single operation and a third patient had a cup revision and approximately five years later had a stem revision.

The aseptic revision rate for the porous-coated acetabular components was seven of 165 (4.2 percent). The aseptic revision rate for the cemented stems was five of 100 (5 percent) and one of 65 (1.5 percent) for the porous-coated stems. Although there was no difference with regard to revision rate for aseptic loosening of porous coated stems, there was a significant difference between smokers and nonsmokers with regard to cemented stem revisions for aseptic loosening. Two of 11 cemented stems were revised for aseptic loosening in smokers compared to three of 89 cemented stems in nonsmokers (p=0.0335). The aseptic loosening rates for acetabular plus femoral components were eight of 68 components (11.8 percent) in smokers compared to five of 262 components (1.9 percent) in nonsmokers (p=0.0012). Aseptic revision rates by patient, regardless of whether one or both components were revised, was six of 31 smokers (19.4 percent) compared to four of 116 nonsmokers (2.5 percent) (p=0.0063). The component mechanical failure rates (component revision for aseptic loosening plus radiographically loose cup and/or stem) for each group are seen in Table 3.

Kaplan-Meier survivorship with an endpoint of cup and/or stem revision for aseptic loosening was 93.7 percent ± 4.3 percent, 75.3 percent ± 9.1 percent, and 37.6 percent ± 27.0 percent at 10, 15, and 18 years for smokers compared to 96.7 percent ± 1.6 percent at each of the same time intervals for nonsmokers (F=7.0886, p=0.00081) (see Figure 1). Analyses of demographic

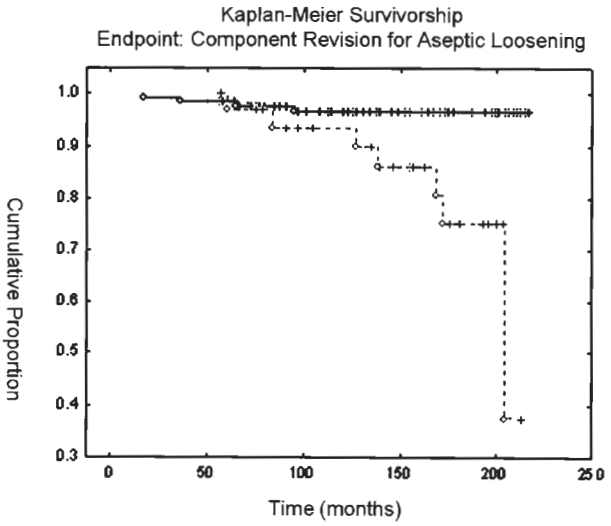

Figure 1. Kaplan-Meier survivorship using the endpoint of component revision for aseptic loosening. Solid line represents survivorship for nonsmokers. Dashed line represents survivorship for smokers.

factors between patients who had a revision for aseptic loosening (n=10) and those who did not (n=137) found no differences in age, body mass, number of comorbidities, alcohol use or stem type, with a statistical trend toward more males (p=0.05) and more diagnoses of avascular necrosis (p=0.09) in the revised group. The only statistically significant variable was smoking (p=0.006).

Results of multivariate Cox regression modeling using the covariates of gender, age and body mass index at the time of the index procedure, diagnosis, stem fixation, alcohol use and smoking found that smokers had a 4.5 times higher risk hazard than did non-smokers with regard to the endpoint of component revision for aseptic loosening (p=0.0662). Male gender yielded an 11.3 times greater risk (p=0.0391), and no other factors approached statistical significance.

DISCUSSION

There have been no prior studies examining the effect of smoking on intermediate- or long-term implant survivorship in THA. We hypothesized that there would be an increased aseptic loosening rate in smokers, regardless of whether the implant was cemented or cementless, and this hypothesis was supported, within the limitations of this study design. Interestingly, there was also no difference between smokers and nonsmokers with regard to reoperation rates for osteolysis in the case of cementless implants.

Although smokers had a higher percentage of implant failure due to aseptic loosening than did non-smokers, a larger proportion of smokers also had other demographic features which have previously been reported as associated with higher failures rates, specifically younger age, male gender and a diagnosis of avascular necrosis of the hip.[31-33] Since those reported relationships are correlational in nature, it is possible that the higher failure rates were incorrectly attributed to those factors if smoking history was not considered. In multivariate analysis, controlling for other covariates, smokers were found to have a 4.5 times greater hazard risk than did non-smokers with regard to the endpoint of component revision for aseptic loosening in this study. The only variable that posed a significantly greater risk was male gender.

This retrospective study is the first to explore the possible deleterious effect of smoking on total hip implant survivorship, and although the results indicated only a statistical trend in multivariate analysis, the percentage differences in failure noted between smokers and nonsmokers are compelling and, we believe, worthy of further study. Until factors contributing to implant failure, including smoking, are studied in greater depth, it is recommended that the arthroplasty surgeon consider smoking status only in conjunction with other accepted risk factors such as age, gender, and bone quality when selecting hip implants for a given patient.

Smoking alone may or may not be a major contributor to implant failure, but in combination with other known or unknown variables, may be worthy of at least discussion between the surgeon and the patient. As an example, although cemented stems failed at a higher rate in smokers than in nonsmokers and there was no difference between groups with respect to revision for aseptic loosening of the porous coated stem in this study, because of the limited number of cases in this study, at this time the authors would not recommend the use of cementless implants over cemented implants based purely on whether the patient is a smoker or not.

Two relatively recent studies[13-14] examined the effect of smoking on the incidence of perioperative complications following total hip or knee arthroplasty with somewhat differing results. Lavernia and his colleagues[13] found that smokers had more comorbidities, longer surgical times, and higher hospital charges with no difference in the percent of complications, whereas Møller and her colleagues[14] found that smokers had a higher risk of postoperative complications, in particular wound- and cardiopulmonary-related ones. In this study, we found no differences in the average number or type of comorbid conditions or in the incidence of postoperative complications.

The effect of smoking has been studied extensively relative to fracture and osteotomy healing and in bony

fusions. In an animal model, Lau and colleagues[23] found the incidence of nonunion or delayed union to be twice as great in smokers, and Schmitz and colleagues[24] reported that grade I open tibial shaft fractures took 62 percent longer to heal in smokers. Similarly, Chen and colleagues[18] found that smokers had longer healing times and more nonunions after ulna-shortening osteotomy, and Hilibrand et al[25] found that smoking had a significant negative impact on healing and clinical recovery following anterior cervical arthrodesis with strut-grafting. It was this growing body of literature on the negative effects of smoking on various orthopaedic procedures that prompted the question of the effect of smoking on hip implant survivorship over time.

The process of osseointegration of cemented and cementless implants was described by Willert and Buchhorn[19] as occurring in three overlapping phases involving the destruction and necrosis of bone followed by repair with integration of the implant into the bone and finally a stabilization and adaptation of the implant to load transfers and other factors. Furthermore, primary fixation is achieved during implantation, whereas secondary fixation is a result of repair and bone remodeling during the healing process, a process comparable to that of fracture healing. Al-Saffar,[26] in a histologic study of osseointegration of implants, concluded that a negative balance between the rate of bone growth and resorption around the prosthesis is central to the pathogenesis of aseptic loosening. Yet another histologic study of osseointegration focused on the microvasculature around implants and concluded that vascular injury and decreased blood supply at the host-implant interface may be one reason for insufficient implant osseointegration and loosening.[20] These studies may provide theoretical support for the clinical results seen in this study. However, although osteolysis can lead to implant loosening, osteolysis may be more specifically related to particle disease whereas aseptic loosening may be more multifactorial.

In this study, to control as many extraneous variables as possible, we chose to limit the surgeon to a single experienced arthroplasty surgeon; to limit the diagnoses to osteoarthritis and avascular necrosis only; and to limit the implants in the study to those which have documented good outcomes at least ten years post-implantation. In our own published work, the aseptic revision rates for the porous-coated cup and stem were 1.3 and 2.6 percent, respectively, at an average ten-year follow-up, and 2.0 percent for the cemented stem at an average nine-year follow-up.[21-22] In this study, at an average 13-year follow-up and with the population limited to a diagnosis of osteoarthritis or avascular necrosis of the hip, the aseptic loosening rates were 4.2 percent, 1.5 percent, and 5.0 percent for the porous-coated cup, porous-coated and cemented stems, respectively. These failure rates for the porous-coated cup and cemented stem, although higher than those reported for the same components at an average three-to-four year shorter time period, include revision surgeries performed outside of the primary institution and are in concert with other reports of implant loosening at greater than ten-year follow-up.[27-30] In fact, five of the seven porous-coated cups that failed in this study group were revised between ten and 14 years post implantation.

While the overall component aseptic loosening rates are in concert with other implants in the literature, there is a striking difference in the aseptic loosening rates between smokers and nonsmokers in this study. Acetabular aseptic revision rates were 14.7 percent for smokers and 1.5 percent for nonsmokers. On the femoral side, the aseptic revision rates were 8.8 percent for smokers and 2.3 percent for nonsmokers. Differences in the numbers of smokers (n=34 hips) and nonsmokers (n=131 hips) and the relatively overall small sample sizes may magnify the percentage differences, however the proportion of smokers in this study population (31 of 147 patients, 21 percent) is similar to the 23 percent reported by the National Center for Health Statistics in 2000.[1]

Studies of the relationship between smoking, drinking, and the development of femoral head necrosis indicate a cumulative effect of alcohol use and an increased risk in current smokers with no cumulative increased risk.[34] Because of the small sample number of smokers in this study, no attempt was made to analyze cumulative dose effects of smoking on aseptic loosening. However, anecdotally, of the five patients who quit smoking at various times in the follow-up period, the three who quit at one, two and four years postoperatively had no component failures. One patient who quit smoking nine years postoperatively had a cup revision for aseptic loosening at 17 years postoperative, and one patient who quit smoking at 14 years postoperatively had undergone revision for aseptic loosening of both the cup and stem at 10.5 years postoperative. Because of the time elapsed between implantation and failure, and time of last follow-up, many other factors could have intervened which may or may not have affected our results. However, there is no known reason to suspect that intervening variables differed between the smokers and nonsmokers in this study.

Limitations of this study are the small sample size, the inability to obtain smoking and outside revision data on the deceased patients, and the retrospective nature of obtaining the smoking histories of the patients. Nonetheless, follow-up interviews were obtained on 86 per-

cent of the living patients and no statistical differences were found between those patients who completed the follow-up interview and those who did not due to death or inability to contact. The authors acknowledge the limitations of this study and consider this work a preliminary effort in determining the potential deleterious effect of smoking on total hip arthroplasty outcome. The authors recommend that future studies utilize a prospective design and a much larger number of subjects to allow for the study of multiple contributing variables including both patient and implant factors.

In summary, in this series of 147 patients (165 hips) followed an average 13 years after total hip arthroplasty, there was a significantly greater rate of component revision for aseptic loosening in patients who smoked at the time of THA and who continued to smoke for years afterward. Further study is needed to determine the extent to which smoking contributes to aseptic loosening in relationship to other known contributing factors, and whether there is a smoking dose relationship. For now, the American Academy of Orthopaedic Surgeons Fact Sheet for patients preparing for joint replacement surgery currently states that patients who smoke should try to cut down or quit prior to the arthroplasty as smoking changes blood flow patterns, delays healing, and slows recovery.[35]

REFERENCES

1. **National Center for Health Statistics:** *Health*, United States, 2002. U.S. Government Printing Office, Washington DC, 2002.
2. **Kwaitkowski TC, Hanley EN Jr, Ramp WK:** Cigarette smoking and its orthopaedic consequences. *Am J Orthop* 9:590, 1996.
3. **De Vernejoul MC, Bielakoff J, Herve M, Gueris J, Hott M, Modrowski D, Kuntz D, Miraret L, Ryckewaert A:** Evidence for defective osteoblastic function. A role for alcohol and tobacco consumption in osteoporosis in middle-aged men. *Clin Orthop* 179:107, 1983.
4. **Aloia JF, Cohn SH, Vaswani A, Yeh JK, Yuen K, Ellis K:** Risk factors for postmenopausal osteoporosis. *Am J Med* 78:95, 1985.
5. **Hollenbach KA, Barrett-Connor E, Edelstein SL, Holbrook T:** Cigarette smoking and bone mineral density in older men and women. *Am J Public Health* 83:1265, 1993.
6. **Hopper JL, Seaman E:** The bone density of female twins discordant for tobacco use. *N Engl J Med* 330:387, 1994.
7. **Law MR, Hachshaw AK:** A meta-analysis of cigarette smoking, bone mineral density and risk of hip fractures: Recognition of a major effect. *Br Med J* 315:841, 1997.
8. **Reynolds KL, Heckel HA, Witt CE, Martin JW, Pollard JA, Knapik JJ, Jones BH:** Cigarette smoking, physical fitness, and injuries in infantry soldiers. *Am J Prev Med* 10:145, 1994.
9. **Altarac M, Gardner JW, Popovich RM, Potter, R, Knapik JJ, Jones BH:** Cigarette smoking and exercise-related injuries among young men and women. *Am J Prev Med* 18;96, 2000.
10. **Nolan J, Jenkins RA, Kurihara K, Schultz RC:** The acute effects of cigarette smoke exposure on experimental skin flaps. *Plast Recontr Surg* 75:544, 1985.
11. **Sherwin MA, Gastwirth CM:** Detrimental effects of cigarette smoking on lower extremity wound healing. *J Foot Surg* 29:84, 1990.
12. **Jenson JA, Goodson WH, Hopf HW, Hunt TK:** Cigarette smoking decreases tissue oxygen. *Arch Surg* 126:1131, 1991.
13. **Lavernia CJ, Sierra RJ, Gomez-Marin O:** Smoking and joint replacement: Resource consumption and short-term outcome. *Clin Orthop* 367:172, 1999.
14. **Møller AM, Pedersen T, Villebro N, Munksgaard A:** Effect of smoking on early complications after elective orthopaedic surgery. *J Bone Joint Surg Br* 85:178, 2003.
15. **Riebel GD, Boden SD, Whitesides TE, Hutton WC:** The effect of nicotine on incorporation of cancellous bone graft in an animal model. *Spine* 20:2198, 1995.
16. **Silcox DH, Daftari T, Boden SD, Schimandle JH, Hutton WC, Whitesides TE:** The effect of nicotine on spine fusion. *Spine* 20:1549, 1995.
17. **Daftari TK, Whitesides TE, Heller JG:** Nicotine on the revascularization of bone graft: An experimental study in rabbits. *Spine* 19:904, 1994.
18. **Chen F, Osterman AL, Mahony K:** Smoking and bone union after ulnar-shortening osteotomy. *Am J Orthop* 30:486, 2001.
19. **Willert HG, Buchhorn GH:** Osseointegration of cemented and noncemented implants in artificial hip replacement. *J Long-term Effects of Med Implants* 9:113, 1999.
20. **Santavirta S, Ceponis A, Solovieva SA, Hurri H, Jin J, Takagi M, Suda A, Konttinen YT:** Periprosthetic microvasculature in loosening of total hip replacement. *Arch Orthop Trauma Surg* 115:286, 1996.

21. **Hellman EJ, Capello WN, Feinberg JR:** Omnifit cementless total hip arthroplasty. A 10-year average follow-up. *Clin Orthop* 364:164, 1999.
22. **Meneghini RM, Feinberg JR, Capello WN:** Primary hybrid total hip arthroplasty with a roughened femoral stem: Integrity of the stem-implant interface. *J Arthroplasty* 18:299, 2003.
23. **Lau GG, Luck JV, Marshall GJ, Griffith G:** The effect of cigarette smoking on fracture healing: An animal model. *Clin Res* 37:132A, 1989.
24. **Schmitz MA, Finnegan M, Natarajan R, Champine J:** Effect of smoking on tibial shaft fracture healing. *Clin Orthop* 365:184, 1999.
25. **Hilibrand AS, Fye MA, Emery SE, Palumbo MA, Bohlman HH:** Impact of smoking on the outcome of anterior cervical arthrodesis with interbody or strut-grafting. *J Bone Joint Surg Am* 83:668, 2001.
26. **al-Saffar N:** The osteogenic properties of the interface membrane at the site of orthopedic implants: The impact of underlying joint disease. *J Long-Term Effects Med Implants* 9:23, 1999.
27. **Sanchez-Sotelo J, Berry DJ, Harmsen S:** Long-term results of use of a collared matte-finished femoral component fixed with second-generation cementing techniques. A fifteen-year-median follow-up study. *J Bone Joint Surg Am* 8:1636, 2002.
28. **Mallory TH, Lombardi AV, Leith JR, Fujita H, Hartman JF, Capps SH, Kefauver CA, Adams JB, Vorys GC:** Minimal 10-year results of a tapered cementless femoral component in total hip arthroplasty. *J Arthroplasty* 16(8 Suppl 1):49, 2001.
29. **Engh CA, Claus AAM, Hopper RH, Engh CA:** Long-term results using the anatomic medullary locking hip prosthesis. *Clin Orthop* 393:137, 2001.
30. **Xenos JS, Callaghan JJ, Heekin RD, Hopkinson WJ, Savory CG, Moore MS:** The porous-coated anatomic total hip prosthesis, inserted with cement. A prospective study with a minimum of ten years of follow-up. *J Bone Joint Surg Am* 1999; 81:74, 1999.
31. **Ballard WT, Callaghan JJ, Sullivan PM, Johnston RC:** The results of improved cementing techniques for total hip arthroplasty in patients less than 50 years old. *J Bone Joint Surg Am* 76:959. 1994.
32. **Brinker MR, Rosenberg AG, Kull L, Galante JO:** Primary total hip arthroplasty using noncemented porous-coated femoral components in patients with osteonecrosis of the femoral head. *J Arthroplasty* 9:457, 1994.
33. **Kim Y-H, Oh J-H, Oh S-H:** Cementless total hip arthroplasty in patients with osteonecrosis of the femoral head. *Clin Orthop* 320-73, 1995.
34. **Hirota Y, Hirohata T, Fukuda K, Mori M, Yanagava H, OhnoT, Sugioka Y:** Association of alcohol intake, cigarette smoking, and occupational status with the risk of idiopathic osteonecrosis of the femoral head. *Am J Epidemiology* 137:530, 1993.
35. **American Academy of Orthopaedic Surgeons:** Preparing for Joint Replacement Surgery. *On-line fact sheet.* http://orthoinfo.aaos.org (July 2001).

EARLY ATTEMPTS AT HIP ARTHROPLASTY—1700s TO 1950s

Pablo F. Gomez M.D.* and Jose A. Morcuende M.D., Ph.D.

ABSTRACT

Over the last three centuries, treatment of hip arthritides has evolved from rudimentary surgery to modern total hip arthroplasty (THA), which is considered one of the most successful surgical interventions ever developed. We here review the history of the early hip arthroplasty procedures for hip arthritis that preceded Charley total hip arthroplasty. An evaluation of such past enterprises is relevant, and reminds us of the ephemeral nature of human industriousness, and how medical research and procedures are not isolated developments, but correlate to the social, economical, and cultural framework of their time.

INTRODUCTION

"Comme le Medecin, qui desire trencher
Quelque member incurable, avant que d'aprocher
Les glaives impiteux de la part offense,
Endort le patient d'une boisson glacee,
Puis sans nulle douleur, guide d'usage et d'art,
Pour sauver l'homme entier, il en coupe une part . . ."
—Guillaume de Saluste Seigneur Du Bartas.
La Sepmaine ou Creation du Monde,
Le sixiéme jour (960-65). 1581

Arthritides have defied the effectiveness of many interventions for several thousand years.[1] Joint pathologies have been evidenced in *Homo sapiens* from Saxon,[2] medieval[2] and Roman[3] excavations. *Homo sapiens neanderthalensis* bones also harbor the pathological marks of articular disease.[4]

EARLY HIP ARTHRITIS SURGERY IN THE 1800s

Toward the end of the eighteenth century, the field of operative orthopaedics was considerably advanced as a result of the progress made in identifying the physiology of the skeletal tissues that occurred during the first half of that century.

Excision of the joints was practiced liberally for many types of joint diseases. Liverpool, in the United Kingdom, had gained notoriety for its skilled surgeons, where Henry Park (1744-1831) worked at The Royal Infirmary. In a letter to Percival Pott (1717-88), a luminary of surgery and his teacher, Dr. Park described his principles of treatment:[5]

> *The resource I mean is the total extirpation of the articulation, or the entire removal of the extremities of all the bones which form the joints, with the whole, or as much as possible of the Capsular Ligament; thereby obtaining a cure by means of Callus.*

The enthusiasm shown at that time for joint excision was, as with all surgical innovations, the result of special circumstances. It was a reaction to the appalling frequency with which amputation was being practiced in Europe and America. Liverpool was a large commercial port and sailors arrived with wounded limbs, in many instances injured months before. These types of injuries required a radical treatment, which in the late 1700s meant amputation. Amputation of the extremity in these cases often offered a simple but, as Park thought, unnecessary solution to the problem.

Because of warfare that afflicted some of Europe, military surgeons were applying amputation too. As a matter of fact, amputations became so common that Johann Ulrich Bilguer (1720-96), surgeon-general of the Prussian army, wrote *De membrorum amputatione rarissime admnistranda*[6] in 1761, pleading for the conservation of injured extremities among the unfortunate soldiers who crowded the military hospitals after every great victory. However, the technical ease of amputation when compared to joint excision slowed the acceptance of this technique by Park's colleagues. During the pre-anesthesia era, expeditiousness of a procedure was most valued.

Anthony White[i] (1782-1849) of the Westminster Hospital in London, is credited with the first excision ar-

Department of Orthopaedics and Rehabilitation
University of Iowa Hospitals and Clinics, Iowa City, Iowa

Correspondence:
Pablo F. Gomez, M.D.
University of Iowa Hospitals and Clinics
4120 D MERF
375 Newton Road
Iowa City, IA 52242
Email: pablo-gome@uiowa.edu

[i] Anthony White was the first to give an account of *phlegmasia alba dolens* (deep venous thrombosis in an extremity, a common complication of THA) and was described by his contemporaries as "the most eminent surgeon by much in the North of England." Leonardo RA. *History of Surgery.* New York: Froben Press; 1943:237.

throplasty in 1821 though he did not make a personal report of the operation. This procedure ameliorated pain and preserved mobility, but at the expense of stability. It was this surgery that gained him recognition in the medical community, as described in his obituary that appeared in *Lancet*.[8]

> *He who first excised the head, neck and trochanters of the femur, the patient surviving the operation twelve years, and then dying consumptive . . . . Mr. White had been unable, from his extensive practice, to contribute any literary work to the advancement of medical science . . . although he did deliver an Hunterian Oration before the Royal Society.*

However, John Rhea Barton[ii] (1794-1871) in Philadelphia, is credited with performing the first osteotomy on an ankylosed hip in 1826.[9] He performed an intertrochanteric osteotomy without anesthesia in only seven minutes. After twenty days, he manipulated the extremity to provoke a fibrous reaction at the ends of the severed bone, and thus created a pseudarthrosis. Barton reported the surgery in the *North American Medical and Surgical Journal*.[9]

> *. . . to divide the bone through the great trochanter and part of the neck of the bone*
>
> *. . . to extend the [adducted] limb and dress the wound. After the irritation from the operation shall have passed away, to prevent, if possible by gentle and daily movement of the limb, the formation of bony union, and to establish an attachment by ligament only, as in cases of ununited (sic) fractures, or artificial joints as they are called.*

Three months after the operation, the patient walked reasonably well with a cane, but six years later all motion had been lost. Barton provided the first evidence that motion would prevent the fusion of bone. This popularized hip osteotomy as a rational plan for overcoming bony ankylosis, a hitherto untreated lesion. However, although there were some spectacular successes, the outcome was generally disconcertingly unpredictable. Most of the operated joints eventually became ankylosed, a disappointing outcome for such a perilous procedure that had a mortality rate of approximately 50 percent, high even by the day's standards.[iii]

Although Auguste Stanislas Verneuil (1823–95), from Paris, France, performed soft tissue hip interpositions in 1860, it was Léopold Ollier's[iv] (1830-1900) work at the Hôtel-Dieu hospital in Lyon, France, that generated tremendous interest in the concept of interpositional arthroplasty. In 1885, he described the interposition of adipose tissue in uninfected joints.[11] However, he did not fix the interposed material to the subjacent bone and his procedures were generally ineffective.

Subsequently, Czech surgeon Vitezlav Chlumsky (1867-1943), working in Breslau, Germany (now Wroclaw, Poland) systematically experimented with many interpositional materials. Among the wide variety of materials he used was muscle, celluloid, silver plates, rubber struts, magnesium (which had the detestable characteristic of fomenting exactly the opposite of what it was supposed to do, this being consolidation of bone osteotomies or fractures), zinc, glass, pyres, decalcified bones, wax and celluloid.[v]

Berliner Professor Themistocles Glück (1853-1942) led the way in the development of hip implant fixation. In 1891, Glück produced an ivory ball and socket joint that he fixed to bone with nickel-plated screws.[13] Subsequently, he experimented with a mixture of plaster of Paris, and powdered pumice with resin to provide fixation. The resemblance between his craftwork and the work of a carpenter or sculptor is remarkable.

Eventually, around the turn of the century, a more reasonable approach was advocated by John Benjamin Murphy[vi] (1857-1916) from Chicago, to just alter symptoms of localized osteoarthritis of the hip joint.[vii] He de-

---

[ii] Barton's name is also associated with a fracture of the dorsal ulnar articular surface of the distal radius; a figure-of-eight bandage that provides support to the lower jaw; and an obstetrics forceps with one fixed curved angle and a lunged anterior blade for application to a high transverse position of the fetal head during complicated labors.

[iii] Asepsis, which was the most important of Joseph Lister's (1827-1912) contributions to the surgical setting, was introduced in the second half of the nineteenth century. Anesthesia was around the corner, but until William Morton's sulphuric ether miracle in 1846, the most appreciated quality of a surgeon was, besides precision, speed. So, with such expedited procedures, and with the almost certain fate of infection, it was surprising that some patients actually survived many operations. For a marvelously written review of the loud and bloodier world of English surgery in the last decade of eighteen and the first half of nineteenth century, see Stanley P. *For Fear of Pain, British Surgery, 1790-1850*. Amsterdam: Editions Rodopi B.V.; 2003.

[iv] Léopold Ollier has been referred to by some as "The Father of Orthopaedic Surgery." He was born in Les Vans, Ardèche, France and developed his professional life in Lyon, France. He pioneered the use of skin grafts, and his research on periosteum allowed him to devise new surgeries for the management of joints and extremity pathologies. He was also the first to demand bone surgery be recognized as a separate discipline, in a speech at the 1867 Congress of French Surgeons.

[v] Chlumky's experiments are described in Chlumsky V. *Zentralblatt für orthopaedische Chirurgie (Continued Centralblatt für orthopaedische Chirurgie un mechanik from 1887-1890)*. 1896. He used laboratory animals for testing before actually implanting the materials in his patients. Not all surgeons at that time were as considerate as he, and most of them, without hesitation, introduced their ideas directly into their clinical practice.

[vi] John Benjamin Murphy was born in Wisconsin, in a log cabin in 1857. Murphy eventually became chief of surgery at the Mercy Hospital in Chicago, a position he held from 1895 until his death in 1916. A controversial figure for his flamboyant style, Murphy held an immense range of interests. He is most famous for his work on appendicitis, where he described the clinical sign that would eventually bear his name.

[vii] Murphy called the disease by its Latin name *malum coxae senilis*.

scribed neither implant surgery, nor resection, but just removed overhanging bone osteophytes from the base of the head of the femur and the rim of the acetabulum, a procedure described as hip cheilotomy.[14]

INTERPOSITIONAL HIP ARTHROPLASTY IN THE 1900s

Earlier in the 1900s, Murphy,[15] along with Erich Lexer (1867-1937) from München, Germany, had advocated the hip interposition of *fascia lata*.[16] This was a modification of the technique described in 1893 by another German surgeon, Heinrich Helferich (1851-1945),[viii] who worked in Tübingen and performed a similar procedure for the treatment of temporomandibular joint arthritis.[18]

Other interesting interpositional material was introduced at the turn of nineteenth century by a French surgeon, Foedre (b. ca. 1860), who noted that pig bladder was sufficiently strong to withstand the stresses of weight bearing and intra-articular pressure.[19] By 1918, William Steven Baer (1872-1931)[ix] had popularized pig bladder arthroplasty at the Johns Hopkins Hospital.[20,21] The modern concept of informed consent authorizing surgical procedures was, obviously, nonexistent at the time and surgeons acted in the best Hippocratic tradition, with authoritative decisions that most times were not discussed with the patient.

During the same period, Sir Robert Jones (1855-1933)[x] used a strip of gold foil to cover reconstructed femoral heads. Twenty-one years later, he was able to report that the patient still retained effective motion at the joint.[22] This was the longest follow-up report recorded, to that point, in the history of arthroplasty.

In 1924, Royal Whitman (1857-1946), from The Hospital for Ruptured and Crippled (now The Hospital for Special Surgery) in New York City, published the first description of hip osteoarthritis[xi] surgery by means other than fusion. He described his surgery in *Annals of Surgery*.[23]

> *The reconstruction operation may be defined as a mechanical adaptation of a hip joint disabled by injury or disease to the essential requirements of locomotion. . . . In this operation, the head of the femur is removed and the trochanter is cut from the shaft in an oblique direction with all its attached muscles so that the additional area thus obtained, together with the part of the neck that remains, may provide a secure weight.*

Following this, several modifications of the procedure were attempted with variable, but not definitive success, as it was necessary to sacrifice either mobility or stability of the joint in order to achieve remission of pain.

It was the Norwegian-born American surgeon Marius Smith-Petersen (1886-1953) from Boston, Massachusetts who in 1923 provided synthetic interpositional arthroplasty with a mold prosthesis. This arthroplasty was intended to facilitate bone-implant movement both at the femoral and the acetabular sides of the implant. Initially, Smith-Petersen had observed a smooth membrane around an excised piece of glass during an unrelated procedure. Encouraged by this finding, he designed a glass mold to be placed between the femoral head and the acetabulum. This device, according to Smith-Petersen's reasoning, would "guide nature's repair" of the joint. He also described the anterior surgical approach to the hip for use in this procedure, which bears his name, and began implanting the devices in 1932. Unfortunately, some of the molds broke, and although he was extremely excited during the revision surgeries to find glistening linings on the broken pieces of glass, the stubbornness of his patients, who persisted in their ailments regardless of the surgical evidence of success, convinced him to abandon such material. He subsequently experimented with celluloid, Bakelite, and Pyrex. In 1937, his dentist suggested he try Vitallium®, which had been recently introduced to the dentistry market. Smith-Petersen implanted 500 Vitallium® moulds in the ensuing ten years with good clinical results. This device provided the first predictable result in interpositional hip arthroplasty.[24]

[viii] In 1882, Helferich presented an eloquent defense for use of muscular interposition in the treatment of joint afflictions during the German Surgical Congress, Helferich H. ‹ber Muskeltransplantation beim Menschen. Paper presented at: Verhandlungen der deutschen Gesellschaft für orthopaedische Chirurgie, 1882. His subsequent work advocated use of that technique in the hip. Murphy's and Lexer's use of the *fascia lata* are based on his original work.

[ix] Baer founded the Orthopaedic Surgery department at Hopkins after an invitation by William Halsted, Chief of Surgery at that hospital in 1900. He also developed new procedures for low back pain and the treatment of osteomyelitis.

[x] The most important orthopaedic surgery figure at the turn of the century, Sir Robert Jones, grew up in Liverpool, United Kingdom, where he worked as an apprentice of Hugh Owen Thomas. He organized and systematized the diagnosis and treatment of bone and joint injuries during his service in World War I, when he worked as Director of Military Orthopaedics in the British Army. He was a champion of crippled children. He also produced several of the most important books in orthopaedic history such as *Orthopaedic Surgery of Injuries* (Oxford Medical Publications, London: Henry Frowde, 1921), *Injuries of Joints* (London: Henry Frowde, 1915) and *Notes on Military Orthopaedics; with an Introductory Note by Sir Alfred Keogh* (London: Cassell and Co., 1917).

[xi] In his paper, he called this disease *arthritis deformans* of the hip.

EARLY PROSTHETIC HIP ARTHROPLASTY IN THE 1900s

The first to use a rubber femoral prosthesis was at Pierre Delbet (1861-1925) at La Ferté Gaucher, Departement Seine-et-Marne, France. He used a rubber femoral prosthesis in 1919 to replace one-half of the hip joint. In 1927, British surgeon[xii] Ernest W. Hey-Groves (1872-1944) preferred ivory, with dubious results. In 1933 he described what, in his opinion, was a preferable method to treat hip arthritis.

A better method of altering the disproportion between the ball and the socket of the joint, is to enlarge the socket by cutting away its lower and anterior margins.

However, a lot of attention for early prostheses was garnered by the Judet brothers—Robert (1901-80) and Jean (1905-95), from Paris, France. They used an acrylic prosthesis in 1948.[25] The Judet prostheses turned out to be exceptionally susceptible to wear, and failed even before the general acclaim had ceased. In the often quoted words of Francis Darwin (1848-1925):[26]

In science the credit goes to the man who convinces the world, not to the man to whom the idea first occurs.

In the 1940s, resection of the femoral head, especially for tuberculosis and infection, was popularized by Gathorne Robert Girdlestone (1881-1950) from the military orthopaedic center that was established at the Wingfield Convalescent Home in Headington, Oxford, United Kingdom.[27] It was Girdlestone who, following the precepts of the biblical references, decreed:[28,xiii]

If thine femoral head offend thee, pluck it out and cast it from thee.

The radical excision arthroplasty that bears his name is occasionally used today as last resort in failed THA, a procedure that is euphemistically called "conversion to a Girldestone."

The Judet brothers' concept[29] was refined by Frederick Röeck Thompson, (1907-83) who developed a Vitallium® prosthesis in 1950 which featured a distinctive flared collar below the head and a vertical intramedullary stem,[30] by Harold R. Böhlman (1893-1979) from Nebraska, and Austin Moore (1899-1963). Dr. Moore inserted the first such metal prosthesis at John Hopkins Hospital in 1940.[31] The procedure replaced the proximal twelve inches of a femur, destroyed by a recurrent giant cell tumor, with a custom made Vitallium® prosthesis. Böhlman and Moore refined their implant and in 1952 described a model that featured a fenestrated stem to allow bone ingrowth. Both designs were produced in collaboration with *Howmedica Inc.,* (at the time, *Austenal Laboratories*, now merged with *Stryker® Corporation*) East Rutherford, New Jersey, United States. These were the first hip arthroplasty products that were widely distributed. They eventually became legendary and are still widely used for replacement of the femoral head and neck, especially following femoral neck fractures in the elderly.

In 1938, Philip Wiles (1899-1966)[xiv] of the Middelsex Hospital in London described the first THA using precisely fitted stainless steel components which were fixed to the bone with screws and bolts.[32] However, he did not achieve satisfactory results.

Edward J. Haboush (1904-1973) of the Hospital for Special Surgery, and Kenneth McKee (1905-1991) of Norwich, England, developed prostheses in the late 1940s and experimented with dental acrylic cement for fixation. In the early 1950s, McKee, who had trained with Wiles in London, started using the Thompson prosthesis on the femoral side that articulated with a three-claw type cup that was screwed into the acetabulum. His high incidence of failure resulted from loosening of the components.[33] Another Briton, Peter Ring (b. 1922), working in parallel with the Russians, in Redhill, Surrey, started his clinical experience with cementless components with a metal-on-metal articulation in 1964. Some of his early arthroplasties provided surprisingly good results with up to 97% of implants surviving at 17 years of follow up.[34] Both the McKee-Farrar and the Ring models were abandoned in the 1970s in favor of Charnley's model. Nevertheless, these implants continued functioning extremely well and were "rediscovered" in the 1980s by Swiss and British surgeons. Today another wave of metal-on-metal bearings is on the rise.

However, the stage was set for Sir John Charnley to drive the evolution of a truly successful operation in orthopaedics, modern Total Hip Arthroplasty.

[xii] Indeed, Hey-Groves was not considered eligible to be a member of the British Orthopaedic Association because of his activities in general surgery. Regardless, he introduced several main orthopaedic procedures such as intramedullary nailing of fractures, repair of the ACL of the knee and the described *ivory* arthroplasty of the hip.

[xiii] Girdlestone's life was governed by deep religious precepts. He was also a strong advocate on social causes.

[xiv] Wiles served in both World War I and II, and achieved the grade of Brigadier Colonel in the British Army Medical Corps. Similar to Sir Robert Jones, Dr. Wiles gained most of his knowledge about traumatic injury care during his service at the battle front. Origins of modern trauma surgery can be traced to their experiences in the military. Orthopaedic surgery owns a great part its development as a medical specialty to the military conflicts that occurred during the first half of the century.

REFERENCES

1. **MacLennan WJ.** History of arthritis and bone rarefaction: evidence from paleopathology onwards. *Scot Med J*. 1999;44:18-20.
2. **Rogers J, Watt I, Dieppe P.** Arthritis in Saxon and mediaeval skeletons. *Br Med J* (Clin Res Ed). 1981;283(6307):1668-1670.
3. **Thould AK, Thould BT.** Arthritis in Roman Britain. *Br Med J* (Clin Res Ed). Dec 24-31 1983; 287(6409):1909-1911.
4. **Trinkaus E.** Pathology and the posture of the La Chapelle-aux-Saints Neandertal. *Am J Phys Anthropol*. Jun 1985;67(1):19-41.
5. **Park H.** *An account of a new method of treating diseases of the joints of the knee and elbow.* In: Pott MP, ed. London; 1782.
6. **Bilguer JH.** *De membrorum amputatione rarissime admnistranda*; 1761.
7. **Leonardo RA.** *History of Surgery.* New York: Froben Press; 1943:237.
8. **Anthony White** (Obituary). *Lancet.* 1849;1:324.
9. **Barton JR.** On the treatment of anchylosis, by the formation of artificial joints. *North Amer Med and Surg Jour.* Jan-Feb 1827;3(279):400.
10. **Stanley P.** *For Fear of Pain, British Surgery, 1790-1850.* Amsterdam: Editions Rodopi B.V.; 2003.
11. **Ollier L.** *Traité des Résections et des opérations conservatives qu'ont peut practiquere sur le sistême osseux.* Paris; 1885.
12. **Chlumsky V.** *Zentralblatt für orthopaedische Chirurgie* (Continued Centralblatt für orthopaedische Chirurgie un mechanik from 1887-1890). 1896.
13. **Rang M.** *Anthology of Orthopaedics.* Edinburgh, London, New York: Churchill Livingstone; 1966.
14. **Murphy JB.** Cheilotomy. *Surgical Clinics of Jhon B. Murphy.* Vol IV. Philadelphia: Sanders; 1915.
15. **Murphy JB.** *Trans Amer Surg Ass*. 1904;22:213.
16. **Lexer E.** Über Gelenktrasportation. *Med Klin Berlin.* 1908;4:817.
17. **Helferich H.** Über Muskeltransplantation beim Menschen. Paper presented at: Verhandlungen der deutschen Gesellschaft für orthopaedische Chirurgie, 1882.
18. **Helferich H.** Über Operationene an der Kniescheibe. *Arch f klin Chir.* 1894;48:864.
19. **Foedre.** *Zentralbl f Chir.* 1896;5.
20. **Baer WS.** Preliminary report of animal membrane in producing mobility in ankylosed joints. *Amer Jour Orth Surg*. 1909.
21. **Baer WS.** Arthroplasty with the aid of animal membrane. *Amer Jour Orth Surg.* 1918;16(1):171.
22. **Jones R, Lovett RW.** *Orthopaedic Surgery.* Baltimore: Wm. Wood; 1929.
23. **Whitman R.** The Reconstruction Operation for Arthritis Deformans of the Hip. *Joint Ann Surg*. 1924; 80:779.
24. **Smith-Petersen M.** Evolution of mould arthroplasty of the hip joint. *J Bone Joint Surg* Br. 1948;30(B(1)):59.
25. **Judet J, Judet R.** The use of an artificial femoral head for arthroplasty of the hip joint. *J Bone Joint Surg Br.* 1950;32B:166-173.
26. **Darwin, Francis.** Oxford University Press. Available at: http://www.oxfordreference.com/views/ENTRY.html?subview=Main&entry=t91.e695. Accessed 02-05, 2004.
27. **Girdlestone GR.** The classic. Acute pyogenic arthritis of the hip: an operation giving free access and effective drainage. G. R. Girdlestone, 1943. *Clin Orthop*. Nov 1982(170):3-7.
28. **Seddon HJ. Girdlestone, Gathorne Robert** (1881-1950). Oxford University Press. Available at: http://www.oxforddnb.com/view/article/33413). Accessed 1 Jul, 2004.
29. **Bhandari M, Busse JW, Jackowski D, et al.** Association between industry funding and statistically significant pro-industry findings in medical and surgical randomized trials. *Cmaj*. Mar 17 2004;170(4):477-480.
30. **Thompson FR.** Vitallium intramedullary hip prosthesis-preliminary report. *N.Y. State J Med*. 1952;52:3011-3020.
31. **Moore AT, Böhlman HR.** The classic. Metal hip joint. A case report. By Austin T. Moore and Harold R. Bohlman. 1943. *Clin Orthop.* Jul 1983(176):3-6.
32. **Wiles P.** The Surgery of the osteo-arthritic hip. *Br J surg*. 1957;45:488-497.
33. **McKee GK, Watson-Farrar J.** Replacement of arthritic hips by the McKee-Farrar prosthesis. *J Bone Joint Surg* Br. 1966;48(2):245-259.
34. **Ring PA.** Replacement of the hip joint. *Ann R Coll Surg Engl.* Jul 1971;48(6):344-355.

A HISTORICAL AND ECONOMIC PERSPECTIVE ON SIR JOHN CHARNLEY, CHAS F. THACKRAY LIMITED, AND THE EARLY ARTHOPLASTY INDUSTRY

Pablo F. Gomez, MD* and Jose A. Morcuende, MD, PhD

ABSTRACT

In the 1960s, Sir John Charnley pioneered modern total hip arthroplasty (THA) and spent the next two decades refining all aspects of the procedure, working with the commercial firm of Chas F. Thackray Limited, now a subsidiary of DePuy Orthopaedics, a Johnson and Johnson Company. We review here that relationship, in light of the complex relationships today that exist among industry, researchers, surgeons, and the public.

OVERVIEW OF TOTAL HIP ARTHROPLASTY ECONOMICS AND INDUSTRY

Osteoarthritis disables about 10% of people older than sixty, compromises the quality of life of more than twenty million Americans, and costs the United States economy more than 60 billion dollars per year.[1] There are now close to 300,000 THAs performed per year in the United States. The cost associated with each operation is approximately $13,339 in the United States,[2] and the cost of each implant has been reported to be approximately $8,017.[2] The calculated total cost of THA procedures performed in the United States during 1995 (a year in which 250,000 arthroplasties were done), was five billion dollars.[3]

Overall, THA has been found to be quite effective in terms of improvement in quality of life indices.[4] THA ranks highly among health care interventions, with a 1140/cost-per-quality-adjusted-life-year,[5] and compares favorably with the medical treatment of hypertension, coronary artery bypass graft surgery and hemodialysis for chronic renal failure.[6] Among all surgical procedures, only coronary bypass compares to THA in terms of effectiveness and improvement of life quality.

Department of Orthopaedics and Rehabilitation
University of Iowa Hospitals and Clinics
Iowa City, Iowa

***Correspondence:**
University of Iowa Hospitals and Clinics
4120D MERF
375 Newton Road
Iowa City IA 52242
e-mail address: pablo-gomez@uiowa.edu

However, one recent paper evaluating the adequacy of economic evaluations in THA literature found only two correctly performed investigations out of 68 papers in the subject.[7] The significance of this percentage is highlighted when compared to 11,078 papers about THA published in journals indexed in the National Health Library of Medicine of The United States. In addition, existing cost-effectiveness studies have generally been limited to the evaluation of hospital expenses[7] and have not included a global substantiation of THA use in today's cost-constrained health environment.

The orthopaedic industry has gone from a six billion dollar market ten years ago to seventeen billion dollars in revenues last year.[8] Five companies hold the majority of the THA market in America. These five are DePuy, Inc., a Johnson & Johnson Company,[i] Warsaw, Indiana, USA; Zimmer, Inc.,[ii] Warsaw, Indiana, USA; Stryker® Corporation,[iii] Rutherford, New Jersey, USA; Biomet Orthopedics, Inc.,[iv] Warsaw, Indiana, USA; and Smith & Nephew,[v] Inc., Memphis, Tennessee, USA.

[i] DePuy, Inc., was established in 1895 by Revra DePuy, on a promising fiber splint to replace the wooden barrel staves then used to treat fractures. They became the first commercial orthopaedic manufacturer in the world. After more than a century, the company has change ownership several times, the last owner being Johnson & Johnson Corporation. The same year that Müller give exclusivity rights to his prosthesis to DePuy, Inc., the company was acquired by the Indianapolis-based diagnostics company Bio-Dynamics, giving the veteran firm a needed economic boost.[3]

[ii] J.O. Zimmer initially began as the first DePuy sales representative. After several failed attempts to purchase DePuy Manufacturing, in 1924 Zimmer founded the company that bears his name. In *Orthopaedics Today*. Edited by Jackson, D. W., SLACK Incorporated, 2000.

[iii] Homer Stryker from Kalamazoo, Michigan, United States, was appalled by the lack of adequate instruments to operate upon his patients. He started this company in 194, which evolved into one of the leaders in the medical implant industry. In December 1998, Stryker, Inc., acquired Howmedica, Inc., from Pfizer, Inc., and doubled its size. Ibid. Edited.

[iv] Dane Miller, Niles Noblitt, Jerry Ferguson and M. Ray Harroff created Biomet, Inc., in 1977. After, a rough start, Biomet expanded and acquired several other manufacturing companies, which allowed it to consolidate and reach its position as one of the main players in today's orthopaedic industry. Ibid. Edited.

[v] Although the origins of this company can be traced back to 1851, Smith & Nephew (Pty) Ltd, Durban S.A., firmly started its orthopaedic venture in only 1931. Originally, Smith & Nephew manufactured only Plaster of Paris bandages. However, over the years it would buy Richards, Inc., and become one of the largest corporations for orthopaedic implants. Ibid. Edited.

Nevertheless, there are still reported opportunities for the orthopaedic arthroplasty industry's growth, as the trend toward expansion will continue for at least another two decades, according to investor analysts.[8]

SIR JOHN CHARNLEY (1911-1982) AND THE ROAD TO DEVELOPING MODERN TOTAL HIP ARTHROPLASTY

It was John Charnley who dominated the development of modern THA. In 1956 he noted:[10]

> *The cart has been put before the horse; the artificial joint has been made and used, and now we are trying to find out how and why it fails.*

Charnley was born in Bury, Lancashire, United Kingdom in 1911. In 1929, he entered medical school at the Victoria University of Manchester, where he qualified with MB ChB MRCS and LRCP in 1935.[vi] During that time Charnley also obtained a BSc in anatomy and physiology. At twenty-five years of age he became a Fellow of the Royal College of Surgeons at Guy's Hospital in London, the youngest physician to receive that honor. He was trained as a general surgeon, acquiring excellent wide-ranging diagnostic judgment and operative skill at the Salford Royal Hospitals, where he started January 1, 1937. During his period in Salford he worked with Mr. Garnett Wright and started to manufacture small apparatuses in Bury, England, where he had access to a lathe. After a year, he followed the advice of one of his professors in Manchester, Professor Rapper, and went to London to work in physiology with Professor RJS McDowall[vii] at King's College, London, where he was appointed as demonstrator in physiology in October 1938. However, when the opportunity presented, he returned to Manchester in 1939 and joined The Manchester Royal Infirmary as resident casualty officer. This was Charnley's first contact with orthopaedics, which at the time, even with the efforts of Sir Robert Jones and Gathorne Girdlestone, was considered a minor specialty.[viii]

Charnley's medical career was interrupted by the outbreak of war on September 3, 1939; he entered the Royal Army Medical Corps as a volunteer, beginning as a lieutenant. His postings included Northern Ireland, the Middle East and Dover, England, where he attended the wounded soldiers from the evacuation of Dunkirk, France. After this experience, he was posted as an orthopaedic officer to the Middle East as a major and officer in charge of No. 2 Orthopaedic Centre at Cairo.[12] During his stationing in Egypt, he met Dudley Buxton who was the consultant orthopaedic surgeon to the Middle East forces. Buxton opened an orthopaedic workshop at No. 4 BOW (Base Ordnance Workshop) and recommended that Captain Charnley to be in charge. Charnley made the workshop a success and designed, among other things, a walking caliper,[13,14] a modified Thomas splint,[15] and various other surgical instruments. This period was critical for Charnley, who had a febrile inventiveness. His workshop was a unit of the Royal Electrical and Mechanical Engineers, and he had the opportunity to work with skilled technicians. Following the war, he returned to England. Sir Harry Platt, later first baronet (1886-1986), acted as Charnley's and David Lloyd Griffiths' mentor.[ix] Platt was of the opinion that although Charnley had a great deal of experience with war surgery, he needed training in cold surgery.[x] Platt sent Charnley to a six-month rotation in the Robert Jones and Agnes Hunt Orthopaedic Hospital (founded as the *Shropshire* Hospital) at Gobowen, near Oswestry, in Shropshire, England.[xi]

It was in Gobowen that Charnley further became curious about the role of periosteum in bone healing. He persuaded a junior colleague to operate on him, removing a piece of cancellous bone from the upper end of his tibia, and implanting one piece above and other beneath the periosteum. Eventually, he developed osteomyelitis in his tibia and needed several surgeries for a cure.

[vi] These qualifications are the college degrees of the Britannic Medical Education curriculum. MB (Bachelor of Medicine) and ChB (Bachelor of surgery) are the primary qualifications. MRCS (Member of the Royal College of Surgeons) and LRCP (licentiate of the Royal College of Physicians) were considered secondary degrees and functioned as a safety net for medical students in case they failed in their MB degree.

[vii] Professor McDowall is best known for being a whisky connoisseur. He wrote one of the classic guides on the subject, McDowall, R. J. S.: The whiskies of Scotland. Edited, Chicago, Ivan R. Dee, 1987. He also gave numerous conferences about this beloved spirit.

[viii] Despite Sir Robert Jones's efforts during the First World War, orthopaedics was not completely established, as the general surgeons, a powerful guild, wanted to keep practicing orthopaedics, too. Manchester, however, was at the lead of the final consolidation of orthopaedics as a specialty in itself.

[ix] Lloyd Griffith was three years older than Charnley and was his senior practitioner. Although they were great friends, the relationship developed an uncomfortable tension when Lloyd Griffith was appointed as Chief of the Service at the Manchester Infirmary. Charnley's personality was not built to be the second in charge, and this, among other reasons, convinced Charnley to leave that hospital and look for an independent post in Wiles; see Waugh, W.: John Charnley: The man and the hip. Edited, London, Springer, 1990.

[x] *Cold Surgery* was the name given to elective surgical procedures in the British surgical jargon, in contrast with emergency surgeries that provided a totally different set of circumstances, and consequently, approaches.

[xi] Both names were judged too long for use, and the hospital is usually spoken of as *Oswestry*, and by the local inhabitants *The Orthopaedic.*

When Charnley finally returned to Manchester, he was appointed as observer in the orthopaedic department at the Manchester Royal Infirmary. For a few months he acted as chief assistant, and then replaced Miss Willis and became consultant orthopaedic surgeon in the department. Plat said of Charnley:[17]

> *The young men who, after such experience [training in general surgery] ultimately entered any one of the divisions—the so-called specialties—carried the hallmark of the generalist throughout their active surgical lives. This was especially true of John Charnley. His roots in the principles and units of surgery were deep and lasting.*

Charnley also had an powerful command of the English language. He describes the required qualities to be an orthopaedic surgeon, published in the *Manchester University Medical School Gazette*:[18]

> *The Orthopaedic Surgeon's faculties must be adaptable to a wide compass; the delicacy of a neurosurgeon, required in nerve and tendon surgery; the power and accuracy of a sculptor wielding the osteotome and heavy mallet; the engineering skill of a fitter, in using precision tools in bone grafting and internal fixation; the indefinable art of closed reduction in manipulating a fracture with the touch and craft of a bonesetter; pleasure in perfect dissection under a tourniquet, and satisfaction in the carnage of hindquarter amputation.*

At the suggestion of Harry Platt, and after fully committing himself to the study of hip arthritis,[xii] Charnley developed a hip center at Wrightington Hospital in Wigan, near Manchester, where he started as a visiting orthopaedic surgeon in 1949. The center, formally inaugurated in 1961, became the focus of Charnley's professional career. Charnley's early experiments on joint function were directed to understanding the friction and lubrication of animal and artificial joints.[21] He financed these studies and the materials involved, as with the lathe he bought in 1946, with royalties from his previous inventions, such as the walking calipers for soldiers he designed during the war. He considered the low friction principle to be the basis of THA design.[22] Serendipity occurred when he noted that a patient, whose left femoral head had been replaced with an acrylic Judet prosthesis, reported that "his left hip squeaked every time he leaned forward."[xiii] Charnley recognized the increased frictional resistance as the cause of this phenomenon and deduced the necessity to reduce the friction at the articular interface of the implant. Also, by applying hip biomechanical concepts that had been developed in the German school,[xiv] during the 1930s, he understood that in addition to maintaining low frictional resistance at the articular interface, it was necessary to minimize the turning force (torque) transmitted from the metal femoral head to the socket. This can only be achieved by reducing the diameter of the femoral head component. Charnley therefore introduced a 22.2 millimeter femoral head. He believed that anything smaller was associated with an unacceptably high incidence of dislocation.[22]

In 1956, he started using polytetrafluoroethylene (PTFE), which was self lubricating. Initially, he employed it as synthetic articular cartilage, lining the acetabulum with a thin shell of the plastic and covering the femoral head (which he reshaped) with a hollow cup of the same material. The chemical structure of PTFE is similar to that of Ultra High Molecular Weight Polyethylene (UHMWP) except that the pendant hydrogen atoms on the carbon backbone of the polymer molecule are replaced by fluorine (PTFE belongs to the family of fluoropolymers). As a consequence, PTFE has a density of 2.2 f/cc, higher than the 0.94 f/cc of the UHMWP. PTFE is often (and incorrectly) referred to in the orthopaedic literature as Teflon®, which is the trade name for a family of PTFE resins produced by DuPont, Wilmington, Delaware, USA. Charnley's acetabular components were fabricated from Fluon resin produced by Imperial Chemical Industries in Great Britain.[23] Subsequent universal failures after spectacular early successes persuaded him to remove the femoral head and replace it with a metal prosthesis. Unexpectedly, the PTFE defied laboratory predictions and exhibited significant wear within the first few years. Two main disadvantages of PTFE were discovered only after implantation in three hundred patients. First, the PTFE exhibited elevated wear rates *in vivo* of up to 0.5 mm per month.[24] Second the PTFE wear debris elicited an "intense foreign-body reaction." Charnley understood the basis for this from experiments on himself years

---

[xii] Charnley's contributions to orthopaedic surgery were not limited to his invention of THA. He also published landmark treatises in trauma and compression arthrodesis: Charnley, J.: The Closed Treatment of Common Fractures. Edited, Edinburgh, Livingston, 1974.; and Charnley, J.: Compression arthrodesis: Including Central Dislocation as a Principle in Hip Surgery. Edited, Edinburgh, Livingston, 1953. Paradoxically, the father of modern joint replacement initiated his academic career studying and succeeding in the fusion of joints.

[xiii] Charnley always acknowledged the importance of serendipity. One of his favorite aphorisms said "*You have got to be able to see where others do not appreciate the importance of fortuitous facts.*" *Waugh, W.: John Charnley: The man and the hip. Edited, London, Springer, 1990.*

[xiv] During the first decades of the twentieth century, German medicine provided many advances in the understanding of body physiology and disease etiology. Friedrich Pauwels (1885-1980), for instance, described the basic concepts of hip biomechanics, such as transmission of loads around the articulation, lever length and gluteus medius' role in the torque forces around the hip, and gravity center variation during limp.

ago while in Gobowen. In addition to the experiment on his own tibia, he had also experimented on himself and injected two specimens of "finely divided" PTFE into his own thigh[25] where he described in himself that the particles excited an aggressive foreign body reaction. In patients, he pointed to this inflammatory process as a possible loss of bone stock:[26]

> *After surgery, then came the dreadful weeks . . . PTFE proved unsuitable, not so much by its low resistance to wear, as by the adverse tissue reaction caused by wear debris.*

Colleagues reported that every time Charnley did a PTFE revision it was "like observing a monk pouring ashes over his own head."[27] Charnley also attempted to use glass-filled PTFE (under the trade name of Fluorosint), but despite promising *in vitro* test results the composite also performed poorly *in vivo*.

Subsequently he was offered a new material, ultra high molecular weight polyethylene, but he despised this, depressed by PTFE's failure. UHMWP produced by Hoechst (Oberhausen, Germany) was first widely adopted in the textile industry and was distributed throughout Europe during the 1950s for use in the impact bearings of mechanical looms. Despite Charnley's refusal, one of his more resilient assistants mechanically tested the material and found it to have superior wear properties to PTFE. Extensive testing demonstrated that UHMWP was a more suitable plastic for the construction of artificial joins and Charnley inserted the first UHMWP socket, labeled RCH 1000, in November 1962.[24]

RCH was Hoechst's early trade name for UHMWP. RCH designated the resin manufacturing location (RuhrCHemie AG, Oberhausen, Germany) and 1000 indicated that the polymer was UHMWP. The qualities that made this material the choice for early THA, namely its excellent wear resistance, low friction and high impact strength (relative to other polymers), have not changed substantially during the last four decades.[28] The microstructure complexities of UHMWP give rise to a range of mechanical behaviors, depending upon the processing, thermal and radiation exposure, storage and prior mechanical history of the polymer. Today, over 90% of the UHMWP used in orthopedics is produced in the form of a fine white powder, or resin, which is then consolidated through ram extrusion, slab molding, or direct compression.

Orthopaedic surgeons borrowed from the dental community a form of acrylic cement suitable for surgery, PMM. Kiaer and Jansen of Copenhagen reported attaching plastic cups to femoral heads with acrylic bone cement in 1951, and Haboush of New York used bone cement to secure a femoral prosthesis. It was Charnley, however, who noted that the points of direct contact between an implant and bone, requisite for a tight fit, were the points where the bone would absorb and leave the implant inadequately supported. His momentous publication, *Anchorage of the Femoral Head Prosthesis to the Shaft of the Femur*,[29] signaled a turning point in hip arthroplasty. He suggested that the bone cement acted as a "grout," not as glue, so that fixation was achieved by interlocking and not by adhesion. The cement was forced into all available interstices, so the weight of the body was dispersed over a large area of bone. This bold and generous use of cement improved fixation by a factor of two hundred. Heat generated during polymerization was absorbed by the metal prosthesis, which acted as a heat sink.

Charnley's surgical skills were remarkable. He had the capacity to complete an operation two to three times faster than his colleagues. His postoperative care was carried out through distinctive clinical pathways. Patients were encouraged to return for evaluation at regular intervals. Data were meticulously collected. Charnley's registrars and fellows advanced through a program of steady responsibilities, first observing, then assisting, and finally performing the operation. He would not permit the use of his prosthesis by an inexperienced surgeon, and insisted on the personalized training of his fellow colleagues.

His contributions to orthopaedic surgery were recognized both nationally and internationally with numerous awards, including the Knighthood in 1977, and a Lasker Foundation Clinical Medical Research Award, also known as the "American Nobel Prize" in 1974 (joining an elite group of luminary surgeons who had received the award—Alfred Blalock in 1954, and Michael DeBakey in 1963), and knighthood in 1977. The Lasker award committee in 1974 stated:

> *Combining his talents as an orthopaedic surgeon and biomedical engineer, Professor Charnley conducted original laboratory and clinical research . . . the introduction of the use of methyl-methacrylate as a plastic cement to firmly affix the prosthetic components to the bone . . . While the pioneering work on joint prosthetics, going back to 1908, cannot be ignored, the present advances were made possible by Professor Charnley's unique concepts. . . . it is estimated that 50,000 Charnley-type hip operations are performed annually in the United States alone . . . For his combination of engineering skill and clinical acumen, and for his development of the concept and technique of total hip joint replacement . . . this 1974 Albert Lasker Clinical Medical Research Award is given (www.laskerfoundation.org)*

CHARNLEY AND CHAS. F. THACKRAY LIMITED

Charnley was quite conscious of the importance the industry had in the development of his prosthesis:[24]

> *In Britain it is not considered good form to acknowledge commercial undertakings in too glowing terms, even though the work would not have been possible without their collaboration.*

The relationship between John Charnley and the commercial firm of Chas. F. Thackray Limited (now a subsidiary of DePuy Orthopaedics, Inc., a division of DePuy, Inc., a Johnson & Johnson Company),[xv] Leeds, England, provided grounds for the growth of Charnley's implants. The successes and frustrations of the process are recorded in the abundant correspondence maintained between Charnley and the company until Charnley's death in 1982.[xvi]

In 1902, Charles Frederick Thackray (1877-1934) and H.S. Wainwright bought from Samuel Taylor a pharmacy he had established in Leeds in 1862. They had bigger plans than just the pharmaceutical retail businesses, and in 1905 bought a sterilizer for dressings, initiating the expansion of the businesses. From 1918 on, the focus of the company was surgical equipment. Initially, they fabricated instruments for Lord Moynihan, one of Leeds' most prominent surgeons. Thackray Sr. died in 1934, and his two sons C. Noel and W.P. (Tod) took over the commercial and manufacturing operations.

The first description of orthopaedic implants by the company dates from 1947. At that time Charnley was looking for a firm to develop hip fracture devices after he quarreled with Down Brothers Ltd, of London, his previous associate. The instrument curator at the Manchester Royal Infirmary put him in contact with Thackrays, and the company worked the first gadgets of what would prove to be a fructuous partnership.[30]

With the help of Arthur Hallman,[xvii] the chief of development in Thackrays, the firm started producing low friction arthroplasty devices in 1963; they were in charge of the manufacture of the UHMWP sockets and the femoral prostheses. However, the heads were polished at Charnley's lathe in Wrightington. Importantly, the firm contributed £1 to the research fund at the hospital for every prosthesis used.[16]

Charnley was demanding with the company. He wrote at least two letters a week to them. This was not particularly pleasant for Thackray's technicians and executives because, aside from perfection in the workmanship, he also demanded low prices (from a letter dated January 26, 1968):

> *. . . your firm may have been influenced by my desire to keep the cost of the implant as low as possible. . . . I now feel that you have plenty of latitude in the price . . . compared with world prices, to cover a considerable capital investment looking towards a long-term dominance in this field.*

However both parties remained loyal to each other. The label distributed with every implant sold, summarized the philosophy behind its production:

> *The Total Hip Prosthesis contained in this package consists of a plastic socket made of High Density Polyethylene for the acetabulum and a stainless steel femoral head. Both components have been developed by Mr. J. Charnley Dsc, FRCS, at Wrightington Hospital. Chas. F. Thackray Ltd., has been granted sole rights of manufacture in return for which they contribute to the Wrightington Hip Centre Research Fund. All prostheses are manufactured under carefully controlled production techniques which meet rigid requirements as laid down by Mr. Charnley. Quality control of the product includes a final inspection of a representative proportion in the Research Laboratory at Wrightington Hospital. Mr. Charnley has authorized the issue of this statement.*
>
> *Chas. F. Thackray Ltd*

Neither Charnley nor the company patented their invention,[xviii] not that this would have prevented duplication, and numerous variations on the implant began to be produced around the world. Initially, Charnley, in his idealism, did not think there were any problems because his name was associated with those products, but the reality proved to be quite different.

Later, Maurice Müller (b. 1918), founder of AO (Arbeitsgemeinschaft für Osteosynthesefragen), would visit Wrightington on multiple occasions during the 1960s, and in 1967 he started large-scale production of his own version of a Charnley type prosthesis through Protek AG, Münsingen, Switzerland (later merged with

---

[xv] In 1990 Chas. F. Thackray Limited merged with DePuy, Inc., Warsaw, Indiana, United States, and became DePuy International Inc., still based in Leeds. After the acquisition of DePuy, Inc., by Johnson & Johnson Corporation in 2000, DePuy, Inc., and DePuy International were merged and became DePuy Orthopaedics Inc. Hereafter, I will be referring to the original company when using the term Thackray, as the actions I am describing took place during the 1960s and 1970s.

[xvi] This correspondence was reviewed in a comprehensive book about John Charnley and his life, written by Waugh, W.: John Charnley: The man and the hip. Edited, London, Springer, 1990.

[xvii] An excellent instrument maker and craftsman, Hallman was deeply appreciated by Charnley, who learned from him many of the techniques used in the manufacturing of his ideas. After Hallman's retirement, and when defective material arrived at Wrightington, he commented "I am quite sure that this defective workmanship would not have occurred in the days of Mr. Hallman." Ibid. Edited.

[xviii] Charnley never thought it would be necessary. He had a vision of medicine as a profession formed by idealistic individuals looking over interests different from monetary ones. This attitude explains his willingness to share his name and credit. Nevertheless, at that time, litigation processes were extremely slow and in many cases unproductive, in an epoch where copyright issues were still in their infancy.

Sulzer Medica) a company that distributed the implants made by Mathys and Sulzer (now Centerpulse, a Zimmer, Inc., company)[xix] Münsingen, Switzerland. Charnley became a personal friend of Müller and agreed to give his name to the implant, so the Charnley-Müller prosthesis was born. However, Müller changed some of the features of the prosthesis, making the head bigger (30mm) and increasing the available number of neck lengths, but he also modified the surgical technique. Importantly, Müller did not use osteotomy of the great trochanter for application of the femoral component, something that Charnley considered a basic feature of the surgery. Partly because of this, Müller's technique and implant became preferred by some in North America over Charnley's laborious procedure. Also, Müller was extremely entrepreneurial and ambitious. He recognized an opportunity, and instead of trying to directly sell his products in America through his company Protek AG, as Charnley and Thackrays were trying to do, in 1968 he associated with an American company, DePuy, Inc.[31] to distribute his prosthesis in the United States. DePuy, Inc., had been the pioneer of orthopaedic implant manufacturers in the United States, and was an established local industry, exceeding Thackrays in financial resources, and experience.

This situation affected Charnley, as we can infer from one of his letters to Thackrays expressing new doubts about the utilization of his name:

> *Müller attached my name to his prosthesis out of courtesy because we are close personal friends and because he was acknowledging my pioneer work. . . . The situation has now changed in so far as my operation is certainly a more extensive mechanical procedure than his . . . those manufacturers who in the past have made the Charnley-Müller with the 30 mm head should now drop my name . . . . (10-28-1970)*[16]

A typical example of the situation Charnley and Thackrays was experiencing was the 1968 visit to Wrightington of Charles Bechtol (1912-98), from The University of California at Los Angeles, Los Angeles, California, United States. He, along with three other California surgeons, were planning to start a 100-bed centre for hip surgery and had decided to choose Charnley's low friction arthroplasty as their starting model. Both Charnley and Thackrays expected the development of franchise arrangements. But the transaction was never completed. Bechtol's group never used Thackrays' prosthesis, but developed their own modification of Charnley's model with Richards Medical Company, Memphis, Tennessee, United States (acquired by Smith & Nephew Inc., in 1986).[32]

Eventually, this type of situation put enormous pressure on Thackrays as they saw business leaving them, evidenced in a letter sent to Charnley four years later:[16]

> *It is certainly not our wish to produce a larger headed model, but all the time we are being pressed by our foreign agents who seem to insist that there is as much demand for the Müller type, as for your small-headed variety, mainly required by the not-so-good surgeon, where he can use an easier operative technique.*[16]

Charnley never gave up and did not alter the design of the implant, its material nor the size of the femoral component head (22 mm). What did change, in the early 1970s, was the direction of the company. After C.N. Thackray Sr. died, his brother W.P. (Tod) took control of the company. If there was any change in the partnership with Charnley, it was positive. The new management was committed to being competitive, and by 1971 they were producing five different types of stems and four sockets, with an output of approximately nine to ten thousand hip implants a year.[30]

Low friction arthroplasty devices had been in use for at least eight years when the Food and Drug Administration of the United States asked for laboratory testing of their toxicity. Frustrated, Charnley expressed that the best proof he could provide was his own healthy patients, alive and without signs of disease several years after THA, and that it was an error to exclusively rely on laboratory tests, something that in his opinion was symptomatic of modern scientists and technicians.[xx]

The unregulated North American medical world of the 1970s provided a sharp contrast to British circumstances. Thus, different companies began trying Co-Cr and titanium alloys for the production of their implants. This put Thackrays on the spot due to Charnley's reluctance to use material other than stainless steel. However, after the financial difficulties of the company in the American market became evident, Charnley concurred with the decision to use Co-Cr alloys for a portion of the prostheses intended for the North American market. Nevertheless, he never used the new alloys in

[xix] Sulzer Medical, in an effort to recover from a highly publicized lawsuit over defects found in its artificial hips and knees, changed its name to Centerpulse AG, just before it was bought by Zimmer, Inc., on October 2, 2003.

[xx] Charnley's position in this respect was well known. He was a staunch skeptic of the AO techniques and principles for the treatment of fracture. He maintained that the best experimental model was inferior to an adequate clinical judgment. I must note, however, that this position was fundamental in Charnley, and it was developed well before any personal schism developed between him and AO's founder, Maurice Müller. Charnley's positions in this matter can be reviewed in an excellent recount of AO history by Schilich. Schilich, T.: Surgery, Science and Industry. A Revolution in Fracture Care, 1950s-1990s. Edited, 349, New York, Palgrave Macmillan, 2002.

his surgeries, and felt that implant failures attributed to stainless steel were the result of implant misuse and poor indications:

> *I have indicated from time to time that Thackrays will be overtaken in the United States by the build-up of publicity against stainless steel in favour of very sophisticated and expensive alloys . . . many of my loyal pupils can no longer risk using stainless steel . . . a number of surgeons who are on the bio-engineering bandwagon are teaching that stainless steel is no longer acceptable . . .(3-3-79)*[16]

In the end, Thackrays were unable to conquer a significant share of the American market, not even in the early 1980s when most THA sales were cemented implants. Its sales never represented more than two percent of the United States total market. Fortunately for both surgeon and company, the story was different in England, and stainless steel implants are still in use in Wrightington. By 1990, the year when Thackrays was overtaken by DePuy, Inc., and became DePuy International, Inc., it had about 50% of sales in the British market. This allowed Thackrays to maintain a continuous funding of research at Charnley's laboratory.

Charnley benefited economically from his implant and at his death had accumulated wealth of over £300,000. Nevertheless, money was never his main concern, and he commonly sacrificed personal benefits in favor of what he thought was right.

SUMMARY

The history of total hip arthroplasty is particularly interesting because it mirrors dramatic changes in priorities and values in Western culture over the last decades. Every implant design and company is a world with its own tale. The necessary involvement of the industry has provided invaluable resources for solutions to problems associated with the use of arthroplasty implants. It has also fomented a competitive environment driving the development of multiple approaches to THA design and technique. Orthopaedic surgeons need to act as checkpoints and critical evaluators of developments in the specialty, especially when economic interests are so closely related to the development of products, surgery, patient care, and medical education. Industry has become a partner in, and an important shaper of orthopaedics. Orthopaedic surgeons and corporations should be able to together turn the corner into a new century of progress.

REFERENCES

1. **Buckwalter, J. A.; Saltzman, C.; Brown, T.; and Shurman, D. J.:** The Impact of Osteoarthritis: Implications for research. *Clin Orthop,* 427 Suppl: S6-15, 2004.
2. **Antoniou, J.; Martineau, P. A.; Filion, K. B.; Haider, S.; Zukor, D. J.; Huk, O. L.; Pilote, L.; and Eisenberg, M. J.:** In-hospital cost of total hip arthroplasty in Canada and the United States. *J Bone Joint Surg Am,* 86(11): 2435-9, 2004.
3. **Healy, W. L.:** Economic considerations in total hip arthroplasty and implant standardization. *Clin Orthop,* (311): 102-8, 1995.
4. **Ethgen, O.; Bruyere, O.; Richy, F.; Dardennes, C.; and Reginster, J. Y.:** Health-related quality of life in total hip and total knee arthroplasty. A qualitative and systematic review of the literature. *J Bone Joint Surg Am,* 86-A(5): 963-74, 2004.
5. **Maynard, A.:** Developing the health care market. *Econ, J.,* 101: 1277, 1991.
6. **O'Shea, K.; Bale, E.; and Murray, P.:** Cost analysis of primary total hip replacement. *Ir Med J,* 95(6): 177-80, 2002.
7. **Saleh, K. J.; Gafni, A.; Saleh, L.; Gross, A. E.; Schatzker, J.; and Tile, M.:** Economic evaluations in the hip arthroplasty literature: lessons to be learned. *J Arthroplasty,* 14(5): 527-32, 1999.
8. The Business & Medicine Report. Edited, 2004.
9. The Century in Orthopedics. A Year by Year Review of the Advance, Events and Accomplishments of the Specialty. In *Orthopaedics Today*. Edited by Jackson, D. W., SLACK Incorporated., 2000.
10. **Charnley, J.:** Arthroplasty of the hip. Discussion. South African Orthopaedic Association (1955). *J Bone Joint Surg Br,* 38: 592, 1956.
11. **McDowall, R. J. S.:** *The whiskies of Scotland.* Edited, Chicago, Ivan R. Dee, 1987.
12. **Duthie, R. B.:** Charnley, Sir John (1911-1982). In *Oxford Dictionary of National Biography*. Edited, Oxford, University Press, 2004.
13. **Charnley, J.:** The Walking Caliper. *Lancet,* I: 467-7, 1947.
14. **Charnley, J.:** Adjustable Army Calliper. *J bone Joint Surg Br,* 27: 348, 1945.
15. **Charnley, J.:** Fractures of the femoral shaft. *Lancet,* I: 235-9, 1944.
16. **Waugh, W.:** *John Charnley: The man and the hip.* Edited, London, Springer, 1990.
17. **Platt, H.:** John Charnley. In *Some Manchester Doctors*. Edited by Elwwod, W. J. T., A.F., Manchester, Manchester University Press, 1985.

18. **Charnley, J.:** Biomechanical orthopaedic engineering ung. *Manchester Univ Med School Gazette*: 97-105, 1949.
19. **Charnley, J.:** *The Closed Treatment of Common Fractures.* Edited, Edinburgh, Livingston, 1974.
20. **Charnley, J.:** *Compression arthrodesis: Including Central Dislocation as a Principle in Hip Surgery.* Edited, Edinburgh, Livingston, 1953.
21. **Charnley, J.:** The Lubrication of animal joints. In *Symposium on Biomechanics*, pp. 12-22. Edited, 12-22, Institution of Mechanical Engineers, 1959.
22. **Charnley, J.:** Arthroplasty of the hip: A new operation. *Lancet,* I: 1129-1132, 1961.
23. **Li, S., and Burstein, A. H.:** Ultra-high molecular weight polyethylene. The material and its use in total joint implants. *J Bone Joint Surg Am,* 76(7): 1080-90, 1994.
24. **Charnley, J.:** *Low Friction Arthroplasty of the Hip: Theory and Practice.* Edited, Berlin, Springer, 1979.
25. **Charnley, J.:** Tissue reaction to the polytetrafluoroethylene. *Lancet,* II: 1379, 1963.
26. **Charnley, J.:** The development of the centre for hip surgery at Wrightington hospital (written in 1982). In *Wrightington Hospital, the story of the first 50 years*. Edited by Swinburn, W. R., Wrightington, Wrightington Hospital, 1983.
27. **Hardinge, K.:** *Hip Replacement—The facts.* Edited by Hospital, W., Oxford, Oxford University Press, 1983.
28. Polyethylene resins. In *Modern Plastics Encyclopaedia for 1962*, pp. 251-268. Edited, 251-268, New York, McGraw-Hill, 1961.
29. **Charnley, J.:** Anchorage of the femoral head prosthesis to the shaft of the femur. *J Bone Joint Surg Br,* 42-B: 28-30, 1960.
30. **Anderson, J.:** Joined at the Hip: John Charnley, Thackray and the artificial hip joint. In *Medical History and Material Culture*. Edited by Centre for Heritge Research, U. o. L., Leeds, The Thackray Medical Museum, 2002.
31. About Us History, DePuy a Johnson & Johnson company. Edited, 2004.
32. *Remembering . . . Charles.* Bechtol, M.D. Edited by foundation, J. I. S. R., 2004.
33. **Schilich, T.:** *Surgery, Science and Industry. A Revolution in Fracture Care, 1950s-1990s.* Edited, 349, New York, Palgrave Macmillan, 2002.

TOTAL HIP ARTHROPLASTY AND REHABILITATION IN AMBULATORY LOWER EXTREMITY AMPUTEES—A CASE SERIES

Edward J. Nejat[1]; Amy Meyer, PT[2]; Pamela M. Sánchez[3]; Sarah H. Schaefer[3]; Geoffrey H. Westrich, MD[4]

INTRODUCTION

A high incidence of osteoarthritis in the hip and knee joints has been reported in lower limb below-knee amputees.[1] However, there is limited literature about the outcomes and role of total hip arthroplasty (THA) as a surgical option for amputee patients. Salai et al.[2] reported on five below-knee amputee patients who were treated with total hip arthroplasty for displaced subcapital femoral head fractures. Their results suggest that total hip arthroplasty in below-knee amputee patients may prevent functional deterioration and preserve functional capacity.[2]

Nevertheless, patients with lower extremity amputations in need of contralateral or ipsilateral total hip arthroplasty present with additional challenges with regard to their acute postoperative care, and need a modified rehabilitation program. The purpose of this brief case series is to describe four patients with lower extremity amputations who subsequently underwent total hip arthroplasty. We also review the rehabilitation challenges that these patients present.

MATERIALS AND METHODS

To identify patients who met the criteria for our study, a cross-reference of diagnosis and procedure codes was used against the hospital's patient database. Patients with lower extremity amputations who underwent total hip arthroplasty were identified. Retrospective chart reviews were performed on four different patients who had lower extremity amputations and who later underwent total hip arthroplasty at our institution. Procedures were performed between 1998 and 2001 on patients ranging in age from 39 to 79 years of age.

Two patients had ipsilateral total hip arthroplasties with respect to the amputated limb (in one below-knee amputee and one Symes-level amputee), one had a contralateral total hip arthroplasty, and one patient with bilateral below-knee amputations had right total hip arthroplasty. Two patients underwent total hip arthroplasty for osteoarthritis, one for post-traumatic osteoarthritis after acetabular fracture, and one patient required THA for avascular necrosis. The patient with avascular necrosis had a previous Symes-level amputation, but the other three patients had conventional below-knee amputations. A different surgeon using a posterior approach with regional anesthesia performed each total hip arthroplasty.

Retrospective chart analysis included review of patient demographics, preoperative diagnosis, type and time of amputation, type of prosthesis, radiological examination, length of hospital stay, postoperative physical therapy notes and milestones, and follow-up office visit notes. Achievement of physical therapy milestones was compared against the average for all other patients who underwent total hip arthroplasty surgery during the same time period (1998-2001).

CASE STUDIES

Patient One

The first patient was a 66-year-old woman who had amelia of both fibulae and the lesser toes resulting in a series of operations and eventually, at the age of 20, bilateral below-knee amputations. Forty-six years later, she developed severe osteoarthritis of the right hip and failed conservative treatment. She ultimately underwent a successful right hybrid total hip arthroplasty in 2000. Prior to surgery, she ambulated with a cane two to three blocks, and negotiated stairs in a non-reciprocating manner. On postoperative day number one, she transferred from a supine to a sitting position. On postoperative day number two, she required assistance with her below-knee prostheses, and then was able to ambulate with a walker. On postoperative day number five, she progressed from the walker to Canadian crutches and on postoperative day number six she was discharged to a rehabilitation facility. Seven months postoperatively, she returned to work 40 hours per week. She used a cane only in snowy and icy weather.

Hospital for Special Surgery—Weill Medical College of Cornell University, New York, NY
[1] Medical Student, Weill Medical College of Cornell University
[2] Physical Therapist, Hospital for Special Surgery
[3] Research Assistant, Hospital for Special Surgery
[4] Associate Professor of Orthopedic Surgery, Hospital for Special Surgery and Weill Medical College of Cornell University

Correspondence:
Geoffrey H. Westrich, MD
Hospital for Special Surgery
535 East 70th Street
New York, NY 10021
Tel: (212) 606-1510
Fax: (212) 639-9266
Email: westrichg@hss.edu

TABLE 1
Summary of Patient Demographics and Physical Therapy Milestones Compared to Hospital Average

PATIENT NUMBER	1	2	3*	4	Non-amputee THA average
Sex	F	M	F	F	
Below Knee Amputee	Bilateral	Left	Left	Right	
Total Hip Arthroplasty	Right	Right	Left	Right	
Time period between Below Knee Amputee & Total Hip Arthroplasty (in years)	46	22	10	0.058	
Total Hip Arthroplasty indication	Osteoarthritis	Osteoarthritis	Avascular necrosis	Failed total hip arthroplasty	
Transfer assisted: postoperative day	1	1	1	Did not	1.4
Ambulation with walker: postoperative day	2	1	1	Achieve	1.2
Ambulation with cane / crutches: postoperative day	5	4	4	PT	4.2 / 4.5
Reciprocation of stairs: postoperative day	-	5	4	goals	4.9
Length of Stay (in days)	6	6	5	15	5.5

*Data after third revision

Patient Two

The second patient was a 79-year-old man who underwent a left below-knee amputation in 1979 for severe peripheral vascular disease. Two years later, he underwent a total hip arthroplasty of the contralateral limb due to debilitating osteoarthritis. Prior to surgery the patient was able to ambulate three to four blocks with a cane. He negotiated stairs in a non-reciprocating manner. On postoperative day number one, he was able to place his contralateral below-knee prosthesis with assistance. He transferred with moderate assistance and was able to ambulate with a walker. By postoperative day number four, he transferred without assistance and progressed from ambulation with a walker to ambulation with two canes. On postoperative day number five, he was able to ascend and descend stairs in a non-reciprocating manner. He was discharged home the next day, on postoperative day number six. His three-month follow-up visit indicated that he was doing well clinically and radiographically and was ambulating with a cane.

Patient Three

The third patient had a congenital dysgenesis of the left femur creating an inequality in leg length. Subsequently, in 1967 she underwent a left Symes amputation. Ten years later, in 1977, she underwent a left total hip arthroplasty for avascular necrosis. A revision was performed in 1983 secondary to a loose acetabular component. In 1993, the patient underwent a second revision, this time for the femoral component. In 1998, the patient underwent a third revision for a failed femoral component. Prior to admission for the latest revision the patient was able to ambulate half a block with a cane and was able to reciprocate stairs. On postoperative day number one the patient required minimal assistance for transfers and was able to ambulate with a walker after donning her prosthesis. On postoperative days number two and three the patient increased her ambulation with the walker. On postoperative day number four the patient progressed to axillary crutches and was able to negotiate stairs in a non-reciprocating fashion. On postoperative day number five the patient was discharged home with crutches. At her last follow-up, she did not need ambulatory aids.

Patient Four

The fourth patient was a 39-year-old woman with a past medical history significant for congestive heart failure, cerebrovascular accidents, seizures and end-stage renal disease secondary to hypertension. In June of 2000 she had a seizure while having dialysis. She fell and sustained a right acetabular fracture treated nonoperatively. A right heel ulcer with osteomyeltis developed, for which she subsequently underwent below-knee amputation. The patient eventually developed post-traumatic arthritis status post acetabular fracture, and in October 2001 underwent right total hip arthroplasty as treatment for the acetabular fracture. Prior to

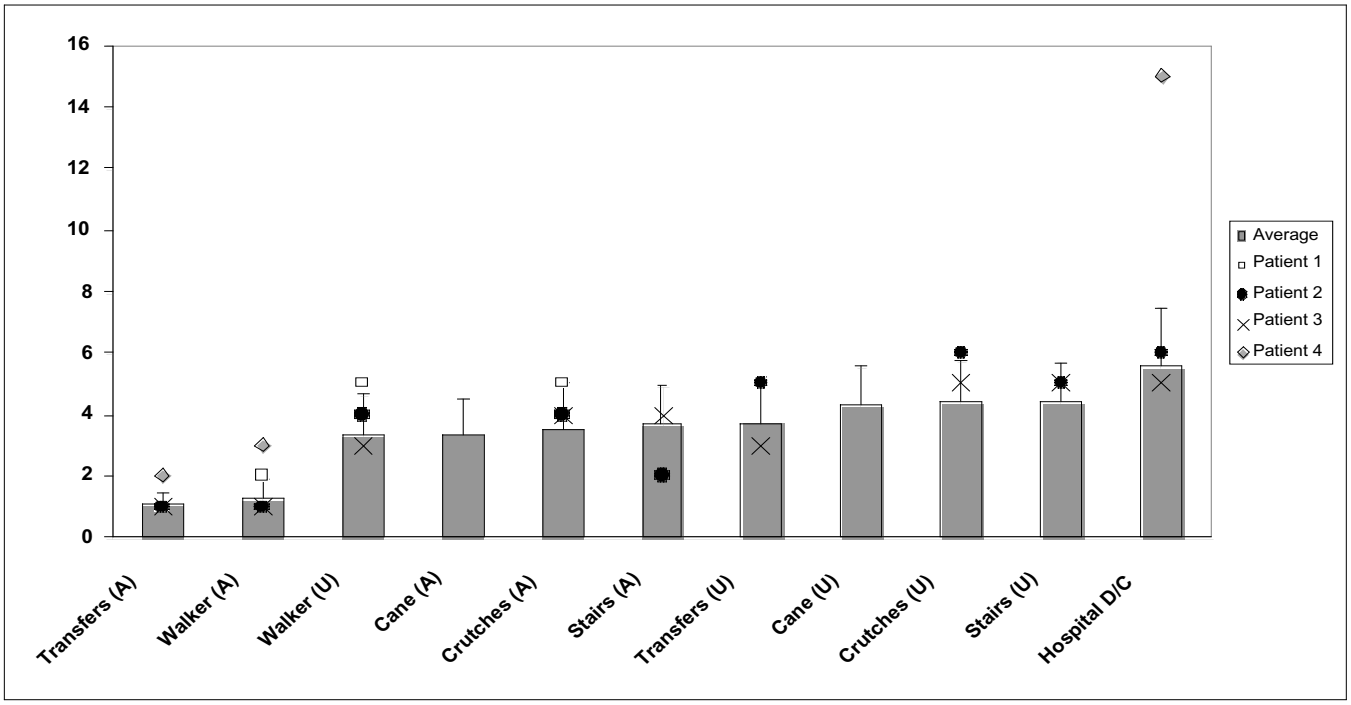

Figure 1. Achievement of physical therapy milestones (i.e. assisted/unassisted transfer into and out of bed, assisted/unassisted ambulation with the appropriate assistive device and the ability to negotiate stairs in a non-reciprocating manner) and total length of stay of patients one through four, compared to the average for total hip replacement patients who underwent surgery from 1998-2001.

THA, the patient was debilitated and wheelchair bound. Since the below-knee amputation was performed only three weeks prior to the total hip arthroplasty, the patient had not yet been fitted for a prosthesis. Although she received physical therapy daily, she was unable to ambulate mainly due to weakness in her left uninvolved leg. On postoperative day three, she was able to stand with the walker and by discharge she stood for a maximum of three minutes. She did not achieve physical therapy goals and was discharged to a rehabilitation facility on postoperative day 15. Three months postoperatively, she was ambulating well with a walker and prosthesis.

The number of days to achieving physical therapy milestones and total length of stay were examined and compared to our institution's physical therapy database. This information is summarized in Table 1 and individually presented in Figure 1.

DISCUSSION

Physical therapy following total hip arthroplasty in patients who have an ipsilateral or contralateral amputation is important to obtain optimal physical function. Patients one, two, and three recovered well compared to non-amputee patients. The patients were ambulating independently with a cane prior to surgery and this may be correlated with their outcomes. Patient one dangled at the bedside and was able to ambulate with a walker on postoperative day number two, while patients two and three were able to ambulate with a walker on postoperative day number one. Our institution's figures for non-amputee total hip arthroplasty patients from 1998 to 2001 show an average of 1.2 (n=1172) days before ambulation with a walker. Patient one was discharged on postoperative day number six to a rehabilitation facility. Patients two and three were discharged home on postoperative day number five. The average length of stay for a total hip arthroplasty patient at our institution is 5.5 days.

Patient four, unlike the others, was not ambulatory at the time of admission. Her situation was unique in that her below-knee amputation was only three weeks prior to her total hip arthroplasty. She was only able to stand with a walker while in our hospital. Her length of stay was 15 days, approximately ten days greater than our institutional average (see Table 1).

An aggressive inpatient physical therapy regimen has been demonstrated as effective in lower limb amputees.

In particular, Turney et al[4] demonstrated that below-knee amputees generally gain better mobility than above knee amputees (p=0.002). In an effort to establish guidelines for suitable methods of treatment and expected functional results, Bowker et al[5] evaluated a series of patients with fractures of the lower limbs, who had prior amputations. The authors concluded that the most important surgical goal in treating this group of patients with either below- or above-knee amputations, was to restore the normal angle between the neck and shaft of the femur. This objective further restores the hip abductor function. In addition, Bowker et al found that after the fracture healed, 97.0 percent of below-knee amputees resumed the use of their prosthesis, however the proportion of patients requiring the use of supplemental aids, i.e. cane or crutches, increased from 26 to 35 percent.[5] Total hip arthroplasty to treat subcapital fractures of the femoral head has been demonstrated to be effective in below-knee amputees. Salai et al[2] found that total hip arthroplasty in these patients may prevent functional deterioration and preserve functional capacity.

In amputees undergoing THA, there are important factors to consider. In one of the four patients, the total hip arthroplasty was contralateral to the below-knee amputation. Therefore, the role of the contralateral limb in below-knee amputee gait must be considered. Hurley and McKenney et al[6] found that below-knee amputation patients demonstrate a lesser degree of limb symmetry during gait than non-amputees. In studies with below-knee amputations, J. Breakey[7] found that the stance phase in gait was longer in the normal limb and shorter in the amputated limb. Perron et al[8] found that following total hip arthroplasty, patients had a four-percent decrease in single-limb stance on the surgical side. A possible rationale for why the second patient required more external support (two canes) may be due to decreased single-limb support time bilaterally. In the two patients whose surgeries were ipsilateral, the combination of the below-knee amputation and total hip arthroplasty on the same side may decrease single limb support time even further and explain why the third patient required crutches rather than a cane.

Our study has demonstrated that lower extremity amputee patients present a challenging acute postoperative rehabilitation course status post total hip arthroplasty relative to non-amputee patients. The first six weeks after surgery are critical with respect to enforcing the standard hip precautions. These precautions are important in order to avoid dislocation and are especially critical for amputees while placing and removing their prostheses.

REFERENCES

1. **Burke, M. J., Roman, V., and Wright, V.:** Bone and joint changes in lower limb amputees. *Annals Rheum Dis*, 37:252-254, 1978.
2. **Salai, M., Amit, Y., Chechik, A., Blankstein, A., and Dudkiewicz, I.:** Total hip arthroplasty in patients with below-knee amputations. *J Arthroplast*,15:999-1002, 2000.
3. **Prickett, N. M. and Scanlon, C. J.:** Total joint replacement in extremities with below-knee amputations. *Phys Ther*, 56:925-927, 1976.
4. **Turney, B. W., Kent, S. J., Walker, R. T., and Loftus, I. M.:** Amputations: no longer the end of the road. *J Royal Col Surg Ed*,. 46:271-273, 2001.
5. **Bowker, J. H., Rills, B. M., Ledbetter, C. A., Hunter, G. A., and Holliday, P.:** Fractures in lower limbs with prior amputation. A study of ninety cases. *J Bone Joint Surg Am*, 63:915-920, 1981.
6. **Hurley, G. R., McKenney, R., Robinson, M., Zadravec, M., and Pierrynowski, M. R.:** The role of the contralateral limb in below-knee amputee gait. *Pros Orthot Int*, 14:33-42, 1990.
7. **Breakey, J.:** Gait of unilateral below-knee amputees. *J Pros Orthot*, 30:17-24, 1976.
8. **Perron, M., Malouin, F., Moffet, H., and McFadyen, B. J.:** Three-dimensional gait analysis in women with a total hip arthroplasty. *Clin Biomech*, 15:504-515, 2000.

CASE REPORT: SALMONELLA INFECTION FOLLOWING TOTAL HIP ARTHROPLASTY

Paul Y. Chong[1]; Scott M. Sporer, M.D., M.S.[2]

ABSTRACT

A case of a total hip arthroplasty infection with *Staphylococcus aureus*, co-infected with *Salmonella choleraesuis* was treated with two-stage exchange and administration of vancomycin and ciprofloxacin. No signs of re-infection have appeared fourteen months after surgery. Cases of salmonella infection of hip prostheses are quite rare, with only a handful of reports in the literature.

CASE REPORT

A 79-year-old pig farmer presented to our hospital with chronic hip wound purulent drainage eight months following a right total hip arthroplasty. He had a total hip arthroplasty performed for degenerative joint disease at an outside hospital. He otherwise was in good health, with mild chronic obstructive pulmonary disease and benign prostatic hyperplasia. Roughly three months after the index operation, he underwent superficial irrigation and debridement for drainage. The patient had initially been treated with a prolonged course of intravenous vancomycin, but the wound drainage persisted after discontinuation of the antibiotics.

Aspirations of his hip demonstrated heavy growth of gram-positive cocci in clusters consistent with *Staphylococcus aureus*, as well as gram-negative rods later identified as *Salmonella choleraesuis*. A two-stage exchange arthroplasty was recommended to attempt eradication of this chronic infection. A resection arthroplasty using an extended trochanteric osteotomy was performed to remove both the loose cemented stem and cementless cup. This included the excision of two areas of draining sinus tracts that extended into the hip joint containing a moderate amount of intra-articular purulence. Intra-operative hip joint fluid demonstrated a cell count of 109,000 cells/cm^2 with multiple positive frozen cultures. Gram stain was negative. Cultures demonstrated light growth of presumptive *Salmonella* species on aerobic culture, later determined to be *Salmonella choleraesuis*. Both the acetabular and femoral components, which were grossly loose, were removed, followed by placement of a Prostalac® cement spacer. The spacer contained 1 gm tobramycin and 3 gm vancomycin with Surgical Simplex P bone cement (Howmedica-Osteonics, Allendale, New Jersey).

Infectious disease was consulted, and the patient was placed on vancomycin and ciprofloxacin during his hospital stay. Stool culture post-resection failed to demonstrate *Salmonella*. By time of discharge one week later, his wound was sealed and dry. He was discharged on intravenous vancomycin and oral ciprofloxacin, which he remained on for six weeks.

Eight weeks after resection arthroplasty, his laboratory values had normalized, included an erythrocyte sedimentation rate of 28 mm/hr, white blood cell count of 5.3 k/cm^2, and C-reactive protein of 0.4 mg/dl. The patient underwent second-stage re-implantation arthroplasty with cementless components. At the time of re-reimplantation, intra-operative fluid demonstrated a white cell count of 625 cells/cm^2, and frozen sections from three separate locations were all without acute inflammation. Cultures were also taken, which later revealed no growth. After re-implantation surgery, the patient was discharged five days after surgery with scant serous wound drainage, which resolved.

At latest follow-up sixteen months after resection (fourteen months after re-implantation), the osteotomy site was completely healed, and components were in proper position with radiographic signs of osseous integration.

DISCUSSION

Infection rates following total hip replacement have been reported between 0.5% to 2%, with *Staphylococcus aureus* being the most common agent. Cases of *Salmonella* infection of hip prostheses are quite rare, with only a handful of reports in the literature.[1-6]

[1]Vanderbilt University Medical Center, Nashville, TN

[2]Rush Presbyterian St-Luke Medical Center, Chicago, IL
Central DuPage Hospital, Winfield, IL

Correspondence:
Scott M. Sporer, M.D., M.S.
Midwest Orthopedics
Central DuPage Hospital
25 N. Winfield Road
Winfield, IL 60190
P 630-682-5653
F 630-682-8946
Email: ssporer@hotmail.com

By mid-2002, only 12 case reports of *Salmonella* complication of total hip arthroplasty had been reported in the English-language literature. Almost all of the 12 cases did not involve patients with an underlying illness, such as systemic lupus erythematosis (SLE) or malnutrition, which have typically been associated with native joint *Salmonellosis.* With the exception of re-occurrences in two cases, the *Salmonella* infections were cured. The authors pointed to the use of prompt debridement, early component replacement and appropriate antibiotics in the cure of *Salmonella* prosthetic joint infection.[2]

Two-stage exchange is a standard procedure for treatment of infection of total joint arthroplasty. In one study of 50 patients, two-stage exchange for infected total hip arthroplasty to cementless components, with minimum three-week placement of antibiotic-impregnated spacer with beads, and three months of follow-up antibiotics kept the re-infection rate at 8% at 5.8 years mean follow-up.[7]

The present case demonstrates the use of two-stage exchange in the treatment of total hip arthroplasty complicated by *Salmonella* infection. In the present case, the implants used in the index procedure had already become grossly loose at the time of resection, presumably from the chronic infectious process. A routine six-week course of antibiotics appeared to be sufficient.

In this patient, a potential source of infection was occupational, with his exposure to farm animals. A bovine-specific *Salmonella* was described in a man who tended infected calves up until the time of his hip replacement operation.[4] The present case involved a co-infection of both a *Staphylococcus* and *Salmonella* species. Either a direct inoculation to the hip or a hematogenous route could have been involved in either case. It is unclear whether one organism or both were initially involved in the septic joint.

This patient requires continued follow-up for any new signs of infection. At fourteen months after re-implantation, the clinical and radiographic signs are good so far.

Prevention of infection in the first place is the most important consideration in the discussion of infection management. It appears that the use of contemporary aseptic methods such as perioperative antibiotics, laminar air-flow operating rooms, and body-exhaust systems, can help keep incidence of infection very low, even for complex total hip operations.[8] While keeping peri-operative sources of infection at bay is important, the source of infection in the present patient was more likely related to his occupational environment.

REFERENCES

1. **Chen CM, Lu TC, Lo WH, et al:** *Salmonella* infection in total hip replacement—report of successful reimplantation and review of the literature. *Zhonghua Yi Xue Za Zhi* (Taipei). 1999 Jul;62(7):472-6.
2. **Day LJ, Qayyum QJ, Kauffman CA:** *Salmonella* prosthetic joint septic arthritis. *Clin Microbiol Infect.* 2002 Jul;8(7):427-30.
3. **Fu TS, Ueng SW:** Two-staged revision total hip arthroplasty due to *Salmonella* infection: case report. *Chang Gung Med J.* 2001 Mar;24(3):202-7.
4. **Kristensen W, Solund K:** Total hip prosthesis infected with *Salmonella dublin*. *Ugeskr Laeger.* 1990 Feb 26;152(9):609-10.
5. **Samra Y, Shaked Y, Maier MK:** Nontyphoid *salmonellosis* in patients with total hip replacement: report of four cases and review of the literature. *Rev Infect Dis.* 1986 Nov-Dec;8(6):978-83.
6. **Widmer AF, Colombo VE, Gachter A, et al:** *Salmonella* infection in total hip replacement: tests to predict the outcome of antimicrobial therapy. *Scand J Infect Dis.* 1990;22(5):611-8.
7. **Haddad FS, Muirhead-Allwood SK, Manktelow AR, et al:** Two-stage uncemented revision hip arthroplasty for infection. *J Bone Joint Surg* Br. 2000 Jul;82(5):689-94.
8. **Schutzer SF, Harris WH:** Deep-wound infection after total hip replacement under contemporary aseptic conditions. *J Bone Joint Surg* Am. 1988 Jun;70(5):724-7.

EPIDEMIOLOGY OF ANKLE ARTHRITIS: REPORT OF A CONSECUTIVE SERIES OF 639 PATIENTS FROM A TERTIARY ORTHOPAEDIC CENTER

Charles L. Saltzman, M.D.; Michael L. Salamon, M.D.; G. Michael Blanchard, M.D.; Thomas Huff, M.D.; Andrea Hayes; Joseph A. Buckwalter, M.D.; Annunziato Amendola, MD

ABSTRACT

The purpose of our study was to identify the cause of symptomatic ankle arthritis in a consecutive series of patients presenting in a tertiary care setting. Between 1991 and 2004, 639 patients with Kellgren grade 3 or 4 ankle arthritis presented to the University of Iowa Orthopaedic Foot and Ankle Surgery service. The cause of the arthritis was determined based on medical history, physical examination, and imaging studies. To get a sense of the relative prevalence of the etiologies of lower extremity arthritis in our setting, we evaluated the cause of arthritis of all new patients presenting to the University of Iowa Orthopaedic Department from 1999-2004 with arthritis of the ankle, to those with arthritis of the hip or knee during one year. Of the 639 arthritic ankles, 445 (70%) were post-traumatic, 76 (12%) were rheumatoid disease and 46 (7%) were idiopathic (primary osteoarthritis). The post-traumatic ankle arthritis patients were most commonly associated with past rotational ankle fractures. The majority of ankle arthritis is associated with previous trauma, whereas the primary cause of knee or hip arthritis is idiopathic. Unique strategies to prevent or treat post-traumatic ankle arthritis are needed.

INTRODUCTION

Primary or idiopathic osteoarthritis (OA) is the most common joint disease, and is a significant source of pain and disability for middle-aged and elderly people throughout the world. It occurs rarely in people under the age of 40. Secondary causes of joint degeneration include dysplasia, inflammatory conditions, traumatic injury, infection, hemophilia and vascular or neurological insults.[1] Primary osteoarthritis is known to occur commonly in the hand, spine, hip and knee. However, it occurs much less frequently in the elbow, shoulder, wrist and ankle.[2] The reasons for this are not completely understood, but differing anatomical, biomechanical, and biological factors likely contribute to this variability. Primary osteoarthritis is the most common indication for total hip and total knee arthroplasty, whereas post-traumatic arthritis is the most common indication for ankle arthrodesis.

Review of published reports of the treatment of ankle osteoarthritis indicate that primary osteoarthritis in the ankle is rare, and that secondary osteoarthritis that follows rotational ankle fractures or recurrent ligamentous instability is much more common.[3,4,5,6] Some patients report sustaining no more than a single major ankle sprain, suggesting an undiagnosed chondral injury as the inciting event. The purpose of our study was to identify the cause of symptomatic ankle arthritis in a consecutive series of patients presenting in a tertiary care setting, and to compare the cause of ankle arthritis to that of the hip and knee. The purpose of this subset of data is to report a "snapshot" of a group of patients presenting to the University of Iowa Orthopaedic Department with lower extremity osteoarthritis and to compare the differences between these groups.

METHODS AND RESULTS

Between 1991 and 2004, 639 patients with Kellgren grade 3 or 4 ankle arthritis presented to the University of Iowa Orthopaedic Foot and Ankle Surgery service (Tables 1, 2, and 3). The cause of the arthritis was determined based on medical history, physical examination and imaging studies. Only ankles with Kellgren/Lawrence grade 3 or 4 changes were included. The cause of ankle arthritis was determined whenever possible. If no cause could be elucidated, then by a process of elimination the case was classified as primary osteoarthritis.

In addition, during a one-year period (April 1998-March 1999) we collected data on patients who pre-

Department of Orthopaedics and Rehabilitation
The University of Iowa

Correspondence:
Charles L. Saltzman, M.D., Professor
Department of Orthopaedics and Rehabilitation
Department of Biomedical Engineering
The University of Iowa
200 Hawkins Drive
JPP-01017
Iowa City, IA 52242
Email: charles-saltzman@uiowa.edu

TABLE 1
All ankle arthritis patients presenting to the University of Iowa Orthopaedics Department

Type	No.	% of total	Avg. Age	SD Age
Septic	10	1.6	56.7	16.94
Rheumatoid	76	11.9	58.7	12.6
Osteonecrosis	14	2.2	49.5	14.91
Neuropathic	31	4.9	53.8	13.95
Hemophiliac	12	1.9	24.3	16.86
Gout	5	0.8	46.0	18.1
Primary	46	7.2	67.2	12.4
Post-traumatic	445	70.0	51.5	14.4
	639			

September 1991 to August 2004

TABLE 2
Subset with post-traumatic ankle arthritis

Causes	No.	% of total	Avg. Age	SD Age
Tibial and fibular shaft	18	4.0	54.9	11.5
Tibia fracture	38	8.5	49	16.3
Plafond fracture	40	9.0	43.1	11.5
Rotational ankle	164	37.0	50.8	14.2
Talar fracture	38	8.3	46.9	14.5
Osteochondritis dissecans	21	4.7	44.6	12.62
Recurrent ankle instability	65	14.6	57.7	13.29
Single sprain with cont'd pain	61	13.7	50	16.17
	445			

TABLE 3
Subset with primary ankle arthritis

Causes	No.	% total
Congenital foot deformity	7	15
Planovalgus foot	6	13
Cavovarus foot	10	22
No foot deformity	23	50

(N=46)

TABLE 4
Demographics of lower extremity arthritis in the hip, knee and ankle

	Hips	Knees	Ankles
Total	167	424	48
Primary	109 (65%)	347 (82%)	9 (19%)
Post-traumatic	14 (8%)	53 (12.5%)	26 (54%)
Rheumatoid	3 (2%)	15 (3.5%)	7 (14.6%)
Neuropathic	0	3 (0.7%)	3 (6%)
Dysplastic	18 (11%)	2 (0.5%)	3 (6%)
Avascular Necrosis	18 (11%)	2 (0.5%)	0
Other	5 (3%)	2 (0.5%)	1 (2%)

(N=639 total)
April 1998 to March 1999

sented to all of the University of Iowa Orthopaedic clinics with symptomatic Kellgren grade 3 or 4 arthritis of the hip, knee or ankle (Table 4).

DISCUSSION

The majority of clinical and basic science research has focused on hip and knee osteoarthritis. The ankle joint has received relatively less attention. Ankle osteoarthritis has characteristics that distinguish it from osteoarthritis occurring in other joints, resulting in differences in prevalence, clinical presentation, natural history and possibly even response to treatment. This study is one of the first to characterize the epidemiology of ankle arthritis.

The ankle joint possesses unique epidemiological, anatomic, biomechanical and biologic characteristics when compared to other joints in the lower extremity. While primary hip and knee arthritis is common, ankle arthritis has been characterized as usually secondary, and the result of another initiating event or underlying pathologic process.[7] These differences are supported by our data.

Ankle articular cartilage is different from that of the hip and knee in several ways. The anatomy and motion characteristics of the ankle joint are unique and the ankle has a much smaller articular surface area than the hip or knee. Ankle articular cartilage is thinner (1-2mm) and better preserves its tensile stiffness and fracture stress with aging than hip articular cartilage. There are also metabolic differences between ankle and knee articular cartilage that may also help explain the relative rarity of primary ankle osteoarthritis. All of these differences may protect the ankle from developing primary osteoarthritis.[8]

Studying the prevalence of osteoarthritis is fraught with limitations and biases. Our data is limited in that our sample was gathered from patients presenting to a tertiary orthopaedic department with complaints of ankle pain, thus limiting the generalizability of our data. This approach has been used by others working in tertiary rheumatology clinics by Cushnaghan and Dieppe,[2] and allows a sample of convenience.

Despite these limitations, our data helps define the etiology of ankle arthritis in the largest consecutive, unselected series of patients published. The prevalence

of primary osteoarthritis in our sample was only 7.2%, and half of these patients had substantial malaligment of the hindfoot, predisposing the ankle joint to eccentric wear and degenerative disease. The data further suggests that the proper alignment and function of the subtalar joint remains crucial in the proper long-term durability of the human ankle.

Previous reports suggest that trauma is the most common cause of ankle osteoarthritis; this is supported by our data (70%). Among the prevalent sub-causes are recurrent ankle sprains and a single ankle sprain with continued pain. The former suggests the absolutely critical importance of spatially well-distributed loading of cartilage, whereas the latter likely represents unrecognized full-thickness cartilage injury. The differences in the causes of lower limb arthritis are striking. The one-year data also shows a much higher percentage of post-traumatic ankle osteoarthritis (54%) as compared to the hip (8%), and the knee (12.5%).

In conclusion, arthritis of the ankle is unique compared to the other major lower extremity arthritidies. The relatively young average age of presentation of painful, post-traumatic ankle OA to our tertiary center is concerning because of the lack of available long-lasting treatments. Future research is needed in order to help better understand the prevention and treatment of ankle OA, particularly in light of the burden of this disease to society and the health system.[9]

ACKNOWLEDGMENTS

The work reported in this manuscript was supported by award P50 AR48939 from the National Institutes of Health, Specialized Center on Research for Osteoarthritis.

REFERENCES

1. **Praemer AP, Furner S, Rice DP:** *Musculoskeletal Conditions in the United States.* Rosemont, Illinois, American Academy of Orthopaedic Surgeons. 182. 1999.
2. **Cushnaghan J, Dieppe P:** Study of 500 patients with limb joint osteoarthritis. I. Analysis by age, sex, and distribution of symptomatic joint sites. *Ann Rheum Dis.* 1991 Jan;50(1): 8-13.
3. **Demetriades L, Strauss E, Gallina J:** Osteoarthritis of the Ankle Joint. *Clin Orthop* 1998: 349: 28-42.
4. **Wyss C, Zollinger H:** The causes of subsequent arthrodesis of the ankle joint. *Acta Orthop Belg* 1991: 57 (suppl 1): 22-27.
5. **Taga I, Shino K, Inoue M, Nakata K, Maeda A:** Articular cartilage lesions in ankles with lateral ligament injury: An arthroscopic study. *Am J Sports Med*, 1993; 21:120-126.
6. **Inokuchi S, Ogawa K, Usami N, Hashimoto T:** Long-term follow up of talus fractures. *Orthopaedics*, 1996; 19:477-481.
7. **Saltzman C, Buckwalter J:** *Ankle Arthritis: Emerging Concepts and Management Strategies*, AAOS Instructional Course Lectures, 1999, 48:231.
8. **Buckwalter J, Saltzman C:** *Ankle Osteoarthritis: Distinctive Characteristics*. AAOS Instructional Course Lectures, 1999, 48:233-41.
9. **Buckwalter J, Saltzman C, Brown T:** The impact of osteoarthritis: implications for research. *Clin Orthop*, 2004, 427 Suppl:S6-15.

SALVAGE OF DIFFUSE ANKLE OSTEOMYELITIS BY SINGLE-STAGE RESECTION AND CIRCUMFERENTIAL FRAME COMPRESSION ARTHRODESIS

Charles L. Saltzman, MD

ABSTRACT

Salvage of diffuse ankle osteomyelitis, especially in compromised hosts, is a challenging problem. The purpose of this report was to evaluate early complications and results using a standardized salvage protocol. Eight patients with diffuse ankle osteomyelitis were treated by resection of all infected tissue and hybrid-frame compression arthrodesis. At presentation, five had open wounds. According to the Cierny/Mader classification, all had diffuse anatomic involvement and six of eight were compromised hosts. Seven had central distal tibial column involvement and one had primarily talar involvement. Surgical technique involved a two-incision approach, removal of all infected material and application of a compression circumferential frame with five thin wires across the foot, two across the tibia and two half-pins in the tibia. Fusion of eight ankles and four subtalar joints was attempted. All patients received six weeks of intravenous antibiotics. Open wounds were treated with wound vacuum assisted closure (VACs) devices until closure was achieved. Frames were removed at three months and walking casts were applied for one to two more months. Ankle sepsis was eradicated in all patients. Seven of eight ankles fused at an average of 13.5 weeks (range, 10 to 16 weeks). One limb required below-knee amputation (BKA) at five weeks due to nonreconstructible vascular insufficiency. Three of four subtalar joints fused. Fixation problems included two pin-track infections cleared with oral cephalexin and one broken half-pin. Two diabetic Charcot patients required long-term ankle-foot orthosis (AFO) use due to subtalar instability. At average 3.4-year follow-up, none of the seven fused ankles has required further surgery. Use of this standardized salvage treatment protocol for these difficult problems in selected patients was effective with a relatively low associated complication rate.

INTRODUCTION

Salvage of diffuse ankle osteomyelitis, especially in compromised hosts, is a challenging problem. Although transtibial-level amputation is a treatment option, many patients would like to preserve their limb. Options for salvage surgery are several, and most involve multiple surgeries and long term treatment.[3,6,10,11,13,15] The author has used a protocol utilizing some well-described techniques including complete debridement of all infected or involved tissue,[11] application of a modified Ilizarov compression frame,[8,9] use of vacuum-assisted wound closure[7] and intravenous antibiotics. The purpose of this report is to evaluate early complications and results using a standardized salvage protocol in a selected case series.

METHODS

Between 2000 and 2002, medical records and radiographs of patients with diffuse ankle infection treated by single-stage debridement/arthrodesis were reviewed under an IRB-approved protocol. Data collected included age, gender, major co-morbidities, previous treatment, presence of open wounds, location of osteomyelitis, microbiological data, adjunct procedures and outcome from surgery. All patients were given informed consent preoperatively and understood that the surgical treatment choices were either a transtibial-level amputation or an attempted resection/arthrodesis. They were further informed of the projected period of major convalescence with each (average six weeks for amputation versus six months for resection/arthrodesis salvage) and the higher predictability of results with amputation. Patients were followed until ultimate resolution of the presenting problem.

Correspondence:
Charles Saltzman, M.D., Professor
Department of Orthopaedics and Rehabilitation
Department of Biomedical Engineering
University of Iowa
200 Hawkins Drive
Iowa City, IA 52246 USA
Phone: 319-356-7149
Fax: 319-353-6754
charles-saltzman@uiowa.edu

Surgical Technique

The ankle was approached with medial and lateral J-type incisions, which are longitudinal across the malleoli and horizontal in the hindfoot. A transfibular approach to the ankle was used and the lateral malleolus was removed. If the medial malleolus was not involved, it was left intact, otherwise, it was removed. All hardware, infected bone and soft tissue were removed. The incisions were extended up the calf as needed to completely expose and debride the infection. After the wounds were completely irrigated and dÈbrided, the ankle and subtalar joints were placed in the optimal position for fusion and two temporary smooth Steinmann pins were driven through the heel across the hindfoot into the tibia.

We applied a pre-built circular fixation frame. Three tensioned 1.8 mm wires were placed in the hindfoot. If the talus was preserved and the subtalar joint was not included in the fusion, one of these wires was placed across the talus and two were placed through the calcaneus. Two more wires were tensioned across the metatarsals. The tibia was fixated at two levels with circular rings. At each level, a tensioned thin wire and half-pin were used. The sole of the foot was placed perpendicular to the anterior crest of the tibia, with the foot externally rotated five degrees more than the opposite side. Open wounds were left open; all surgical wounds were closed in one layer with monofilament.

Postoperative Care

Open wounds were treated with vacuum assisted closure (Kinetic Concepts, Inc, San Antonio, TX) until complete epithelialization. Pin care involved removing bandages on the second day after surgery and removing heavy crusts around the half-pins with a cotton-tipped applicator. Daily showering and towel-pad drying were encouraged. Intravenous antibiotics were used for six weeks. Frames were removed around three to four months and a plaster below-knee cast was applied. Weight bearing was permitted after radiographic fusion was apparent. Casts were removed one month after apparent radiographic fusion, and patients were progressed to a removable walker and then to a shoe in another month. Patients with continued instability of the hindfoot were placed in an ankle-foot orthosis. Follow-up was a minimum of two years.

RESULTS

Eight patients were identified who underwent treatment of diffuse ankle osteomyelitis with this protocol during the study period. Mean age was 58.3 years (range, 51 to 72 years); three were female and five were male. Five had open wounds. Five patients had diabetes mellitus. One had rheumatoid arthritis and a history of chronic steroid use. According to the Cierny/Mader staging system of osteomyelitis, all had type IV (diffuse permeative lesions), and six of eight were considered type B, "systemically compromised" hosts.[6] Therefore, the clinical staging of this group of patients was six type IV-B, and two type IV-A. Localizing the osteomyelitis by structural column[6] revealed seven patients had central column destruction, four had additional medial column involvement, four had additional lateral column involvement and one had an infected, collapsed, necrotic talus.

Most patients had had previous surgery. One patient had two attempts at an open reduction/internal fixation (ORIF) of an ankle fracture, one had talar fracture ORIF, one had an attempted ankle fusion, and one had an infected total ankle replacement component removal. Two previous soft tissue flaps failed on a single patient, and two patients had previous incision and drainage procedures. At presentation to our center, two patients had completed a six-week course of intravenous antibiotics, two had been treated over six weeks on oral antibiotics, and four were not pretreated with antibiotics.

At surgery, intraoperative specimens were sent for culture and sensitivity on all ankles. Five grew out Staphylococcus aureus, one grew out Morganella morganii and two did not grow out an organism. All patients were treated with culture-specific intravenous antibiotics, and the two patients with no identifiable organisms were treated with a first-generation cephalasporin (Cefazolin).

In these eight patients, compression arthrodesis of eight ankles and four subtalar joints was attempted. One patient required a below-knee amputation for non-reconstructible vascular insufficiency five weeks after surgery. Fixation problems included two pin track infections successfully treated with oral Cephalexin for ten days, and one broken half-pin that was treated by removing the external portion of the pin, leaving the internal portion within the tibia.

Frames were removed at an average of 12.7 weeks (range, 10 to 16 weeks). Cast or boot immobilization was used for an average of 6.9 weeks (range, 4 to 10 weeks). Seven of eight ankles radiographically fused at an average of 13.5 weeks (range, 10 to 16 weeks) (Figure 1), while the other limb required transtibial amputation at five weeks due to non-reconstructible vascular insufficiency. Three of four subtalar joints fused in the same time frame. Two diabetic Charcot patients required long-term AFO use due to clinical subtalar joint instability (Figure 2); neither had pain. No patient complained of problems with limb shortening. At average 3.4 years follow-up, none of the seven fused ankles have required further surgery.

Figure 1A

Figure 1B

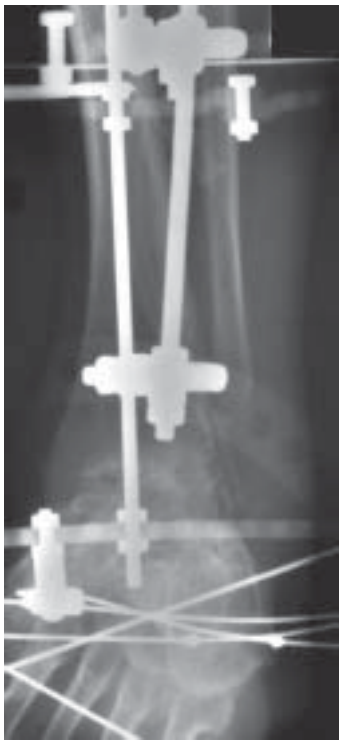

Figure 1C

Figure 1D

Figure 1E

Figure 1F

Figure 1. AP (a) and lateral (b) radiographs of massively swollen (closed) ankle of a 54-year-old type II diabetic male. He had received six weeks of IV nafcillin. According to the Cierny/Mader classification, he has diffuse involvement (IV) and is a systemically compromised host (B). The central and lateral columns are involved. He was treated with debridement of all infected tissue, removal of joint cartilage from the ankle and subtalar joints, and (c, d) modified Ilizarov external fixation. AP (e) and lateral (f) radiographs at two years show solid fusion of both joints.

Figure 2A

Figure 2B

Figure 2C

Figure 2D

Figure 2. AP (a) and lateral (b) radiographs of swollen (closed) ankle of a 59-year-old type I diabetic female. She had two previous open reduction and internal fixations of her ankle complicated by Staphylococcus aureus infection. She had received seven weeks of intravenous vancomycin and was advised to have an amputation. She was treated with debridement of all infected tissue, removal of hardware and joint cartilage from the ankle and subtalar joints, and circular ring compressive fixation. At two years (c, d), she has a solid ankle fusion, but requires AFO use for coronal plane subtalar joint instability.

DISCUSSION

This retrospective case study series shows promise with the use of a simple single-stage protocol for treatment of diffuse ankle osteomyelitis in mostly compromised hosts. The approach requires meticulous care with debridement and frame application. The results reveal a high rate of limb salvage. The key elements are 1) complete resection of all infected tissue, 2) application of a circular frame with pins and wires out of the zone of infection, 3) using only tensioned thin wires in the foot, 4) six weeks of intravenous antibiotics post-operatively, and 5) use of a wound VAC to close all open wounds. With this strategy, we had a high success rate despite the poor condition of the ankles and the systemically debilitated state of six out of eight of our patients.

Cierny et al. developed important concepts for classifying ankle sepsis and reported their results in 36 patients.[6] They presented two important concepts: 1) the concept of a biological classification of adult osteomyelitis, and 2) the concept of an anatomical classification of three columns of the distal tibia and ankle. The first is a generic system intended to give clinical information on prognosis and treatment. This system has been widely adopted for use to describe the results of treatment throughout the musculoskeletal system. Stage IV (diffuse) lesions fare the most poorly, especially in systemically compromised hosts (B). The second system is an anatomical classification used by Cierny et al. to guide fixation strategies.

In the present series, all eight patients had diffuse osteomyelitis: Six were systemically compromised hosts, seven had central tibial column loss, and the other had complete talar body collapse. In the original series of 36 patients studied by Cierny et. al., using aggressive reconstructive techniques for that time period, the limb salvage rate was 74

percent.[6] Patients with substantial central column involvement were treated with staged reconstruction involving antibiotic bead placement, multiple bone graftings and liberal use of free muscle transfers. They reported a rate of 86 percent with major complications. All of their treatment failures occurred in type B hosts. In that series, of the 12 non-amputated ankles classified as Cierny/Mader stage IV-B, the average number of procedures per patient was 4.9, eventually eradicating infection in 83 percent and attaining union in 92 percent.[6]

Several different salvage strategies have been used for limited numbers of patients with these challenging problems.[1,2,6,10,11,13,15] Before the Cierny/Mader classification system was developed, Lortat-Jacob et al. reported successful fusions in 18 of 24 (75 percent) ankles with external fixation and multiple Papineau graftings.[11] Thordarson et al. reported their center's experience with staged reconstruction of five patients with distal tibial osteomyelitis with open wounds. The treatment protocol involved staged debridements, soft tissue transfers, unilateral external fixation and a six-week course of intravenous antibiotics. These authors had a high rate of salvage and infection eradication.[15] Richter et al. reported the results of 45 ankle and/or subtalar infections treated by debridements, a combination of internal and simultaneous large-pin external fixation, and selective iliac crest grafting.[13] Their patients required an average of 2.8 surgical procedures until fusion. Solid fusion was achieved in 39 of 45 patients with this protocol, six requiring further pin track surgery for continuous infectious drainage. Their cohort of patients was different from that in our present study, as only five of 45 patients in their study had diabetes mellitus. The complication rates were higher in their patients with systemic comorbidities.

Kollig et al. presented a series similar to our present study.[10] In their series of 15 patients with septic ankles, 12 were treated with hybrid external fixation and three with a combination of external fixation and internal screw fixation. Open wounds were treated with dressing changes, and skin grafting as needed. Tensioned thin wires were used in the foot and distal tibia. Systemic comorbidities were present in six of 15 patients, and one other was noted to have "mental illness." In Kollig's series, one patient required revision ankle arthrodesis, and two required extension of fusion to the subtalar joint. Fourteen of 15 (93 percent) of ankles ultimately fused, but three patients had a persistently draining fistula.[10]

Our present study follows the lead of past studies in defining a protocol to treat these challenging problems. The importance of a complete debridement of all devitalized and potentially infected tissue was emphasized by other authors.[2,4-6,10-15] In the present series, a simple circular frame was used. This frame's basic features were described by Johnson et al.,[9] and has a relatively low incidence of hardware failure or bone cut-out, even in debilitated patients. The addition of a wound VAC has substantially improved our ability to obtain secondary closure without the need for free tissue transfer or skin grafting, and appears to hasten closure, thereby reducing the incidence of persistently draining sinuses.

Even with a complex practice in a tertiary center, these cases are relatively rare. Patients with life-threatening limb infections or clear-cut non-reconstructible vascular insufficiency are directly treated with an amputation and are not given the option of limb salvage by this protocol. Others have limb-threatening infections with adequate vascularity, and are possible candidates for limb salvage. When I give informed consent for this procedure, I tell the patient that a transtibial-level amputation will likely restore ambulatory function more quickly and reliably. Some patients decide to have an amputation. They are usually systemically debilitated from infection, have undergone multiple previous surgeries, need or want to get back to work sooner, and financially cannot risk possible failure of the salvage protocol. Therefore, a major limitation of this study relates to the retrospective design. I have not specifically kept records of how many patients were possible candidates, but decided to have an amputation of their limb rather than undergoing an attempted salvage ankle fusion/reconstruction with this protocol. Undoubtedly, there was inherent selection bias as patients who were unwilling or unable to consider extensive salvage surgery are likely different from those willing to have the surgery.

Another limitation relates to antibiotic coverage. All patients were given a six-week course of intravenous antibiotics after surgery. Swiontkowski et al. showed that a shorter course of intravenous antibiotics followed by culture-specific antibiotics is effectively equivalent to a six-week course of intravenous antibiotics in the treatment of chronic osteomyelitis.[14] In that series, however, local antibiotic-impregnated polymethylmethacrylate bead treatment and soft tissue transfers were used liberally, and these two techniques were not used in our present series. In the present series, a six-week course of intravenous antibiotic therapy may not always have been necessary to eradicate infection. Further study of the optimal time-course and route of antibiotic treatment is clearly needed.

In conclusion, patients with severe, diffuse peri-ankle osteomyelitis may be treated effectively with a single-stage resection and circumferential frame compression

arthrodesis. The tensioned thin wires in the foot confer good mechanical stability and are associated with low infection rates. The use of a wound VAC for open wounds may have been one major reason there were no persistent sinuses or need for soft tissue transfer/grafting surgeries. The author believes this is a reasonable alternative to below-knee amputation in selected patients.

REFERENCES

1. **Anderson, J. G.; Coetzee, J. C.; and Hansen, S. T.:** Revision ankle fusion using internal compression arthrodesis with screw fixation. *Foot Ankle Int,* 18(5): 300-9, 1997.
2. **Bibbo, C.; Lee, S.; Anderson, R. B.; and Davis, W. H.:** Limb salvage: the infected retrograde tibiotalocalcaneal intramedullary nail. *Foot Ankle Int,* 24(5): 420-5, 2003.
3. **Bishop, A. T.; Wood, M. B.; and Sheetz, K. K.:** Arthrodesis of the ankle with a free vascularized autogenous bone graft. Reconstruction of segmental loss of bone secondary to osteomyelitis, tumor, or trauma. *J Bone Joint Surg Am,* 77(12): 1867-75, 1995.
4. **Chan, Y. S.; Ueng, S. W.; Wang, C. J.; Lee, S. S.; Chen, C. Y.; and Shin, C. H.:** Antibiotic-impregnated autogenic cancellous bone grafting is an effective and safe method for the management of small infected tibial defects: a comparison study. *J Trauma,* 48(2): 246-55, 2000.
5. **Cierny, G., III:** Infected tibial nonunions (1981-1995). The evolution of change. *Clin Orthop,* (360): 97-105, 1999.
6. **Cierny, G., III; Cook, W. G.; and Mader, J. T.:** Ankle arthrodesis in the presence of ongoing sepsis. Indications, methods, and results. *Orthop Clin North Am,* 20(4): 709-21, 1989.
7. **Clare, M. P.; Fitzgibbons, T. C.; McMullen, S. T.; Stice, R. C.; Hayes, D. F.; and Henkel, L.:** Experience with the vacuum assisted closure negative pressure technique in the treatment of non-healing diabetic and dysvascular wounds. *Foot Ankle Int,* 23(10): 896-901, 2002.
8. **Hawkins, B. J.; Langerman, R. J.; Anger, D. M.; and Calhoun, J. H.:** The Ilizarov technique in ankle fusion. *Clin Orthop,* (303): 217-25, 1994.
9. **Johnson, E. E.; Weltmer, J.; Lian, G. J.; and Cracchiolo, A., III:** Ilizarov ankle arthrodesis. *Clin Orthop,* (280): 160-9, 1992.
10. **Kollig, E.; Esenwein, S. A.; Muhr, G.; and Kutscha-Lissberg, F.:** Fusion of the septic ankle: experience with 15 cases using hybrid external fixation. *J Trauma,* 55(4): 685-91, 2003.
11. **Lortat-Jacob, A.; Beaufils, P.; Coignard, S.; and Elahmadi, J.:** [Tibiotarsal arthrodesis in a septic milieu]. *Rev Chir Orthop Reparatrice Appar Mot,* 70(6): 449-56, 1984.
12. **Patzakis, M. J.; Greene, N.; Holtom, P.; Shepherd, L.; Bravos, P.; and Sherman, R.:** Culture results in open wound treatment with muscle transfer for tibial osteomyelitis. *Clin Orthop,* (360): 66-70, 1999.
13. **Richter, D.; Hahn, M. P.; Laun, R. A.; Ekkernkamp, A.; Muhr, G.; and Ostermann, P. A.:** Arthrodesis of the infected ankle and subtalar joint: technique, indications, and results of 45 consecutive cases. *J Trauma,* 47(6): 1072-8, 1999.
14. **Swiontkowski, M. F.; Hanel, D. P.; Vedder, N. B.; and Schwappach, J. R.:** A comparison of short- and long-term intravenous antibiotic therapy in the postoperative management of adult osteomyelitis. *J Bone Joint Surg Br,* 81(6): 1046-50, 1999.
15. **Thordarson, D. B.; Patzakis, M. J.; Holtom, P.; and Sherman, R.:** Salvage of the septic ankle with concomitant tibial osteomyelitis. *Foot Ankle Int,* 18(3): 151-6, 1997.

SYSTEMIC BLASTOMYCOSIS WITH OSSEOUS INVOLVEMENT OF THE FOOT: CASE REPORT

Anthony V. Mollano, M.D.; Hala Shamsuddin, M.D.; Jin-Soo Suh, M.D.

ABSTRACT

We report a patient who presented with three months of foot pain, lytic bone lesions in the foot, and a painless ipsilateral leg skin ulcer. Bone and skin biopsies revealed organisms compatible with *Blastomyces*. Systemic blastomycosis is rare, especially with bone involvement in the foot.

CASE REPORT

The patient is a 27-year-old woman who presented to our foot outpatient clinic with three months of worsening right midfoot pain, worst with weight-bearing. Non-steroidal anti-inflammatory agents and tramadol did not help. There was no history of trauma. A few weeks after the foot pain onset, she also noticed a quarter-sized painful nodular skin lesion in the popliteal fossa that subsequently started to drain clear fluid.

Several weeks before the foot pain onset, she was diagnosed with a "pneumonia" for which she was treated locally as an outpatient with two weeks of amoxicillin, with resolution of her respiratory symptoms. A microbiologic diagnosis was not attempted. Past medical history was otherwise significant for depression and childhood asthma. She had no fevers, chills, weight loss or change in appetite. She was a 1.5 pack-per-day smoker for 15 years. She denied a history of sexually transmitted diseases, cancer, immunocompromise, drug abuse or frequent or recurrent infections. She had multiple tooth caries in the past, with multiple extractions. She lived in a farm house. She had a monogamous partner. She was not pregnant.

On examination, she was obese, in no acute distress, and with normal vital signs. Lung examination revealed clear breath sounds. Left foot examination revealed exquisite tenderness throughout the medial midfoot. She could not tolerate any midfoot passive or active motion due to pain. The skin was normal in the foot with minimal swelling. A left popliteal fossa examination revealed a 4 x 2 cm beefy red granulomatous plaque with mild creamy exudate (Figure 1). There was no inguinal or popliteal adenopathy.

Figure 1. Left leg popliteal fossa skin plaque (top), and closeup (bottom).

Plain radiographs (Figure 2) of the foot, performed at an outside institution two months prior to her evaluation at our clinic,

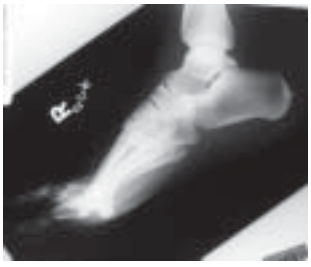

Figure 2. Normal foot lateral radiograph one month after onset of pain.

University of Iowa Hospitals and Clinics, Iowa City, Iowa

Correspondence:
Anthony V. Mollano, MD
Department of Orthopaedics and Rehabilitation
University of Iowa
200 Hawkins Drive
Iowa City, IA 52246
Email: anthony-mollano@uiowa.edu

Figure 3. Sagittal MRI one month after onset of pain, revealing diffuse signal change in navicular with associated soft tissue edema.

Figure 4. Lateral foot radiograph at presentation in our clinic, three months after onset of pain, revealing destructive lytic lesion in proximal navicular.

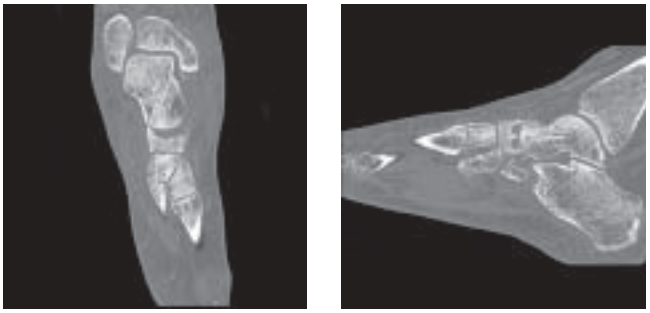

Figure 5. CT scans revealing diffuse foot and ankle lytic lesions with the largest erosive lesion in the proximal navicular on coronal and sagittal images.

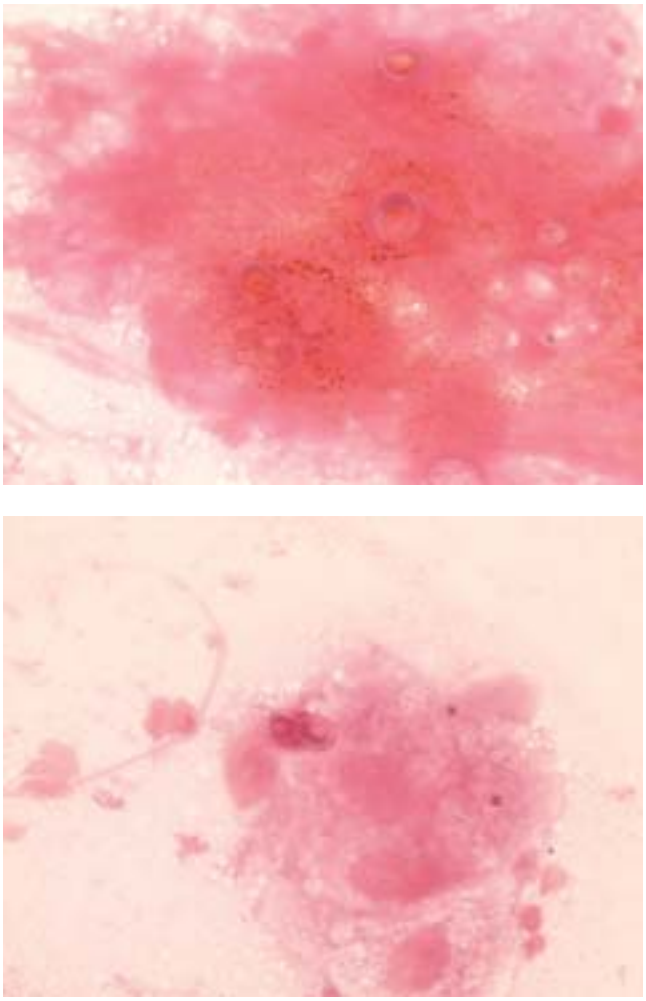

Figure 6. Microscopic blastomycosis from foot navicular biopsy: spherical yeast forms with budding apparent.

were normal. MRI (Figure 3) at that time revealed signal changes throughout the navicular bone with surrounding edema in the soft tissue. The MRI would have been consistent with possible infection, malignancy, stress fracture, or avascular necrosis of the navicular.

At our evaluation, plain radiographs revealed a proximal navicular well-demarcated cyst that had eroded into the talonavicular joint (Figure 4). There was osteopenia

throughout the foot. Foot computerized tomography (CT) scan revealed multiple lytic lesions throughout the foot, and a large focal cyst of the proximal navicular with intra-articular involvement (Figure 5).

Laboratory data revealed a CRP of 2.0 (normal < 0.5), an ESR of 30, and a normal CBC.

The most likely etiology on our differential was chronic multi-focal infectious process, more likely of fungal or tubercular etiology, rather than bacterial etiology.

She underwent small open incisional biopsy of the navicular bone. The navicular cyst was filled with white gelatinous material; cultures and pathology were obtained. Cultures were also obtained from the talonavicular joint synovial fluid. Intraoperative frozen pathology revealed granulomatous chronic and acute inflammation. The wound was irrigated and closed. She was casted and remained non-weight-bearing.

Blastomyces dermatitidis (Figure 6) was seen on gram stain and Calcoflor stain, and later grew from cultures of the navicular cyst material, and the talonavicular synovial fluid. Histology of bone revealed abundant acute inflammatory cells with multiple necrotizing granulomas, and spherical yeast forms were present with thick walls and broad-based budding, compatible with *Blastomyces*.

Further workup included a chest radiograph showing right upper-lobe linear opacities, and a chest CT with right upper-lobe scarring. Pathology of the left leg skin popliteal lesion shave specimens revealed chronic suppurative inflammatory infiltrate with giant cells, scattered plasma cells, and scattered broad-based budding yeast forms, again compatible with *Blastomyces*. Peripheral blood immunopathology revealed normal T-lymphocytes and B-lymphocytes. Electrolytes and liver enzymes were normal. HIV testing was negative.

Clinical diagnosis was North American blastomycosis involving lung, bone, and skin. She most likely had respiratory inoculation resulting in the pneumonia that was diagnosed prior to the onset of foot pain, with subsequent hematogenous involvement of bone and skin. Primary bone or skin inoculations are not likely. Treatment with oral itraconazole was initiated at 200 milligrams orally, twice daily.

DISCUSSION

Blastomyces dermatitidis is a dimorphic fungus. In its natural soil habitat, it exists as a mold in multi-cellular colonies composed of branching hyphae. The mold releases spores (conidia) into the air. At body temperature, the fungus grows in a yeast unicellular form, appearing spherical or elliptical, and reproduces by budding. The yeast cell has a thick refractile cell wall. Pulmonary infection occurs after the spores are inhaled. The respiratory infection could be asymptomatic, or result in self-limited acute pneumonia, or chronic pneumonia. Systemic involvement infrequently occurs overall, but when it does, it can manifest in any organ, most commonly the bone and joints, skin and central nervous system. In North America, *Blastomyces* is endemic in Southeastern and Southcentral states, especially those bordering the Mississippi and Ohio river basins.

Our patient demonstrated several uncommon manifestations of this infection. She had multi-organ involvement: lung, skin, and bone. A large series of 326 blastomycosis cases revealed that a single organ was involved in 82.8% of cases (lung 91.4%; skin 18.1%; bone 4.3%; genitourinary 1.8%; nervous system 1.8%).[1] Bone involvement has been reported in the literature from 1950[2] to recently.[3] However, bone involvement in many cases has been at the distal ends of long bones.[3] It is unusual for foot involvement to occur, as in this patient.

The pneumonia that occurred prior to her foot symptoms likely represented blastomycosis, resulting from pulmonary inoculation. Her pulmonary symptoms were self-limited. However, the chest CT showing chronic scarring could be compatible with chronic pulmonary infection. She then likely proceeded to disseminate to involve the skin and bones of the foot. Eventually, diagnosis required pathology examination of the foot navicular cyst. The skin lesion was not appreciated initially to be fungal, nor was it related to the foot bone lesion, but its realization may have initially made us more suspicious for *Bastomycosis.*

The diagnosis of skeletal blastomycosis is frequently delayed. In our patient, she had three months of symptoms before a bone biopsy was obtained. This is similar to the reported literature, where diagnosis of blastomycosis is delayed due to low suspicion, and greater consideration given to malignancy or tuberculosis. In a study from the University of Mississippi, only 18% of 123 patients with blastomycosis were correctly diagnosed early.[4] In our patient, once the bone diagnosis was made, the skin lesion was confirmed to be fungal.

The plan for therapy of this patient will involve oral itraconazole for at least one year. Amphotericin B is only indicated in cases of either life-threatening disease, or central nervous system involvement.[5]

REFERENCES

1. **Chapman SW, Lin AC, Hendricks KA, Nolan RL, Currier MM, Morris KR, Turner HR:** Endemic blastomycosis in Mississippi: epidemiological and clinical studies. *Semin Respir Infect*. 1997 Sept; 12(3):219-28.
2. **Alfred KS, Harbin M:** Blastomycosis of bone; report of a case. *J Bone Joint Surg Am*. 1950 Oct; 32(A:4):887-9.
3. **Saiz P, Gitelis S, Virkus W, Piasecki P, Bengana C, Templeton A:** Blastomycosis of long bones. *Clin Orthop Relat Res*. 2004 Apr;421:255-9.
4. **Lemos LB, Guo M, Baglia M:** Blastomycosis: organ involvement and etiologic diagnosis. A review of 123 patients from Mississippi. *Ann Diagn Pathol*. 2000 Dec;4(6):391-406.
5. **Chapman SW, Bradsher RW Jr, Campbell GD Jr.:** Practice guidelines for the management of patients with blastomycosis. *Clin Inf Dis* 2000; 30:679-83.

SIGNIFICANT SCOLIOSIS REGRESSION FOLLOWING SYRINGOMYELIA DECOMPRESSION: CASE REPORT

Anthony V. Mollano, MD; Stuart L. Weinstein, MD; *Arnold H. Menezes, MD

ABSTRACT

We present the case of a 5-year-old boy presenting with a 54-degree scoliosis secondary to a Chiari I malformation with a holocord syringomyelia extending from C1 to T10. Neurosurgical treatment involved posterior fossa craniectomy with decompression, and partial C1 laminectomy. At follow-up 7 years later, at age 12, radiographs revealed only a 4-degree scoliosis, and follow-up MRI revealed a deflated syrinx. We report this case to reveal the most significant scoliosis regression seen in our experience that may occur in younger patients after neurosurgical syringomyelia decompression for Chiari I hindbrain herniation.

CASE REPORT

A five-and-a-half year-old Caucasian boy presented to his pediatrician with rounding of his shoulders and scoliosis noticed over the course of one month. A pediatric orthopaedic surgeon (S.L.W.) evaluation revealed abnormal neurologic exam findings, including a diminished gag reflex, and 3+ knee hyperreflexia. Radiographs demonstrated a 54-degree right thoracic scoliosis (Figure 1), and a 42-degree thoracic kyphosis. Given the rapid onset scoliosis and kyphosis, and the abnormal neurologic exam, an MRI was indicated to evaluate for primary central nervous system pathology. MRI identified a Chiari I malformation with a holocord syringomyelia extending from C1 to T10 (Figure 2).

Successful neurosurgical treatment (A.H.M.) involved posterior fossa decompression via craniectomy and partial C1 laeminectomy (Figure 3A). The superior two-thirds of the C1 lamina were removed. Intraoperatively, the cerebellar tonsils were found to be shrunken and medially approximated, and had descended below the C1 lamina (Figure 3A). A pathologic "veil" was occluding the egress of cerebrospinal fluid (CSF) from the fourth ventricle to the subarachnoid space (Figure 3B). The "veil" was surgically opened to restore CSF outflow from the fourth ventricle (Figure 3C). A fascia duraplasty was then performed.

The patient gradually returned to all activities. The scoliosis regressed. Six month post-operative radiographs showed a scoliosis decrease to 33 degrees; and at 7 years after surgery, a further decrease to 4 degrees (Figure 4). After 9 years, the curve clinically increased slightly, likely related to pubertal growth, but it remained stable thereafter, with no orthopaedic intervention indicated. Follow-up MRI showed a deflated stable syrinx. At age 17, he had no deformity or back pain, and was the starting running back for his high school varsity football team.

DISCUSSION

A series of very young children with Chiari I malformation with hindbrain herniation without myelodysplasia has been reported from our institution.[1] In this report, 31 patients were seen at the University of Iowa from 1985 to 2000. Most patients presented similar to our patient with oropharyngeal impairment and scoliosis. In the above reported series, patients presented most commonly with a chief complaint of impaired oropharyngeal function (35%), scoliosis (23%), headache or neck pain (23%), sensory disturbance (6%), and weakness (3%). Patients were treated surgically with posterior fossa decompression, duraplasty, and cerebellar tonsillar shrinkage, as described in our patient. Syringomyelia improved in all patients, as in our case. Scoliosis resolved in 2 of 8 patients, improved in 5, and stabilized in 1. However, our patient in this case report represents a substantial scoliosis resolution, from 55 degrees to 4 degrees. This is in our experience the largest secondary scoliosis regression that we have seen after neurosurgical decompression.

Age was recently identified by Brockmeyer et al.[2] to correlate with scoliosis improvement in children with Chiari I malformations and scoliosis treated with posterior fossa decompression. Thirteen patients of the 21 study patients (62%) had curve improvement or stabilization following neurosurgical treatment. Eight of 21

Department of Orthopaedics and Rehabilitation; * Department of Neurosurgery; University of Iowa Hospitals and Clinics, Iowa City, Iowa 52242

Correspondence:
Anthony V. Mollano, MD
Department of Orthopaedics and Rehabilitation
University of Iowa Hospitals and Clinics
01008JPP
200 Hawkins Drive
Iowa City, Iowa 52242
(319) 356-2595 work
anthony-mollano@uiowa.edu

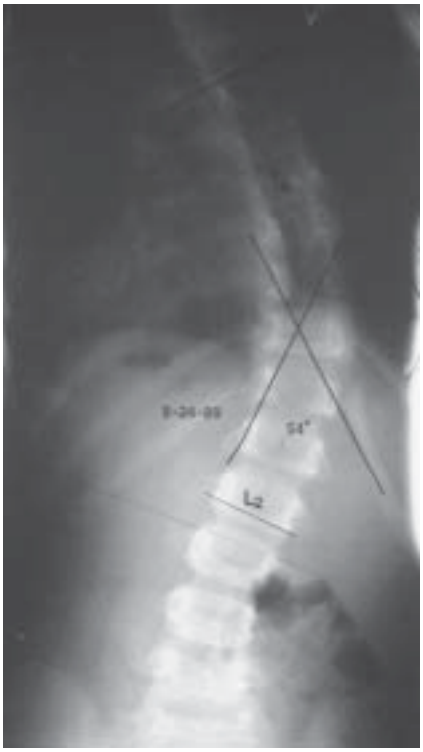

Figure 1. Scoliosis at presentation with a 54-degree Cobb angle.

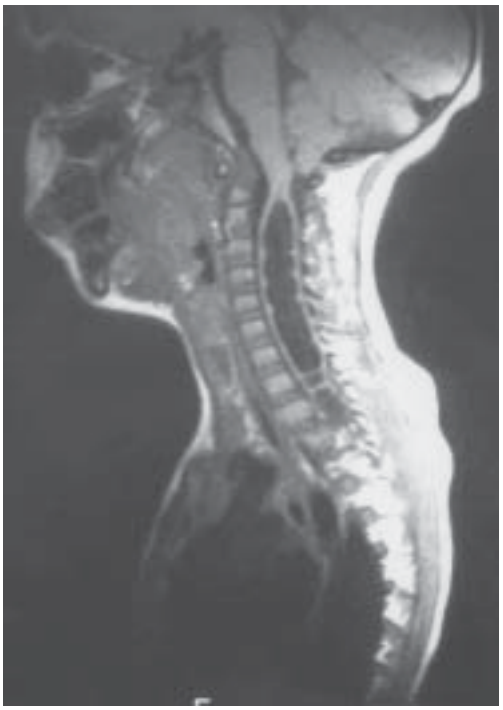

Figure 2. Sagittal MRI revealing holocord Chairi I syringomyelia.

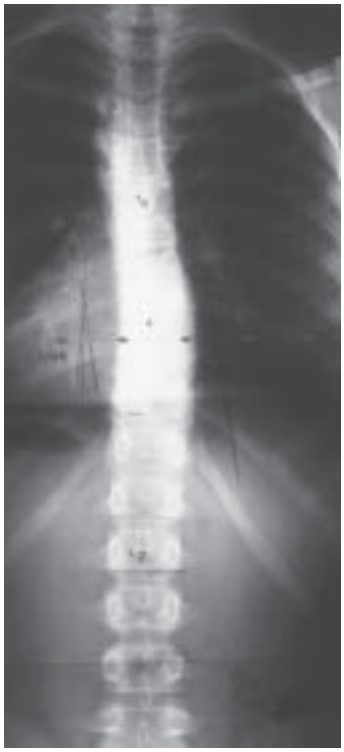

Figure 4. Scoliosis 7 years post-operatively with a 4-degree Cobb angle.

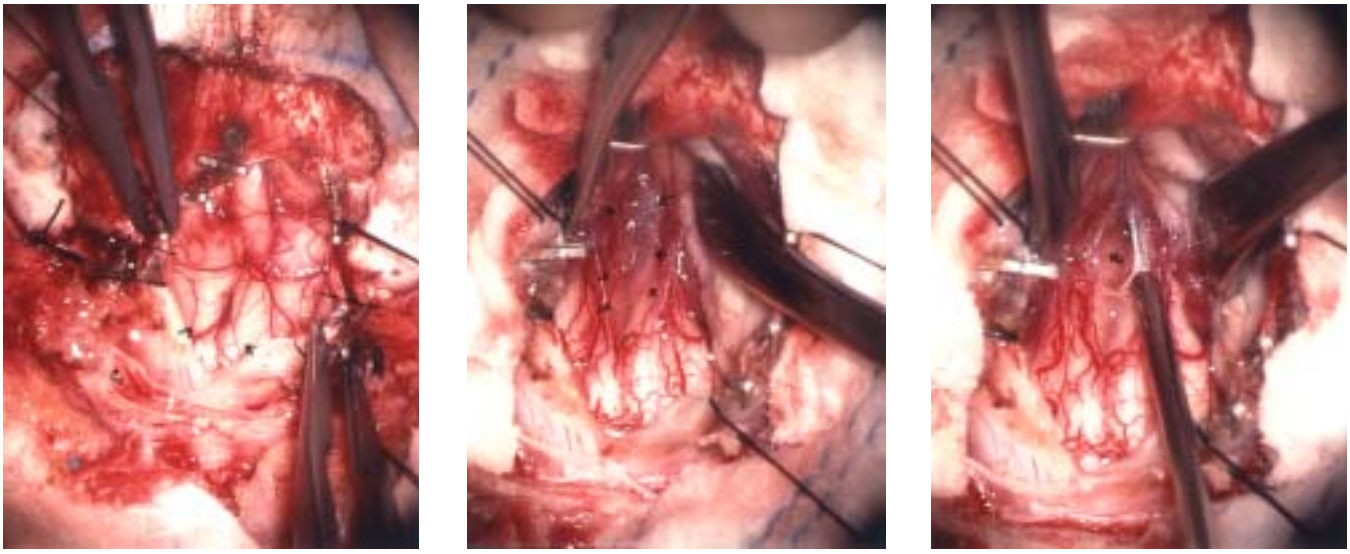

Figure 3. Posterior fossa craniectomy with removal of superior two-thirds of C1 lamina. Interrupted dotted line (3A) represents foramen magnum plane. Arrows (3A) point to herniated medially approximated cerebellar tonsils. Arrows (3B) point to a pathologic "veil" covering the fourth ventricle obstructing CSF outflow. Label V4 refers to fourth ventricle (3C) after the "pathologic" veil has been opened to allow egress and to restore normal CSF dynamics.

patients (38%) had curve progression. Specifically, 10 of 11 patients (91%) who were less than 10 years of age at the time of neurosurgical decompression have had their curves improve or stay the same during follow-up. In contrast, 5 of 7 female patients (72%) older than 10 years old with a curve greater than 40 degrees before neurosurgical decompression have either been fused or are awaiting fusion.

In a prior series by Mulhonen et al. from Iowa City,[3] all Chiari I patients with scoliosis who were under 10 years of age had resolution of their scoliosis, after neurosurgical hindbrain decompression, despite preoperative curves of more than 40 degrees.

The literature, and our case report emphasizes the importance of early diagnosis of Chiari I malformation with syringomyelia in the very young child with scoliosis. The physical exam finding of an abnormal gag reflex is critical. Our case reveals that such young children who undergo surgical manipulation for hindbrain herniation result in improvement of syringomyelia, and also result in improvement of the secondary scoliosis, which in our case was a significant correction of 41 degrees.

REFERENCES

1. **Greenlee JD, Donovan KA, Hasan DM, Menezes AH.** Chiari I malformation in the very young child: the spectrum of presentations and experience in 31 children under age 6 years. *Pediatrics.* 2002 Dec; 110(6):1212-9.
2. **Brockmeyer D, Gillogly S, Smith JT.** Scoliosis associated with Chiari I malformations: the effect of suboccipital decompression on scoliosis curve progression: a preliminary study. *Spine.* 2003 Nov 15;28(22):2505-9.
3. **Mulhonen MG, Menezes, AH, Sawin PD, Weinstein SL.** Scoliosis in pediatric Chiari malformations without myelodysplasia. *J Neurosurg,* 1992 Jul;(77):69-77.

EVALUATION, IMAGING, HISTOLOGY AND OPERATIVE TREATMENT FOR DYSPLASIA EPIPHYSEALIS HEMIMELICA (TREVOR DISEASE) OF THE ACETABULUM: A CASE REPORT AND REVIEW

Dennis R. Wenger, MD[1] and Mark J. Adamczyk, MD[1]

ABSTRACT

Dysplasia epiphysealis hemimelica (DEH), or Trevor's disease, is a rare disorder that most commonly affects the epiphysis of long bones in children. Rarely, major joints such as the hip can be involved. In this paper we describe a successfully treated case involving the acetabulum, documented with multiple imaging modalities, intraoperative photographs, histology, and follow-up radiographs.

INTRODUCTION

Dysplasia epiphysealis hemimelica (DEH), or Trevor disease, is a rare disorder affecting the epiphysis of long bones in pediatric patients. Initially described in 1926 by Mouchet and Belot[1] and subsequently in 1950 by Trevor[2] in relation to the foot, Fairbank[3] in 1956 provided its current name.

The disease is most commonly seen in male children under ten years of age[1,2,3,4,5,6] although it has been described in adults up to age 45.[4] The epiphyseal osteochondroma has a predilection for the lower extremity, typically involving the distal femur, distal tibia and talus.[1,2,3,4,5,6] It usually involves the medial side of the joint, but lateral involvement has also been described. Multiple sites on a single extremity are often involved. Azouz[7] classified the process as localized (involving a single epiphysis), classic (involving more than one bone on a single limb) or generalized (involving the entire lower extremity from pelvis to foot).

We describe a case of localized dysplasia epiphysealis hemimelica involving the acetabulum that caused progressive hip dysplasia. This case is of special interest because of the extensive imaging studies used to document its severity, the complexity of surgery required for treatment, and the good result obtained.

Figure 1. Seven-year-old female with mild right-sided limp. The AP pelvis x-ray demonstrates coxa magna with lateralization of the right femoral head. The acetabular roof and sourcil appear distorted.

CASE PRESENTATION, WORKUP AND MANAGEMENT

History

A seven-year-old female presented to the orthopaedic clinic for evaluation of a mild limp and hip pain, which had been present for one year. She initially had fallen while rollerblading, without significant injury, and subsequently developed a limp which was worse at the end of each day. She also complained at that time of hip pain with walking or running over a distance.

Physical examination

The patient had a near-normal gait. Hip range of motion was limited, especially in external rotation (which lacked 35 degrees compared to the uninvolved hip) and abduction (which lacked 20 degrees). All other hip ranges were symmetric bilaterally. The other joints of the lower extremities appeared to be uninvolved with normal motion.

[1]Children's Hospital of San Diego and the University of California—San Diego
Investigation performed at Children's Hospital San Diego and the University of California—San Diego
No author received financial support for this study.

Correspondence:
Dennis R Wenger, MD
Children's Hospital of San Diego
3030 Children's Way, Suite 410
San Diego, CA 92123
Fax number: (858) 966-8519
Telephone number: (858) 966-5822
Email: orthoedu@chsd.org

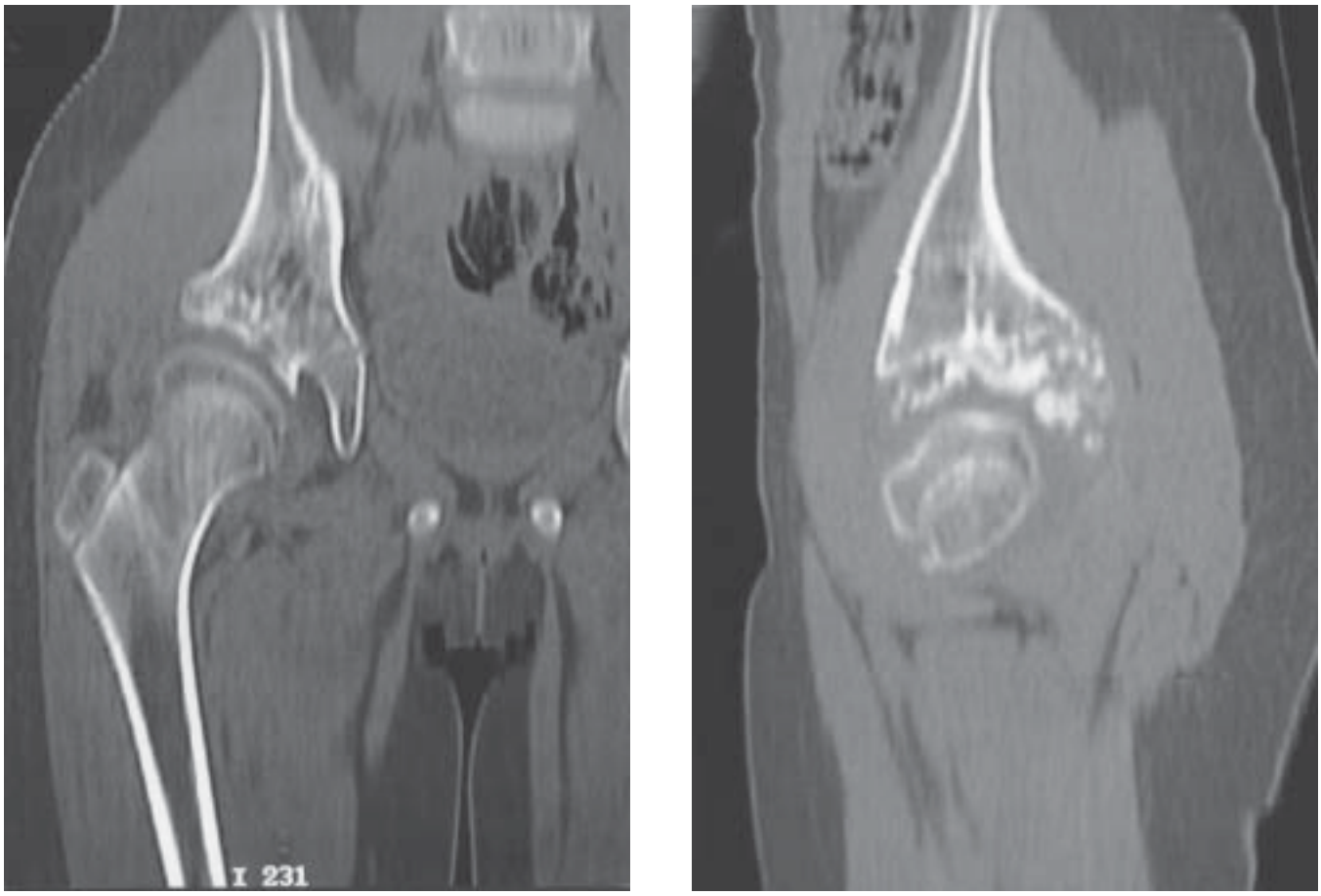

Figure 2. Coronal (A) and sagittal (B) computed tomography images demonstrating a probable intra-articular osteochondroma of right hip.

Imaging studies

Radiographs of the pelvis and hips showed acetabular dysplasia with associated coxa magna (Figure 1). Also noted were sclerotic changes in the acetabulum.

A computerized tomography (CT) scan (Figure 2) that included three-dimensional reconstructed images (Figure 3) was ordered to further evaluate the hip for surgical planning. A magnetic resonance imaging (MRI) study was also ordered to evaluate the lesion and the articular cartilage of the acetabulum (Figure 4). Both studies showed the dysplasia to be caused by an intra-articular bony lesion involving the superior and posterior articular surface of the acetabulum, pushing the femoral head laterally.

Surgical approach

At surgery, the hip was approached anteriorly and the hip capsule opened. The femoral head was then gently dislocated. A large intra-articular bony growth was noted within the acetabulum (Figure 5). After a varus derotational and shortening osteotomy of the femur was performed (through a separate lateral incision), the femoral head could be retracted distally, allowing better visualization of the hip joint. The joint was best inspected with the osteotomy performed but prior to blade plate fixation, because of free mobility of the head and neck.

The extent of the lesion was then better appreciated, involving the medial, superior and posterior portions of the acetabulum. Curved gouges were then used to carefully remove the osteochondroma (Figure 6). Although a substantial portion of the acetabular articular surface was also removed (having already been destroyed by the lesion), this approach was selected with the idea that the non-involved femoral head articular cartilage could mold the formation of fibrocartilage on the acetabular surface, as might occur in a cup arthroplasty.

The femoral head was then concentrically reduced into the acetabulum, but appeared poorly covered laterally. Therefore, a triple osteotomy of the pelvis was performed (Figure 7) to improve hip stability. Pathologic study demonstrated the lesion to be an osteochondroma (Figure 8).

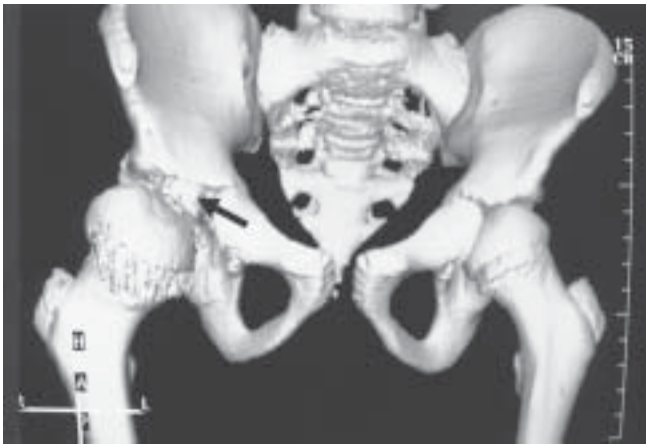

Figure 3A

Figure 3B

Figure 3C

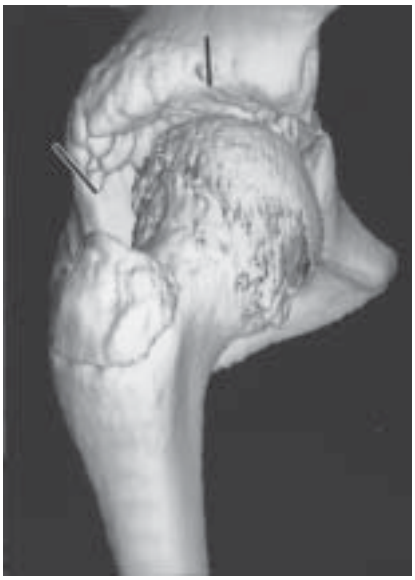

Figure 3D

Figure 3E

Figure 3. AP (A, B and C) three-dimensional computed tomographic images of pelvis and hip demonstrating an intra-articular osteochondroma (solid arrows) within acetabulum (open arrow = anterior rim of acetabulum). Lateral images (D and E) showing osteochondroma (solid lines demarcate borders).

Post-operative course

Post-operatively, the patient was maintained in a hip spica cast for four weeks, at which time early motion of the hip was initiated. She was kept non-weight bearing for twelve weeks. Hardware was removed from the pelvis and femur one year postoperatively.

At most recent follow-up, three-and-one-half years after excision, she had no hip complaints and had returned to all activities. Her hip range of motion continued to be moderately decreased as compared to the uninvolved side, especially in relation to external rotation (lacking 30 degrees) and abduction (lacking 50 degrees). There had been no radiographic evidence for recurrence (Figure 7).

DISCUSSION

While other cases of DEH involving the acetabulum have been reported (with varying degrees of documentation),[8,9,10,11,12,13,14] the patient presented here represents the most complete case documentation to date. Our case clarifies how each type of imaging modality can contribute unique information that guides successful treatment.

Treatment of DEH is not clearly defined and must be specialized for each case encountered. Some authors recommend observation for lesions that are not causing pain, deformity or interference with function.[15] Partial excision of the osteochondroma, while avoiding excessive damage to the articular surface, has been

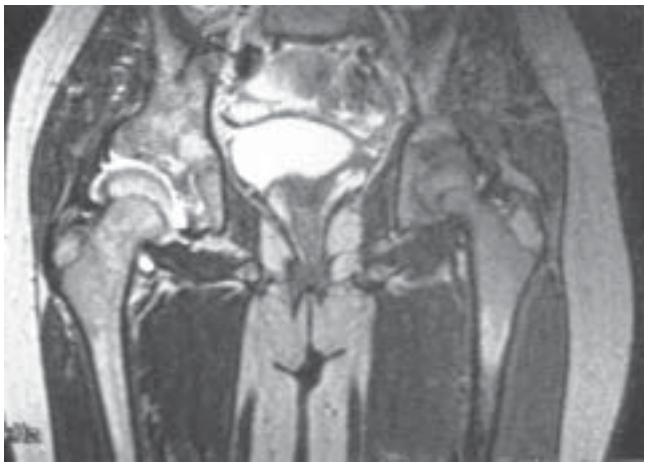

Figure 4. Coronal MRI image demonstrates an intra-articular heterogeneous high-signal mass, which merges imperceptibly into the remainder of the ilium with anterolateral displacement of the femoral head and a small joint effusion. The reading suggested an intra-articular osteochondroma.

recommended for other cases.[1,2,3,4,5] Others recommend avoiding the joint altogether, preferring to make compensatory osteotomies distant from the lesion itself in cases in which the joint surface remains intact.[16] A final novel approach has recently been proposed involving cartilage wedge excision from the lesion itself.[6]

We felt that intra-articular excision would provide the best treatment in this case because allowing progressive femoral head extrusion would lead to inevitable painful hip arthritis. Only longer-term follow-up will define the ultimate outcome for our patient.

The other benefit of surgical excision is the ability to provide a definitive histological diagnosis. This allows a definitive prognosis to be relayed to the patient and family, since malignant degeneration of a DEH lesion has not been documented in the literature.[17]

In summary, dysplasia epiphysealis hemimelica of the hip joint in a child is a rare condition demanding complex planning and analysis. Careful surgical excision that includes acetabular and/or femoral osteotomies to ensure hip joint stability, would appear to provide the best treatment option.

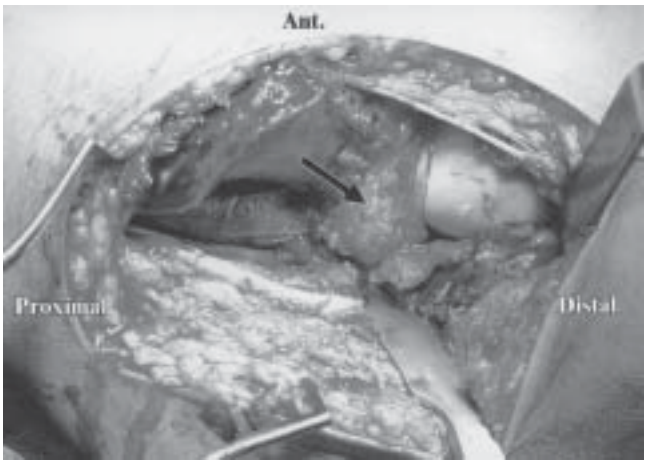

Figure 5A

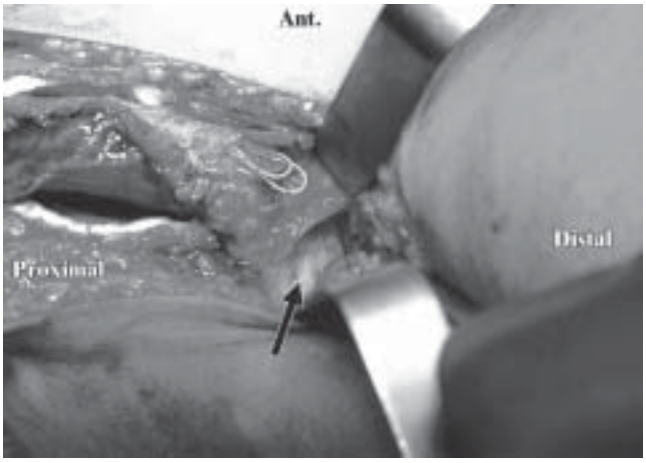

Figure 5B

Figure 5. (A) Intra-operative photographs demonstrating osteochondroma growing out of posterior acetabular roof. (B) Intra-articular component of osteochondroma as seen during surgical removal (arrows).

REFERENCES

1. **Mouchet A, Belot J.** Tarsomegalie. *J Radiol Electrol* 1926;10:289-93.
2. **Trevor D.** Tarso-epiphysial aclasis: a congenital error of epiphyseal development. *J Bone Joint Surg* [Br] 1950;32:204-13.
3. **Fairbank TJ.** Dysplasia epiphysealis hemimelica (tarso-epiphyseal aclasis). *J Bone Joint Surg* [Br] 1956;38:237-57.
4. **Kettelkamp D, Campbell C, et al.** Dysplasia epiphysealis hemimelica: a report of fifteen cases and a review of the literature. *J Bone Joint Surg* [Am] 1966;48:746-766.
5. **Kuo RS, Bellemore MC, et al.** Dysplasia epiphysealis hemimelica: clinical features and management. *J Pediatr Orthop* 1998;18:543-548.
6. **Skripitz R, Lussenhop S, Meiss AL.** Wedge excision chondroplasty of the knee in dysplasia epiphysealis hemimelica—report of two cases. *Acta Orthop Scand* 2003;74:225-229.
7. **Azouz EM, Slomic AM, et al.** The variable manifestations of dysplasia epiphysealis hemimelica. *Pediatr Radiol* 1985;15:44-49.

Figure 6A

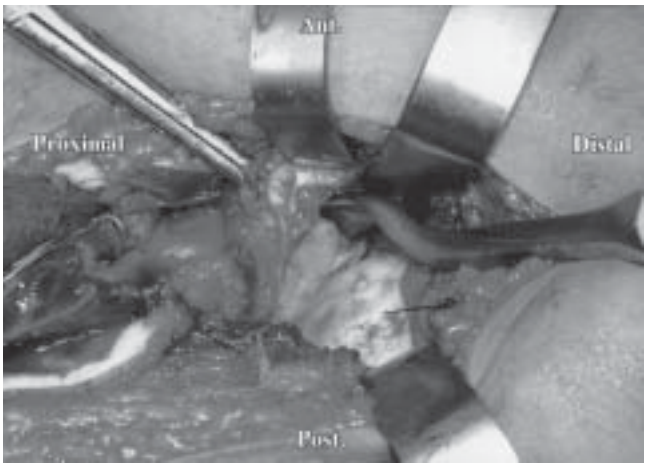

Figure 6B

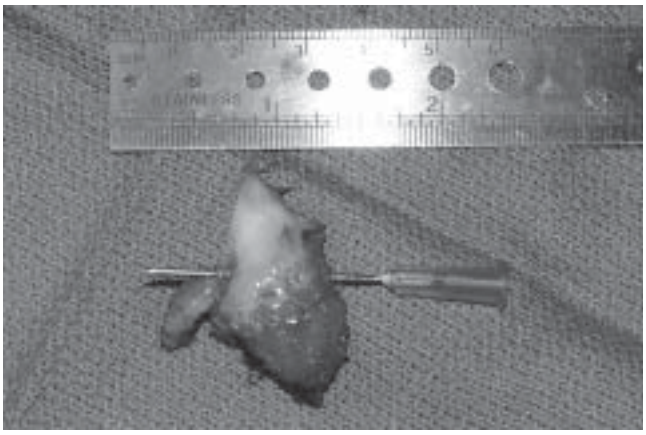

Figure 6C

Figure 6. (A) Intra-operative fluoroscopy view demonstrating the extent of the osteochondroma. (B) Surgical removal using gouges, taking care to leave as much articular cartilage as possible intact. (C) Gross specimen.

8. **Bleshman MH and Levy RM.** An unusual location of an osteochondroma. *Radiol* 1978;127:456-63.
9. **Cruz-Conde R, Amaya S, et al.** Case report: dysplasia epiphysealis hemimelica. *J Pediatr Orthop* 1984;4:625-29.
10. **Sherlock DA and Benson MKD.** Dysplasia epiphysealis hemimelica of the hip: a case report. *Acta Orthop Scand* 1986;57:173-75.
11. **Mendez AA, Keret D, et al.** Isolated dysplasia epiphysealis hemimelica of the hip joint: a case report. *J Bone Joint Surg* [Am] 1988;70:921-25.
12. **Woodward MN, Daly KE, et al.** Subluxation of the hip joint in multiple hereditary osteochondromatosis: report of two cases. *J Pediatr Orthop* 1999;19:119-21.
13. **Skaggs DL, Moon CN, et al.** Dysplasia epiphysealis hemimelica of the acetabulum: a report of two cases. *J Bone Joint Surg* [Am] 2000;82:409-14.
14. **Tschauner C, Roth-Schiffl E and Mayer U.** Early loss of hip containment in a child with dysplasia epiphysealis hemimelica. *Clin Orthop* 2004;427:213-19.
15. **Silverman FN.** Dysplasia epiphysealis hemimelica. *Semin Roentgenol* 1989;24:246-58.
16. **Keret D, Spatz DK, et al.** Dysplasia epiphysealis hemimelica: diagnosis and treatment. *J Pediatr Orthop* 1992;12:365-72.
17. **Murphey MD, Choi JJ, et al.** Imaging of osteochondroma: variants and complications with radiologic-pathologic correlation. *AFIP Archives* 2000;20:1407-34.

Figure 7A

Figure 7B

Figure 7C

Figure 7. (A) Immediate post-operative x-ray. (B) One year post-operative AP pelvis radiographs demonstrate improved coverage with maintained joint space. The triple innominate osteotomy plus femoral osteotomy have provided hip stability. (C) Three-year and four-month follow-up films demonstrate the right hip to be well located in the joint with the joint space maintained and no evidence of recurrence. The patient is currently asymptomatic and participating in all activities without restriction.

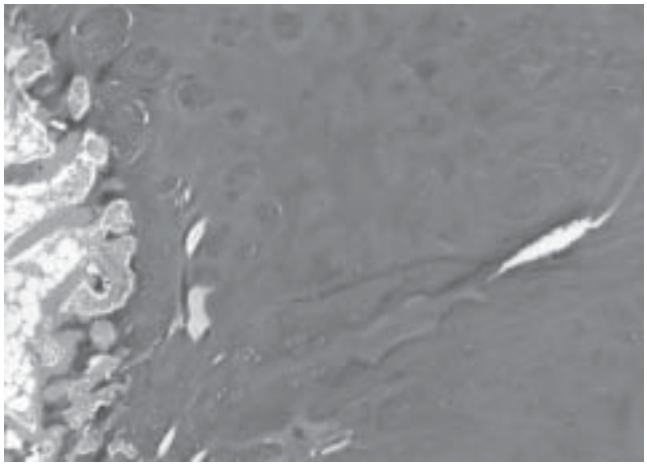

Figure 8. Pathologic specimen demonstrating cartilage cap with underlying bone consistent with a diagnosis of osteochondroma.

CASE REPORT: UNUSUAL TIBIA INTRAMEDULLARY OSTEOID OSTEOMA IN A TWO-YEAR-OLD

Matthew A. Halanski, M.D.; David C. Mann, M.D.

ABSTRACT

In this report, we discuss a case of a 30-month-old male presenting with a painful limp. Plain radiographic studies gave a preliminary diagnosis of a Brodie abscess. Further studies, including magnetic resonance imaging (MRI), were more consistent with that of an osteoid osteoma located within the tibial medullary canal, which is a rare location. The patient had an excisional biopsy. The final pathologic diagnosis confirmed intramedullary osteoid osteoma.

INTRODUCTION

The cause of limp in a child may be a result of trauma, infection or neoplasm. If findings on plain radiographs are consistent with infection or neoplasm, further non-invasive studies may be warranted prior to any surgical intervention. Potential diagnoses include osteoblastoma, osteomyelitis, eosinophilic granuloma, osteogenic sarcoma, Ewing sarcoma or healing fracture. While studies such as computerized tomography (CT) scans, MRI, or bone scan may help delineate these lesions, a final diagnosis frequently requires a pathologic specimen.

CASE REPORT

A 30-month-old male patient presented to our pediatric orthopedic clinic with a two-to-three-month history of right leg pain. The mother reported mild relief of pain with acetaminophen during the day and ibuprofen at night. She denied any recent trauma. The patient's medical history was significant for craniofacial reconstruction for craniosynostosis at the age of nine months, and slightly delayed motor development. Physical exam showed symmetric non-tender lower extremities with normal strength and sensation. No leg-length discrepancy was noted. The patient was ambulatory with an antalgic gait. He localized the pain to the distal aspect of his right lower extremity. Initial plain radiographs of the right lower extremity were normal. The patient was given a fracture boot for comfort.

Figure 1A. Lateral radiograph

Figure 1B. AP radiograph

At his one-month follow up appointment, the patient had increasing pain. His mother reported frequent falls and stated that he often held his ankle complaining of pain. His limp had progressed with a diminished stance phase on the right limb. Repeat radiographs revealed a lesion of localized sclerosis with central lucency within the distal tibial diaphysis (Figures 1A and 1B). This was consistent with a Brodie abscess, a region of chronic localized osteomyelitis. An MRI with intravenous contrast was performed to further delineate this lesion. On T1- and T2-weighted images of the distal tibial diaphysis, a centrally placed 5mm x 4mm x 16mm area

Correspondence:
David Mann, M.D.
Department of Orthopedics and Rehabilitation
University of Wisconsin College of Medicine
K4/731 Clinical Science Center
600 Highland Avenue—UWHC
Madison, Wisconsin 53792
(608) 263-1344

Figure 2A. Sagittal T1 MRI

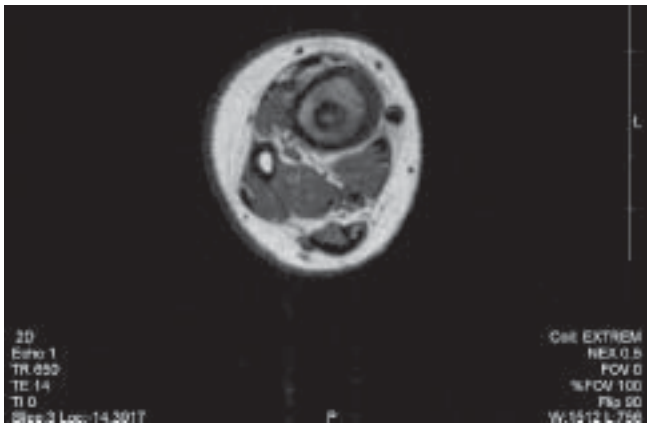

Figure 2B. Axial T1 MRI

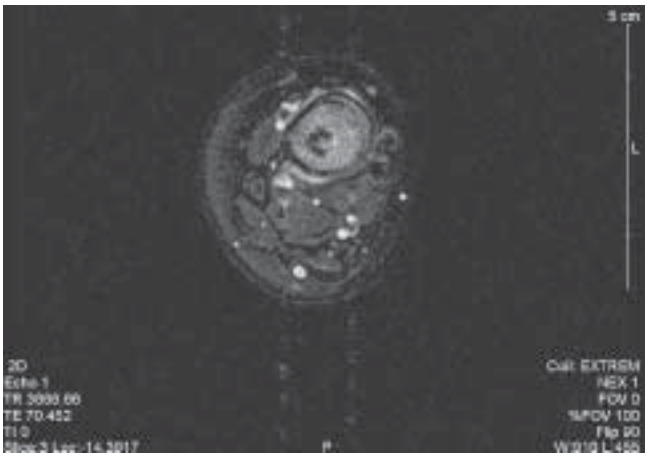

Figure 3A. Axial T2 MRI

Figure 3B. Coronal post-contrast MRI

of decreased signal intensity was identified (Figures 2 and 3). This lesion was associated with bone marrow edema and peripheral enhancement; however, there was no fluid collection or soft tissue mass present. While this lesion was in an unusual location, it was more consistent with osteoid osteoma. The patient underwent an open excisional biopsy of the lesion. The nidus, with surrounding sclerotic bone, was excised. The cavity was then filled with demineralized bone matrix. Final pathologic specimen analysis confirmed the diagnosis of osteoid osteoma. Post-operatively the patient was placed into a short-leg cast and allowed to bear weight as tolerated. At his one-month follow-up, the patient had no pain or recurrence of his symptoms.

DISCUSSION

Osteoid osteoma is a common benign bone lesion in the pediatric and young adult populations. Typical age of patients ranges from five to 40 years old, with reports of patients from nine months to 77 years of age reported in the literature.[6] Males are more commonly affected at a 1.6–4 ratio.[3] Long bones are the most common location for these lesions with the majority occurring in the lower extremity.[7] Presenting symptoms in children are often pain, which is worse at night and relieved with salicylates,[3] and a noticeable limp.[6]

The location of these lesions within the bone may vary. The classic and most common location is within the cortex.[7,8] These lesions have also been found in the periosteal region of long bones.[7] Children can have lesions involving the epiphyses of long bones. In all patients, the intramedullary location within bone is relatively infrequent, 2/38 in one study and 6/67 in another.[7,8] In our review of the literature, only one report of two intramedullary osteoid osteomas in young pediatric patients was described, in the French litera-

ture.[5] Similar to our patient, both of these patients in the literature were under 3 years of age, and the lesions were in the distal tibia. However, unlike our patient, the two in the literature had reactive bone formation more characteristic of cortical lesions.

The differential diagnosis of an osteoid osteoma includes osteoblastoma, osteomyelitis, eosinophilic granuloma, osteogenic sarcoma, Ewing sarcoma or healing fracture. Typical radiographic findings are of a dense ivory-like sclerotic mass attached to the bone with sharply demarcated borders.[4] When localized in the cortex, these lesions often evoke a reactive sclerosis; however, intramedullary lesions often fail to elicit such a response.[8] Further delineation can be obtained using computerized tomography (CT) scan or MRI. CT scans generally show a small lucent nidus surrounded by reactive sclerosing bone, sometimes seen on plain films.[2] Visualizing the nidus by MRI can be difficult, and intramedullary soft tissue changes may produce a misleading aggressive appearance.[1] Typically, an intermediate signal is seen on T1 and a high-intensity signal on T2-weighted images. Low-intensity signal within the nidus on T2 images suggests calcification.[2]

Treatment options for an osteoid osteoma include prolonged non-steroidal anti-inflammatory drug (NSAID) use, CT-guided ablation and surgical excision.[3] In this case, we chose surgical excision. While prolonged NSAID use has been shown to be effective, we were uncomfortable placing a two-year-old on long-term non-steroidal medication due to skeletal and renal complications. Likewise, CT-guided ablation could have been performed and this is done regularly at our institution. However, performing this on a two-year-old would have required anesthesia during the procedure. Therefore, we proceeded with an open excisional biopsy performed under the controlled environment of the operating room. This allowed for an adequate tissue sample to be sent for pathology and direct visualization of the nidus, helping to ensure complete excision.

In this case, we present a rather common pathologic lesion, osteoid osteoma, found at an atypical age, 30 months, in an uncommon location, within the medullary canal of the distal tibia. Because this lesion did not have the common reactive sclerosis often seen in cortical osteoid osteomas, diagnosis is more difficult.

The cause of pain in a limping child can often be difficult to discern. Osteoid osteoma should be kept in mind as a source of pain in the pediatric age group, with or without “classic” radiographic features.

REFERENCES

1. **Assoun J, Richardi G, Railhac JJ et al.** Osteoid Osteoma—MR-Imaging Versus CT. *Radiol* 1994; 191:217-23.
2. **Azouz EM.** Magnetic resonance imaging of benign bone lesions: cysts and tumors. *Top. Magn Reson. Imaging* 2002; 13:219-29.
3. **Frassica FJ, Waltrip RL, Sponseller PD, Ma LD, and McCarthy EF.** Clinicopathologic features and treatment of osteoid osteoma and osteoblastoma in children and adolescents. *Orthop Clin North Am* 1996; 27:559.
4. **Greenspan A.** Benign Bone-Forming Lesions—Osteoma, Osteoid Osteoma, and Osteoblastoma—Clinical, Imaging, Pathological, and Differential Considerations. *Skeletal Radiol* 1993; 22:485-500.
5. **Jawish R, Kassab F, Kairallah S, and Rizk R.** Intramedullary diaphyseal osteoid osteoma in children. *Revue de Chirurgie Orthopedique et Reparatrice de l Appareil Moteur* 1997; 83:74-7.
6. **Kaweblum M, Lehman WB, Bash J, Strongwater A, and Grant AD.** Osteoid Osteoma Under the Age of 5 Years—The Difficulty of Diagnosis. *CORR* 1993; 218-24.
7. **Kayser F, Resnick D, Haghighi P et al.** Evidence of the subperiosteal origin of osteoid osteomas in tubular bones: Analysis by CT and MR imaging. *Am J Roentgenol* 1998; 170:609-14.
8. **Klein MH and Shankman S.** Osteoid Osteoma—Radiologic and Pathological Correlation. *Skeletal Radiol* 1992; 21:23-31.

UNICAMERAL BONE CYSTS OF THE PELVIS: A STUDY OF 16 CASES

Sommer Hammoud, BS[1], Kristy Weber, MD[3,4], Edward F. McCarthy, MD [2,3]

ABSTRACT

Unicameral bone cysts of the pelvis are extremely rare. This study summarizes the clinical, radiologic and pathologic features of 16 cases. Patients ranged in age from nine to 69. Most lesions were in the anterior portion of the iliac wing; many appeared to be related to an open iliac crest apophysis. This suggests that the pathogenesis of unicameral bone cysts in this portion of the ilium is similar to that seen in the proximal humerus and the proximal femur. The correct diagnosis was made preoperatively in only five cases. This indicates that, although they are well documented, unicameral bone cysts of the pelvis remain a diagnostic problem. Patients received a spectrum of treatments from curettage to observation. There appeared to be no difference in the outcome after any form of treatment. Therefore, unicameral bone cysts of the pelvis can be managed conservatively. The choice to manage patients conservatively depends on making the correct diagnosis based on clinical history and imaging. The most effective imaging is a combination of plain radiographs, computed tomography (CT) and magnetic resonance imaging (MRI).

[1]Johns Hopkins University School of Medicine
[2]Department of Pathology
[3]Department of Orthopaedic Surgery
[4]Department of Oncology

Each author certifies that he or she has no commercial associations (e.g. consultancies, stock ownership, equity interest, patent/licensing arrangements, etc.) that might pose a conflict of interest in connection with the submitted article.

Each author certifies that his or her institution has approved the reporting of this case series, that all investigations were conducted in conformity with ethical principles of research, and that informed consent was obtained.

Correspondence:
Edward F. McCarthy, MD
Department of Pathology
Division of Surgical Pathology
The Harry & Jeanette Weinberg Building
401 N. Broadway/Room 2242
Baltimore, MD 21231-2410
Phone: 410-614-3653
Fax: 410-614-3766
E-mail: mccarthy@jhmi.edu

INTRODUCTION

Unicameral bone cysts, also known as simple bone cysts, are relatively common bone lesions that usually occur in the proximal femur or proximal humerus in the developing skeleton. Very rarely, a unicameral bone cyst may form in the pelvis. Because of their rarity, lesions in the pelvis are often misdiagnosed and overtreated. This paper summarizes the clinical, radiographic and pathologic features of sixteen cases of unicameral bone cysts of the pelvis, collected over a thirty-year period.

METHODS

The 16 patients were either collected from the orthopaedic surgery files of the Johns Hopkins Hospital or culled from the personal consultation files of one of us (EFM) (Table1). Plain radiographs of the pelvis were available on all 16 patients. Thirteen patients had either CT scans or MRI studies or both. Histological material from 12 patients was available for review.

RESULTS

Patients ranged in age from nine to 69 years. The mean age was 30 years. Six patients were age 20 or younger. There were ten females and six males.

Fourteen lesions occurred in the ilium. One was in the pubic ramus, and one was in the ischium. Of the 14 lesions in the ilium, 11 were present in the iliac wing. Five patients had cysts in the posterior part of the ilium adjacent to the sacroiliac joint. These posterior lesions occurred in the older group of patients.

These patients' symptoms varied. Two patients had dull, aching pain probably directly related to their cysts. Two patients had pain after minor trauma to the ilium. One patient suffered a pathologic fracture of the lesion after a fall. In eight patients, lesions were discovered incidentally during evaluation for other symptoms such as back pain or hip pain. The clinical presentation was unclear in the remaining three patients.

Nine patients had curettage of their lesions. In one of these patients, the lesion was filled with bone graft. Three patients had only a biopsy. One patient had drill holes placed, and another had a needle aspiration. Two patients were observed only and had no surgical intervention.

TABLE 1
Simple Bone Cysts of the Pelvis

Case	Age/ Sex	Location	Presentation	Preoperative Diagnosis	Treatment	Years of Follow Up
1	9F	Left ilium	Asymptomatic	Fibrous dysplasia	No treatment	1
2	14F	Left ilium	Vague discomfort after trauma	Simple cyst	Aspiration	8 weeks
3	15M	Left ilium	Pathologic fracture after fall	Aneurysmal bone cyst	Biopsy and curettage	2
4	16F	Right ilium	Incidental finding	Simple cyst	Biopsy and curettage	4
5	17M	Right ischium	Incidental finding	Fibrous dysplasia	No treatment	1
6	20M	Left ilium	Unclear	Aneurysmal bone cyst	Biopsy only	1
7	26F	Right ilium	Vague pain after trauma	Fibrous dysplasia	Curettage, Re-curettage after 21 years	25
8	27F	Right ilium; posterior	Incidental finding Back pain	Simple cyst	Drill holes	8 months
9	33F	Left ilium	Vague dull pain	Aneurysmal bone cyst	Biopsy curettage	3
10	36M	Right ilium; posterior	Vague dull pain	Simple cyst	Curettage	2
11	43F	Left ilium	Hip pain	Fibrous dysplasia	Biopsy partial excision	3
12	48F	Right ilium; posterior	Incidental finding	Neoplasm	Cyst removed	2
13	48F	Pubic ramus	Incidental finding	Simple cyst	Curettage	3
14	48M	Right ilium; posterior	Unclear	Aneurysmal bone cyst	Needle aspiration	2
15	52M	Right ilium	Unclear	Neoplasm	Curettage	1
16	69F	Right ilium; posterior	Asymptomatic	Neoplasm	Biopsy only	1

In the seven patients who had no treatment, a biopsy only, or drilling, the follow-up was one year or less. Eight of the patients who were treated with curettage were followed from one to four years. One patient had a second curettage 21 years after the first.

Radiographic Findings

On plain radiographs, lesions were well-circumscribed lytic zones ranging in size from 3 to 12 cm. One lesion occupied almost the entire iliac wing (Figure 1). Most lesions had a faint sclerotic rim (Figure 2). Some lesions had a soap-bubble type appearance (Figure 3). These inner markings corresponded to ridges on the inside of the cysts as seen best on the CT scan. These were seen more frequently in older patients, suggesting attempted spontaneous healing (Figure 4). On CT scans, lesions showed no or minimal expansion of the wall of the pelvis. CT scans demonstrated that lesions were either in the anterior iliac wing or posterior, adjacent to the sacroiliac joint. The posterior location was more prevalent in older patients (Figure 5A and B). Except for a few cases with inner trabeculations, all lesions were unilocular. On T2-weighted MRI studies, lesions showed a uniform high signal corresponding to fluid (Figure 6). There were no fluid-fluid lines typical of aneurysmal bone cyst.

Based on these radiographic features, the diagnosis of unicameral bone cyst was made in only five patients. The diagnosis of fibrous dysplasia was made in five cases, and aneurysmal bone cyst was suspected in three patients. In three patients, the lesion was diagnosed as a neoplasm. The correct diagnosis was made when the lesions were studied with a combination of plain radiographs, CT scans and MRI.

Histopathologic Findings

Tissue was available for study from 12 patients. Tissue was obtained at curettage or from an open biopsy. In all cases where surgery had been performed, the surgeon reported the lesion to be filled with clear serosanguineous fluid. The biopsy showed a fibrous membrane with varying amounts of reactive bone (Figure 7). In several cases, a fluffy material was present in the fibrous wall (Figure 8). This was identical to the char-

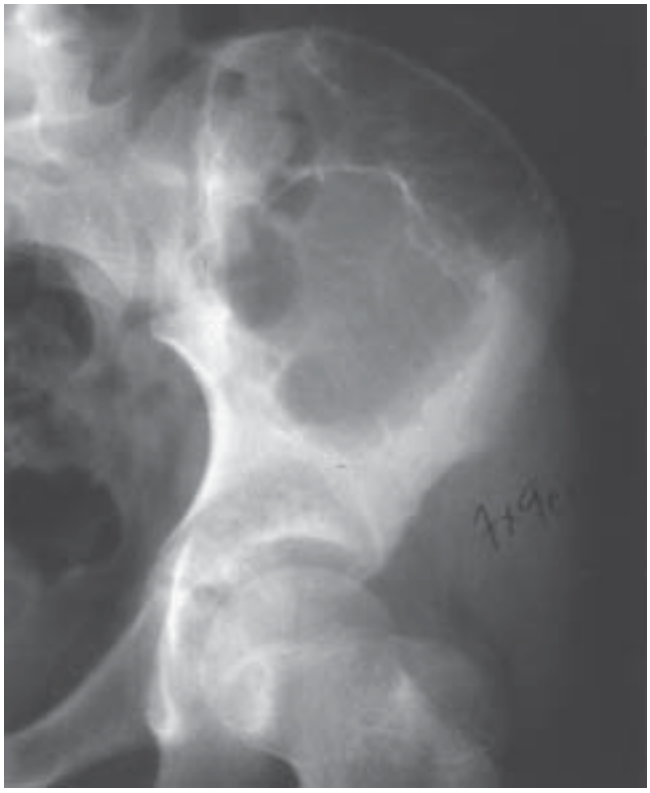

Figure 1. Plain radiograph of a unicameral bone cyst of the iliac wing from patient number one. This lesion occupies most of the iliac wing and was asymptomatic.

Figure 2. This unicameral bone cyst of the left ilium from patient number two has a faint sclerotic rim (arrows).

acteristic cementum-like material seen in the walls of typical unicameral bone cysts of the proximal humerus or proximal femur.[1]

DISCUSSION

A unicameral bone cyst is a unilocular cavity in bone, lined by a fibrous membrane and filled with fluid. The lesion almost always arises in the metaphysis of a long bone adjacent to an epiphyseal plate. The development of the lesion is related to skeletal growth. For a period of time bone does not form in the metaphysis and the defect fills with fluid. Eventually, bone formation recommences and normal medullary bone forms between the physis and the cyst. This normal zone lengthens as skeletal growth continues. The cause of this process is not known.

The first description of a unicameral bone cyst was by Virchow in 1876.[2] Although Bloodgood in 1910[3] wrote a detailed early report, it was not until 1942 that Jaffe and Lichtenstein characterized fully the clinical, radiographic and pathologic features of unicameral bone cysts.[4]

Although unicameral bone cysts may occur anywhere in the skeleton, two-thirds of cases occur either in the proximal humerus or proximal femur.[5] The pelvis is an uncommon site for the development of a unicameral cyst. This location accounts for only two percent of reported cases.[6] In 1975, Samuelson et al reported two cases, and summarized the 20 other cases documented at that time.[7] Since that summary, there have been isolated case reports.[8,9,10] In 1977, Norman and Schiffman reviewed 75 cases of simple bone cysts.[11] They noted that the nine cases which were in the pelvis occurred in older patients, and they suggested that the cysts developed later in life. More recently, however, Abdelwahab et al reported four cases of unicameral pelvic bone cysts in adolescents.[6] These authors concluded that in the pelvis, as in the long bones, cysts formed during skeletal development. Pelvic lesions may remain asymptomatic longer because they usually occur in non-weight-bearing portions of the ileum.

Figure 3. A unicameral bone cyst in the posterior portion of the ilium from patient number nine showing a multi-locular appearance. These internal markings are ridges on the inside of the cavity and suggest healing.

Figure 4. A unicameral bone cyst (arrow) from patient number seven in the right iliac wing showing changes suggestive of healing.

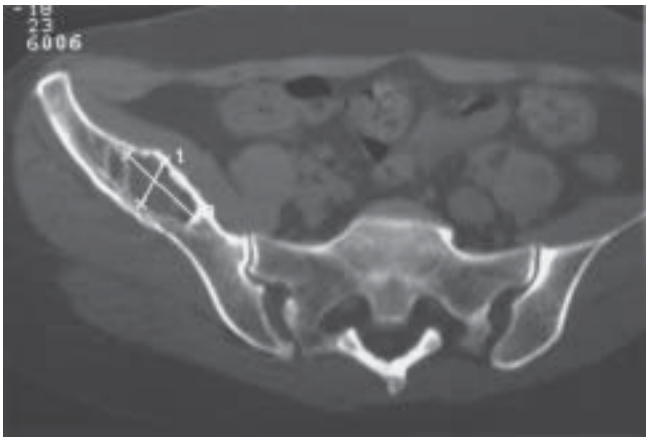

Figure 5A. CT scan of the left ilium of patient number six showing a lesion with a single intralesional ridge. There is minimal expansion of the bone.

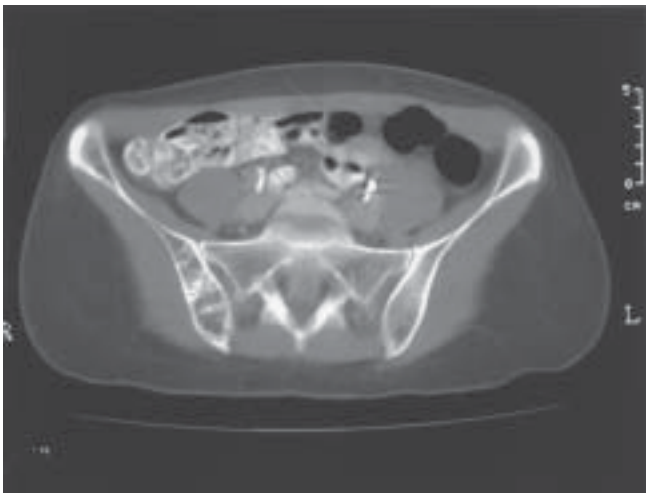

Figure 5B. CT scan of a unicameral bone cyst in the posterior portion of the ilium from patient number ten. Internal marking suggest healing.

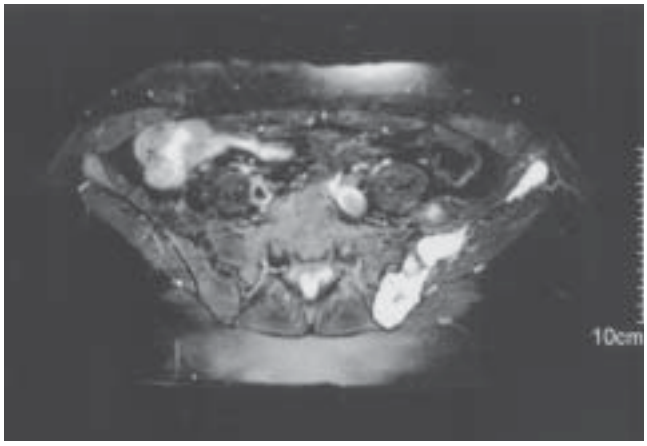

Figure 6. T2–weighted MRI scan of the unicameral bone cyst of patient number 15. There is uniformly high signal throughout much of the iliac wing. This high signal represents fluid, and there is no cortical expansion or fluid-fluid line.

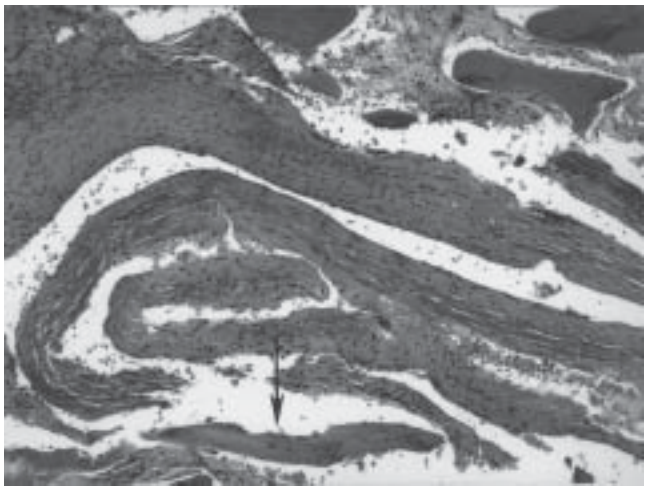

Figure 7. A low-powered photomicrograph (H&E, x20) of the fibrous membrane curetted from a pelvic unicameral bone cyst. Some reactive bone is present in the membrane (arrow).

In the present series of 16 cases, lesions were diagnosed in both young and older patients. In the adolescent group, more lesions occurred adjacent to an open iliac crest apophysis. This suggests that the pathogenesis of unicameral bone cysts in the ilium is similar to that of lesions in the proximal humerus and femur. Five of our cyst cases occurred in the posterior portion of the ilium adjacent to the sacroiliac joint in an older age group, and may represent subchondral cysts related to sacroiliac joint degeneration. Two of our cyst cases had atypical locations, one in the pubis and one in the ischium. Because they were unilocular and filled with fluid, we regarded them as unicameral bone cysts.

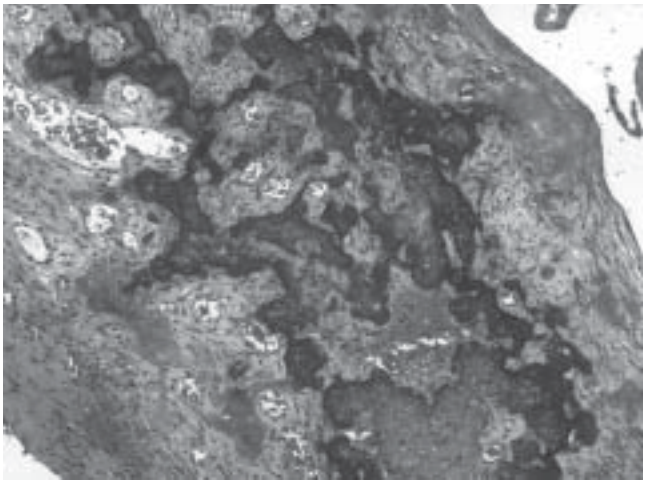

Figure 8. A high-powered photomicrograph (H&E, x40) of the fibrous membrane. There is fluffy, cementum-like material in the wall. This material is highly characteristic of unicameral bone cysts.

The study of these 16 cases emphasizes several points. First, despite previous documentation of unicameral cysts in the pelvis, this lesion remains a diagnostic problem. The correct diagnosis was made preoperatively in only five cases. The most frequent misdiagnoses were fibrous dysplasia and aneurysmal bone cyst. An MRI demonstrating intralesional fluid should rule out fibrous dysplasia. The absence of cortical expansion and multiple locules with fluid-fluid lines rules out aneurysmal bone cyst.

The second point is that the frequent misdiagnosis leads to overtreatment. Follow-up indicates that patient outcomes are the same whether lesions are curetted, drilled or observed. Whether treated or not, cystic cavities persist in the pelvis and remain asymptomatic. Because the pelvis is a non-weight-bearing bone, these lesions do not threaten the integrity of the skeleton. This suggests that unicameral bone cysts of the pelvis may require no surgical intervention. Symptomatic lesions may be treatable with drill holes similar to proximal humeral lesions. Lesions in older patients tended to have more intralesional trabeculations suggesting spontaneous healing. Therefore, the correct preoperative diagnosis is critical to avoid overtreatment.

These cases indicate that simple cysts of the pelvis are most accurately diagnosed with a combination of plain radiographs, CT scans and MRI. Once the diagnosis is established, lesions may be best managed conservatively.

REFERENCES

1. **Mirra JM, Bernard GW, Bullough PG, Johnston W, Mink G:** Cementum-like bone production in solitary bone cysts (so-called "cementoma" of long bones). Report of three cases. Electron microscopic observations supporting a synovial origin to the simple bone cyst. *Clin Orthop* 1978; 135:295-307.
2. **Virchow R:** Ueber die bildung von knochencysten. *Monatsber d Kgl Akad D Wissenschaften*, Sitzung der Phisikalischen-mathemat Klasse vom 12 Juni, 1876.
3. **Bloodgood JC:** Benign bone cysts, osteitis fibrosa, giant cell sarcoma and bone aneurysm of the long pipe bones. A clinical and pathological study, with the conclusion that conservative treatment is justifiable. *Ann Surg* 1910; 52:145.
4. **Jaffe H, Lichtenstein L:** Solitary unicameral bone cyst. *Arch. Surg* 1942; 44:1004.
5. **Boseker E, Bickel W, Dahlin D:** A Clinicopathologic Study of Simple Unicameral Bone Cysts. *Surg Gynec and Obstet* 1968; 127: 550-560.
6. **Abdelwahab IF, Hermann G, Norton KI, et al:** Simple bone cysts of the pelvis in adolescents. A report of four cases. *J Bone Joint Surg* (Am) 1991; 73(7):1090-1094.
7. **Samuelson KM, Momberger GL, Coleman SS:** Solitary bone cyst of the ilium. Report of two cases and a review of the literature. *Rocky Mt Med J* 1975; 72(10):443-445.
8. **Blumberg ML:** CT of iliac unicameral bone cysts. *AJR Am J Roentgenol* 1981; 136:1231-1232.
9. **Baker DM:** Benign unicameral bone cyst. A study of forty-five cases with long-term follow up. *Clin Orthop* 1970; 71:140-151.
10. **Wray CC:** Unicameral bone cyst of the ilium. *J R Coll Surg Edinb* 1986; 31(4):233-236.
11. **Norman A, Schiffman M:** Simple bone cysts: factors of age dependency. *Radiology* 1977; 124(3):779-782.

SEVERE PERIPROSTHETIC CORTICAL ATROPHY IN THE SKELETALLY IMMATURE: A REPORT OF THREE CASES

Kevin B. Jones, M.D. and Joseph A. Buckwalter, M.S., M.D.

ABSTRACT

We describe three patients who developed cortical bone atrophy around cemented endoprostheses used for partial femur reconstructions after resection of Ewing's sarcoma. We believe this to be related to remodeling secondary to stress-shielding. Rather than increased porosity and decreased mineral density, the stress-shielding in these skeletally immature patients resulted in altered morphology of the cortical bone, with apparent maintenance of density.

INTRODUCTION

Stress-shielding is a well-recognized phenomenon associated with many clinical scenarios in which an implant with higher elastic modulus than bone bears the majority of stress transmitted through an anatomic region by fixation to bone above and below. This prevents the load bearing necessary for osseous homeostasis, and thus encourages a disuse-type osteopenia in the accompanying bone. It is most widely discussed in relation to diaphyseal fit designs for noncemented total hip arthroplasty, but is recognized in many other scenarios including external and internal fixation for fractures and cemented hip arthroplasty. Stress-shielding usually results in osteopenia, or an atrophy of bone mineral and trabecular density, rather than an atrophy of bone morphology overall.

We present three skeletally immature patients who developed peri-implant cortical atrophy following endoprosthetic reconstructions for bone defects created by resection of malignant neoplasms.

Department of Orthopaedics and Rehabilitation,
University of Iowa Hospitals and Clinics,
Iowa City, Iowa, U.S.A.

Correspondence:
Kevin B. Jones, M.D.
Department of Orthopaedics and Rehabilitation
University of Iowa Hospitals and Clinics
Pappajohn Pavilion, Lower Level, 01051
200 Hawkins Drive
Iowa City, Iowa 52242
Phone: 319-356-2595
Fax: 319-356-8889
E-mail: kevin-jones@uiowa.edu

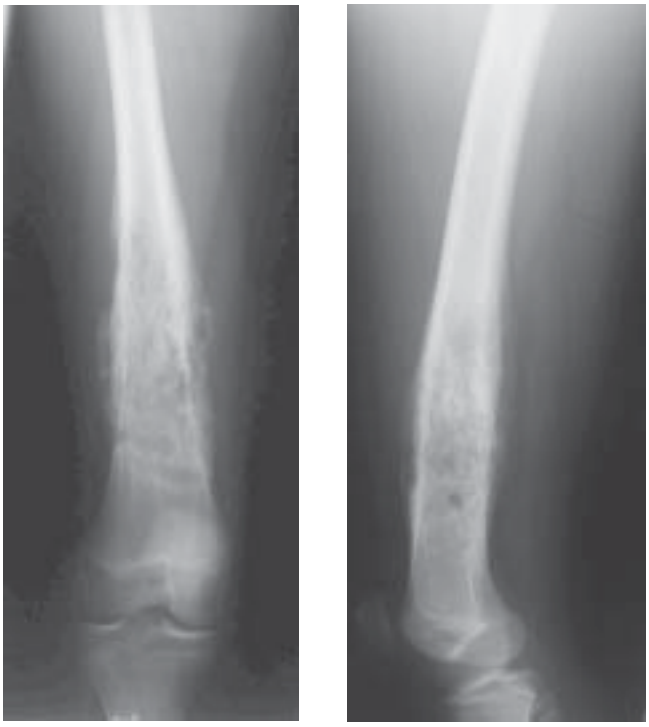

Figure 1. AP and lateral radiographs of the distal femur in case 1, a 13-year-old female with Ewing's sarcoma.

PATIENTS

Case 1

The first patient was diagnosed with a Ewing's sarcoma of the distal femur at 13 years of age (Figure 1). She was treated with neo-adjuvant and adjuvant chemotherapy, resection and cemented endoprosthetic reconstruction of her distal femur and knee (Figures 2A and 2B). She developed no recurrence and returned to excellent function after reconstruction. Over time, however, the periprosthetic cortical bone atrophied (Figures 2C and 2D). The patient continues to have excellent knee function without fracture or failure, eight years after her resection. She has declined repeated encouragements to consider prophylactic onlay reinforcement of the atrophied implant-bone junction.

Figure 2A

Figure 2B

Figure 2C

Figure 2D

Figure 2. AP and lateral radiographs of the distal femoral endoprosthetic reconstruction after resection of a Ewing's sarcoma (case 1). Panels A and B were obtained one month after resection and reconstruction; panels C and D were obtained eight years after reconstruction.

Figure 3. AP and lateral hip radiographs demonstrating the pathologic proximal femur fracture through a Ewing's sarcoma in a ten-year-old (case 2).

Case 2

The second patient presented at 10 years of age with a pathologic subtrochanteric femur fracture through a Ewing's sarcoma (Figure 3). The fracture punctuated a two-month history of thigh pain treated conservatively for a presumptive diagnosis of Osgood-Schlatter after knee imaging showed no abnormality.

An open biopsy was obtained and the fracture internally fixed with a pediatric hip screw prior to neoadjuvant chemotherapy (Figure 4). Her resection demonstrated negative mar-

Figure 4. AP radiographs demonstrating the reduced and internally fixed pathologic fracture after biopsy confirming Ewing's sarcoma in a ten-year-old (case 2).

Figure 5A

Figure 5B

Figure 5C

Figure 5D

Figure 5. AP and lateral radiographs of the proximal femur shortly following (A and B) and three years after (C and D) resection of a Ewing's sarcoma and reconstruction with a proximal femur-replacing endoprosthesis.

gins and excellent necrosis response to chemotherapy. She was also reconstructed with a cemented modular endoprosthesis (Figures 5A and 5B). Adjuvant chemotherapy was completed uneventfully. Treatments included Idamycin, Cytoxan, VP16, ifosfamide, and anthracycline.

Other than the anticipated limb-length discrepancy that developed with growth, the only concern that arose after full functional recovery was progressive and severe cortical atrophy (Figures 5C and 5D). She was first advised to undergo onlay strut allograft reinforcement of the bone-implant junction at two-and-one-half years after her resection and reconstruction. She agreed to proceed with this another year later (Figure 6). She continues to do well, now 18 months after the reinforcement surgery.

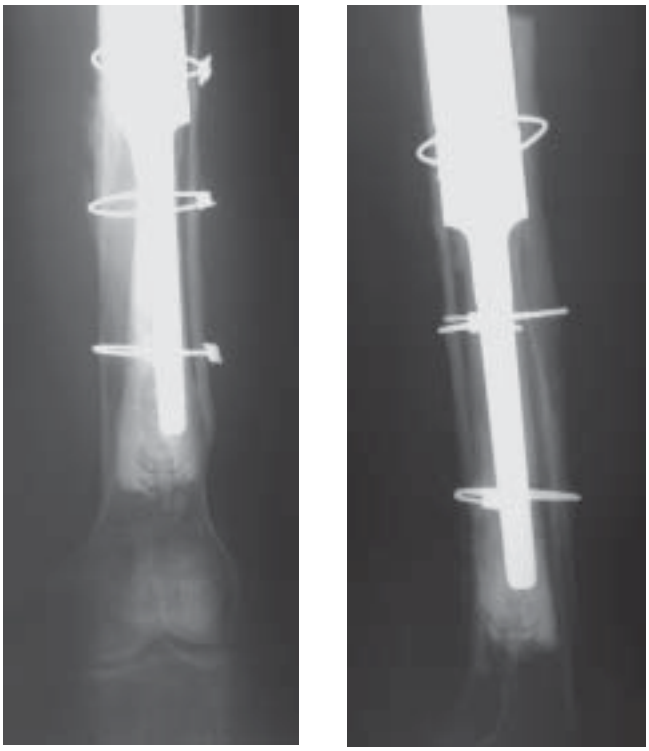

Figure 6. AP and lateral radiographs of the proximal femur demonstrating onlay allograft strut reinforcement of the prosthesis-bone junction, performed due to concern for severe periprosthetic cortical atrophy.

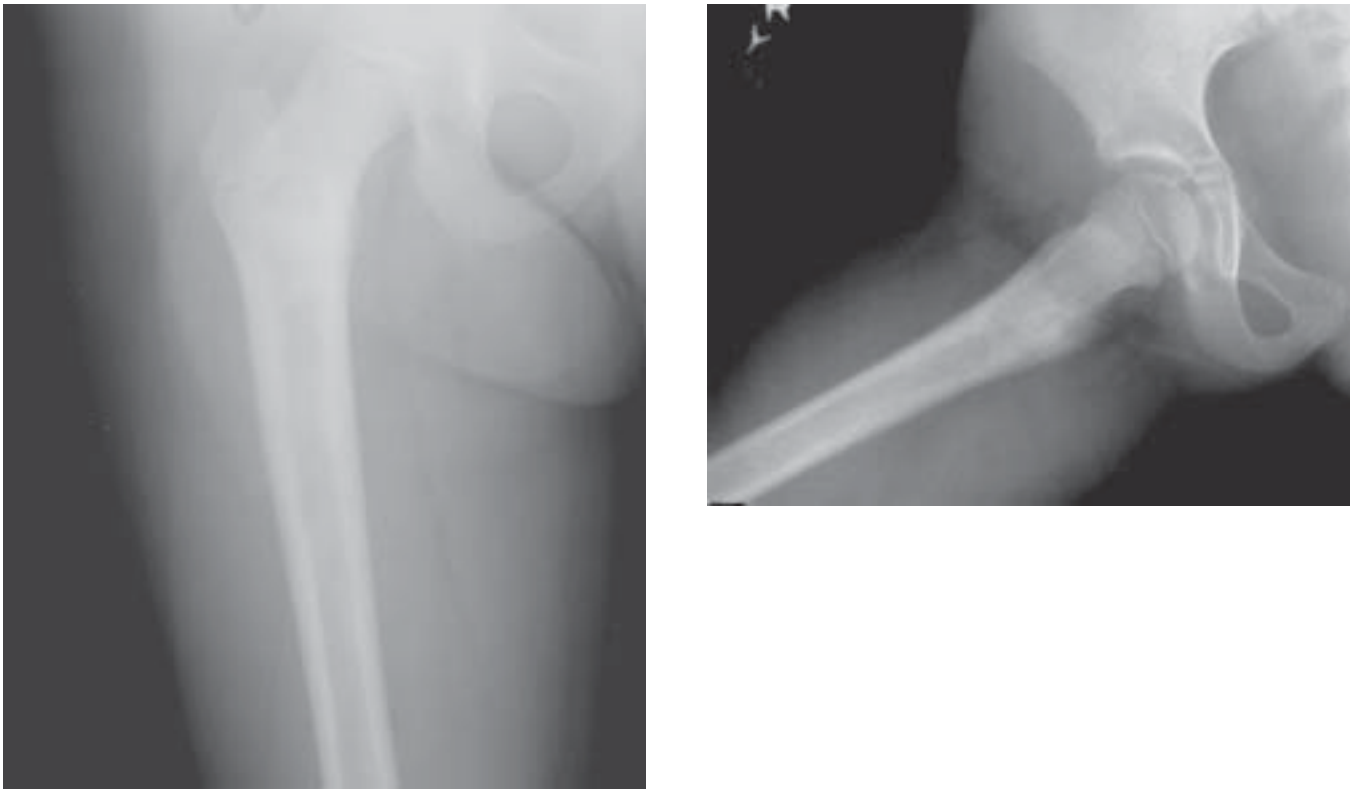

Figure 7. AP and lateral radiographs of the proximal femur demonstrating a Ewing's sarcoma of the trochanteric region and femoral neck in an eight-year-old female.

Case 3

The final patient presented at eight years of age with thigh pain and systemic illness. She was diagnosed with a proximal femoral Ewing's sarcoma and associated pulmonary metastatic disease (Figure 7). Treatment for the sarcoma included chemotherapy and radiation to both femur and thorax. A total of 5580 centi-Gray units (cGy) of external-beam radiation was administered to the proximal femur. Fifteen months later, she sustained a fracture through the irradiated bone, which was treated with pediatric hip screw prophylactic fixation (Figures 8A and 8B).

Five otherwise-uneventful years after the initial diagnosis, she developed a chondroblastic osteosarcoma in the previously irradiated proximal femur (Figures 8C and 8D). This was treated with neo-adjuvant and adjuvant chemotherapy, wide resection and cemented endoprosthetic proximal femoral reconstruction (Figures 9A and 9B).

Beginning approximately three years after her reconstruction, cortical atrophy at the implant-bone junction progressed to a worrisome degree. She was advised to consider onlay strut allograft reinforcement of the bone-implant junction but declined such an intervention.

At six years after her initial reconstruction, she sustained a catastrophic failure from minor trauma, sustaining a periprosthetic femur fracture and prosthetic stem fracture (Figures 9C and 9D). This was successfully treated with a revision modular hip prosthesis (Figure 10). She continues to do well, despite concern for insufficiently robust bone at the implant junction, now three years later.

Figure 8A

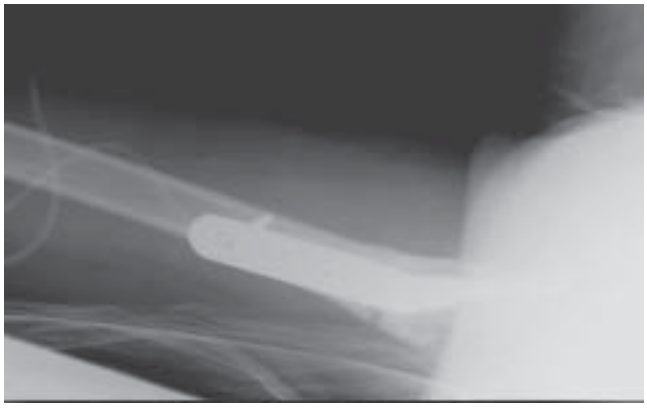

Figure 8B

Figure 8. AP and lateral radiographs (A and B) after open reduction and internal fixation of a subtrochanteric fracture that was sustained 15 months after diagnosis of Ewing's sarcoma, treated with external beam radiation. Panels C and D demonstrate the chondroblastic osteosarcoma that subsequently developed in the same region, another three-and-one-half years later.

Figure 8C

Figure 8D

Figure 9A

Figure 9B

Figure 9C

Figure 9D

Figure 9. AP and lateral radiographs demonstrating endoprosthetic reconstruction of the proximal femur after resection of a post-radiation chondroblastic osteosarcoma. Panels A and B represent early post-operative radiographs; C and D represent a periprosthetic fracture with prosthetic stem fracture sustained six years later.

DISCUSSION

Charnley first described the phenomenon of stress-shielding in his 1968 mid-term follow-up of 190 of his early cemented hip arthroplasties[1]. Stress-shielding was manifested in two radiographic features. Over one-third of his patients had radiographic resorption of two-to-three millimeters of the calcar femorale, separating it from the collar of the prosthesis and its initial abutting position. Second, just under five percent of his patients had developed greater than five percent relative atrophy of the peri-implant cortex. As understanding of stress-shielding increased over the years, it came to be specifically associated with loss of bone mineral density in the trochanteric region proximal to a well-fixed diaphyseal fit non-cemented prosthesis. It is interesting, however, that in Charnely's original description of the phenomenon, he used cortical thinning as his measure.

We reviewed three cases of significant peri-prosthetic cortical atrophy of the femoral diaphysis following cemented reconstruction with a modular tumor prosthesis in two adolescents and one pre-adolescent. The etiology remains uncertain, but excessive remodeling from stress-shielding is suspected.

Tumor recurrence should always be primarily ruled out when any osseous changes are noted after resection of a malignant neoplasm. This was considered carefully in each case. That it was appropriately ruled-out is evidenced by the continued event-free survival of all of the patients, years after recognition of the atrophy.

The magnitude of the stress-shielded remodeling response may be due to side effects of chemotherapy or even radiation (in case three, only), but the fact that the morphology of the cortical bone changed rather than porosity, argues that neither osteoblasts nor osteoclasts were relatively impaired. It is interesting that all three of the patients had Ewing's as a primary diagnosis, but this yields no obvious explanation of bone changes after disease eradication. Mostly likely, the well-recognized increased osteoclastic response to minimal load bearing secondary to stress-shielding is better matched in these skeletally immature patients by osteo-blastic recontouring of the shape of the cortical bone.

Periprosthetic bone remodeling has previously been studied by the oncology group in Toronto for distal femoral replacements with a noncemented Kotz prosthesis after resection of malignancies[2]. They demon-

Figure 10A

Figure 10C

Figure 10D

Figure 10B

Figure 10. AP and lateral radiographs of the proximal and distal femur demonstrating the revision endoprosthetic reconstruction undertaken to treat a periprosthetic fracture from a previous implant. Cortical atrophy around the new implant remains a concern.

strated that bone mineral density loss as measured by DEXA averaged 23.7 percent in the region immediately adjacent to the base of the prosthetic stem.

Whatever the explanation, cortical atrophy surrounding a modular implant increases a patient's risk for catastrophic failure of the implant. Such events require urgent, major surgery rather than the elective circumstances possible for prophylactic reinforcement. It will continue to be our practice to look for these changes radiographically and recommend prophylactic onlay strut allograft reinforcement when such atrophy is recognized.

REFERENCES

1. **Charnley J, Follacci FM, and Hammond BT.** The long-term reaction of bone to self-curing acrylic cement. *J Bone Joint Surg* Br. 1968 Nov;50(4):822-9.
2. **Lan F, Wunder JS, Griffin AM, Davis AM, Bell RS, White LM, Ichise M, Cole W.** Periprosthetic bone remodeling around a prosthesis for distal femoral tumours. Measurement by dual-energy X-ray absorptiometry (DEXA). *J Bone Joint Surg* Br. 2000 Jan;82(1):120-5.

JOINT CONTACT STRESS: A REASONABLE SURROGATE FOR BIOLOGICAL PROCESSES?

Richard A. Brand, M.D.

ABSTRACT

A joint's normal mechanical history contributes to the maintenance of articular cartilage and underlying bone. Loading facilitates the flow of nutrients into cartilage and waste products away, and additionally provides the mechanical signals essential for normal cell and tissue maintenance. Deleteriously low or high contact stresses have been presumed to result in joint deterioration, and particular aspects of the mechanical environment may facilitate repair of damaged cartilage. For decades, investigators have explored static joint contact stresses (under some more or less arbitrary condition) as a surrogate of the relevant mechanical history. Contact stresses have been estimated *in vitro* in many joints and in a number of species, although only rarely *in vivo*. Despite a number of widely varying techniques (and spatial resolutions) to measure these contact stresses, reported ranges of static peak normal stresses are relatively similar from joint to joint across species, and in the range of 0.5 to 5.0 MPa. This suggests vertebrate diarthrodial joints have evolved to achieve similar mechanical design criteria. Available evidence also suggests some disorders of cartilage deterioration are associated with somewhat higher peak pressures ranging from 1-20 MPa, but overlapping the range of normal pressures. Some evidence and considerable logic suggests static contact stresses per se do not predict cartilage responses, but rather temporal aspects of the contact stress history. Static contact stresses may therefore not be a reasonable surrogate for biomechanical studies. Rather, temporal and spatial aspects of the loading history undoubtedly induce beneficial and deleterious biological responses. Finally, since all articular cartilage experiences similar stresses, the concept of a "weight-bearing" versus a "non-weight-bearing" joint seems flawed, and should be abandoned.

INTRODUCTION

Clinicians have long suspected pressure affects cartilage. Heuter recognized the effects of pressure on growth cartilage of the developing joint.[59] However, the effects on mature cartilage were not well recognized until well into the twentieth century, when the role of loading on osteoarthrosis was clearly established. Ironically, the role of loading on the normal maintenance of cartilage was recognized after its potentially deleterious effects.

Lovett, in 1891 mentioned a mechanical role in osteoarthrosis primarily to suggest it was not important.[96] Pemberton and Osgood allude to the role of mechanics in osteoarthrosis to emphasize the importance of "carriage of the body," but do not explicitly mention overloading of cartilage as the critical factor.[118] Two other authors[45,75] writing about the same time suggested repeated mild trauma was causative, although neither explored or documented this concept. Substantive consideration of a mechanical role in joint degeneration primarily occurred after the mid twentieth century. We now recognize increased loading, and ostensibly contact stresses, on articular surfaces substantially affect the durability of joints and their responses to treatment.[16,24,46]

The notion that physiological loading and motion of joints are essential for normal maintenance (i.e., metabolism) paradoxically appear to arise from observations that osteoarthritis begins in areas of the joint which were least loaded[53] and that immobilization leads to alterations in cartilage metabolism[103,142] and histology[37] of articular cartilage. Harrison et al. remarked, "Our somewhat surprising findings forced us to consider that if excess of joint pressure is deleterious to hyaline cartilage the lack of pressure is an even more compelling cause of its degeneration."[53] Thus, not only overloading, but also underloading appeared related to deleterious changes. However, *in vivo* contact stresses are typically related to motion, and the importance of motion in normal maintenance of cartilage[22,41,132] and in cartilage repair[22,55,80,131,143] is now a well accepted notion.

Correspondence:
Richard A. Brand, M.D.
Editor-in-Chief
Clinical Orthopaedics & Related Research
3550 Market St., Suite 220
Philadelphia, PA 19104
Phone: 215-349-8375
FAX: 215-349-8379
E-mail: dick.brand@clinorthop.org

Because biological changes are initiated at the local tissue level (i.e., small gross, or even microscopic level), any relevant mechanical parameter relating to tissue adaptation likely needs to be independent of area or volume of tissue or at least averaged over a very small region. That is, spatial resolution of the measures becomes a critical (although obviously question-dependent) issue. For intuitive reasons, and without any explicit consideration of this latter point, most investigators quite naturally turned to joint contact stresses as a single mechanical surrogate reflecting biological behavior.[i] In earlier studies spatially averaged contact stress was a parameter that could be readily calculated if the load and surface area were known. Methods to estimate contact stresses and their spatial distributions (with varying degrees of spatial resolution) arose only in the latter part of the twentieth century.

In this report, then, I will explore what is known about contact stresses in human and animal joints. First I will briefly describe the methods to estimate contact stresses, then I will review the quantitative estimates made by those methods, and finally I will explore the limitations of contact stress as a parameter to explain or predict clinical disease. While I do not intend a comprehensive review, it is intended to be representative.

METHODS TO ESTIMATE CONTACT STRESSES

There are a limited number of ways to estimate contact stresses: computational approaches, individual transducers, pressure sensitive films, and pressure sensitive mats. Each approach has its advantages and limitations.

Computational Approaches

In simple form[38,68] computational approaches were perhaps not surprisingly the earliest since they required no technology, and relatively simple models and calculations.[38,100,115,116] These sorts of models typically used a single load the authors implicitly assumed represented biologically important aspects of the mechanical history (e.g., presumed peak load during single leg stance). These approaches resulted in spatially averaged stresses, not biologically critical local peaks, and while illustrating principles did not materially advance our understanding of the biologic issues. A number of groups have reported more sophisticated computational approaches,[34,48,66,67,70,90,91] each of which necessarily includes simplifications and assumptions (some explicit, others implicit). Simplifications include geometry (often two-dimensional),[18,124] spherical hip joints, frictionless surfaces, and limited loading conditions, elastic properties. Such assumptions are not inherent, however, since with enormously enhanced computational power, models may be three-dimensional,[15,48,66,71,134] or include more sophisticated treatments of material properties,[90] or multiple loading conditions.[16,60,67,70,105] Perhaps the major question of these models is that of model confirmation.[ii] Ordinarily, this means comparing model results against some independent measure such as those from experimental techniques (see below). (It is critical to recognize we do not know whether the experiments provide "true" results: those that would be occurring naturally in the course of human or animal function. Therefore, we cannot "verify" or ascertain the truth of the model except under conditions limited to those of the experiment. In effect, perhaps the strongest corroboration arises from determining that many studies obtain similar results, despite the widely varying methods used to obtain them, and despite the many computational or experimental conditions.[iii])

Individual Transducers

Ingelmark and Blomgren[68] recognized functional loading had an "influence . . . on the morphological and pathological state of the articular cartilages" and that a spatially averaged pressure in a joint was not likely meaningful, in contrast to a local peak. They also indicated earlier attempts to estimate pressures required "a certain amount of calculation work" and the methods were "very time-consuming." Therefore, they devised (and elegantly described) a small (9 mm diam-

[i] Oreskes[112] explores the issue of how individual parameters may inadequately capture phenomena of interest owing to both theoretical and empirical uncertainties. Although contact stress seems a reasonable parameter reflecting behavior of cartilage since it teleologically seems designed to distribute load, closer examination reveals a number of problems yet to be explored.

[ii] Oreskes and her colleagues[113] have argued numerical models of complex natural systems cannot be logically "validated" (i.e., establish the soundness or legitimacy of a proposition). In a complex system there are not only recognized parameters for which we have no quantitative knowledge, but also unrecognized parameters. In this situation, many models can produce the same result, precluding validation of any given model. Rather, we can "confirm" or strengthen our propositions.

[iii] Authors are unlikely to report a model in which experimental confirmation has been attempted, but not successful. Oreskes[113] notes she was unable to find such a case, and this author has never seen a published example. While many, if not most numerical models are published without any attempt at experimental confirmation, it is likely many models with confirmation were not initially confirmed. In these cases, authors would (appropriately) modify the model until computational and experimental answers coincided. However, this does not really imply confirmation. Rather, confirmation would need to arise from a new and fully independent set of results.

eter, 1 mm thick) rubber transducer based upon electrical inductance (and contrasted to other potential approaches based upon resistive or capacitive methods used by later investigators). This device, they reported, was accurate to within 25% of the actual pressure. Importantly, Ingelmark and Blomgren realized contact stresses averaged over some large region were not likely as biologically meaningful as local peaks: "A knowledge of such pressure peaks—should they exist—would probably be of great importance for the understanding of the pathologic changes in the joints as well as for the study of the relation between the functioning of the joints and their morphologic structure." Unfortunately, Ingelmark's device was sufficiently large that true local peaks (i.e., at the levels undoubtedly important for biological responses) could not be recorded; that is, spatial resolution was problematic. Furthermore, it was a single device that would only record in a single location, which an investigator could not a priori insure would represent stresses in an entire joint.

The transducer approach was not again utilized until the mid 1970s, when Carlson et al.[27] constructed a hemiarthroplasty device for human implantation. This device partly addressed two limitations of Ingelmark's device: measurement artifacts from insertion of a device of finite thickness between the articular surfaces and multiple transducers (14) to provide more than a single measurement. Furthermore, this device could be and indeed was implanted in humans,[52,61,62,137] allowing dynamic pressure measurements in a variety of activities. However, this device was still limited to a few discrete areas, local peak pressure estimates were limited to the size of the transducer surface, recordings could be made only of cartilage-on-metal (which would likely be quite distinct from natural cartilage-on-cartilage), and the authors reported no integration of the measurements to insure the device could recover applied loads (thus confirming the measurements). Two subsequent groups[1,20,21] did, however, map contact stresses using *in vitro* experiments. Obviously, these experiments would be limited by the limited loading conditions (which might or might not "represent" critical loading conditions from a biological point of view). Joint lubrication might also differ in the *in vitro* experiments, resulting in artifactual pressure recordings, although these differences would likely be small.

Pressure Sensitive Films

The problem of spatial resolution was largely solved by the introduction of a pressure sensitive film (PreScale® Fuji Film Co., Ltd., Tokyo; now distributed as Pressurex®, Sensor Products In. East Hanover, NJ) in the late 1970s.[42] (Company specifications note a spatial resolution of 5 to 15 microns, theoretically fine enough to study pressures at the cell level.) In addition, the thin nature of the film (0.076 mm) would result in relatively little artifact on flat surfaces.[141] However, since the film was not very flexible, artifacts were introduced on curved surfaces, including most animal joints. Finally, the calibration procedures were tricky. Nonetheless, owing to their advantages, a number of investigators reported *in vitro* use in the 1980s.[2,17,63,64,127,133,136,138] The images were, of course, qualitative, but scanning and semi-automated computerized approaches[26] afforded quantitative analysis of experimental replications, and comparisons of conditions. In addition, Caldwell et al.[26] reported a numerical algorithm to detect and remove crinkle artifacts in curved joints (e.g., the hip). They and others[30] further used a petal-like arrangement of the film which would fit into the joint (much like the flat paper placed on a globe of the world). Thus, the refinements provided a reasonable estimate of contact pressures with better resolution than transducers. However, these images remained "snapshots" of one point in time, and were therefore limited to a single, or at best a few, experimental loading conditions, which as noted earlier might not reflect the biologically important aspects of loading history.

Pressure Sensitive Mats

The ability to digitally sample and store large amounts of data afforded by computers led to a later refinement came using a mat with multiple capacitive transducers (Pedar™, novel GMBH, Munich) capable of recording dynamic pressures over time.[110] That advantage is partly offset by a mat thickness (required by the mechanical and electrical components) more likely to introduce artifact, as well as a loss of spatial resolution (imparted by limitations on sampling frequency and computer storage required for multiple sensors). Typically, the spatial resolution of these devices is in the range of 1 cm.[2] (Rapid advances in processing speeds and memory, along with affordable miniaturization of transducers may obviate reduce this limitation in the foreseeable future.) Most of the applications of these devices has been for external (e.g., skin) applications,[25,43,56,57,120] although these devices have also been developed for joints.[31,141] A major disadvantage of these mats in recording joint contact stress is their thickness (now perhaps as thin as 0.5 mm). Their introduction may result in artifactual recordings, particularly in small joints with thin cartilage. These problems have partly been solved by a different technology using high-resolution, thin-film resistive sensors (F-Scan™, Tekscan, South Boston).[5,33,40,99,122] The major problem with these devices is the stiffness of the films (considerably greater

TABLE 1
Spatially Averaged and Peak Contact Stresses in Normal Joints

Author/Year	Species	Joint	Spatially averaged contact stress (MPa)	Peak contact) stress (MPa)
(Pellegrini et al., 1993)	Human	Hand		0.4-0.9
(Tencer et al., 1988)	Human	Wrist		3.2
(Viola et al., 1998)	Human	Radioscaphoid	1.7±0.5	
(Viola et al., 1998)	Human	Radiolunate	1.7±0.4	
(Conzen and Eckstein, 2000)	Human	Shoulder		10
(Legal and Ruder, 1977)	Human	Hip	0.1	
(Rushfeld et al., 1979)	Human	Hip		6.8*
(Brown and Ferguson, 1980)	Human	Hip		10
(Brinckmann et al., 1981)	Human	Hip	1.4-1.6	2.4-3.2
(Brown and Shaw, 1983)	Human	Hip	2.9	8.8
(Adams and Swanson, 1985)	Human	Hip		4.9-9.6
(Hodge et al., 1989)	Human	Hip		5.5*
(Maxian et al., 1995)	Human	Hip	<2.0	6-10
(Tackson et al., 1997)	Human	Hip	5.6*	
(Tsumura et al., 1998)	Human	Hip		2.5
(Hak et al., 1998)	Human	Hip		7.5-9.0
(von Eisenhart et al., 1999)	Human	Hip		7.7
(Hipp et al., 1999)	Human	Hip		2.1
(Ipavec et al., 1999)	Human	Hip		1.6-2.7
(Iglic et al., 2001)	Human	Hip		2.2 (male) 2.4 (female)
(Fukubayashi and Kurosawa, 1980)	Human	Tibiofemoral		3-4
(Ahmed and Burke, 1983)	Human	Tibiofemoral		2.75
(Brown and Shaw, 1984)	Human	Tibiofemoral	2.6	8.0
(Brown et al., 1991)	Dog	Tibiofemoral		0.5-6.0
(Kuroda et al., 2001)	Human	Tibiofemoral	0.5-0.7	
(Trumble et al., 2001)	Sheep	Tibiofemoral	1.2	
(Ahmed et al., 1983)	Human	Patellofemoral		3.44
(Manouel et al., 1992)	Human	Patellofemoral		0.1-1.3
(Clark et al., 2002)	Cat	Patellofemoral		
(Wagner et al., 1992)	Human	Ankle		>6 MPa (20-40% of contact surface)
(Calhoun et al., 1994)	Human	Ankle		3-8
(Steffensmeier et al., 1996)	Human	Ankle	5.1±1.2	8.9±2.2
(Rosenbaum et al., 1996)	Human	Talonavicular, Calcaneocuboid	1.1-1.4	1.8-2.0
(Thomas et al., 2000)	Human	Subtalar		2.3-6.0
(Cooper et al., 1997)	Human	Calcaneocuboid		2.3
(Lakin et al., 2001)	Human	Tarsometatarsal	0.5-5.7	

The reports involve a number of differing methods and assumptions, and with widely varying loading conditions; these numbers often reflect only a representative figure from sometimes many reported in the study. Thus, one should not attempt to directly compare the results, but rather get a sense of the range of pressures. Articles marked with an asterisk (*) arise from the only *in vivo* data in the literature but reflect cartilage-on-metal, rather than cartilage-on-cartilage contact stresses.

than that of the Pedar™ mats) making them only useful for relatively flat surfaces.[10,31,47,93] Thus, while current approaches allow reasonable recordings of large and/or relatively flat joints, they are less useful for small or substantially curved joint surfaces.

ESTIMATES OF NORMAL CONTACT STRESSES

Astonishingly, experimental measurements of peak or spatially averaged joint contact stresses are surprisingly similar, and within an order of magnitude of each other, regardless of the species or joint, and loading method (Table 1). Such variations as are reported can

TABLE 2
Peak Contact Stresses in Abnormal Hips

Author/Year	Normal Hips Peak contact stress (MPa)	Dysplastic Hips Peak Peak contact stress (MPa)	Dysplastic Hips After Osteotomy(MPa)	Slipped capital femoral epiphysis after osteotomy (MPa)	Malreduced acetabular fractures Peak contact stress (MPa)
(Iglic et al., 1993)	1.2-2.7	3-6	1.2-2.0		
(Michaeli et al., 1997)	5-8*	1-2.5*			
(Hak et al., 1998)	7.5-9.0				6.0-20.5
(Tsumura et al., 1998)	2.5	5.3			
(Hipp et al., 1999)	2.1-5.0	2.6-6.5			
(Zupanc et al., 2001)				1.1-4.3	
(Mavcic et al., 2000)	2.3	4.6			

The reader should again note these values reflect the methods and assumptions of the study in question, and more emphasis should be placed on relative, rather than absolute values. The higher values reported by Michaeli et al. 1997, (noted by asterisk) came from pressure sensitive films in a cadaveric pelvis, while the lower values for a "dysplastic" hip came from a plastic model in which the lateral lip was resected to simulate dysplasia. (Table taken from Brand et al., 2001, with permission.)

readily be explained by the differences in methods (including spatial resolution for peak stresses) or experimental conditions including loads. (Most authors make the argument their loads are "physiological.") Spatially averaged stresses range from 0.1 to 2.0 MPa while peak stresses range from about 2 to 10 MPa.

ESTIMATES OF CONTACT STRESS IN ABNORMAL CONDITIONS

Any number of clinical conditions associated with early degeneration (e.g., developmental dysplasia, slipped capital femoral epiphysis, malreduced fractures) intuitively lead to increases in contact stresses. Experimentally, compared to normal joints, a variety of studies demonstrate peak static contact stresses in such conditions are increased 2-5 times (Table 2). However, these reports show considerable variation, as well as overlap with static peak contact stresses in normal conditions. If these peak static stresses reflect the entire loading history affecting deterioration and if they have been ascertained with adequate resolution (see comments below), we could logically infer cartilage does not have a large margin of safety between the stresses required for normal maintenance, and those leading to deterioration. I hasten to add, however, these are two questionable premises, even if frequently made.[iv]

CONTACT STRESS DISTRIBUTIONS IN NORMAL JOINTS

The reader will have just seen that peak and even spatially averaged contact pressures are remarkably similar from joint to joint and even species-to-species in the limited data on the latter. The distribution of these stresses is, however, quite variable, even within a given joint and obviously dependent upon the experimental conditions including directions of loading and constraints on bones adjacent to the joint. Pereira, et al.[119] commented, "There was a high degree of scatter in the mean pressure intensity data, which precluded our attempts to quantify this parameter." It is unlikely one can draw generalizations on the limited amount of pressure distribution.[3,4,20,21,30,130] In these limited cases, the authors illustrate isometric "contour" plots with one or perhaps two regions of highest contact stress surrounded by lower levels. These plots are based upon single instances of loading, and in a moving joint with variable loads, the patterns would differ in details both qualitatively and quantitatively.[67,104] However, not surprisingly in the human acetabulum, the patterns reflect a basic horseshoe shaped region smaller than but more or less corresponding with all but the peripheral regions of the horseshoe-shaped articular surface (if imagined flattened out), although much of the joint is unloaded or minimally loaded at any one time. Several reports suggest the resultant joint loads on the acetabulum vary considerably in location and direction throughout the gait cycle,[117,145] but remain relatively more constant in location and direction on the femoral head.[11-13,35,86,87] Thus, one would expect the contact stress patterns on the proximal femoral articular surface to be more constant than those on the acetabulum, but I am unaware of any reports documenting that point.

WHAT ASPECTS OF JOINT CONTACT AFFECT CARTILAGE MAINTENANCE AND DEGRADATION?

At the outset, I noted the mechanical history is responsible for normal maintenance of cartilage, although

[iv] The eminent French neurologist, Paul Broca, commented, "The least questioned assumptions are often the most questionable."

at some levels is deleterious to cartilage and at yet others perhaps facilitates repair. Exploration of the effects of low, normal, and high levels of mechanical history each reflect a legitimate area of exploration, but more often than not investigators have traditionally been mostly interested in what causes tissue degeneration, and only more recently what facilitates repair. Several questions immediately arise: What aspect or aspects (parameters) of the mechanical history relate to the responsiveness of cartilage cells and cartilage as a tissue? What magnitude levels of those aspects result in normal maintenance, deterioration, repair? (In other words, what mechanical history does cartilage tolerate?) Are these levels the same in all joints? Are these levels the same for all ages? To what degree can cartilage adapt to a new and unexpected mechanical history?

What Aspects of the Mechanical History Relate to Cartilage Biology?

Implicitly, if intuitively, contact stresses have been used as a surrogate for whatever aspect of the mechanical history stimulates chondrocytes. Quite naturally, the choice of parameters intimately depend upon the question being asked. Whatever the question, however, a single local contact stress peak or spatially averaged peak, or even pattern measured under some loading regimen presumed representative does not likely relate directly to cartilage biology. Brown and his colleagues ascertained that while *in vitro* defects in articular cartilage result in elevated contact stresses immediately around defects, those stresses did not appear excessive (e.g., rim pressures elevated on 10-30% compared to peak local stresses on an intact surface).[19] The degree of elevation was only modestly related to defect size (1, 2, 3, 4, 5, 6, and 7 mm). The explanation for this failure to elevate stresses seems obviously related to the compliant nature of the cartilage: the rims are simply pushed into the defect, thus abrogating the effects on a rim of a more rigid surface.[44,69,129] At the same time, the radially directed peak contact stress *gradient* was elevated by as much as an order of magnitude. (Again, the degree of elevation was at best modestly related to defect size, with high gradients occurring with all sizes.) Since contact stress gradients, particularly those associated with regions of high contact stresses would relate to fluid flow,[69,101] the stress gradient more than the stress per se seems a more likely surrogate candidate if experienced over time. In a related *in vivo* experiment (but *in vitro* contact stress measurements) by Brown and colleagues, 6 mm defects allowed to repair over a period of 11 months were not associated with elevations of rim contact stresses.[109] Importantly, the repair tissue was flimsy and did not contribute to load transmission (that is, contact stresses were minimal if at all detected). This suggests remaining cartilage adapts whether by structural change[44,129] or by biological change.[89] Undoubtedly, in any joint incongruity, initially elevated contact stress gradients would disappear, and would likely do so in a fairly short time (initially owing to cartilage compliance and later owing to remodeling of the cartilage and underlying subchondral bone). Thus, if contact stress gradients per se are related to repair, they would like be so related in the early stages until adaptation occurred.

While it seems obvious that tissues respond not to some static parameter, but to complex time and spatially varying loads, it is entirely unclear what aspects of the mechanical environment and history are important. Brand and Stanford[14] proposed that tissues ignored the majority of the mechanical signals they experienced, and rather responded only to select features. This may mean many submaximal loadings might have far more effects than a few maximal loadings, in which case maximal loading (and stressing) would be irrelevant. (This would not necessarily suggest, however, that some high loading environments could not lead to damage or deterioration.) Consistent with that notion, Turner[140] proposed three rules governing the adaptation of bone to its mechanical history: 1.) Bone is driven by dynamic, rather than static, loading; 2.) Only a short duration of mechanical loading is necessary to initiate an adaptive response; 3.) Bone cells accommodate to a customary mechanical loading history, making them less responsive to routine loading signals. These notions are supported by considerable experimental evidence cited in the papers. Furthermore, Robling et al.[128] reported the same "dose" of mechanical stimulus over a period of time had differing effects on bone adaptation depending upon how the mechanical history was "partitioned." Such biological effects have been long well known in radiation biology, where "dose-fractionation" is routine part of practice.[9,73,83,135,144] Furthermore, recent experimental studies document the time scale is critical for biological responses in cartilage.[28,36,123] Thus, in ascertaining biological responses, it is insufficient just to consider contact stress magnitude, but one must also consider the time frame over which individual loading cycles are applied. Presuming these notions are correct (and substantial evidence suggests they are), and they apply to all tissues, then the contact stresses we measure may not relate directly to *in vivo* cartilage responses. While both contact stresses and stress gradients reflect the local distributions of overall joint loads, until and unless we ascertain the contact stress or contact stress gradient *dose history*—or "stress profile"[114]—which relates to cartilage biology, we will undoubtedly gain limited insight.

Another important issue in ascertaining an optimal range of mechanical histories for cartilage maintenance, adaptation, or repair relates to spatial scale. If deleteriously high stress histories occur over a small area (or volume) involving a few cells, will that region die and lead to clinically significant consequences? I think this unlikely since a small region of dead cells can probably recover. However, what if the area of cell death is over 100 micrometers, or, say 1 mm?

Cartilage has limited capacity for repair.[98] In fact, all known cells have limits on their ability to replicate ("Hayflick limit").[51,58,76,92,97,108] This limited replicative capacity appears to be related to the length of a fragment (telomere) on the end of DNA chains.[6,7,32,49-51,81,92,94,102] With each replication the telomere length is reduced and when it is sufficiently short, replication cases. Cartilage cells, in particular appear to have a very limited capacity to replicate,[84,85,102] with perhaps only 25-35 doublings during the life of a cell (contrasted to perhaps 40-60 or more with other sorts of cells). Further, "replicative senescence" is preceded by a phenotypic senescence.[125] Thus, the capacity of cartilage to produce molecules essential for maintenance, may be especially limited in aged cartilage due to a larger fraction of senescent chondrocytes. If the cells in a small region (say 100 micrometers volume) of chronically overloaded cartilage replicate and/or produce extra matrix to adapt, and subsequently become prematurely senescent they will then fail to maintain their region of matrix and the local mechanical properties will change. When this happens adjacent areas will have to take up the load, thus leading to overloading and destruction in the adjacent region, creating a vicious cycle in a spatially expanding region. Huberti and Hayes[63] noted high local patellofemoral contact stresses (approximately 3-5 MPa) in the normal-appearing cartilage in knees with degeneration of the patellar cartilage elsewhere, and low stresses in the regions of clearly abnormal cartilage. It is unclear, however, whether the regions or volumes of articular cartilage that were degenerated and under low contact stress in the experiment once under high contact stress prior to degeneration, although their observations are consistent with that notion. Further, while we do not know what regions or volumes of cartilage can be irreparably damaged, quantitative information of this sort is critical to knowing the spatial resolution required for any measures of contact stress. Thus, the notion of contact stress *histories* aside, a technique with a spatial resolution of 5 mm may be entirely insensitive to the changes in contact stresses to answer a question relevant to tissue repair or deterioration.

What Magnitude Levels of Those Aspects of Contact Stress Dose History Result in Normal Maintenance, Deterioration, Repair?

Few *in vivo* or *ex vivo* studies address this important question. Repo and Finlay[126] demonstrated impact stresses of 25 MPa (and strain rates of 500 and 1000 per second) were sufficient to cause chondrocyte death. This level of contact stress is also close to the level required to produce patellar fracture.[54] Thus, at the high end, a single load producing 25 MPa will likely result in either fracture or chondrocyte cell death. However, it is important to recognize that cartilage normally experiences peak contact stresses 1 to 2 orders of magnitude below this level (Table 1). Since a single accidental impact load engendering stresses below these levels is unlikely to result in local peak contact stresses and stress patterns similar to normal, we could argue a single contact stress load is unlikely to relate to subsequent cell behavior. Recognizing stress history, not single loading is critical, Brown and colleagues[48,105] estimated the contact stress histories for 83 patients with developmental dysplasia of the hip followed for an average of 29 years, and demonstrated the propensity for degeneration related to the cumulative contact stress "overdose." That overdose was at a level of 10 MPa-years, where the contact stress reflected a spatial mean. (Note this figure arises not from local peaks, but spatial averages that would generally be an order of magnitude lower.) Importantly, "single-time snapshot pressures" correlated only weakly (r=0.39) with long-term outcome. This again suggests, static contact stresses are not likely a good surrogate for biological behavior. I am unaware of any other attempts to address this question. However, these studies do suggest possible bounds on cartilage tolerance.

Are These Levels the Same in All Joints?

The differences in propensity for osteoarthrosis between various joints is well known epidemiologically.[39,65,82] Less well understood are the mechanical[78,139] and biological differences between the cartilage in differing joints.[29,77,139] Thus, it appears the adaptation to cartilage in each joint is unique, and it is possible the levels of dose history required for normal maintenance and damage differ. However, this argument is speculative based upon inferential evidence.

Are These Levels the Same for All Ages?

Age-related changes in the biological[23,77,82,106,107,121] as well as mechanical[8,78,79,111] behavior of joints are well known. As with the question of differing joints, however, whether and to what degree the mechanical dose

histories relate to tissue biology are unknown. However, investigators exploring the relationship between mechanical histories and cartilage responses should be aware that age is likely an important factor.

To What Degree Can Cartilage Adapt to a New and Unexpected Mechanical History?

Despite the important nature of this question, evidence again remains sketchy. There is little question cartilage can adapt[74,95] or repair to at least a limited degree[72,88] in response to a new mechanical history. However, virtually nothing quantitative is known about the optimal contact stress histories required for repair.

COMMENT

The loading history of a joint, or a region of a joint is critical to normal maintenance of articular cartilage. Investigators have long assumed contact stress a suitable mechanical parameter relating to cartilage biology. However, for a variety of reasons, that assumption is not likely a reasonable one for answering most questions relating to cartilage maintenance, adaptation, repair, and deterioration. First, a single, or even a few, contact stress measurements under very well defined (ostensibly needed for reproducibility) and restricted loading conditions may not adequately represent all those experienced by a joint. Second, all biological responses occur because of a loading ("dose") history, and given evidence cells and tissues respond to a minority of their mechanical history, we do not know which aspects of even a contact stress history result in subsequent responses. Third, the region of cells or tissues which if irreparably damaged will ultimately lead to failure of joint repair and degeneration is not known. Without some knowledge of tissue tolerance, we cannot speculate the required resolution of contact stress patterns, and rather must presume fine resolution is required. Fourth, the levels of the contact stress history which result in normal maintenance or degeneration are not known, but limited evidence suggests a spatially averaged (not peak local) joint contact stress "dose" of 10 MPa-years appears to be deleterious.

The basis for the critical nature of intermittent joint loading in maintaining normal articular cartilage is sound, and experimental studies consistently support the concept. Intermittent loading results in flow of nutrients into and waste products out of cartilage, and in addition provides the mechanical signals essential for normal cell and tissue maintenance. On the other hand, deleteriously low or high contact stresses result in joint deterioration. Particular aspects of the environment may facilitate repair of damaged cartilage. However, I am unaware of any such studies that attempted to quantify the mechanical history, and in particular the contact stress history in their protocols. It would seem, however, based upon other evidence, motion alone in the absence of adequate contact stress would not suffice for either maintenance or repair of cartilage.

Contact stresses have been estimated in many joints, and in a number of species, although rarely *in vivo*. Despite a number of widely varying techniques to measure these contact stresses, the ranges of peak normal stresses are relatively similar from joint to joint across species, and in the range of 0.5 to 5.0 MPa. This suggests diarthrodial joints have evolved with similar tissues (cartilage, underlying bone, ligaments, capsule) to achieve similar mechanical design criteria, and that the articular cartilage in particular normally experiences a narrow range of contact stresses. Disorders resulting in elevated static peak local pressures (i.e., 2-4 times normal or more, sometimes over 5.0 MPa) are loosely associated with cartilage deterioration over time. Evidence as well as intuition suggests contact stresses per se are not associated with deterioration, although some associated quantity (e.g., stress gradient) over time might be. Therefore, we may not presume that contact stresses, whether peak or spatially averaged provide a good surrogate for biological behavior. Rather, spatial and temporal aspects of the loading history induce the biological responses.

Finally, let me make an observation about "weight-bearing joints." Many authors imply that those joints involved directly in gait (i.e., the lower extremity joints in bipedal animals) somehow experience greater loads and stresses. While it might be true the loads are higher, the joints are also much larger. The available evidence I have reviewed suggests the contact stresses (if not stress histories) are similar in all joints. Thus, it is appealing to speculate joints have evolved to some aspect of contact stresses or stress histories, not loads. That being the case, the concept of a "weight-bearing joint" is misleading and perhaps the term should be abandoned.

REFERENCES

1. **Adams D, Swanson SA:** Direct measurement of local pressures in the cadaveric human hip joint during simulated level walking. *Ann Rheum Dis* 44:658-666, 1985.
2. **Afoke NY, Byers PD, Hutton WC:** Contact pressures in the human hip joint. *J Bone Joint Surg Br* 69:536-541, 1987.
3. **Ahmed AM, Burke DL:** In-vitro measurement of static pressure distribution in synovial joints—Part I: Tibial surface of the knee. *J Biomech Eng* 105:216-225, 1983.

4. **Ahmed AM, Burke DL, Yu A:** In-vitro measurement of static pressure distribution in synovial joints—Part II: Retropatellar surface. *J Biomech Eng* 105:226-236, 1983.
5. **Ahroni JH, Boyko EJ, Forsberg R:** Reliability of F-scan in-shoe measurements of plantar pressure. *Foot Ankle Int* 19:668-673, 1998.
6. **Allsopp RC, Chang E, Kashefi-Aazam M, et al:** Telomere shortening is associated with cell division in vitro and in vivo. *Exp Cell Res* 220:194-200, 1995.
7. **Allsopp RC, Harley CB:** Evidence for a critical telomere length in senescent human fibroblasts. *Exp Cell Res* 219:130-136, 1995.
8. **Armstrong CG, Bahrani AS, Gardner DL:** In vitro measurement of articular cartilage deformations in the intact human hip joint under load. *J Bone Joint Surg Am* 61:744-755, 1979.
9. **Baumann M, Appold S, Petersen C, Zips D, Herrmann T:** Dose and fractionation concepts in the primary radiotherapy of non-small cell lung cancer. *Lung Cancer* 33 Suppl 1:S35-45, 2001.
10. **Becker R, Wirz D, Wolf C, et al:** Measurement of meniscofemoral contact pressure after repair of bucket-handle tears with biodegradable implants. *Arch Orthop Trauma Surg*, 2004.
11. **Bergmann G, Deuretzbacher G, Heller M, et al:** Hip contact forces and gait patterns from routine activities. *J Biomech* 34:859-871, 2001.
12. **Bergmann G, Graichen F, Rohlmann A:** Is staircase walking a risk for the fixation of hip implants? *J Biomech* 28:535-553, 1995.
13. **Bergmann G, Graichen F, Rohlmann A, Linke H:** Hip joint forces during load carrying. *Clin Orthop*:190-201, 1997.
14. **Brand RA, Stanford CM:** How connective tissues temporally process mechanical stimuli. *Med Hypotheses* 42:99-104, 1994.
15. **Brinckmann P, Frobin W, Hierholzer E:** [Pressure on the bearing surface of the hip joint (author's transl)]. *Z Orthop Ihre Grenzgeb* 118:107-115, 1980.
16. **Brinckmann P, Frobin W, Hierholzer E:** Stress on the articular surface of the hip joint in healthy adults and persons with idiopathic osteoarthrosis of the hip joint. *J Biomech* 14:149-156, 1981.
17. **Brown TD, Anderson DD, Nepola JV, et al:** Contact stress aberrations following imprecise reduction of simple tibial plateau fractures. *J Orthop Res* 6:851-862, 1988.
18. **Brown TD, DiGioia AM, III:** A contact-coupled finite element analysis of the natural adult hip. *J Biomech* 17:437-448, 1984.
19. **Brown TD, Pope DF, Hale JE, Buckwalter JA, Brand RA:** Effects of osteochondral defect size on cartilage contact stress. *J Orthop Res* 9:559-567, 1991.
20. **Brown TD, Shaw DT:** In vitro contact stress distributions in the natural human hip. *J Biomech* 16:373-384, 1983.
21. **Brown TD, Shaw DT:** A technique for measuring instantaneous in vitro contact stress distributions in articular joints. *J Biomech* 15:329-333, 1982.
22. **Buckwalter JA:** Effects of early motion on healing of musculoskeletal tissues. *Hand Clin* 12:13-24, 1996.
23. **Buckwalter JA, Roughley PJ, Rosenberg LC:** Age-related changes in cartilage proteoglycans: quantitative electron microscopic studies. *Microsc Res Tech* 28:398-408, 1994.
24. **Bullough P, Goodfellow J, Greenwald AS, O'Connor J:** Incongruent surfaces in the human hip joint. *Nature* 217:1290, 1968.
25. **Burgess S, Jordan C, Bartlett R:** The influence of a small insert, in the footbed of a shoe, upon plantar pressure distribution. *Clin Biomech* (Bristol, Avon) 12:S5-S6, 1997.
26. **Caldwell NJ, Hale JE, Rudert MJ, Brown TD:** An algorithm for approximate crinkle artifact compensation in pressure- sensitive film recordings. *J Biomech* 26:1001-1009, 1993.
27. **Carlson CE, Mann RW, Harris WH:** A radio telemetry device for monitoring cartilage surface pressures in the human hip. *IEEE Trans Biomed Eng* 21:257-264, 1974.
28. **Chen CT, Burton-Wurster N, Lust G, Bank RA, Tekoppele JM:** Compositional and metabolic changes in damaged cartilage are peak-stress, stress-rate, and loading-duration dependent. *J Orthop Res* 17:870-879, 1999.
29. **Chubinskaya S, Kuettner KE, Cole AA:** Expression of matrix metalloproteinases in normal and damaged articular cartilage from human knee and ankle joints. *Lab Invest* 79:1669-1677, 1999.
30. **Conzen A, Eckstein F:** Quantitative determination of articular pressure in the human shoulder joint. *J Shoulder Elbow Surg* 9:196-204, 2000.
31. **Cooper PS, Nowak MD, Shaer J:** Calcaneocuboid joint pressures with lateral column lengthening (Evans) procedure. *Foot Ankle Int* 18:199-205, 1997.
32. **Counter CM:** The roles of telomeres and telomerase in cell life span. *Mutat Res* 366:45-63, 1996.
33. **D'Amico JC:** The F-Scan system with EDG module for gait analysis in the pediatric patient. *J Am Podiatr Med Assoc* 88:166-175, 1998.

34. **Daniel M, Antolic V, Iglic A, Kralj-Iglic V:** Determination of contact hip stress from nomograms based on mathematical model. *Med Eng Phys* 23:347-357, 2001.
35. **Davy DT, Kotzar GM, Brown RH, et al:** Telemetric force measurements across the hip after total arthroplasty. *J Bone Joint Surg Am* 70:45-50, 1988.
36. **Duda GN, Eilers M, Loh L, et al:** Chondrocyte death precedes structural damage in blunt impact trauma. *Clin Orthop*:302-309, 2001.
37. **Enneking WF, Horowitz M:** The intra-articular effects of immobilization on the human knee. *J Bone Joint Surg Am* 54:973-985, 1972.
38. **Ewles J, Curry C:** Cathode-ray recording micrometer and force gage. *J Scient Instr* 24:261-265, 1947.
39. **Felson DT:** The Epidemiology of Osteoarthritis: Prevalence and Risk Factors. In *Osteoarthritic Disorders*, edited by Kuettner, KE, Goldberg, VM. Rosemont, IL, American Academy of Orthopaedic Surgeons, pp. 13-24, 1995.
40. **Ferguson-Pell M, Cardi MD:** Prototype development and comparative evaluation of wheelchair pressure mapping system. *Assist Technol* 5:78-91, 1993.
41. **Finsterbush A, Friedman B:** Reversibility of joint changes produced by immobilization in rabbits. *Clin Orthop* 290-298, 1975.
42. **Fukubayashi T, Kurosawa H:** The contact area and pressure distribution pattern of the knee. A study of normal and osteoarthrotic knee joints. *Acta Orthop Scand* 51:871-879, 1980.
43. **Garbalosa JC, Cavanagh PR, Wu G, et al:** Foot function in diabetic patients after partial amputation. *Foot Ankle Int* 17:43-48, 1996.
44. **Ghadially JA, Ghadially FN:** Evidence of cartilage flow in deep defects in articular cartilage. *Virchows Arch B Cell Pathol* 18:193-204, 1975.
45. **Goldthwait JE, Brown LT, Swaim LT, Kuhns JG:** *Body Mechanics in the Study and Treatment of Disease*. Edited, Philadelphia, PA, J.B. Lippincott Company, 1934.
46. **Greenwald AS, Nelson CL, Jr.:** Relationship of degenerative arthritis to weight-bearing areas in the human hip joint. *Surg Forum* 23:463-464, 1972.
47. **Greis PE, Scuderi MG, Mohr A, Bachus KN, Burks RT:** Glenohumeral articular contact areas and pressures following labral and osseous injury to the anteroinferior quadrant of the glenoid. *J Shoulder Elbow Surg* 11:442-451, 2002.
48. **Hadley NA, Brown TD, Weinstein SL:** The effects of contact pressure elevations and aseptic necrosis on the long-term outcome of congenital hip dislocation. *J Orthop Res* 8:504-513, 1990.
49. **Harley CB:** Human ageing and telomeres. *Ciba Found Symp* 211:129-139; discussion 139-144, 1997.
50. **Harley CB:** Telomere loss: mitotic clock or genetic time bomb? *Mutat Res* 256:271-282, 1991.
51. **Harley CB, Futcher AB, Greider CW:** Telomeres shorten during ageing of human fibroblasts. *Nature* 345:458-460, 1990.
52. **Harris WH, Rushfeldt PD, Carlson CE, Scholler J-M, Mann RW:** Pressure distribution in the hip and selection of hemiarthroplasty. In *The Hip*, edited by Amstutz, HC. St. Louis, The C.V. Mosby Company, pp. 93-102. 1975.
53. **Harrison MHM, Schajowicz F, Trueta J:** Osteoarthritis of the hip: A study of the nature and evolution of the disease. *J Bone Joint Surg Br* 35:598-626, 1953.
54. **Haut RC:** Contact pressures in the patellofemoral joint during impact loading on the human flexed knee. *J Orthop Res* 7:272-280, 1989.
55. **Haut RC, Ide TM, De Camp CE:** Mechanical responses of the rabbit patello-femoral joint to blunt impact. *J Biomech Eng* 117:402-408, 1995.
56. **Hayes A, Seitz P:** The average pressure distribution of the diabetic foot: can it be used as a clinical diagnostic aid? *Clin Biomech* (Bristol, Avon) 12:S3-S4, 1997.
57. **Hayes A, Seitz P:** Reproducibility test on a children's insole for measuring the dynamic plantar pressure distribution. *Clin Biomech* (Bristol, Avon) 12:S4-S5, 1997.
58. **Hayflick L:** Human cells and aging. *Sci Am* 218:32-37, 1968.
59. **Heuter C:** *Klinik der Gelenkkrankheiten mit Einschluss der Orthopädie: Auf anatomisch-physiologischen Grundlagen nach klinischen Beobachtungen für Aerzte und Studirende*. Edited, Leipzig, Verlag von F.C. Wogel, 1876.
60. **Hipp JA, Sugano N, Millis MB, Murphy SB:** Planning acetabular redirection osteotomies based on joint contact pressures. *Clin Orthop*:134-143, 1999.
61. **Hodge WA, Carlson KL, Fijan RS, et al:** Contact pressures from an instrumented hip endoprosthesis. *J Bone Joint Surg Am* 71:1378-1386, 1989.
62. **Hodge WA, Fijan RS, Carlson KL, et al:** Contact pressures in the human hip joint measured in vivo. *Proc Natl Acad Sci U S A* 83:2879-2883, 1986.
63. **Huberti HH, Hayes WC:** Contact pressures in chondromalacia patellae and the effects of capsular reconstructive procedures. *J Orthop Res* 6:499-508, 1988.

64. **Huberti HH, Hayes WC:** Patellofemoral contact pressures. The influence of q-angle and tendofemoral contact. *J Bone Joint Surg Am* 66:715-724, 1984.
65. **Huch K, Kuettner KE, Dieppe P:** Osteoarthritis in ankle and knee joints. *Semin Arthritis Rheum* 26:667-674, 1997.
66. **Iglic A, Antolic V, Srakar F:** Biomechanical analysis of various operative hip joint rotation center shifts. *Arch Orthop Trauma Surg* 112:124-126, 1993.
67. **Iglic A, Kralj-Iglic V, Antolic V:** Reducing the stress in the articular surface of the hip joint after shifting the upper part of the body towards the painful hip. *Acta Chir Orthop Traumatol Cech* 61:268-270, 1994.
68. **Ingelmark BE, Blomgren E:** An apparatus for the measurement of pressure, especially in human joints. *Ups J Med Sci* 53:53-75, 1948.
69. **Ingelmark BE, Ekholm R:** A study on variations in the thickness of articular cartilage in association with rest and periodical load. *Upsala Lakereforen Forh* 53:61-74, 1948.
70. **Ipavec M, Brand RA, Pedersen DR, et al:** Mathematical modelling of stress in the hip during gait. *J Biomech* 32:1229-1235, 1999.
71. **Ipavec M, Iglic A, Iglic VK, Srakar F:** Stress distribution on the hip joint articular surface during gait. *Pflugers Arch* 431:R275-276, 1996.
72. **Itoman M, Yamamoto M, Yonemoto K, Sekiguchi M, Kai H:** Histological examination of surface repair tissue after successful osteotomy for osteoarthritis of the hip joint. *Int Orthop* 16:118-121, 1992.
73. **Jacobson BS:** Optimum inactivation dose and indices of radiation response based on the linear quadratic survival equation. *Radiat Environ Biophys* 32:311-317, 1993.
74. **Jones IL, Klamfeldt A, Sandstrom T:** The effect of continuous mechanical pressure upon the turnover of articular cartilage proteoglycans in vitro. *Clin Orthop* 165:283-289, 1982.
75. **Jones R, Lovett RW:** *Orthopaedic Surgery*. Edited, New York, William Wood and Company, 1923.
76. **Juckett DA:** Cellular aging (the Hayflick limit) and species longevity: a unification model based on clonal succession. *Mech Ageing Dev* 38:49-71, 1987.
77. **Kang Y, Koepp H, Cole AA, Kuettner KE, Homandberg GA:** Cultured human ankle and knee cartilage differ in susceptibility to damage mediated by fibronectin fragments. *J Orthop Res* 16:551-556, 1998.
78. **Kempson GE:** Age-related changes in the tensile properties of human articular cartilage: a comparative study between the femoral head of the hip joint and the talus of the ankle joint. *Biochim Biophys Acta* 1075:223-230, 1991.
79. **Kempson GE:** Relationship between the tensile properties of articular cartilage from the human knee and age. *Ann Rheum Dis* 41:508-511, 1982.
80. **Kim HK, Moran ME, Salter RB:** The potential for regeneration of articular cartilage in defects created by chondral shaving and subchondral abrasion. An experimental investigation in rabbits. *J Bone Joint Surg Am* 73:1301-1315, 1991.
81. **Kipling D, Wynford-Thomas D, Jones CJ, et al:** Telomere-dependent senescence. *Nat Biotechnol* 17:313-314, 1999.
82. **Koepp H, Eger W, Muehleman C, et al:** Prevalence of articular cartilage degeneration in the ankle and knee joints of human organ donors. *J Orthop Sci* 4:407-412, 1999.
83. **Kolb HJ, Losslein LK, Beisser K, et al:** Dose rate and fractionation of total body irradiation in dogs: short and long term effects. *Radiother Oncol* 18 Suppl 1:51-59, 1990.
84. **Kolettas E, Buluwela L, Bayliss MT, Muir HI:** Expression of cartilage-specific molecules is retained on long-term culture of human articular chondrocytes. *J Cell Sci* 108 (Pt 5):1991-1999, 1995.
85. **Kolettas E, Muir HI, Barrett JC, Hardingham TE:** Chondrocyte phenotype and cell survival are regulated by culture conditions and by specific cytokines through the expression of Sox-9 transcription factor. *Rheumatology* (Oxford) 40:1146-1156, 2001.
86. **Kotzar GM, Davy DT, Berilla J, Goldberg VM:** Torsional loads in the early postoperative period following total hip replacement. *J Orthop Res* 13:945-955, 1995.
87. **Kotzar GM, Davy DT, Goldberg VM, et al:** Telemeterized in vivo hip joint force data: a report on two patients after total hip surgery. *J Orthop Res* 9:621-633, 1991.
88. **Lane JG, Tontz WL, Jr., Ball ST, et al:** A morphologic, biochemical, and biomechanical assessment of short-term effects of osteochondral autograft plug transfer in an animal model. *Arthroscopy* 17:856-863, 2001.
89. **Lefkoe TP, Walsh WR, Anastasatos J, Ehrlich MG, Barrach HJ:** Remodeling of articular stepoffs. Is osteoarthrosis dependent on defect size? *Clin Orthop* 314:253-265, 1995.
90. **Legal H:** Introduction to the biomechanics of the hip. In *Congenital Dysplasia and Dislocation of the Hip*, edited by Tonnis, D. Berlin, Springer-Verlag, pp. 26-57, 1987.

91. **Legal H, Reinecke M, Ruder H:** Zur biostatischen Analyse des Hüftgelenks III. *Z Orthop Ihre Grenzgeb* 118:804-815, 1980.
92. **Levy MZ, Allsopp RC, Futcher AB, Greider CW, Harley CB:** Telomere end-replication problem and cell aging. *J Mol Biol* 225:951-960, 1992.
93. **Li G, DeFrate LE, Zayontz S, Park SE, Gill TJ:** The effect of tibiofemoral joint kinematics on patellofemoral contact pressures under simulated muscle loads. *J Orthop Res* 22:801-806, 2004.
94. **Linskens MH, Harley CB, West MD, Campisi J, Hayflick L:** Replicative senescence and cell death. *Science* 267:17, 1995.
95. **Lovasz G, Llinas A, Benya PD, et al:** Cartilage changes caused by a coronal surface stepoff in a rabbit model. *Clin Orthop* 354:224-234, 1998.
96. **Lovett RW:** *The Etiology, Pathology, and Treatment of Diseases of the Hip Joint*. Edited, Boston, Geo. H. Ellis, 1891.
97. **Macieira-Coelho A, Diatloff C, Malaise E:** Concept of fibroblast aging in vitro: implications for cell biology. *Gerontology* 23:290-305, 1977.
98. **Mankin HJ:** The response of articular cartilage to mechanical injury. *J Bone Joint Surg Am* 64:460-466, 1982.
99. **Mann R, Yeong EK, Moore ML, Engrav LH:** A new tool to measure pressure under burn garments. *J Burn Care Rehabil* 18:160-163; discussion 159, 1997.
100. **Maquet P:** Le sourcil cotylidien, materialisation du diagramme des contraintes dans l'articulation de la hanche. *Acta Orthop Belg* 40:150-165, 1974.
101. **Maroudas A, Bullough P, Swanson SA, Freeman MA:** The permeability of articular cartilage. *J Bone Joint Surg Br* 50:166-177, 1968.
102. **Martin JA, Buckwalter JA:** Telomere erosion and senescence in human articular cartilage chondrocytes. *J Gerontol A Biol Sci Med Sci* 56:B172-179, 2001.
103. **Matthiass HH, Glupe J:** [The effect of immobilization and pressure stress on the joints]. *Arch Orthop Unfallchir* 60:380-396, 1966.
104. **Mavcic B, Antolic V, Brand R, et al:** Weight bearing area during gait in normal and dysplastic hips. *Pflugers Arch* 439:R213-214, 2000.
105. **Maxian TA, Brown TD, Weinstein SL:** Chronic stress tolerance levels for human articular cartilage: two nonuniform contact models applied to long-term follow-up of CDH. *J Biomech* 28:159-166, 1995.
106. **Meachim G:** Age changes in articular cartilage. *Clin Orthop* 64:33-44, 1969.
107. **Meachim G, Bentley G, Baker R:** Effect of age on thickness of adult patellar articular cartilage. *Ann Rheum Dis* 36:563-568, 1977.
108. **Naveilhan P, Baudet C, Jabbour W, Wion D:** A theory that may explain the Hayflick limit—a means to delete one copy of a repeating sequence during each cell cycle in certain human cells such as fibroblasts. *Mech Ageing Dev* 75:205-213, 1994.
109. **Nelson BH, Anderson DD, Brand RA, Brown TD:** Effect of osteochondral defects on articular cartilage. Contact pressures studied in dog knees. *Acta Orthop Scand* 59:574-579, 1988.
110. **Nicol K, Rusteberg D:** Pressure distribution on mattresses. *J Biomech* 26:1479-1486, 1993.
111. **Oikawa MA, Yoshihara T, Kaneko M:** Age-related changes in articular cartilage thickness of the third metacarpal bone in the thoroughbred. *Nippon Juigaku Zasshi* 51:839-842, 1989.
112. **Oreskes N:** Evaluation (not validation) of quantitative models. *Environ Health Perspect* 106 Suppl 6:1453-1460, 1998.
113. **Oreskes N, Shrader-Frechette K, Belitz K:** Verification, validation, and confirmation of numerical models in the earth sciences. *Science* 264:641-646, 1994.
114. **Parkkinen JJ, Lammi MJ, Karjalainen S, et al:** A mechanical apparatus with microprocessor controlled stress profile for cyclic compression of cultured articular cartilage explants. *J Biomech* 22:1285-1291, 1989.
115. **Pauwels F:** *Biomechanics of the Normal and Diseased Hip: Theoretical Foundations, Technique, and Results of Treatment*. Edited, Berlin, Springer-Verlag, 1976.
116. **Pauwels F:** Die Struktur der Tangentialfaserschicht des Gelenkknorpels der Schulterpfanne als Beispiel für ein verkörpertes Spannungsfeld. *Z Anat Entwick-lungsgesch* 121:188-240, 1959.
117. **Pedersen DR, Brand RA, Davy DT:** Pelvic muscle and acetabular contact forces during gait. *J Biomech* 30:959-965, 1997.
118. **Pemberton R, Osgood RB:** *The Medical and Orthopaedic Management of Chronic Arthritis*. Edited, New York, The Macmillan Company, 1934.
119. **Pereira DS, Koval KJ, Resnick RB, et al:** Tibiotalar contact area and pressure distribution: the effect of mortise widening and syndesmosis fixation. *Foot Ankle Int* 17:269-274, 1996.
120. **Polliack AA, Sieh RC, Craig DD, et al:** Scientific validation of two commercial pressure sensor systems for prosthetic socket fit. *Prosthet Orthot Int* 24:63-73, 2000.

121. **Poole AR:** Imbalances of Anabolism and Catabolism of Cartilage Matrix Components in Osteoarthritis. In *Osteoarthritic Disorders,* edited by Kuettner, KE, Goldberg, VM. Rosemont, IL, American Academy of Orthopaedic Surgery, pp. 247-260. 1994.
122. **Quesada P, Rash G, Jarboe N:** Assessment of pedar and F-Scan revisited. *Clin Biomech* (Bristol, Avon) 12:S15, 1997.
123. **Quinn TM, Allen RG, Schalet BJ, Perumbuli P, Hunziker EB:** Matrix and cell injury due to subimpact loading of adult bovine articular cartilage explants: effects of strain rate and peak stress. *J Orthop Res* 19:242-249, 2001.
124. **Rapperport DJ, Carter DR, Schurman DJ:** Contact finite element stress analysis of the hip joint. *J Orthop Res* 3:435-446, 1985.
125. **Reddel RR:** A reassessment of the telomere hypothesis of senescence. *Bioessays* 20:977-984, 1998.
126. **Repo RU, Finlay JB:** Survival of articular cartilage after controlled impact. *J Bone Joint Surg Am* 59:1068-1076, 1977.
127. **Rieck B, Paar O, Bernett P:** [Intra-articular pressure measurement. A new method for the use of the pressure measuring film "Prescale"]. *Z Orthop Ihre Grenzgeb* 122:841-842, 1984.
128. **Robling AG, Burr DB, Turner CH:** Partitioning a daily mechanical stimulus into discrete loading bouts improves the osteogenic response to loading. *J Bone Miner Res* 15:1596-1602, 2000.
129. **Rudd RG, Visco DM, Kincaid SA, Cantwell HD:** The effects of beveling the margins of articular cartilage defects in immature dogs. *Vet Surg* 16:378-383, 1987.
130. **Rushfeld PD, Mann RW, Harris WH:** Influence of cartilage geometry on the pressure distribution in the human hip joint. *Science* 204:413-415, 1979.
131. **Salter RB:** The biologic concept of continuous passive motion of synovial joints. The first 18 years of basic research and its clinical application. *Clin Orthop* 242:12-25, 1989.
132. **Salter RB:** Royal College Lecture, prevention of arthritis through preservation of cartilage. *J Can Assoc Radiol* 32:5-7, 1981.
133. **Short WH, Palmer AK, Werner FW, Murphy DJ:** A biomechanical study of distal radial fractures. *J Hand Surg* [Am] 12:529-534, 1987.
134. **Srakar F, Iglic A, Antolic V, Herman S:** Computer simulation of periacetabular osteotomy. *Acta Orthop Scand* 63:411-412, 1992.
135. **Sram RJ, Zudova Z:** Effect of the dose-fractionation on the frequency of chromosome aberrations induced in mice by TEPA. *Folia Biol* (Krakow) 21:58-67, 1973.
136. **Stormont TJ, An KN, Morrey BF, Chao EY:** Elbow joint contact study: comparison of techniques. *J Biomech* 18:329-336, 1985.
137. **Tackson SJ, Krebs DE, Harris BA:** Acetabular pressures during hip arthritis exercises. *Arthritis Care Res* 10:308-319, 1997.
138. **Tarr RR, Resnick CT, Wagner KS, Sarmiento A:** Changes in tibiotalar joint contact areas following experimentally induced tibial angular deformities. *Clin Orthop* 199:72-80, 1985.
139. **Treppo S, Koepp H, Quan EC, et al:** Comparison of biomechanical and biochemical properties of cartilage from human knee and ankle pairs. *J Orthop Res* 18:739-748, 2000.
140. **Turner CH:** Three rules for bone adaptation to mechanical stimuli. *Bone* 23:399-407, 1998.
141. **Valdevit A, Ortega-Garcia J, Kambic H, et al:** Characterization and application of thin film pressure sensors. *Biomed Mater Eng* 9:81-88, 1999.
142. **Videman T, Michelsson JE, Rauhamaki R, Langenskiold A:** Changes in 35S-sulphate uptake in different tissues in the knee and hip regions of rabbits during immobilization, remobilization the development of osteoarthritis. *Acta Orthop Scand* 47:290-298, 1976.
143. **Williams JM, Moran M, Thonar EJ, Salter RB:** Continuous passive motion stimulates repair of rabbit knee articular cartilage after matrix proteoglycan loss. *Clin Orthop* 304: 252-262, 1994.
144. **Withers HR:** Some changes in concepts of dose fractionation over 20 years. *Front Radiat Ther Oncol* 22:1-13, 1988.
145. **Witte H, Eckstein F, Recknagel S:** A calculation of the forces acting on the human acetabulum during walking. Based On in vivo force measurements, kinematic analysis and morphometry. *Acta Anat* 160:269-280, 1997.

IN VIVO HEALING AFTER CAPSULAR PLICATION IN AN OVINE SHOULDER MODEL

B.T. Kelly[1]; A.S. Turner[2]; M. Bansal[1]; M. Terry[1]; B.R. Wolf, M.D.[3]; R.F. Warren[1]; D.W. Altchek[1]; A.A. Allen[1]

ABSTRACT

Traditionally, arthroscopic management of shoulder instability has been reserved for patients with isolated Bankart lesions without any capsular laxity or injury. To date, there are no animal studies evaluating the healing potential of capsular plication and/or capsulo-labral repair. The purpose of this *in vivo* animal study was to determine if the histological capsular healing of an open capsular plication simulating an arthroscopic plication is equivalent to the more traditional open capsular shift involving cutting and advancing the capsule. Twenty-six skeletally mature sheep were randomized to either an open capsular plication simulating arthroscopic plication (n=13), or an open traditional capsular shift (n=13). A sham operation (n=4) was also performed involving exposure to visualize the capsule. Normal non-operated control shoulders were also analyzed. A pathologist blinded to the treatment evaluated both hematoxylin and eosin (H&E) sections and polarized light microscopy. Qualitative scoring evaluated fibrosis, mucinous degeneration, fat necrosis, granuloma formation, vascularity, inflammatory infiltrate and hemosiderin (0 to 3 points). Both the capsular plication and open shift groups demonstrated healing by fibrosis at the site of surgical manipulation. There were no statistical differences in the capsular healing responses between the two groups with regard to fibrosis, granuloma formation and vascularity. The open shift group demonstrated significantly more mucinous degeneration (p=0.038). Fat necrosis was present in 4/13 specimens in the open shift group and none in the capsular plication specimens. Both groups demonstrated disorganized collagen formation under polarized light microscopy. There were no differences between non-operated control specimens and sham surgery specimens. Our findings support the hypothesis that histologic capsular healing is equivalent between the plication group and the open shift group. In addition, the open shift group demonstrated significantly more changes indicative of tissue injury. This basic science model confirms capsular healing after simulated arthroscopic plication, providing support for arthroscopic capsular plication in practice.

INTRODUCTION

Shoulder stabilization has historically been performed via open surgical procedures.[2,8,24,26] Success rates following open stabilization have routinely been reported to be greater than 90%.[2,17,18,22,24,26,28,36] Development of more advanced arthroscopic techniques over the last two decades has provided a less invasive and potentially more efficacious means of addressing glenohumeral instability.[3,12,13,25,29,31] Although several early reports have shown that the management of shoulder instability through arthroscopic techniques has resulted in higher failure rates compared with open stabilization procedures,[15,16,27] more recently, investigators have demonstrated comparable clinical results between these two procedures.[8,10,12]

Arthroscopic stabilization has several advantages over open procedures including: more thorough documentation of intraarticular pathology, the ability to address associated injuries and improve cosmesis, greater postoperative motion, faster recovery and increased cost effectiveness.[1,6,15] It is becoming increasingly well accepted that shoulder instability primarily associated with labral pathology can successfully be addressed arthroscopically.[8,9,11,19] However, instability associated with excessive capsular laxity is still considered by some to be a relative indication for shoulder arthrotomy.[9] Nonetheless, recent advances in surgical technique and instrumentation have led to the performance of arthroscopic capsular plication in an increasing number of patients.[12] Preliminary clinical results of this procedure indicate that arthroscopic plication is an effective method of eliminating or significantly reducing excessive capsular laxity without the use of an arthro-

[1]Hospital for Special Surgery, New York, NY

[2]Colorado State University, Fort Collins, CO

[3]University of Iowa, Iowa City, IA

Correspondence:
Bryan T. Kelly, M.D.
The Hospital for Special Surgery
535 East 70th Street
New York, NY 10021
Telephone: 212.606.1159
E-mail: kellyb2847@hotmail.com



Figure 1. Capsular plication was performed using three interrupted horizontal mattress sutures shifting the capsule from an inferior to superior direction without cutting the capsule.

tomy.[3-5,12,37] To our knowledge, there are no animal studies nor is there basic science research evaluating the healing potential of the capsule after capsular plication performed in the manner that is required during the arthroscopic stabilization procedure. Histologic evaluation of capsular healing has not been well documented after any type of shoulder stabilization surgery, thus scientific evaluation and comparison of open capsular shift and arthroscopic plication has not been possible.

The purpose of this study was to evaluate the healing potential of side-to-side capsular placation via an open approach simulating arthroscopic capsular placation, compared to the healing potential of the more traditional open capsular shift involving cutting and advancing the capsule. Our primary hypothesis was that the capsular plication procedure would demonstrate similar histologic properties compared to the traditional open capsular shift. Thus, our first specific aim was to demonstrate that capsular plication is a viable surgical alternative for addressing redundant capsular tissue in the clinical arena. Our secondary hypothesis was that a sham operation group consisting of surgical exposure of the capsule without manipulation of the tissue, would demonstrate no significant differences in histology compared to non-operated limbs. Thus, our second specific aim was to demonstrate that the surgical approach and associated inflammatory mediators would, in and of themselves, have little effect on the capsular tissue. Validation of the potential to effectively address capsular laxity through arthroscopic capsular plication techniques using histological analysis is important to allow further advancement of these techniques.

METHODS

After Animal Institute Care and Use Committee (AICUC) approval was obtained, thirty skeletally mature Columbian X Rambouillet ewes were allocated for use. The thirty sheep were randomly placed into three groups: 1) capsular plication group (n = 13); 2) open shift group (n = 13); 3) sham operation (n = 4).

After standard prepping and draping, each of the shoulders was approached through a caudal (posterior) incision with the animal in lateral recumbency. The incision was made over the spine of the scapula and deepened to the level of the infraspinatus muscle tendon junction. The plane between the upper and lower portions of the infraspinatus was then developed to fully expose the caudal (posterior) capsule of the shoulder joint. For the capsular plication group, three interrupted horizontal mattress sutures were placed without disruption of the capsule, resulting in plication of the capsule (Figure 1). The sutures were placed midway between the proximal and distal portions of the caudal (posterior) capsule in line with the capsular fibers. The horizontal mattress sutures were placed so that 8 to 10 mm of capsular tissue was translated in a distal to proximal direction. For the open shift surgeries, a transverse incision was made in the caudal (posterior) capsule and the distal capsule was shifted proximally and sutured with three interrupted figure-of-eight sutures (Figure 2). The capsule was similarly shifted 8 to 10 mm with the open procedure. For the control animals, no further surgery was performed once the capsule was exposed. For all three groups, dissection down to the capsule was performed bluntly between muscle planes to minimize any soft tissue injury.

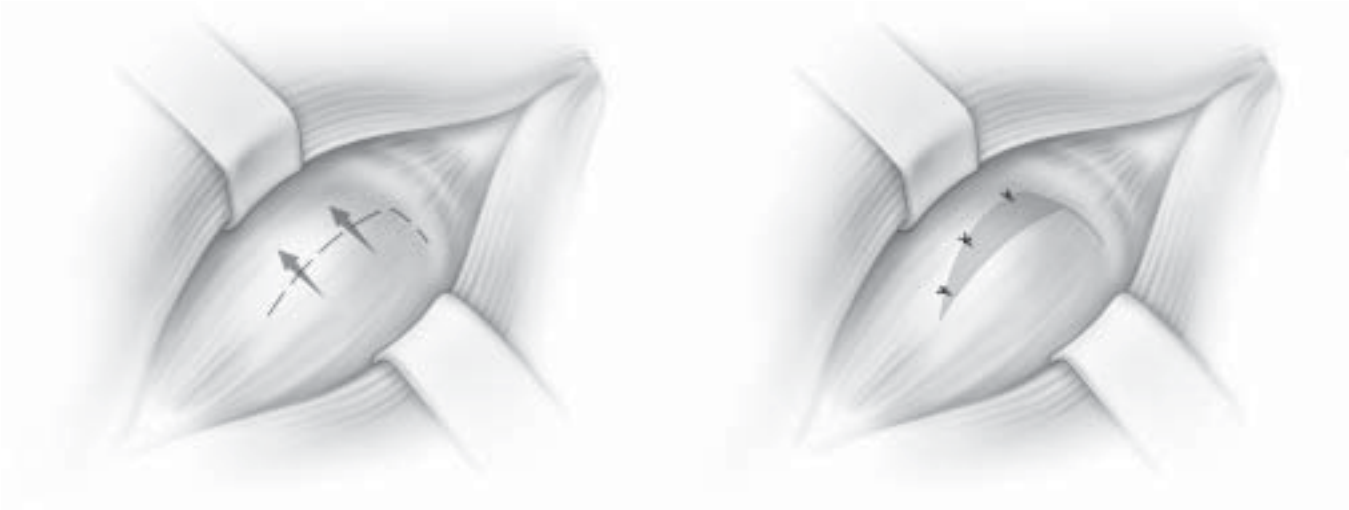

Figure 2. The open shift procedure was performed by cutting the capsule in a horizontal fashion, shifting it superiorly, and suturing it using three interrupted figure-of-eight sutures.

Figure 3. H&E-stained photomicrograph (2.5x) of the posterior capsule after the plication procedure was performed. This section demonstrates healing by fibrosis at the site of surgical manipulation.

Figure 4. H&E-stained photomicrograph (2.5x) of the posterior capsule after the open shift procedure was performed. Histologically, there were no differences between groups in terms of the size of the fibrotic scar.

Postoperative activity was restricted for the first two weeks. The limbs were not immobilized. At six weeks, the animals were sacrificed and both the operated and non-operated limbs were harvested for analysis. Fresh tissue samples of the entire caudal (posterior) capsule were dissected from a cranial (anterior) approach to avoid tissue injury. Hematoxylin and eosin sections were prepared and scored by an attending pathologist blinded to the procedure performed. Polarized light microscopy was performed to further assess collagen orientation.

Statistical Methods

Qualitative scoring evaluated fibrosis, mucinous degeneration, fat necrosis, granuloma formation, vascularity, inflammatory infiltrate and hemosiderin (0=none; 1=slight; 2=moderate; 3=severe). Mean values and standard deviations were calculated for each of the categories within each test group (open shift group, plication group, sham group and non-operated controls). The Mann-Whitney test was used for pairwise comparisons between: The plication versus open shift group; sham group versus the open shift group; sham group versus plication group; and sham group versus non-operated controls. A significance level of 0.05 was used for all tests. Collagen organization was evaluated and graded with polarized light microscopy (0=organized; 1=disorganized). Fisher's exact test was used to identify significant differences between groups, again with the p-value set at 0.05.

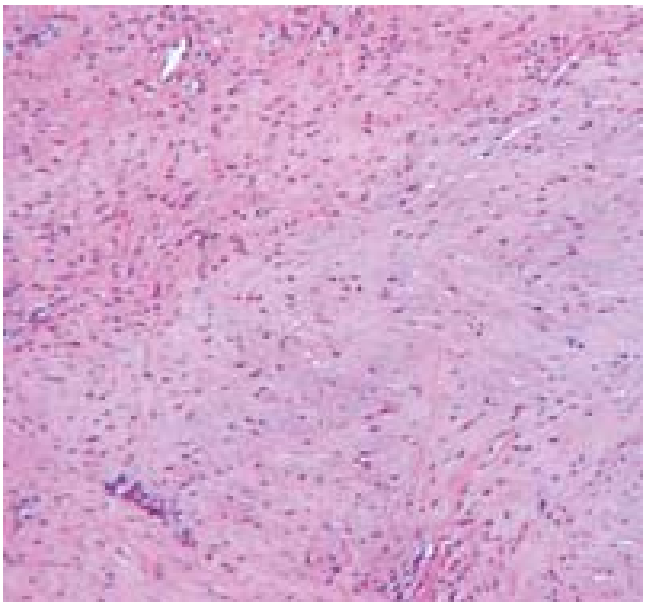

Figure 5. H&E-stained photomicrograph (10x) showing mucinous degeneration the posterior capsule after the open shift procedure.

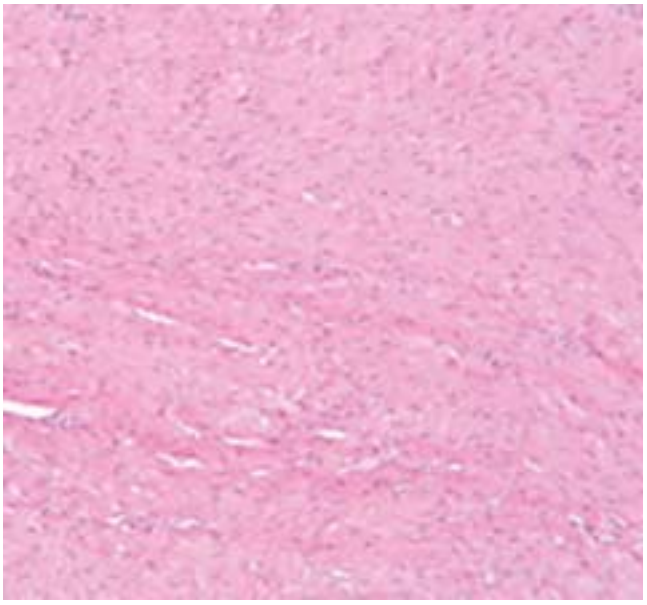

Figure 6. H&E-stained photomicrograph (10x) showing no mucinous degeneration in the posterior capsule after the capsular plication procedure. There was significantly less mucinous degeneration after capsular plication compared to open shift.

RESULTS

There were no gross failures at the capsule from either surgical procedure. There was one infection in the plication group that was noted at the time of dissection and confirmed with histological evaluation. This animal was eliminated from any statistical analyses. Both the capsular plication group (Figure 3), and the open shift group (Figure 4) demonstrated healing by fibrosis at the site of surgical manipulation. The size of the fibrotic scar was measured by the number of high-power fields. There were no statistically significant differences in the capsular healing responses between these two groups using the histological criteria of: fibrosis (p=0.13); granuloma formation (p=1); and vascularity (p=0.1). Both groups demonstrated disorganized collagen formation under polarized light microscopy. The open shift group (Figure 5), however, demonstrated significantly more mucinous degeneration compared to the plication group (Figure 6) (p=0.038). Furthermore, fat necrosis was present in 4/13 specimens in the open shift group (Figure 7), while no fat necrosis was present after any of the plication or sham surgeries.

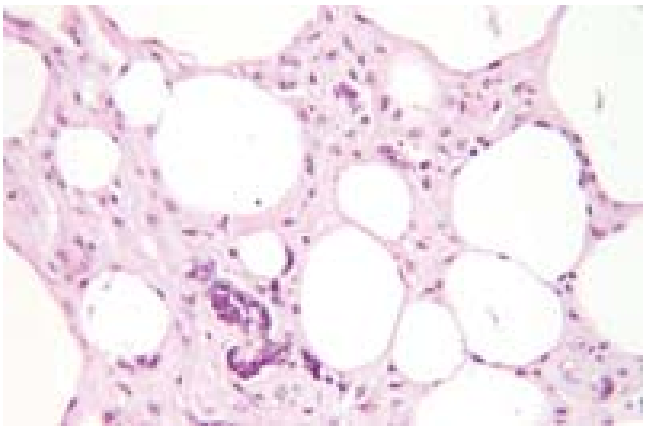

Figure 7. H&E-stained photomicrograph (10x) showing the presence of fat necrosis after the open shift procedure. No cases demonstrated fat necrosis after the plication procedure while four out of 13 of the open shift specimens demonstrated areas of fat necrosis.

The sham group, compared to the open shift group, had significantly less of the following histological findings: fibrosis (p=0.03); mucinous degeneration (p=0.03); granuloma formation (p=0.03); vascularity (p=0.03); and collagen organization (p=0.015).

Compared to the plication group, the sham group scored significantly lower in the histological criteria of: fibrosis (p=0.03); granuloma formation (p=0.03); vascularity (p=0.03); and collagen organization (p=0.015). There was no significant difference in the presence of mucinous degeneration in the sham group compared to the plication group (p=0.2) (minimal in both groups). There were no significant differences in the presence of inflammatory infiltrates between any of the three groups (minimal in all groups).

There were no significant differences in the histological appearance of the capsule after sham surgeries compared to non-operated controls in any of the qualitative scoring categories (Figures 8 and 9). Furthermore, under polarized light microscopy, both the sham surgery group and the non-operated controls demonstrated equally organized and well-aligned collagen.

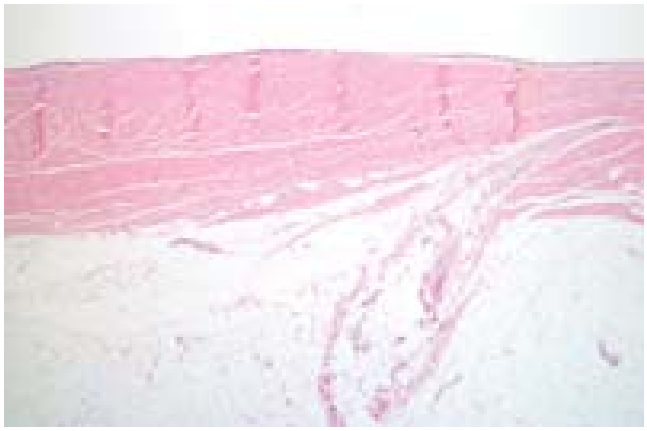

Figure 8. H&E-stained photomicrograph (2.5x) of the capsule after the sham surgery.

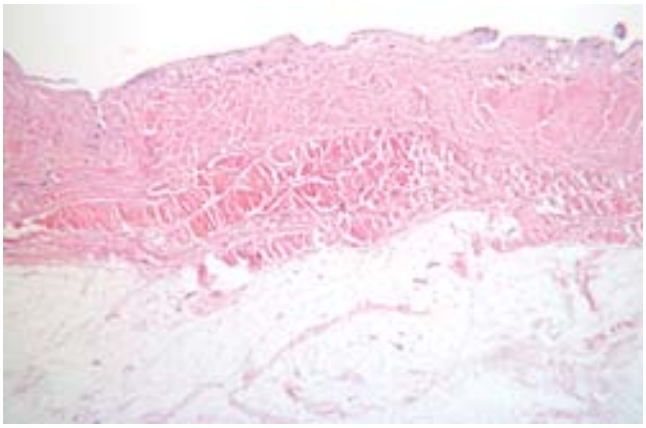

Figure 9. H&E-stained photomicrograph (2.5x) of the capsule in non-operated control animals. There were no differences in the histological appearance of the capsule in any of the qualitative scoring categories between the sham surgeries and non-operated control specimens.

DISCUSSION

Arthroscopic management of shoulder instability has become increasingly popular with several reports demonstrating comparable results to the more traditional open technique.[8,12,20,21,30] Previous reports have suggested that the success of the arthroscopic procedure is related to careful patient selection, with the best results occurring in patients with instability due to a discrete Bankart lesion without significant capsular laxity or injury.[8,32-35]

With the continued refinement of arthroscopic techniques, surgeons have begun to expand the indications of arthroscopy to patients in whom significant capsular laxity is a component of the instability pattern. There have been numerous reports demonstrating the clinical efficacy of arthroscopic posterior labral repair and capsular plication for recurrent posterior subluxation of the shoulder.[3-5,21,23,37] Recently, Kim et al.[20] reported a 4% recurrence rate in 167 patients treated with arthroscopic capsulolabral repairs for recurrent traumatic anterior instability. These authors emphasized the importance of adequate tensioning of the redundant anterior aspect of the capsule in addition to repair of the Bankart lesion, as plastic deformation of the capsular ligament may precede the failure of the anterior-inferior labral attachment.[7,20]

Successful re-tensioning of both the anterior and posterior capsule can be achieved arthroscopically by plication and proximal shift of the inferior aspect of the capsule. However, this is individualized depending upon the condition of the capsular tissue and the location of the capsular laxity. Cadaveric biomechanical studies have demonstrated the importance of tensioning different portions of the capsule in different arm positions.[14] A greater appreciation of the importance of both the placement of plication sutures and the position of the arm during tensioning will likely improve the results of selective capsulorrhaphy procedures. Unfortunately, there continues to be a lack of basic science evaluating the healing potential of capsule-to-capsule plication in the manner that is required for arthroscopic shoulder stabilization procedures.

The primary purpose of this project was to perform a histological evaluation of the healing potential of an open side-to-side capsular plication simulating arthroscopic capsular plication, and compare this to the healing potential of the more traditional open capsular shift involving cutting and advancing the capsule. Our findings confirmed the hypothesis that capsular healing was equivalent between the plication group and the open shift group. There were no differences in the size of the fibrotic scar, the amount of granuloma formation, or the degree of vascularity seen in the surgically manipulated tissue. In addition, the open shift group demonstrated significantly more changes indicative of tissue damage demonstrated by increased mucinous degeneration in the shifted capsular tissue, and the presence of fatty degeneration in nearly one-third of the open shift specimens. Evaluation of collagen organization by polarized light microscopy demonstrated disorganized collagen formation in both groups. However, these results represent early post-surgical healing (six weeks), and longer-term studies will be required to further evaluate the potential for maturation of fibrotic scar into organized collagen.

The most important limitations of this study were that an open approach was used to simulate an arthroscopic technique and the procedure was evaluated in an animal model. Unfortunately, there is no ideal animal model to truly assess arthroscopic techniques.

For both the open shift procedure as well as the plication procedure, an intermuscular caudal (posterior) approach through the two heads of the infraspinatus (the ovine infraspinatus is divided into a discreet upper and lower portion) was performed to access the posterior capsule. Preliminary dissections of the ovine shoulder revealed that the posterior capsule could be easily approached without detaching any musculotendinous structures. Unlike the human shoulder, the caudal (posterior) capsule was robust, and in most specimens, thicker than the cranial (anterior) capsule; thus it was felt to be an appropriate model to assess capsular tissue healing.

In order to confirm that the surgical approach itself and any potential inflammatory mediators would have little effect on the capsular tissue, a sham operation group consisting of surgical exposure of the capsule without manipulation of the tissue was performed and histological specimens were compared to non-operated limbs. We found that the capsular tissue from animals that underwent the sham operation was indistinguishable from non-operated control animals. Thus, we feel that the lack of tissue response seen in our control sham operation group suggests that the histological capsular healing in the plication group was truly related to the surgical intervention of capsular plication with suture placement.

The management of the capsule in the plication group did accurately simulate what is performed clinically during arthroscopic stabilization procedures. In fact, we believe that this animal model represents the worst-case scenario for capsule-to-capsule healing, because the intraarticular portions of the capsule were folded side-to-side without any prior abrasion or manipulation of the tissue, which is typically performed clinically in order to stimulate an inflammatory response. A potential explanation for the ability of this tissue to form fibrotic scar similar to that seen after an open shift, is that the actual penetration of the capsule with the suture needle results in sufficient tissue bleeding and inflammation to mount a healing response. However, we still recommend light abrasion of the capsule prior to plication in the clinical setting.

The previously reported inferior clinical results seen after arthroscopic plication relative to open shift for shoulder instability may be improved with current arthroscopic techniques. Most surgeons feel that arthroscopic stabilization procedures should be reserved for patients with isolated labral pathology without significant capsular injury or laxity. The patient criteria, however, is expanding and validation of the potential to effectively address capsular laxity through arthroscopic capsular plication techniques using histological analysis will provide further evidence that these procedures can be successfully performed. To date, we are aware of no scientific investigations that have looked at capsular healing after any type of shoulder stabilization procedure (open or arthroscopic). This basic science evaluation confirms the capsular healing potential after arthroscopic plication and supports its use in clinical practice. Future research in this area will address functional and biomechanical considerations to further delineate the role of arthroscopic management of excessive capsular laxity.

REFERENCES

1. **Allen, A. A., and Drakos, M. C.:** Arthroscopic instability repairs: are they as good as open? *Current Opinion in Orthopedics,* 12(4): 315-18, 2001.
2. **Altchek, D. W.; Warren, R. F.; Skyhar, M. J.; and Ortiz, G.:** T-plasty modification of the Bankart procedure for multidirectional instability of the anterior and inferior types. *J Bone Joint Surg Am,* 73(1): 105-12, 1991.
3. **Antoniou, J.; Duckworth, D. T.; and Harryman, D. T., II:** Capsulolabral augmentation for the management of posteroinferior instability of the shoulder. *J Bone Joint Surg Am,* 82(9): 1220-30, 2000.
4. **Antoniou, J., and Harryman, D. T., II:** Arthroscopic posterior capsular repair. *Clin Sports Med,* 19(1): 101-14, vi-vii, 2000.
5. **Antoniou, J., and Harryman, D. T., II:** Posterior instability. *Orthop Clin North Am,* 32(3): 463-73, ix, 2001.
6. **Barber, F. A.; Click, S. D.; and Weideman, C. A.:** Arthroscopic or open bankart procedures: what are the costs. *Arthroscopy,* 14: 671-4, 1998.
7. **Bigliani, L. U.; Pollock, R. G.; Soslowsky, L. J.; Flatow, E. L.; Pawluk, R. J.; and Mow, V. C.:** Tensile properties of the inferior glenohumeral ligament. *J Orthop Res,* 10(2): 187-97, 1992.
8. **Cole, B. J.; L'Insalata, J.; Irrgang, J.; and Warner, J. J.:** Comparison of arthroscopic and open anterior shoulder stabilization. A two to six-year follow-up study. *J Bone Joint Surg Am,* 82-A(8): 1108-14, 2000.
9. **Cole, B. J., and Warner, J. J.:** Arthroscopic versus open Bankart repair for traumatic anterior shoulder instability. *Clin Sports Med,* 19(1): 19-48, 2000.
10. **Cole, B. J., and Warner, J. J.:** Prospectively determined arthroscopic versus open shoulder stabilization: 2-6 year follow-up. *J Shoulder Elbow Surg,* 7: 313, 1998.
11. **Fealy, S.; Drakos, M.; Allen, A. A.; and Warren, R. F.:** Arthroscopic Bankart Repair: Experience With an Absorbable, Transfixing Implant. *Clinical Orthopaedics & Related Research,* 1(390): 31-41, 2001.

12. **Gartsman, G. M.; Roddey, T. S.; and Hammerman, S. M.:** Arthroscopic treatment of anterior-inferior glenohumeral instability. Two to five-year follow-up. *J Bone Joint Surg Am,* 82-A(7): 991-1003, 2000.
13. **Gerber, A., and Warner, J. J.:** Thermal capsulorrhaphy to treat shoulder instability. *Clin Orthop,* (400): 105-16, 2002.
14. **Gerber, C.; Werner, C. M.; Macy, J. C.; Jacob, H. A.; and Nyffeler, R. W.:** Effect of selective capsulorrhaphy on the passive range of motion of the glenohumeral joint. *J Bone Joint Surg Am,* 85-A(1): 48-55, 2003.
15. **Green, M. R., and Christensen, K. P.:** Arthroscopic versus open bankart procedures: a comparison of early morbidity and complications. *Arthroscopy,* 9: 371-4, 1993.
16. **Guanche, C. A.; Quick, D. C.; Sodergren, K. M.; and Buss, D. D.:** Arthroscopic versus open reconstruction of the shoulder in patients with isolated Bankart lesions. *Am J Sports Med,* 24(2): 144-8, 1996.
17. **Hovelius, L.:** Anterior dislocation of the shoulder in teen-agers and young adults. Five-year prognosis. *J Bone Joint Surg Am,* 69(3): 393-9, 1987.
18. **Jobe, F. W.; Giangarra, C. E.; Kvitne, R. S.; and Glousman, R. E.:** Anterior capsulolabral reconstruction of the shoulder in athletes in overhand sports. *Am J Sports Med,* 19(5): 428-34, 1991.
19. **Kim, S. H., and Ha, K. I.:** Bankart repair in traumatic anterior shoulder instability: open versus arthroscopic technique. *Arthroscopy,* 18(7): 755-63, 2002.
20. **Kim, S. H.; Ha, K. I.; Cho, Y. B.; Ryu, B. D.; and Oh, I.:** Arthroscopic anterior stabilization of the shoulder: two to six-year follow-up. *J Bone Joint Surg Am,* 85-A(8): 1511-8, 2003.
21. **Kim, S. H.; Ha, K. I.; Park, J. H.; Kim, Y. M.; Lee, Y. S.; Lee, J. Y.; and Yoo, J. C.:** Arthroscopic posterior labral repair and capsular shift for traumatic unidirectional recurrent posterior subluxation of the shoulder. *J Bone Joint Surg Am,* 85-A(8): 1479-87, 2003.
22. **Montgomery, W. H., III, and Jobe, F. W.:** Functional outcomes in athletes after modified anterior capsulolabral reconstruction. *Am J Sports Med,* 22(3): 352-8, 1994.
23. **Murrell, G. A., and Warren, R. F.:** The surgical treatment of posterior shoulder instability. *Clin Sports Med,* 14(4): 903-15, 1995.
24. **Neer, C. S., II, and Foster, C. R.:** Inferior capsular shift for involuntary inferior and multidirectional instability of the shoulder. A preliminary report. *J Bone Joint Surg Am,* 62(6): 897-908, 1980.
25. **Nelson, B. J., and Arciero, R. A.:** Arthroscopic management of glenohumeral instability. *Am J Sports Med,* 28(4): 602-14, 2000.
26. **Pagnani, M. J., and Dome, D. C.:** Surgical treatment of traumatic anterior shoulder instability in american football players. *J Bone Joint Surg Am,* 84-A(5): 711-5, 2002.
27. **Pagnani, M. J.; Warren, R. F.; Altchek, D. W.; Wickiewicz, T. L.; and Anderson, A. F.:** Arthroscopic shoulder stabilization using transglenoid sutures. A four- year minimum followup. *Am J Sports Med,* 24(4): 459-67, 1996.
28. **Rowe, C. R.; Patel, D.; and Southmayd, W. W.:** The Bankart procedure: a long-term end-result study. *J Bone Joint Surg Am,* 60(1): 1-16, 1978.
29. **Savoie, F. H., III, and Field, L. D.:** Thermal versus suture treatment of symptomatic capsular laxity. *Clin Sports Med,* 19(1): 63-75, vi, 2000.
30. **Savoie, F. H., III; Miller, C. D.; and Field, L. D.:** Arthroscopic reconstruction of traumatic anterior instability of the shoulder: the Caspari technique. *Arthroscopy,* 13(2): 201-9, 1997.
31. **Sekiya, J. K.; Ong, B. C.; and Bradley, J. P.:** Thermal capsulorrhaphy for shoulder instability. *Instr Course Lect,* 52: 65-80, 2003.
32. **Speer, K. P., and Warren, R. F.:** Arthroscopic shoulder stabilization. A role for biodegradable materials. *Clin Orthop,* (291): 67-74, 1993.
33. **Speer, K. P.; Warren, R. F.; Pagnani, M.; and Warner, J. J.:** An arthroscopic technique for anterior stabilization of the shoulder with a bioabsorbable tack. *J Bone Joint Surg Am,* 78(12): 1801-7, 1996.
34. **Warner, J. J.; Miller, M. D.; and Marks, P.:** Arthroscopic Bankart repair with the Suretac device. Part II: Experimental observations. *Arthroscopy,* 11(1): 14-20, 1995.
35. **Warner, J. J.; Miller, M. D.; Marks, P.; and Fu, F. H.:** Arthroscopic Bankart repair with the Suretac device. Part I: Clinical observations. *Arthroscopy,* 11(1): 2-13, 1995.
36. **Wirth, M. A.; Blatter, G.; and Rockwood, C. A., Jr.:** The capsular imbrication procedure for recurrent anterior instability of the shoulder. *J Bone Joint Surg Am,* 78(2): 246-59, 1996.
37. **Wolf, E. M., and Eakin, C. L.:** Arthroscopic capsular plication for posterior shoulder instability. *Arthroscopy,* 14(2): 153-63, 1998.

USE OF A NOVEL JOINT-SIMULATING CULTURE SYSTEM TO GROW ORGANIZED EX-VIVO THREE-DIMENSIONAL CARTILAGE-LIKE CONSTRUCTS FROM EMBRYONIC EPIPHYSEAL CELLS

Ilan Cohen, M.D.*, Dror Robinson, M.D., Ph.D.*, Eitan Melamed, M.D.* and Zvi Nevo, Ph.D**

ABSTRACT

A method for growth and maintenance of vital cartilaginous tissue is necessary for cartilage repair by in-vitro produced biologic implants. A previously tested perfusion system simulating joint activity was used. Whole epiphyses collected from thirty 11-day-old chick embryos were divided into two groups. One group was grown in a tissue culture dish for 10 days. The other group was placed in a perfusion system termed a joint-simulating device (JSD). After a period of 10 days, histology and immunohistochemistry were performed on five epiphyses from each group. Histologically, epiphyses grown in the device coalesced into a homogenous three-dimensional mass. The bridging tissue between individual epiphyses was highly cellular (PCNA staining positive) and was composed of mesenchymal stem cells as shown by expression of FGF receptor 3. No such tissue formed between epiphyses in the tissue culture dish and the epiphyseal cores were shown to be necrotic. The rest of the epiphyses were evaluated for radioactive sulfate incorporation into glycosaminoglycans (GAGs). A tenfold increase in sulfate incorporation occurred in epiphyses grown within the JSD as compared to the traditional culture method. In conclusion, embryonic epiphyses could be a suitable source for the ex-vivo growth of tissue-engineered cartilage constructs that might later be used as an in-vivo cartilage implant. The joint simulating device effectively maintains cartilage viability and bioactivity for as long as 10 days.

*Department of Orthopaedic Surgery, Rabin Medical Center, Golda Campus, Petach-Tikva, 7th Keren Kayemet St., 49372 Israel.

**The Department of Clinical Biochemistry, Sackler Medical School, Tel-Aviv, Israel.

Correspondence:
Eitan Melamed, M.D., Department of Orthopaedic Surgery,
Rabin Medical Center, Golda Campus, 7 Keren Kayemet Street,
Petach-Tikva, 49372, ISRAEL.
Tel: 972-3-9372236;
Fax: 972-3-9372501.
E-mail: eitanm@clalit.org.il
Res.: 61 Nordau Str., 63281,Tel-Aviv, ISRAEL
Tel: 972-52-3465610

INTRODUCTION

Cartilage essentially lacks self-repair capacity. In recent years, single autologous chondrocyte transplantation obtained by arthroscopic biopsy and grown in monolayer cultures has been advocated by several groups among first-line procedures for inducing repair and regeneration of articular cartilage defects.[1,2]

The major limiting factor of this method, however, is the need for a well-defined defect with surrounding healthy cartilage as a prerequisite. It is therefore not suitable for coverage of large areas of joints denuded of cartilage. These would require the development of other repair techniques.

One alternative which is still experimental on animal models is to transplant the cartilage cells or grown-in culture ectopically into the soft tissues of the recipient and allow them to grow and develop further in a favourable milieu with rich vascularization before their final implantation as articular cartilage substitutes.[3-5]

Another challenging option presently under investigation is cartilage tissue engineering using three-dimensional (3-D) cartilage constructs grown ex-vivo.[6-11] These constructs may involve scaffolds, adhesives, and cells and/or tissues grown under optimal conditions.[6-11] Previous experience, however, with such 3-D constructs under static culture conditions failed to support cell growth, and viability remained limited to the implant liquid interface and its close vicinity (50 m).[12] Proper growth of three-D cartilage ex-vivo, therefore, requires a milieu favoring chondrogenic proliferation and maturation. Various instruments have been devised lately to achieve this purpose. They appear under a variety of names: bioreactors, perfusion chambers, rotating vessels and joint-simulating devices. They all continuously irrigate the culture sample with fresh medium enriched with carbon dioxide and containing nutrients and growth factors in abundance.[6-11] Constant perfusion also avoids the local accumulation of waste products that might be toxic to the chondrocytes. The perfusion flow in itself has a strong influence upon the growing cartilage by mimicking hydrostatic and gravitational forces normally present in the joint, thereby modulating its biomechanical properties.[13-17] Thus, another advantage of perfusion devices is the possibility to apply hydrostatic loads, whether constant or cyclic, by controlling flow pressures, rates and directions.[13-17] The present study com-

pares the fates of embryonic chick epiphyses grown in regular static tissue culture and in a perfusion joint-simulating system.

MATERIALS AND METHODS

Cell Culture

Femoral and tibial epiphyses were aseptically harvested from thirty 11-day-old chick embryos. Dissection from the surrounding soft tissues was facilitated by pre-digestion with collagenase (1% in phosphate buffered saline, ICN Biomedicals Inc. Costa Mesa, CA). The epiphyses were suspended in culture medium (Dulbecco's minimal essential medium, Biological Industries, Beit Haemeq, Israel) to which 10% fetal calf serum (Biological Industries, Beit Haemeq, Israel) and antibiotics (Penicillin 10,000 units per ml, streptomycin 10 mg per ml, amphotericin B 0.025 mg per ml) were added.

Epiphyses were then divided into three groups: Two groups (1 and 2) were incubated in regular static culture dishes. A third group (3) was incubated within a closed laminar flow perfusion joint-simulating device (JSD) previously described and successfully used for growth and maintenance of embryonic cartilage of human origin.[18] The present experiment was carried out at a flow rate of 570ml/h, with a peak pressure of 150mmHg and a pressure pulse rate of 150 cycles/min. In previous experiments these values were found to be optimal.[18] All groups were cultured for a period of ten days.

Histology and Immunohistochemistry Assays

Ten epiphyses from each group were taken for histological evaluation. Epiphyses were immersed in formalin solution (4%, pH-7.4) containing 0.5% cetylpyridinium chloride for 24-48 hours, and later transferred into 4% formalin solution for an additional 48 hours. The samples were dehydrated with alcohols, embedded in paraffin, and sectioned by a standard microtome. Blocks were cut into two types of sections: 5μ-thick sections for routine histological and histochemical examinations on regular glass slides, and 20μ-sections glued on polylysine-coated glass slides for immunohistochemistry. The paraffin was removed with xylol and samples were rehydrated in serial alcohol. Each sample was stained with Mayer's hematoxylin eosin, Masson's trichrome and Alcian blue (pH1.0. and 2.5) using routine staining techniques.[19]

The presence of various specific antigens was assessed in tissue sections by immunohistochemistry: anti-fibroblast growth factor receptor 3 (FGFR3) antibody (1:100 dilution, Santa Cruz, Menlo Park, CA), anti-proliferating cell nuclear antigen (PCNA, 1:100 dilution, Dako, Glostrup, DK). Incubation with the primary antibody at optimal dilutions was performed in the humidity chamber for 16 hours at 15˚C. The slides were later incubated with a secondary antibody (Swine anti-rabbit 1:150 Dako, Glostrup, Denmark) amplified by peroxidase-antiperoxidase complex (1:150 Dako, Glostrup, Denmark). The substrate was diaminobenzidine (Dako, Glostrup, Denmark). Negative controls included second-layer-only and DAB-only preparations.

Cellular Viability Assays

Cellular viability was assessed by counting living cells with intact nuclei versus non-living cells within five square frames (of 50m X 50m each) that were randomly placed over the micro-section under 400 x magnifications. Average percentage of living cells could thus be calculated (Figure 3).

Biochemical Assays

The epiphyses of group 1 were boiled for five minutes so as to obtain non-viable tissue to serve as a control for non-specific sulfate uptake unrelated to GAG synthesis.[20,21] Five epiphyses from each group were then weighted and incubated for 24 hours with five μCi/ml of radioactive sulfate ($^{35}SO_4$ carrier-free). The reaction was stopped by boiling for five minutes. The samples were solubilized by papain (5% in buffer, ICN Biomedicals Inc., Costa Mesa, CA) digestion at 65˚C. The papain buffer contained 0.1M sodium acetate, 0.005M EDTA and 1mg/ml cysteine chloride. Dialysis against distilled water (containing 0.01M of Na_2SO_4 in the initial dialysate) for several days removed proteolytic papain products and non-incorporated sulfate precursor. Tissue remnants were discarded by centrifugation (10,000 rpm for 10 minutes at 4˚C). GAG molecules were precipitated by the addition of chondroitin sulfate (1 mg per ml, ICN Biomedicals Inc., Costa Mesa, CA) as a carrier of a concentrated NaCl solution and of cetylpyridinium chloride (ICN Biomedicals Inc., Costa Mesa, CA) during an overnight incubation. The precipitate was collected and re-solubilized in 2M calcium chloride. The latter dissociated the cetylpyridinium chloride molecules from the formed GAGs. The GAGs were isolated by precipitation in ethanol:ether (9:1 vol/vol) solution in the cold by centrifugation. The supernatant was discarded and the precipitate was re-solubilized in distilled water. Scintillation fluid was added (Hydroluma by 'LUMAC', Baanstraat 115-117, 6372AE Landgraaf, The Netherlands) and radioactive counts were measured in aliquots by a liquid scintillation counter (Downer Packard Tri-Carb, model 3380, Packard Grove, IL).[20,21]

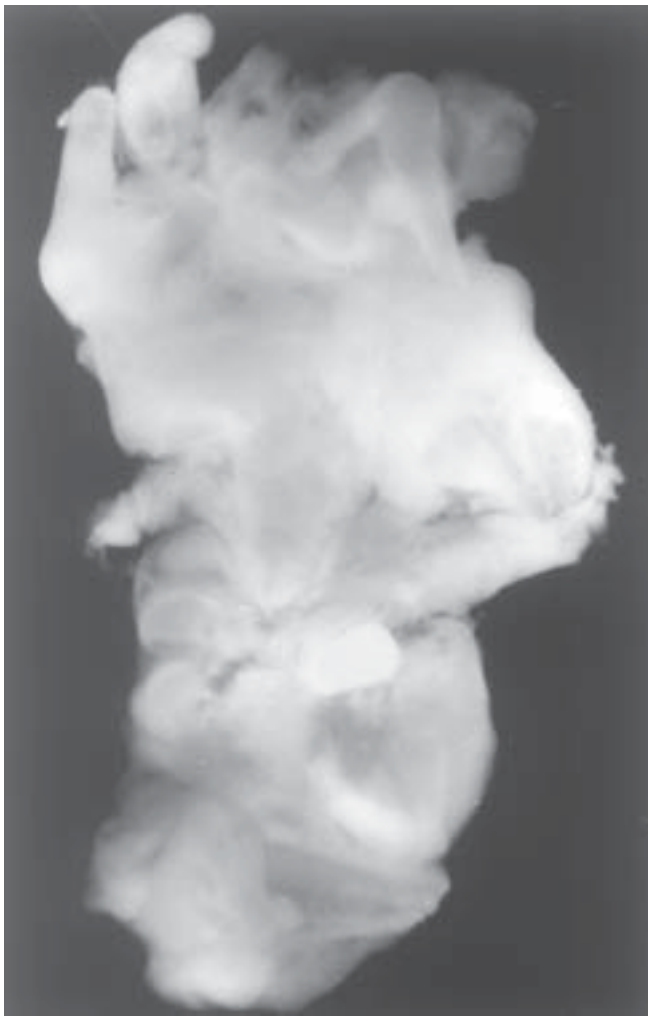

Figure 1. Epiphyses grown for 10 days in the joint-simulating device coalesced and formed three-dimensional cartilaginous tissue (x 6).

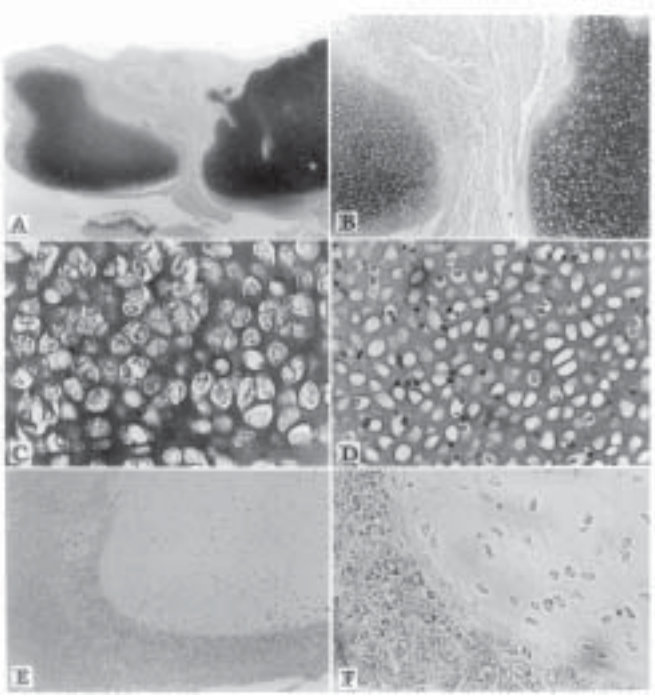

Figure 2. (a) Newly formed tissue bridges the gaps between the epiphyses (alcian blue, x 40). (b) The bridging tissue is highly cellular and has a fibrous-like appearance (alcian blue, x 100). (c) Cartilage grown in the joint simulator—the cells are uniformly viable even in the deepest layers (alcian blue, X 400). (d) Epiphyseal cartilage grown in a regular tissue culture—the peripheral zones appear viable, the cores however contain diffuse areas of cellular necrosis. Empty lacunae and cellular debris are ubiquitous (alcian blue, X 100). (e) The neo-cartilaginous tissue surrounding the epiphyses contains FGFR3 positive cells (anti-FGFR3 1:100, DAB detection, x 100). f) Same as (e), magnification X 400.

Statistical Analysis

The non-parametric Mann-Whitney Test (CSS, StatSoft Inc., Tulsa, OK) was used to compare the different groups since the variables were not normally distributed.

RESULTS

Comparative histological examination of the epiphyses grown under the two different conditions, regular static culture and joint-simulating device (JSD), yielded the following findings: Epiphyses in the JSD coalesced to form a three-D cartilaginous construct (Figure 1) with bridges of perichondral tissue interconnecting the individual epiphyses.

This newly formed tissue was found to be highly cellular and fibrous in nature (Figure 2, a & b). It was shown to express fibroblast growth factor receptor 3 (FGFR3) uniformly as determined by immunohistochemical techniques (Figure 2, e & f) while epiphyses grown in tissue culture dishes did not express FGFR3. Additional parameters indicated high rates of cellular proliferation as assessed by PCNA staining. Areas of active proliferation, staining positive with PCNA, were limited to the newly formed inter-epiphyseal connecting tissues. The epiphyses grown in the JSD appeared uniformly viable both superficially and in the depth of the three-D construct. The cells were found to be intact, seated within typical lacunae with a viable nucleus, abundant cytoplasm and surrounded by rich characteristic extra-cellular matrix heavily stained with alcian blue (Figure 2c). Sections of the cartilaginous tissue grown in the regular static culture dishes, on the other hand, showed large areas of central necrosis with empty lacunae, pyknotic nuclei and cellular debris scattered all over (Figure 2d). The extra-cellular matrix stained relatively poorly with alcian blue indicating depletion of GAG macromolecules during the culturing period (Figure 2d).

Cellular viability in terms of percentage of viable cells was found to be clearly in favor of the JSD as compared

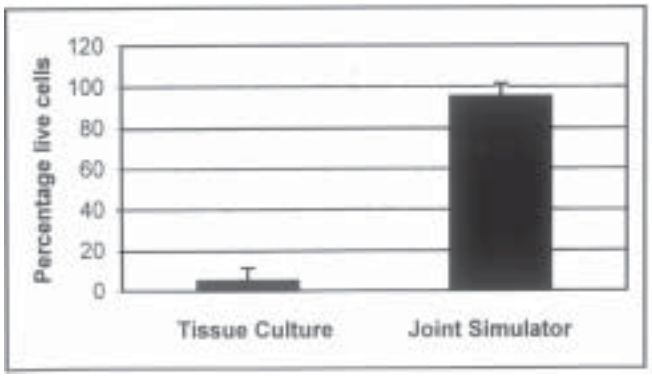

Figure 3. Cellular viability in the joint-simulating device is clearly superior to viability in tissue culture.

to the static tissue culture (Figure 3). A comparative biochemical study was run in parallel on other epiphyseal samples, comparing synthetic activity by ^{35}S incorporation into GAGs for an additional 24 hours after termination of the culturing period. The radioactivity figures obtained from ^{35}S-isolated-GAG molecules showed an elevated rate of sulfate incorporation in the epiphyses grown in the JSD of an order of magnitude tenfold higher than the rate measured in an equal amount of wet epiphyseal tissue grown in traditional static cultures (Table 1). The data revealed a significant higher level of sulfate incorporation with the JSD device (non-parametric Mann-Whitney test, $p<0.008$).

DISCUSSION

Since the first steps of growing cells in cultures, most findings and landmark achievements were obtained by employing cells in monolayers. Until recent years, culturing technologies failed to support growth and survival of three-dimensional cartilage chunks. Innovative approaches have yielded new perfusion systems that allow for cells and tissues to be maintained ex-vivo for relatively long periods of time,[13-18,22] even up to 90 days.[23]

This new field of tissue engineering is rapidly evolving, and present attempts focus on formation of composite cartilage tissue constructs with features that would make them suitable for in-vivo implantation. They should be inherently stable, big enough to cover up large defects and stiff enough to be cut and shaped as needed. They should not evoke any immunogenic response in the recipient nor transmit any acquired or genetic disease. To achieve that goal, cells are being cultured in conjunction with biomaterials that would act as scaffolds and with a variety of growth factors.[5,24]

The ideal scaffold has to be both biocompatible and biodegradable as it is gradually being replaced by the cells that synthesize their own inter-cellular milieu or matrix over time.[25] Many biomaterials are presently under investigation as potential scaffolds.[22]

TABLE 1

Radioactive sulfate ($^{35}SO4$) incorporation into isolated GAG molecules by epiphyses grown in a joint-simulating device compared to static tissue culture (CPM/mg wet weight, n=5, Mean ± S.D.).

Group 1 Control (boiled)	Group 2 Tissue culture	Group 3 Joint simulator
23 ± 9	1201 ± 561	11299 ± 2107

Chondrocytes from multiple sites in the body[26,27] and from various species were tested, including porcine, murine, bovine,[28] avian as well as human,[14,23] and reported results are basically similar: Matrix is gradually being deposited around the scaffold, and the constructs so formed have a macroscopic cartilaginous appearance although they are small in size. The inter-cellular matrix has a high content of both collagen II and glycosaminoglycans.[13,16,18]

Perfusion systems have been shown to yield constructs that are more cellular and that contain more inter-cellular matrix than those grown by ordinary tissue culture methods. Moreover, they have been found to have better mechanical properties. A major role in explaining these differences is being attributed to the flow of liquids. The application of shear stress in monolayer cultures resulted in overgrowth due to chondrocyte proliferation.[29] Modifications of perfusion flow rates and patterns as well as hydrostatic pressures had a major impact on both cellularity and sulfate incorporation by the matrix.[13-17,30] Vunjak-Novakovic and colleagues compared static culture to turbulent flow and to dynamic laminar flow in rotating vessels simulating microgravity. Constructs subjected to the latter conditions were the largest, contained the highest fractions of GAGs and collagen II in their matrices and had the best mechanical properties.[30]

Many technical questions still remain unanswered. We need to clarify how to modulate and integrate different physical parameters such as flow rates, flow pulses, reciprocal stream directions, mechanical hydrostatic pressures and shear stresses so that the impact upon the tissue will be optimal, thereby yielding a cartilaginous tissue of better quality.

Most researchers use mature chondrocytes of allogeneic or isogeneic origin and attempt to manipulate them into de-differentiation to obtain a state of rapid growth and abundant matrix formation.

It is our belief that embryonic cartilage is a better cell source for tissue engineering, as it already possesses these qualities inherently.[5] It may also be harvested in abundance from human embryos originating from miscarriages and planned pregnancy arrests.

In the current study, a self-manufactured perfusion system termed a joint-simulating device (JSD) was uti-

lized. We had previously tested the performance of the JSD with human cartilage of embryonic origin. It has been shown to be effective in keeping cartilage alive and metabolically active for a culture period of 10 days and was found to be highly superior to standard static cultures. The radioactive sulphate incorporation into GAG molecules was elevated tenfold as compared to the static culture.[18] In view of these promising findings, the present study was designed and conducted.

The results presented herein indicate that the JSD provides a better environment for in-vitro growth of chick embryo epiphyseal cartilage. The epiphyses show improved viability. The cells appear metabolically active as demonstrated by GAG production. These biochemical changes are further substantiated by the microscopic findings. The constant perfusion likely prevents central necrosis of the epiphyses.

An interesting observation relates to the coalescence of individual epiphyses into a 3-D macroscopically homogenous cartilage construct. Adherence of epiphyses to one another was apparently the result of specific stimulation of mesenchymal stem cells, which produced de novo tissue in the perfusion chamber of the JSD. These pre-cartilaginous mesenchymal cells originating from the perichondrium region have been previously shown to express fibroblast growth factor receptor 3 (FGFR3)[31] and have also been demonstrated to play similar roles in bunion formation and exostosis growth.[32] It seems that, very much like the situation in the developing embryo, no artificial scaffold is necessary when whole epiphyses are used, provided that satisfactory conditions for growth are available. Not using a scaffold would offer an obvious advantage. An artificial scaffold can be either stable or biodegradable. The former is not desirable, as it would permanently affect the biomechanical properties of the tissues. The latter is potentially toxic when it biodegrades and may evoke a foreign body reaction.

In conclusion, the results reported herein seem to imply that culturing embryonic epiphyses in perfusion chambers encourages formation of neo-cartilage in vitro. This tissue might later be used as implant material for joint reconstruction.[33] It is possible that the future use of epiphyses harvested from embryos would abolish the need for artificial scaffolds and would thus simplify the growing process of 3-D cartilaginous constructs.

REFERENCES

1. **Nevo Z, Robinson D, Horowitz S, Hasharoni A et al**: The manipulated mesenchymal stem cells in regenerated skeletal tissues. *Cell Transplant* 1998, 7: 63-70.
2. **Nixon AJ, Hendrickson DA, Lust G, Grande DA:** Chondrocyte laden fibrin polymers effectively resurface large articular cartilage defects in horses. Transactions from the 38th Annual Meeting, Orthopaedic Research Society, Washington DC 1992, 171.
3. **Staudenmaier R, Miehle N, Kleinsasser N, Ziegelaar B et al:** Tissue engineered cartilage in a prefabricated microvascular flap. *H N O* 2004, 52: 510-517.
4. **Chang SC, Tobias G, Roy AK, Vacanti CA et al:** Tissue engineering of autologous cartilage for craniofacial reconstruction by injection molding. *Plast Reconstr Surg* 2003, 112: 793-799.
5. **Levenberg S, Huang NF, Lavik E, Rogers AB et al:** Differentiation of human embryonic stem cells on three-dimensional polymer scaffolds. *Proc Natl Acad Sci USA* 2003, 100: 12741-12746.
6. **Brittberg M, Faxen E, Petersen L:** Carbon-fiber scaffolds in the treatment of early knee osteoarthritis. *Clin Orthop* 1994, 307: 155-164.
7. **Freed LE, Hollander AP, Martin I, Barry JR et al:** Chondrogenesis in a cell-polymer-bioreactor system. *Exp Cell Res* 1998, 240: 58-65.
8. **Freed LE, Langer R, Martin I, Pellis NR et al:** Tissue engineering of cartilage in space. *Proc Natl Acad Sci* 1997, 94: 13885-13890.
9. **Potter K, Butler JJ, Adams C, Fishbein KW et al:** Cartilage formation in a hollow fiber bioreactor studied by proton magnetic resonance microscopy. *Matrix Biol* 1998, 17: 513-523.
10. **Sharma B, Elisseeff JH:** Engineering structurally organized cartilage and bone tissues. *Ann Biomed Eng* 2004, 32: 148-159.
11. **Hutmacher DW:** Scaffold design and fabrication technologies for engineering tissue: state of the art and future perspectives. *J Biomater Sci Polym Ed* 2001, 12: 107-124.
12. **Nevo Z, Robinson D, Mendes DG, Halperin N:** Biomaterials involved in cartilaginous implants. In Wise DL (ed). *Encyclopedia of Biomaterials and Bioengineering.* NY, Marcel Dekker Inc, Vol (2) 1995, 1717-1740.
13. **Seidel JO, Pei M, Gray ML, Langer R et al:** Long-term culture of tissue engineered cartilage in a perfusion chamber with mechanical stimulation. *Biorheology* 2004, 41: 445-458.

14. **Raimondi MT, Boschetti F, Falcone L, Migliavacca F et al:** The effect of media perfusion on three-dimensional cultures of human chondrocytes. *Biorheology* 2004, 41: 401-410.
15. **Wendt D, Marsano A, Jakob M, Heberer M et al:** Oscillating perfusion of cell suspensions through three-dimensional scaffolds enhances cell seeding efficiency and uniformity. *Biotechnol Bioeng* 2003, 84: 205-214.
16. **Saini S, Wick TM:** Concentric cylinder bioreactor for production of tissue engineered cartilage. *Biotechnol Prog* 2003, 19: 510-521.
17. **Darling EM, Athanasiou KA:** Articular cartilage bioreactors and bioprocesses. *Tissue Eng* 2003, 9: 9-26.
18. **Cohen I, Robinson D, Cohen N, Nevo Z:** Storing live embryonic and adult human cartilage grafts for transplantation using a joint simulating device. *Biomaterials* 2000, 21: 2117-2123.
19. **Pearse AG:** *Histochemistry Theoretical and Applied*. Ed 3 Vol (1) & (2), Little Brown and Company, Boston 1972, 1968-1975.
20. **Nevo Z, Horwitz AL, Dorfmann A:** Synthesis of chondromucoprotein by chondrocytes in suspension culture. *Develop Biol* 1972, 28: 219-228.
21. **Robinson D, Mirovsky Y, Halperin N, Evron Z et al:** Changes in proteoglycans of intervertebral disc in diabetic patients. *Spine* 1998, 23: 849-856.
22. **Chang CH, Lin FH, Lin CC, Chou CH et al:** Cartilage tissue engineering on the surface of a novel gelatine-phosphate biphasic scaffold in a double chamber bioreactor. *J Biomed Mater Res* 2004, a preliminary Epub.
23. **Marlovits S, Tichy B, Truppe M, Gruber D et al:** Chondrogenesis of aged human articular cartilage in a scaffold bioreactor. *Tissue Eng* 2003, 9: 1215-1226.
24. **Gooch KJ, Blunk T, Courter DL, Sieminski AL et al:** IGF1 and mechanical environment interact to modulate engineered cartilage development. *Biochem Biophys Res Commun* 2001, 286: 909-915.
25. **Ochoa ER, Vacanti JP:** An overview of the pathology and approaches to tissue engineering. Ann N Y *Acad Sci* 2002, 979: 10-26.
26. **Xu JW, Zaporojan V, Peretti GM, Roses RE et al:** Injectable tissue-engineered cartilage with different chondrocytes sources. *Plast Reconstr Surg* 2004, 113: 1361-1371.
27. **Van Osch GJ, Mandl EW, Jahr H, Koevoet W et al:** Considerations on the use of ear chondrocytes as donor chondrium for cartilage tissue engineering. *Biorheology* 2004, 41: 411-421.
28. **Masuda K, Sah RL, Hejna MJ, Thonar EJ:** A novel two-step method for the formation of tissue engineered cartilage by mature bovine chondrocytes. *J Orthop Res* 2003, 21: 139-148.
29. **Von-der-Mark K, Conrad G:** Cartilage cell differentiation. *Clin Orthop* 1979, 139: 185-205.
30. **Vunjak-Novakovic G, Martin I, Obradovic B, Treppo S et al:** Bioreactor cultivation conditions modulate the composition and mechanical properties of tissue engineered cartilage. *J Orthop Res* 1999, 17: 130-138.
31. **Robinson D, Hasharoni A, Cohen N, Yayon A, et al:** Fibroblast growth factor receptor 3 as a marker for pre-cartilaginous stem cells. *Clin Orthop* 1999, 367(Suppl): 163(S)-175(S).
32. **Robinson D, Hasharoni A, Halperin N, Yayon A et al:** Mesenchymal cells and growth factors in bunions. *Foot & Ankle International* 1999, 11: 727-732.
33. **Reinholz GG, Lu L, Saris DB, Yaszemski MJ et al:** Animal models for cartilage reconstruction. *Biomaterials* 2004, 25: 1511-1521.

A THREE-DIMENSIONAL FINITE ELEMENT MODEL OF THE RADIOCARPAL JOINT: DISTAL RADIUS FRACTURE STEP-OFF AND STRESS TRANSFER

Donald D. Anderson, PhD[3]; Balachandra R. Deshpande, PhD[2]; Thomas E. Daniel, MS[1]; Mark E. Baratz, MD[4]

ABSTRACT

Displaced intra-articular distal radius fractures are difficult to treat, with numerous associated complications. The potential onset of post-traumatic osteoarthritis (OA) is a major concern. The relationship between malreduced intra-articular fracture of the distal radius and subsequent early onset of radiocarpal OA is clinically important, yet poorly understood. To better understand this presumed mechanical relationship, detailed information regarding joint loading, kinematics and associated stress distributions must be obtained. Toward this end, a three-dimensional finite element (3D FE) contact model of the radiocarpal joint has been developed, including the radius, lunate, scaphoid, articulations between these bones and selected soft tissues near the joint. FE model geometry was derived from cryomicrotome sections of a cadaver wrist. Radiocarpal contact stress distributions in the intact and simulated malreduced fracture conditions, previously collected using a cadaveric intra-articular fracture model, are used to establish validity of the computational model. Finally, a section of the distal radius constituting the entire lunate fossa was displaced 1, 2 and 3 mm to represent a depressed lunate die-punch fracture.

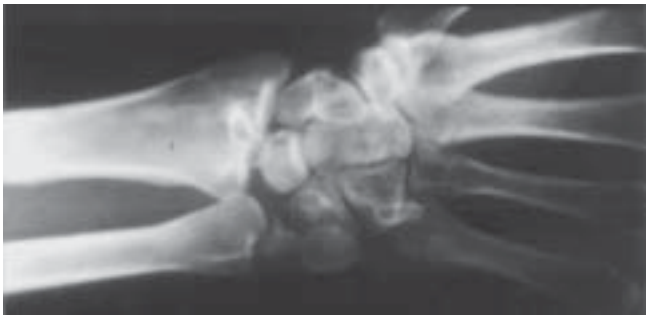

Figure 1. Natural history radiographic appearance of the wrist following healing of lunate die-punch-type fracture of the distal radius.

INTRODUCTION

Intra-articular fractures of the distal radius are a significant clinical problem. In a large number of such fractures, the normally smooth articular surface is greatly disrupted (Figure 1). The frequency of post-traumatic OA of the wrist after this injury has been reported to be as high as 40 to 65%,[1] and the clinical result is often a painful stiff wrist. It has been suggested that this is of particular concern in the younger patient with an incongruity of greater than 2 mm.[1] The development of OA following displaced intra-articular fractures has been attributed to a variety of factors, including the initial trauma to cartilage, elevated contact stresses and joint instability.[2] Although this is a current area of intense research, there remains little that can be done to reverse the initial cartilage trauma, and its influence on subsequent joint loading is poorly understood. With operative intervention, an incongruous joint can be restored to its original anatomical position. Joint instability can be addressed surgically, as well, but has received little attention overall in the management of intra-articular fractures.

Several authors have shown in clinical studies that radiographically-evident "step-offs" that persist following wrist fracture are highly correlated with the onset of early OA. Knirk and Jupiter found that OA developed in 91% of distal radius fractures that healed with any articular incongruity, and in 100% of those that healed with a step-off of 2 mm or more.[1] In contrast, they found a poor correlation for the extent of initial intra-articular

[1]Piziali and Associates
655 Skyway Rd., Suite 202
San Carlos, CA 94070

[2]Vehicle Crash Safety
Ford Motor Company
Dearborn, MI 48126

[3]Department of Orthopaedics and Rehabilitation
Department of Biomedical Engineering
Orthopaedic Biomechanics Laboratory
The University of Iowa, Iowa City, IA 52242

[4]Allegheny General Hospital
Department of Orthopaedic Surgery
1307 Federal Street, 2nd Floor
Pittsburgh, PA 15212

Correspondence:
Donald D. Anderson, Ph.D.
Orthopaedic Biomechanics Laboratory
The University of Iowa
2182 Westlawn Bldg
Iowa City, IA 52242-1100
Tel: 319-335-8135;
Fax: 319-335-7530;
E-mail address: don-anderson@uiowa.edu

disruption with the subsequent development of arthritis. Over half of their patients with arthritic changes had a fair or poor clinical result. Fernandez and Geissler confirmed that operative reduction of displaced intra-articular fractures reduced the incidence of OA to approximately 5%.[3] Bradway et al. found radiographic evidence of OA in only 9% of patients with a step-off of less than 2 mm, but in 100% of those with a step-off of 2 mm or more.[4] While they found that the worst results in their series tended to be in patients who had the most comminuted fractures, they noted that the prognosis was most directly related to a surgeon's ability to reconstruct a congruent distal radial articular surface. This belief represents the current clinical consensus,[5] and these findings in the wrist are generally consistent with clinical experience in other articular joints.[6,7]

The heterogeneity of injuries involved in clinical studies makes it difficult to arrive at specific conclusions regarding clinical outcome, especially since such series normally include only a relatively small number of patients at any one institution. The compilation of relevant clinical information regarding the management of these fractures has been complicated by patient-to-patient variability, and by the great range of fracture fixation devices used to treat them. The fractures are seldom contained within a single plane, and it is not uncommon for multiple fracture fragments to be present. Thus, the use of plain radiographs to assess the degree of fracture malreduction can be misleading, with their appearance sensitive to the obliquity at which radiographs are obtained.[8] The extent of concomitant ligamentous injury associated with these fractures has only recently begun to be appreciated. In most clinical studies, little attention has been given to the presence of these ligamentous injuries, and their potential influence upon post-injury mechanics has not been studied.

Finally, while clinical study may help to identify general relationships between fracture management and clinical outcome, it provides little information regarding relationships between the details of fracture management, the resulting alterations in joint loading and the eventual clinical outcome. Without this information, there is little rigorous guidance toward further improvement and refinement in intra-articular fracture management techniques. In order to begin to understand these relationships in the wrist, more information must be obtained regarding, first, the nature of stress distributions in the vicinity of the articular surfaces, and second, the associated kinematics of the carpal bones.

Laboratory research into the biomechanics of these intra-articular fractures offers an alternative means of investigating the mechanical implications of residual incongruity.[9-13] Although most agree that both mechanical and biological processes cause OA, the factors contributing to its onset are believed to be primarily mechanical in the specific clinical situation of post-traumatic OA. Altered juxta-articular geometry associated with the presence of residual surface incongruities is a logical mechanism by which the details of stress transfer across the joint could be changed following distal radius fracture. Any resulting abnormal stresses would likely be implicated in subsequent disease pathology. Trauma-related injury to the osteochondral zone beneath the articular surface is another potential contributing factor.[14] Our experience with a cadaver model of a simple intra-articular fracture suggests that changes in the proximal carpal row kinematics probably accompany irregularities in articular surface geometry, as well.[11]

The presumed mechanical relationship between residual surface incongruity and subsequent OA is poorly understood, in part because alterations in radiocarpal stresses accompanying fracture step-off are unknown. Cadaveric models (Figure 2) have demonstrated increased contact stresses (measured using pressure-sensitive film inserted into the joint space)[9,10,13] and altered kinematics (measured using electromagnetic sensors affixed to the bones)[11] associated with 1-, 2- and 3-mm step-offs simulating a depressed lunate fossa fracture. While useful in terms of establishing the details of surface loading, these data provide only limited insight into potential initiating factors in the degenerative sequence of events, since they yield little direct information regarding the full juxta-articular stress distribution. Analytical[15] or computational[16,17,18] modeling of articular joints can greatly complement experimental methods, especially when the two methodologies are tightly coupled.

A computational model of the radiocarpal joint permits parametric study of relationships between surgically relevant parameters and alterations in the radiocarpal stress distributions. A two-dimensional FE model of the radiocarpal joint was previously developed to investigate precisely this problem (Figure 3).[16] While providing reasonable agreement with measured contact stress distributions, it was limited to a single plane of analysis. In the case of the radiocarpal joint, in which out-of-plane motions are substantial, two-dimensional analyses are clearly of limited utility. Previous three-dimensional FE models of the wrist have been described in the literature; one restricted to the radiocarpal joint[17] and the other including the entire wrist.[18] Both models relied on CT for source geometry, thus the inclusion of articular cartilage was restricted to uniform thickness regions layered on the ends of the bones. Both also modeled contact in a fairly constrained and arbitrary fashion—Ulrich et al.[17] did not explicitly solve the ra-

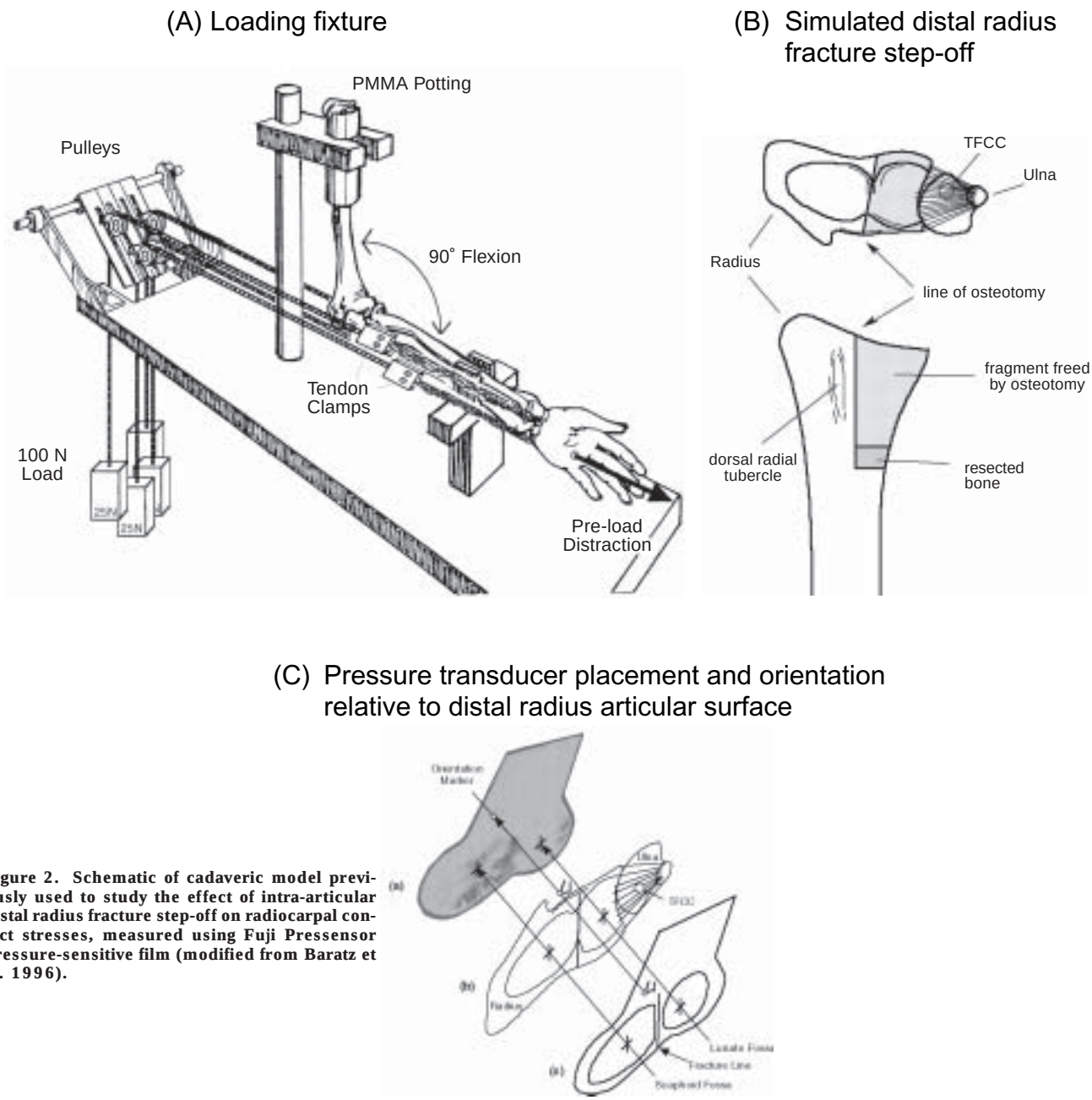

Figure 2. Schematic of cadaveric model previously used to study the effect of intra-articular distal radius fracture step-off on radiocarpal contact stresses, measured using Fuji Pressensor pressure-sensitive film (modified from Baratz et al. 1996).

diocarpal contact problem, while Carrigan et al.[18] constrained articulating bodies to small displacements.

In this paper, we briefly describe the development of a computational model of the radiocarpal joint that, in concert with our previously developed experimental models, provides insight that might one day lead to improvements in intra-articular fracture management techniques. FE-predicted stresses are compared with previously available experimental data reflecting radiocarpal stress distributions in order to validate the model. Finally, a step-off incongruity is introduced into the FE mesh.

METHODS

Radiocarpal geometry was obtained from cryomicrotome sections of a cadaver wrist. This procedure (performed at the Medical College of Wisconsin) involved freezing a cadaver forearm to a very low tem-

Maximum Contact Stress (MPa)		
Step-off (mm)	Experimental* (mean±SD)	FE
0	4.79 ± 0.97	4.87
1	5.66 ± 0.98	6.07
2	7.22 ± 1.19	6.93
3	8.36 ± 2.15	7.73

* n = 8 specimens

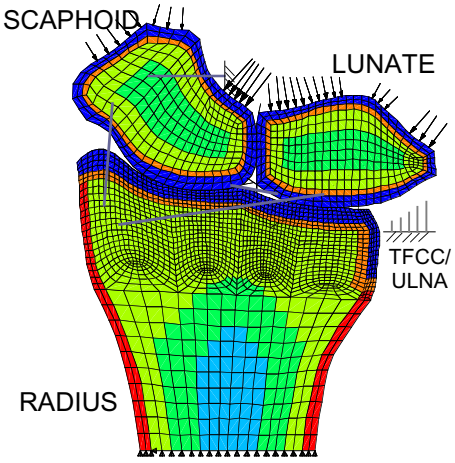

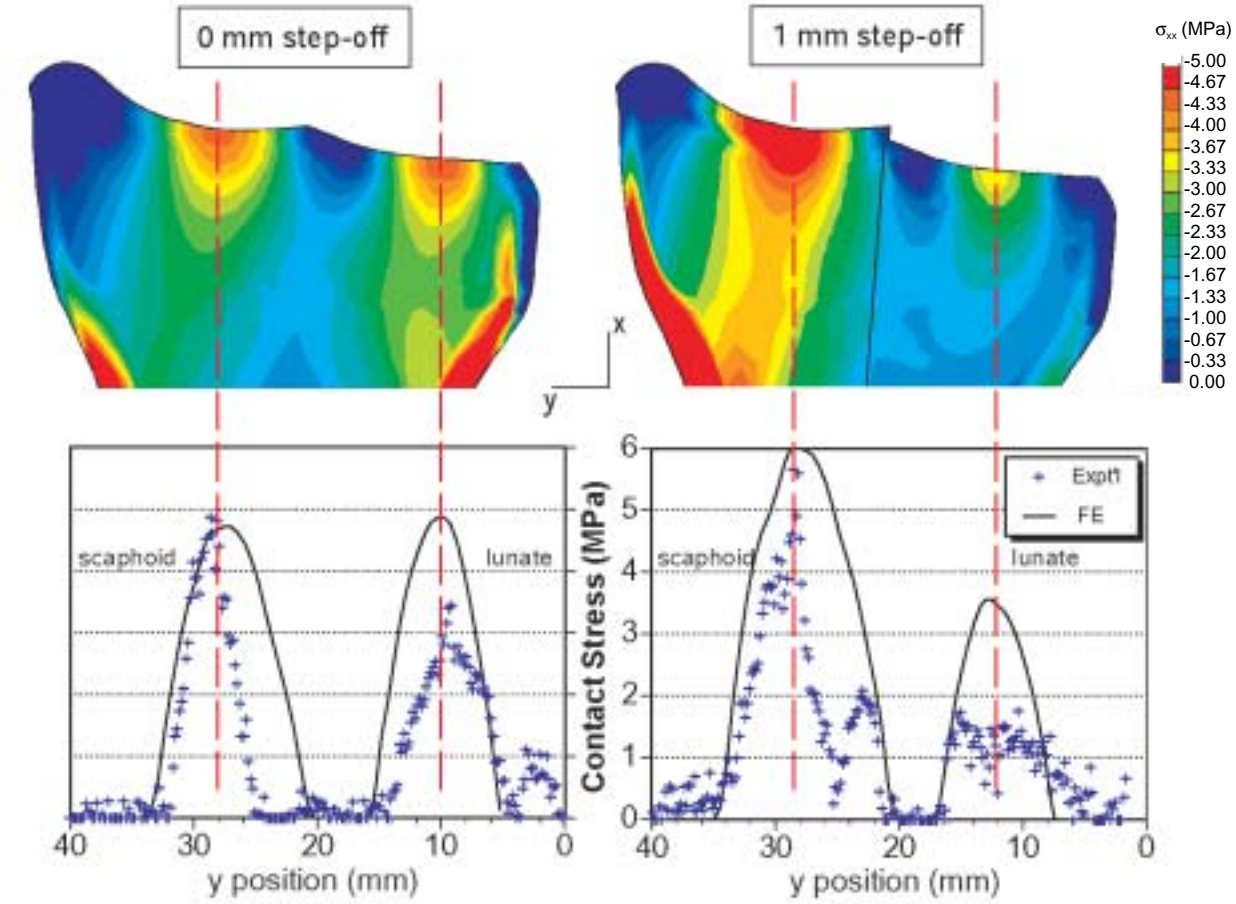

Figure 3. Contour plots of FE-computed stress distribution and graphs comparing computed contact stresses to those measured experimentally (NOTE: The symbols in the graphs are from a single experimental specimen).

perature, then sectioning it at specific intervals (0.5 mm) sagittally with a microtome. A total of 144 tissue slices were cut at 0.5 mm intervals from the mid-forearm through the fingers and photographed. Tissue boundaries were digitized and slices were subsequently registered. One such image is shown in Figure 4, allowing

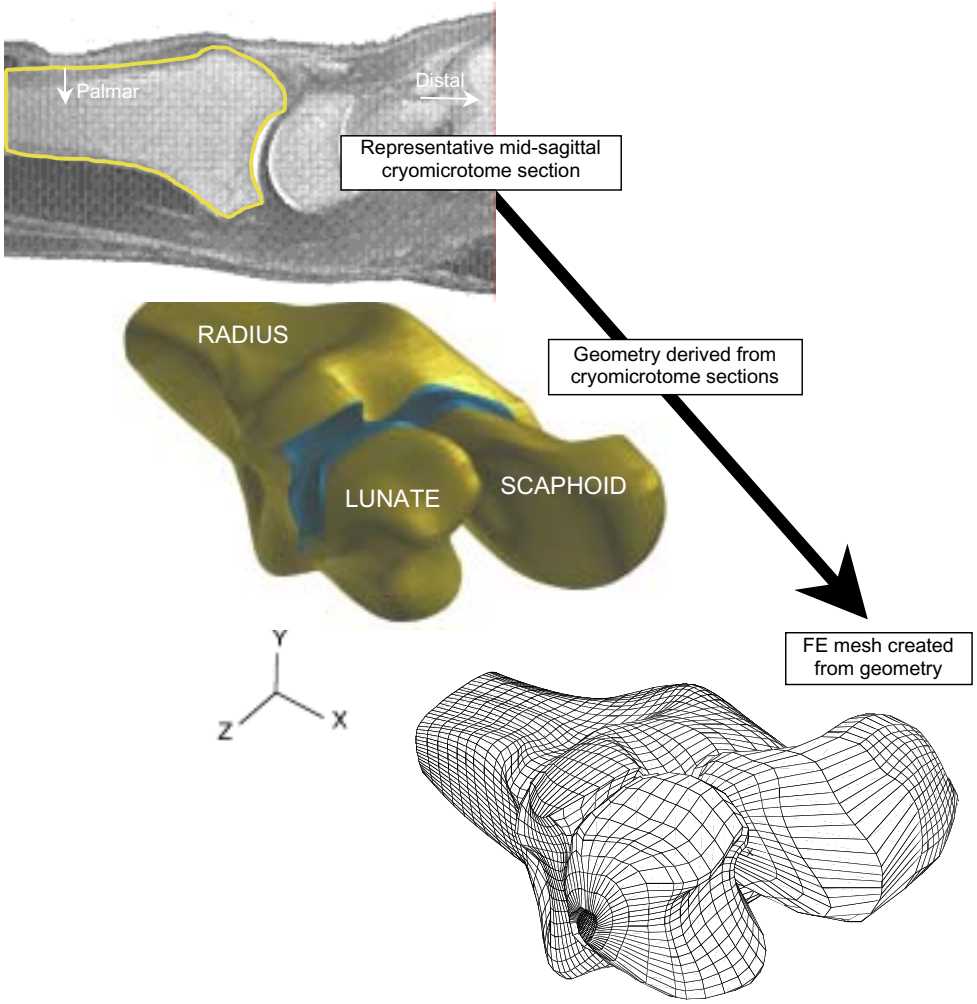

Figure 4. This schematic highlights the procedure for generating a 3D FE model of the radiocarpal joint from cryomicrotome source image data.

clear identification of boundaries for the radius, lunate, and the associated cartilage surface layers.

These image data were then processed to yield full three-dimensional reconstruction of relevant bone and cartilage geometry (Figure 4). Starting from the digitized boundary point data, solid modeling software (PATRAN, MSC Software) was used to create geometric entities (parametric bicubic surfaces) bounding the bone and cartilage regions. A volumetric mesh, consisting of eight noded hexahedral elements, was created on the geometry using mesh generation capability within PATRAN.

Linear elastic isotropic material regions representing cortical bone (E=13.8 GPa), three different densities of cancellous bone (1400 MPa, 690 MPa, and 345 MPa) and subchondral bone (2800 MPa) were defined. The Poisson's ratio of all bone elements was prescribed to be 0.3. Elements were assigned bone modulus values according to their distance from the outer cortical shell, with progressively less dense cancellous regions from the cortex to the center of the bones. After a mesh

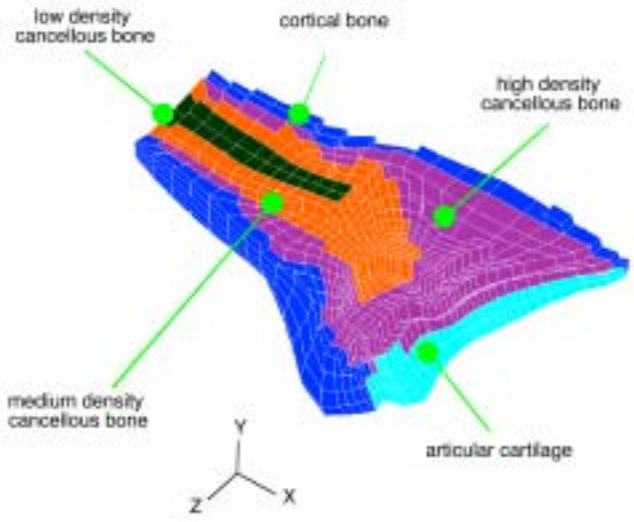

Figure 5. This cut-away view of the distal radius FE mesh shows the prescribed material property distribution.

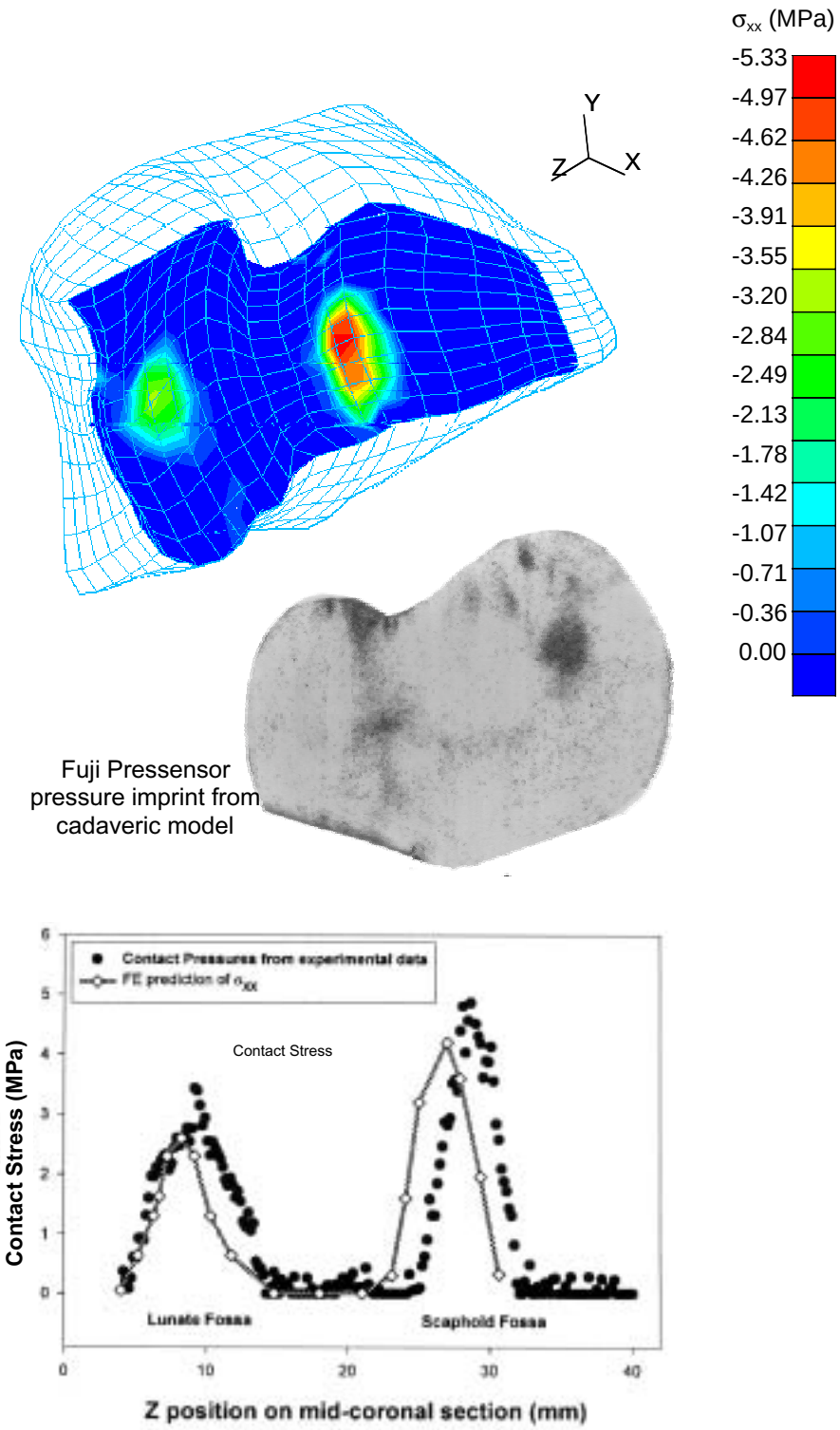

Figure 6. Computed contact stress distribution on the distal radius articular surface, with inset of contact stress imprint from cadaveric model for comparison.

was created, material property distribution was assigned to the mesh based on the proximity of element centroid locations to the cortex using custom-written PATRAN subroutines. The resulting mesh is depicted (Figure 5) in a mid-coronal view of the radius.

Cartilage elements were meshed across the articular surfaces of the radius, scaphoid, and lunate. These elements were assigned a modulus of 10 MPa, and a Poisson's ratio of 0.45. Relevant wrist ligaments were modeled as piecewise linear spring elements. These included the radiolunate, radioscaphoid, scapholunate and scaphotriquetral ligaments. The spring constants assigned for all ligaments were taken from the literature.[15] While the ulna contributes structurally to support the wrist joint, it was not explicitly modeled as a continuum. The structural support provided by the ulna through the triangular fibrocartilage complex (TFCC) was included by modeling TFCC/ulnar support as a parallel array of compressive springs attached from fixed nodes to the lunate.

Contact elements (3D slidelines) were defined on the articulations between the radius and lunate, radius and scaphoid, and scaphoid and lunate. These elements allowed for finite sliding between the contacting bodies and accommodated a non-zero frictional coefficient of 0.01. The entire proximal end of the radius was fixed, and two different mid-carpal load/displacement driving conditions were studied. In one case, mid-carpal loads were applied on the distal surfaces of the lunate and scaphoid (force control). These loads were obtained from a previously reported analysis.[15] In another case, experimentally recorded carpal bone motions were used to drive the FE model via applied displacements (displacement control). The source kinematic data reflecting carpal bone motionwas recorded by rigidly attaching electromagnetic sensors[19] (3Space Tracker,

Polhemus, Inc.) to the lunate and scaphoid during application of a 100 N load across the radiocarpal joint.[11] These displacement data were scaled and applied to the carpal bone FE models.

The FE solutions were obtained using a large displacement static analysis in ABAQUS FE software (ABAQUS, Inc.) on a Cray C90 at the Pittsburgh Supercomputing Center. The average analysis time for the models (nominally 13,000 degrees of freedom) was about 700 CPU seconds.

One of the objectives of the FE modeling undertaken was to study the effect of articular incongruities on the stress distribution in the joint. Toward this end, the FE mesh was modified to reflect the depressed lunate die-punch fracture simulated experimentally. A section of the distal radius mesh constituting the entire lunate fossa was freed from its neighboring elements, and displaced 1, 2 and 3 mm along the long axis of the radius. This was accomplished by removing elements at the base of the fragment, and then tying the nodal degrees of freedom at the fragment base to their nearest neighboring nodes on the remainder of the radius using tied multi-point constraints (MPC's). The model was driven using carpal kinematic data obtained for the corresponding step-off case. Computed contact stresses were then compared to previous experimental recordings of contact stress obtained in the cadaveric fracture step-off studies.

RESULTS

The results from the FE simulations reflect two distinct zones of contact on the distal radius, one each for the scaphoid and the lunate (Figure 6). Large displacements of the lunate and scaphoid were computed in the course of the solution. Adequate mesh refinement was established by performing a mesh convergence study considering three distinct levels of mesh sizes. The coarsest mesh had 3229 elements and the most refined mesh had 8980 elements. For the force control case, applied loads corresponded to a force of 100 N distributed over the distal surfaces of the lunate and the scaphoid. The maximum contact stress predicted in force control was 4.6 MPa on the scaphoid fossa. The resulting loads were distributed as 53 N through the scaphoid fossa and 49 N through the lunate fossa, consistent with previously reported results. The mesh convergence study showed that as mesh refinement was increased, the computed maximum contact stress approached the experimentally reported maximum contact stress value of 4.8 MPa (averaged over eight forearms tested).[10]

In displacement control, the resulting radiocarpal contact stress distribution also showed two distinct zones of contact (one each on the lunate and scaphoid fossa). The maximum predicted contact stress value was 5.3 MPa and it occurred on the scaphoid fossa in a more dorsal location than computed with the force control condition.

Figure 7a shows a close-up of the radiocarpal articulation including a 1-mm step-off. In the presence of a 1-mm step-off of the lunate fossa, the computed contact stress distributions shifted ulnarly (Figure 7b), as was observed experimentally. As the magnitude of step-off increased, there was a continued trend toward unloading of the lunate fossa, increased loading in the scaphoid fossa and a shift in location of maximum stress on the scaphoid fossa toward the fracture line. These findings are all consistent with our previously published results obtained in a cadaveric step-off model.[10]

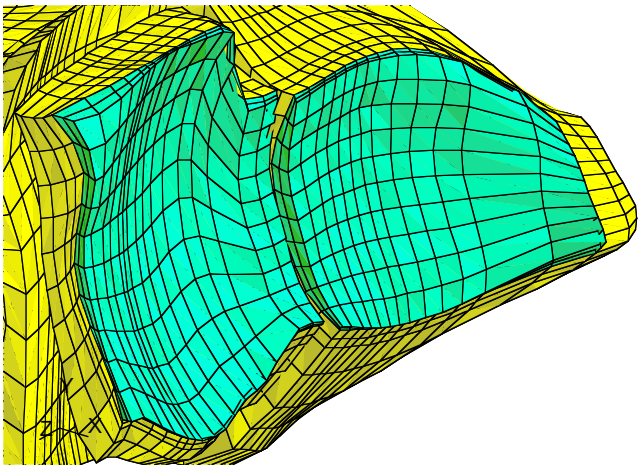

Figure 7A.

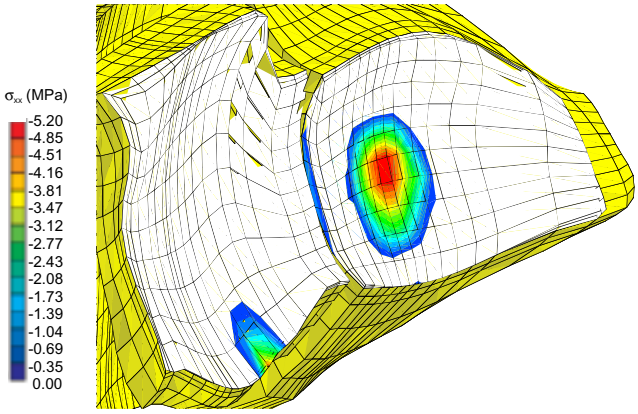

Figure 7B.

Figure 7. Simulated distal radius without step-off (A) and with 1-mm step-off (B) on the FE mesh of the distal radius articular surface with computed contact stress distribution shown.

DISCUSSION

One of the motivations for this research was the need for a more accurate three-dimensional representation of multibody contact in the radiocarpal joint with which to study juxta-articular stress distributions following imprecise fracture reduction. A high-fidelity 3D FE mesh was generated from cryomicrotome sections of a cadaver forearm. The resulting 3D model incorporated finite sliding large deformation contact modeling capabilities not previously used in articular joint simulation. The model was run under force and displacement control in independent simulations. The force control analysis was performed to establish the utility of this general FE approach. The very close agreement of FE predictions to experimental results obtained with force control was highly encouraging, even if the kinematics of the carpal bones were somewhat circumscribed. Displacement control of the FE model was then implemented to allow simulation of intra-articular fracture step-off utilizing previously collected experimental data reflecting radiocarpal kinematics in a cadaver forearm subjected to static loading.

The 3D radiocarpal FE model exhibited behavior consistent with findings from earlier models of joint contact. The predicted compressive strains (ε_{xx}) on the cartilage were on the order of 25-30%, reaffirming the function of cartilage as a load-distributing layer. The role of the subchondral plate in transferring the load applied on the joint surface to the cortical shell was also affirmed.

The load carried by the springs representing the TFCC was around 20% of the total applied load that agreed well with prior analytical models,[15] in which the TFCC/ulnar component of the total load on the wrist was calculated to be 22%. In previous experimental studies, this component was determined to be around 18% in an intact forearm when the wrist was in a neutral position,[20] and around 8% with ulnar deviation of the wrist.[15] In reality, the ulna is a complex structure, and its shape and position with respect to the carpus influences the load transfer at the wrist.

Another important finding relates to the maximum shear stress at the interface between the cartilage and subchondral bone on the radius. Maximum shear stress levels at the deepest (fourth layer of elements) level of cartilage were higher than those seen in more superficial layers. The location of this maximum shear corresponded to the rim of the contact area. Cartilage is a nearly incompressible material (υ=0.45), and the high compressive contact stresses on the surface generate large transverse (shear) deformations. Immediately beneath the cartilage, the subchondral plate, by virtue of its much smaller Poisson's ratio (υ=0.3) and much higher elastic modulus, resists this transverse deformation leading to high stresses at the cartilage-subchondral bone interface. This shear stress is proportional to the longitudinal (compressive) stresses in more superficial layers. Any aberrant behavior in the joint that gives rise to abnormal local contact stresses would directly influence the maximum shear at the deeper levels of cartilage. Elevated levels of shear stress at the osteochondral junction have been suggested to be initiators of fissures in the deeper zones of cartilage as observed in clinical OA.[2]

The success of any type of modeling technique depends upon its being validated using previously established methods. In the present situation, experimental methods employing pressure-sensitive film have been successful in measuring the contact pressures on the articulating surfaces of the radiocarpal joint.[9,10,12] Comparing the FE-predicted stress distribution on the articular surface to the experimental measurements forms a sound basis for validating the FE model. However, a number of important guidelines need to be followed before such comparisons can be made. Most importantly, it is necessary to ensure that the FE model accurately represents the experimental loading conditions. Large deformation FE contact simulations are sensitive to small changes in initial appositions of the contacting bodies, making it critical to ensure that the carpal bones are in the same relative positions and orientations in the computational model in comparison with the experimental cadaver specimen.

For the present model, a number of unique situations confounded validation efforts. The specific cadaver specimen used to generate the base geometry for the FE model was not first tested in our experimental protocol. This implied that, before applying the experimental boundary conditions to the FE model, a one-to-one correspondence had to be established between the bones of the model and of the cadaver specimen used in the experiments. To make this comparison, data representing the boundary of the bones of the experimental cadaver specimen were necessary. Although available, the data points were few in number (compared to the cryomicrotome-based data). These data were collected by manually digitizing the outer surfaces of the bones using an electromagnetic digitizing stylus. The combination of these two factors resulted in a less-than-ideal situation for establishing correspondence. In addition, no contact pressure measurements were made for this particular cadaver specimen. Contact stress distributions were available for a number of other specimens, but for which no bone boundary information was available for establishing post hoc correspondence. The cadaver specimen, which was used for establishing cor-

respondence with the FE model, provided the kinematic data of the carpal bones when the wrist was taken from an unloaded to a fully loaded state.

Another limitation relates to constitutive treatment of articular cartilage. Prior FE models of joint contact that have placed emphasis on accurate description of cartilage constitutive behavior have tended to be geometrically simple.[21-24] In real joints, as demonstrated by the present model, articular surfaces tend to be highly irregular and cartilage thickness varies as a function of location. Such variations cannot be adequately represented with simplistic geometric representations of articular joints. The advantage that the present model offers is thus obvious. It can couple the sophistication of material models with true geometric representation of the joint. The ABAQUS FE code utilized in this study has a poroelastic material capability, which can emulate the biphasic behavior of cartilage. Poroelastic modeling provides capabilities for representing coupled pore fluid diffusion/stress analysis involving partially or fully saturated fluid flow. Incorporating more complex material definitions would be a straightforward extension of the present FE model.

Despite the previously mentioned limitations, the present three-dimensional FE model of the radiocarpal joint is the first attempt at accurately characterizing articular joint contact stresses using existing modeling techniques. The utility of the model lies in the fact that it can now be used as the baseline for making any modifications that would potentially increase model sophistication and applicability. The model has potential to provide a clinician with rigorously established guidelines for treatment of intra-articular fractures. Clinical series have recognized the relationship between the degree of residual articular incongruities and eventual degenerative changes.[1] The FE-predicted results provide quantitative descriptions of the load transfer mechanism through the joint, and therefore potentially reinforce the decision-making process by detailing the efficacy of a treatment procedure. Additionally, the model has capability to incorporate the structural contributions of fracture fixation devices that are conventionally employed to promote faster healing. In this scenario, the clinician, with the help of the model, can decide which type of fixation technique/device is the most suitable one for a specific wrist. This means that the models have to be more patient-specific, and present advancements in the field of musculoskeletal imaging, combined with the availability of faster computers, make such a scenario possible in the foreseeable future.

ACKNOWLEDGMENTS

The financial support of the Whitaker Foundation (DDA) is gratefully acknowledged. This research was also supported in part by grant number MSS950003P from the Pittsburgh Supercomputing Center, sponsored by the National Science Foundation.

REFERENCES

1. **Knirk, J.L. and Jupiter, J.B.:** Intra-articular fractures of the distal end of the radius in young adults. *J Bone Joint Surg* 68A:647-59, 1986.
2. **Radin, E.L., Martin, R.B., Burr, D.B., Caterson, B., Boyd, R.D., and Goodwin, C.:** Mechanical factors influencing cartilage damage. *Osteoarthritis, Current Clinical and Fundamental Problems*. J.G. Peyron (ed.), CIBA-Geigy, France, 90-9, 1985.
3. **Fernandez, D.L. and Geissler, W.B.:** Treatment of displaced articular fractures of the radius. *J Hand Surg* 16A: 375-84, 1991.
4. **Bradway, J.P., Amadio, P.C., and Cooney, W.P.:** Open reduction and internal fixation of displaced, comminuted, intra-articular fractures of the distal end of the radius. *J Bone Joint Surg* 71A:839-47, 1989.
5. **Trumble, T.E., Culp, R.W., Hanel, D.P., Geissler, W.B., Berger, R.A.:** Intra-articular fractures of the distal aspect of the radius. *Instr Course Lect* 48:465-80. Review. 1999.
6. **Lansinger, O., Bergman, B., Korner, L., and Anderson, G.B.J.:** Tibial condylar fractures—A twenty year follow-up. *J Bone Joint Surgery* 68A:13-9, 1986.
7. **Waddell, J.P., Johnston, D.W.C., and Neidre, A.:** Fractures of the tibial plateau: A review of ninety-five patients and comparison of treatment methods. *J Orthop Trauma* 21:376-81, 1981.
8. **McCallister, W.V., Smith, J.M., Knight, J., Trumble, T.E.:** A cadaver model to evaluate the accuracy and reproducibility of plain radiograph step and gap measurements for intra-articular fracture of the distal radius. *J Hand Surg* 29(5):841-7, 2004.
9. **Anderson, D.D., Bell, A.L., Gaffney, M.B., Imbriglia, J.E.:** Contact stress distributions in malreduced intra-articular distal radius fractures. *J Orthop Trauma* 10(5):331-7, 1996.
10. **Baratz, M.E. DesJardins, J.D., Daniel, T.E., Anderson, D.D., and Imbriglia, J.E.:** Displaced Intra-articular Fractures of the Distal Radius: The Effects of Fracture Displacement on Contact Stresses in a Cadaver Model. *J Hand Surg* 21A:183-8, 1996.

11. **DesJardins, J.D., Daniel, T.E., Anderson, D.D., Baratz, M.E., and Imbriglia, J.E.:** Changes in Carpal Kinematics with Displaced Intra-articular Fractures of the Distal Radius. *Advances in Bioengineering* 28:357-8, 1994.
12. **Viegas, S.F., Tencer, A.F., Cantrell, J., Chang, M., Clegg, P., Hicks, C., O'Meara, C., and Williamson, J.B.:** Load transfer characteristics of the wrist. Part I. The normal joint. *J Hand Surg* 12A(6):971-8, 1987.
13. **Wagner, Jr, W.F., Tencer, A.F., Kiser, P., and Trumble, T.E.:** Effects of intra-articular distal radius depression on wrist joint contact characteristics. *J Hand Surg* 21A(4):554-60, 1996.
14. **Thompson, Jr., R.C., Oegema, Jr., T.R., Lewis, J.L., and Wallace, L.:** Osteoarthrotic changes after acute transarticular load: An animal model. *J Bone Joint Surg* 73A(7):990-1001, 1991.
15. **Horii, E., Garcia-Elias, M., An, K.N., Bishop, A.T., Cooney, W.P., Linscheid, R.L., and Chao, E.Y.S.:** Effect on force transmission across the carpus in procedures used to treat Kienböck's disease. *J Hand Surg* 15A(3):393-400, 1990.
16. **Anderson, D.D. and Daniel, T.E.:** A Contact-Coupled Finite Element Analysis of the Radiocarpal Joint. *Seminars in Arthroplasty* 6(1):30-6, 1995.
17. **Ulrich, D., van Rietbergen, B., Laib, A., and Rüegsegger, P.:** Load transfer analysis of the distal radius from in-vivo high-resolution CT-imaging. *J Biomechanics* 32:821-8, 1999.
18. **Carrigan, S.D., Whiteside, R.A., Pichora, D.R., and Small, C.F.:** Development of a Three-Dimensional Finite Element Model for Carpal Load Transmission in a Static Neutral Posture. *Annals of Biomedical Engineering* 31:718-25, 2003.
19. **An, K.-N., Jacobsen, M.C., Berglund, L.J., and Chao, E.Y.S.:** Application of a magnetic tracking device to kinesiologic studies. *J Biomechanics* 21(7):613-20, 1988.
20. **Short, W.H., Palmer, A.K., Werner, F.W., and Murphy, D.J.:** A biomechanical study of distal radius fractures. *J Hand Surg* 12A:529-34, 1987.
21. **Ateshian, G.A., Lai, W.M., Zhu, W.B., and Mow, V.C.:** An asymptotic solution for two contacting biphasic cartilage layers. *J Biomechanics* 27(11):1347-60, 1994.
22. **Donzelli, P.:** A mixed penalty contact finite element formulation for biphasic soft tissues. Ph.D. Thesis, Renssalear Polytechnic Institute, Troy, NY, 1995.
23. **Spilker, R.L. and Maxian, T.A.:** A mixed-penalty finite element formulation of the linear biphasic theory for soft tissues. *Int J Numer Methods Eng* 30: 1063-82, 1993.
24. **Wu, J.Z., Herzog, W., and Epstein, M.:** Articular joint mechanics with biphasic cartilage layers under dynamic loading. *J Biomech Eng* 120(1):77-84, 1998.

QUANTIFICATION OF THE MICROSTRUCTURAL ANISOTROPY OF DISTRACTION OSTEOGENESIS IN THE RABBIT TIBIA

Kevin B. Jones, M.D.,[1] Nozomu Inoue,[3] John E. Tis,[4] Edward F. McCarthy,[2] Kathleen A. McHale,[4] Edmund Y.S. Chao[3]

ABSTRACT

A longitudinal orientation of fibers and trabeculae has been observed histologically within distracted callus. This study quantified the intensity and angle of orientation of trabeculae within a distracted callus. Sixteen New Zealand white rabbits underwent unilateral tibial callus distraction with an external fixator across a mid-diaphyseal osteotomy. Included were: a seven-day post-operative latency period, ten days of distraction at 0.5 mm every 12 hours, and 20 days of post-distraction consolidation before euthanasia. Tibiae were removed, stripped of soft tissue, sectioned, and processed for decalcified histology. Micrographs of mid-coronal sections of the callus were evenly divided into 12 regions and underwent Fast Fourier Transform (FFT) analysis of the digitized image to determine the angle and intensity of the orientation of the bony trabeculae within the callus. The microstructure of the regenerate callus demonstrated an angle of orientation that uniformly matched that of cortical bone in all of regions of the callus and an intensity of orientation which approached that of cortical bone.

[1]Department of Orthopaedics and Rehabilitation
University of Iowa
Iowa City, IA

[2]Department of Pathology
The Johns Hopkins University School of Medicine
Baltimore, Maryland

[3]Department of Orthopaedic Surgery
The Johns Hopkins University School of Medicine
Baltimore, Maryland

[4]Department of Orthopaedic Surgery and Rehabilitation
Walter Reed Army Medical Center
Washington, D.C.

Correspondence:
Nozomu Inoue, M.D., Ph.D.
Director of Orthopedic Biomechanics Laboratory
Department of Orthopedic Surgery
Rush University Medical Center
1653 West Congress Parkway,
1471 Jelke
Chicago, IL 60612-3833
Phone: 312-942-8151
FAX: 312-942-2040
e-mail: nozomu_inoue@rush.edu

INTRODUCTION

The unique mechanical environment of external fixation and periodic tension-stress exerts profound effects on the bony regeneration in distraction osteogenesis. Controversy has surrounded attempts to fit histological descriptions of the distracted callus into various defined modes of ossification.

The majority of studies in various animal models has found intramembranous ossification to be the predominant, if not exclusive, mode of ossification,[1-4] but some investigators also interpret the presence of cartilaginous islands or nodules as evidence of some concurrent endochondral ossification.[5-9] Most studies have agreed on the description of an early callus organization consisting of a fibrous radiolucent zone in the gap center, and two sclerotic zones of trabecular bone extending toward it from each of the distracted osteotomy surfaces. Post-distraction, as the callus consolidates, the sclerotic zones fuse to form a callus with trabecular bone distributed throughout.

In contrast, the callus of fracture healing has a very different organization. Fracture callus ossifies primarily on randomly dispersed fibers and throughout an expanded periosteal region before it then organizes the trabecular callus with remodeling. Markel et al. showed in 1991 that orientation of bony trabeculae changes through the maturation of fracture callus, having profound impact on the mechanical stability of the callus at various stages of healing.[10]

Especially given the trabecular character of the distracted callus early in consolidation, orientation has implications on callus strength. Recent studies assessing the strength of physiologically trabecular bone have indicated that trabecular orientation contributes significantly to its strength.[11-13]

With these potential implications on the strength of the distracted callus in mind, the longitudinal orientation of bony trabeculae after distraction needs to be quantified. The purpose of this study is to quantify not only the angle and intensity of the orientation of trabeculae within the consolidating distracted callus, but to quantify the uniformity and distribution of this anisotropy.

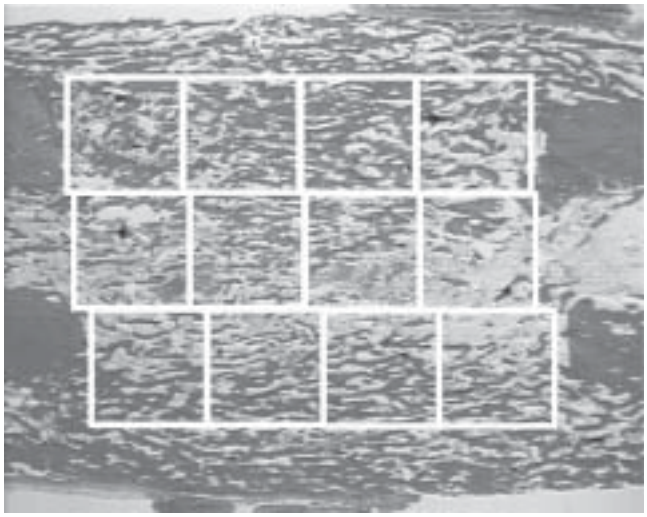

Figure 1. Photomicrograph of a mid-coronal section through the distracted callus of a rabbit tibia, and twelve areas for trabecular orientation analysis.

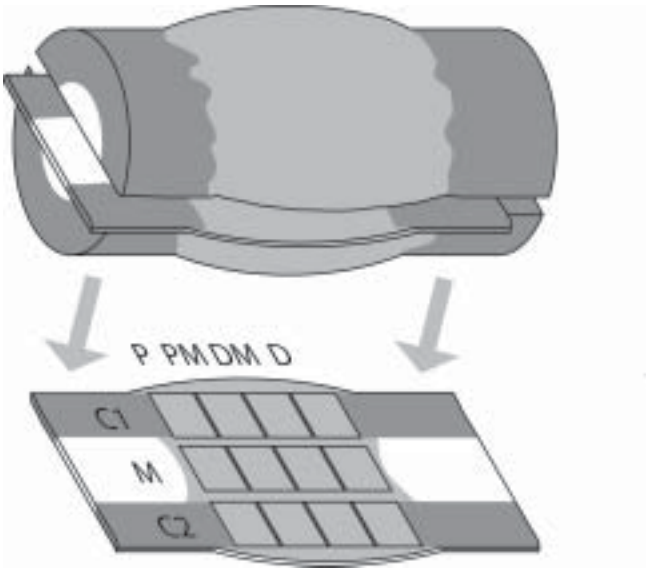

Figure 2. A 6μm mid-coronal plane section is taken from the distracted callus to be histologically prepared. The digitized photomicrograph of the section is then divided into twelve areas described by their coordinates in either cortical (C1 and C2) or medullary (M) longitudinal zones, and in the proximal (P), proximal middle (PM), distal middle (DM) or distal (D) transverse zones.

METHODS

Sixteen skeletally mature (3.5 to 5.0 kg) New Zealand white rabbits underwent unilateral tibial callus distraction with an external fixator across a mid-diaphyseal osteotomy. A mid-diaphyseal osteotomy for lengthening was performed after an external fixation device was applied. Full weight bearing and unrestricted motion were allowed immediately after surgery. All procedures were approved by and performed in accordance with the Institutional Animal Care and Use Committee.

Surgical Technique

Sterile surgical technique under controlled conditions was used to apply a unilateral external fixator (M-103, Orthofix, Verona, Italy) to alternating tibiae on 16 rabbits. Two 1.5-2.0 mm self-tapping, tapered half-pins were placed in pre-drilled 2 mm holes proximally and distally to attach the fixator parallel to the longitudinal axis of the tibial shaft and on the anteromedial aspect (with screws directed posterolaterally). Under saline irrigation for cooling, a transverse osteotomy was performed 1 to 2 mm distal to the tibio-fibular junction (between the two pairs of half-pins) using a Stryker reciprocating saw (Model 1370, Stryker Corporation, Kalamazoo, MI, USA).

Callus Distraction and Consolidation

After a seven-day post-operative latency period, distraction across the osteotomy site was begun at a rate of 0.5 mm every 12 hours. Distraction at this rate was continued for ten days to achieve a 10 mm lengthening of each tibia. After a consolidation period of 20 days post-distraction, rabbits were euthanized, tibiae were harvested and the fixators were removed. After stripping the bulk of soft tissues, specimens were wrapped in saline-soaked gauze sponges and stored at -20 degrees Celsius.

Histological Preparation

After decalcification and fixation, specimens were embedded in paraffin and a longitudinal section of 6μm was taken from the bone center in the coronal plane (Figure 2). These sections were fixed to slides and stained with toluidine blue, aldehyde fuchsin, and hematoxylin and eosin.

Micrograph Digitization

Images of the callus, including the periosteal callus, oriented such that the longitudinal axis of the bone aligned with the horizontal edge of the image field, were digitized using a color Charged Coupled Device (CCD) camera (Model DXC-151, Sony, Japan) interfaced to a microcomputer. Digitized image data were transferred to a Silicon Graphics workstation (Indigo, Elan, Cupertino, CA).



Figure 3. Once a field is selected from the digitized photomicrograph, the program gray- rescales the area (left), generates a Fast Fourier Transform power spectrum (middle), and finally produces an intensity histogram to graphically represent the distribution of oriented angles within the area (right).

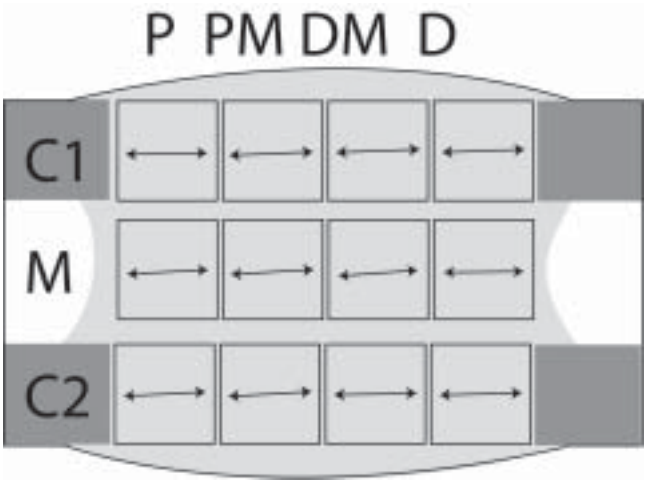

Figure 4. The averaged angle of orientation of the trabeculae within the 12 areas in the distracted callus, described by their coordinates in either cortical (C1 and C2) or medullary (M) longitudinal zones, and in the proximal (P), proximal middle (PM), distal middle (DM) or distal (D) transverse zones.

Quantitative Analysis of Trabecular Orientation

For each digitized specimen image, the callus was divided into twelve approximately 2.5 mm by 2.5 mm areas determined by placement in one of the two neocortical zones or in the neomedullary canal zone transversely, and in the proximal, proximal-middle, distal-middle or distal zone longitudinally (Figure 2). A two-dimensional Fast Fourier Transform of a 256 x 256 pixel field which corresponded to each of the twelve areas on the histological specimen was calculated using custom software on the Silicon Graphics workstation according to the method previously described[14]. Briefly, the software first rescaled the gray levels of the selected field, then detected the directionality by transforming the power spectrum to a polar system using linear interpolation. The intensity of the orientation was then quantified by calculating the power spectrum within fan-shaped segments corresponding to one degree of orientation increment (Figure 3). The intensity of each orientation was represented as an index: 0 indicating a random orientation, and 1.0 indicating a completely parallel orientation. Periosteal callus areas were also measured when present.

TABLE 2
The mean and standard deviation of the intensity of orientation in the twelve areas within the callus

	Proximal Proximal	Proximal Middle	Distal Middle	Distal Distal
Cortex 1	0.80 ± 0.05	0.82 ± 0.04	0.82 ± 0.05	0.81 ± 0.04
Medullary	0.79 ± 0.08	0.81 ± 0.06	0.77 ± 0.04	0.78 ± 0.07
Cortex 2	0.80 ± 0.06	0.81 ± 0.03	0.81 ± 0.03	0.80 ± 0.04

Data Analysis

The angle and intensity of orientation in the twelve averaged FFT areas from each specimen were compared by one-way analysis of variance. They were also compared with those in normal rabbit tibial cortical bone similarly prepared and measured by Student's t-test.

RESULTS

Wherever bony trabeculae were present within the specimen sections, they were highly oriented along the longitudinal axis. All twelve averaged areas had a similar angle and intensity of orientation (Figure 1). The overall average for the angle of orientation was 0.3 ± 4.0 degrees with a mean intensity of 0.80 ± 0.05 (Figure 4, and Tables 1 and 2). While the angle of orientation in the extracortical callus was not significantly different from the angle of orientation in the twelve averaged areas (2.3 ± 4.3 degrees), the intensity of the orientation in extracortical callus regions, while still very high, was significantly lower than the mean intensity of orientation for the twelve areas (0.75 ± 0.07, $p < 0.0001$). The averaged areas that had the lowest p-value in t-test comparison with normal rabbit tibial cortical bone (i.e., were oriented at angles most different from the longitudinal orientation of normal rabbit tibial cortical bone) were the two fields in the callus middle and in the medullary canal. One of these two areas also demonstrated the lowest intensity of orientation, significantly different from the average within the callus, excluding this region (0.77 ± 0.04, $p = 0.037$)

DISCUSSION

In this study, the angle and intensity of trabecular orientation within the distracted rabbit tibial callus was evaluated in a quantitative manner. The longitudinally well-oriented trabecular structure of distraction osteo-

TABLE 1
The mean and standard deviation of the angle of orientation in the twelve areas within the callus along with the p-value from a Student's t-test comparison to the mean of a sampling of normal tibial cortical bone, similarly prepared and evaluated

	Proximal		Proximal Middle		Distal Middle		Distal	
	Angle (deg)	p-value	Angle (deg)	p-value	Angle (deg)	p-value	Angle (deg)	p-value
Cortex 1	-0.9±4.3	0.480	0.6±2.8	0.684	0.3±3.1	0.927	0.1±4.6	0.952
Medullary	1.2±4.1	0.529	1.5±2.5	0.155	2.4±4.8	0.279	-0.1±4.3	0.433
Cortex 2	1.1±4.8	0.599	1.5±3.6	0.878	-0.7±3.8	0.364	-0.3±3.9	0.733

genesis in this rabbit model matched, after 20 days of post-distraction consolidation, the direction of cortical bone microstructural orientation. The trabecular structure also approached the orientational intensity of cortical bone. This anisotropy was uniform throughout the callus.

This quantification corroborates the histological observation that the fibers of the fibrous central zone, and the bony trabeculae of the sclerotic zones of the distracting callus are longitudinally aligned along the direction of distraction.[2,3,5-8] The tension across the callus during distraction aligns cells, as well as the fibrous extra-cellular matrix. Yasui et al. described the longitudinal arrangement of osteogenic cells, longitudinal columns of chondrocytes and mixed columns of osteogenic and chondrogenic cells also aligned along the tension vector.[15]

The tension-alignment of microstructures in distraction osteogenesis may have significance beyond the achieved mechanical alignment of the extracellular matrix. Mizumoto et al. reported that the expression of bone morphogenic protein-7 and many cytoskeletal proteins was upregulated in the callus during the period of active distraction.[16] They hypothesize that gene expression is regulated by the cytoskeletal response to alignment tension. If true, this hypothesis could explain in part the distraction pattern of ossification that has been distinguished from the mainly endochondral ossification of the fracture callus.[1-9,15]

The data reported in this study quantifies a callus that sharply contrasts the microstructural anisotropy of a fracture callus. Markel et al. quantified the anisotropy in 1991 in a fracture callus model, finding that while the intensity of orientation increased with remodeling over time, even after 12 weeks of healing, the intensity of orientation in the trabeculae of the callus was less than one-third that of cortical bone.[17]

In 1990, Markel et al. elucidated an implication of this alignment with the observation that once the fracture gap callus has remodeled to the point of longitudinally oriented trabeculae, the mechanical properties of the callus have tighter correlations to non-invasive quantifications of gap tissue density, such as quantitated computed tomography, single photon absorptiometry and dual-energy x-ray absorptiometry (DEXA).[10] The specific correlation they found between DEXA and torsional strength after this remodeling to longitudinal microstructure had an r^2 value of 0.51. For comparison, in 1998 Reichel et al. reported for distraction osteogenesis in a sheep model, a correlation between DEXA and torsional strength with an r^2 value of 0.60.[18] The strength-predicting value of non-invasive densitometry such as DEXA depends on a tissue's approximation of the modality's assumption of material uniformity. While a distracted callus does not perfectly fulfill the assumption of material uniformity, the strong intensity of its orientation more closely approximates such, explaining the strong correlation between DEXA and torsional strength that Reichel et al. observed.[18]

It has been reported that highly oriented trabecular structure is beneficial to resist axial loading (on-axis loading), but vulnerable to the off-axis loading or shear loading.[19] Similarly, an increase in anisotropy associated with osteoporosis has been considered a risk factor for pathologic fracture.[20] With these findings, the distracted callus with highly oriented trabecular structure may be strong only for axial loading. Standard material testing in orthogonal directions will be required to elucidate the mechanical anisotropy of the distracted callus.

There are attempts to enhance callus maturation after distraction in applying controlled compression.[21] It might be important to measure the changes in trabecular anisotropy in addition to the changes in bone density to evaluate the effects of such modality. Further investigation is necessary to extend the microstructural resolution of the distracted callus into three dimensions. The orientation of fibrous and neovascular structures early in distraction also deserves further pursuit.

REFERENCES

1. **Aronson J, Harrison B, Boyd CM, Cannon DJ, Lubansky HJ, Stewart C.** Mechanical induction of osteogenesis. Preliminary studies. *Ann Clin Lab Sci* 1998; 18:195-203.
2. **Aronson J, Good B, Stewart C, Harrison B, Harp J.** Preliminary studies of mineralization during distraction osteogenesis. *Clin Orthop* 1990; 250:43-9.
3. **Carls FR, Schüpbach P, Sailer HF, Jackson IT.** Distraction osteogenesis for lengthening of the hard palate: Part II. Histological study of the hard and soft palate after distraction. *Plast Reconstr Surg* 1997; 100:1648-54.
4. **Tajana GF, Morandi M, Zembo MM.** The structure and development of osteogenetic repair tissue according to Ilizarov Technique in man. Characterization of extracellular matrix. *Orthopedics* 1989; 12:515-23.
5. **Delloye C, Delefortrie G, Coutelier L, Vincent A.** Bone regenerate formatin in cortical bone during distraction lengthening. An experimental study. *Clin Orthop* 1990; 250:34-42.
6. **Hamdy RC, Silvestri A, Rivard CH, Ehrlich M.** [Histologic evaluation of bone regeneration in cases of limb lengthening by Ilizarov's technique. An experimental study in the dog.] *Ann Chir* 1997; 51:875-83.
7. **Jazrawi LM, Majeska RJ, Klein ML, Kagel E, Stromberg L, Einhorn TA.** Bone and cartilage formation in an experimental model of distraction osteogenesis. *J Orthop Trauma* 1998; 12:111-6.
8. **Kojimoto H, Yasui N, Goto T, Matsuda S, Shimomura Y.** Bone lengthening in rabbits by callus distraction. The role of periosteum and endosteum. *J Bone Joint Surg* [Br] 1998; 70:543-9.
9. **Komuro Y, Takato T, Harii K, Yonemara Y.** The histologic analysis of distraction osteogenesis of the mandible in rabbits. *Plast Reconstr Surg* 1994; 94:152-9.
10. **Markel MD, Wikenheiser MA, Chao EYS.** Formation of Bone in Tibial Defects in a Canine Model. Histomorphometric and Biomechanical Studies. *J Bone Joint Surg* [Am] 1991; 73:914-23.
11. **Ciarelli MJ, Goldstein SA, Kuhn JL, Cody DD, Brown MB.** Evaluation of orthogonal mechanical properties and density of human trabecular bone from the major metaphyseal regions with materials testing and computed tomography. *J Orthop Res* 1991; 9:674-82.
12. **Goldstein SA, Goulet R, McCubbrey D.** Measurement and significance of three-dimensional architecture to the mechanical integrity of trabecular bone. *Calcif Tis Int* 1993; 53:S127-32.
13. **Oden ZM, Selvitelli DM, Hayes WC, Myers ER.** The effect of trabecular structure on DXA-based predictions of bovine bone failure. *Calcif Tis Int* 1998; 63:67-73.
14. **Chao EY, Inoue N, Elias JJ, Frassica FJ.** Image-based computational biomechanics of the musculoskeletal system. In Bankman (ed): *Handbook of Medical Imaging, Processing and Analysis*. San Diego, Academic, 2000, pp 285-298.
15. **Yasui N, Sato M, Ochi T, Kimura T, Kawahata H, Kitamura Y, Nomura S.** Three modes of ossification during distraction osteogenesis in the rat. *J Bone Joint Surg* [Br] 1997; 79:824-30.
16. **Mizumoto Y, Moseley T, Reddi AH.** Expression and localization of bone morphogenetic protein 7 and cytoskeletal proteins during distraction osteogenesis. *Abstracts from the International Conference for Bone Morphogenetic Proteins* 2000:142.
17. **Markel MD, Wikenheiser MA, Morin RL, Lewallen DG, Chao EYS.** Quantification of bone healing: Comparison of QCT, SPA, MRI, and DEXA in dog osteotomies. *Acta Orthop Scand* 1990; 61:487-98.
18. **Reichel H, Lebek S, Alter C, Hein W.** Biomechanical and Densitometric Bone Properties After Callus Distraction in Sheep. *Clin Orthop* 1998; 357:237-46.
19. **Inoue N, Sakakida K, Yamashita F, Hirai T, Katayama T.** The elastic modulus of cancellous bone: Dependence on trabecular orientation. In Bergman G, Kolbel A, Rohlman (eds): *Biomechanics: Basic and Applied Research*, Dordrecht, Martinus Nijihoff Publishers, 1987, pp 207-12.
20. **Sugita H, Oka M, Toguchida J, Nakamura T, Ueo T, Hayami T.** Anisotropy of osteoporotic cancellous bone. *Bone* 1999; 24:513-6.
21. **Claes L, Jaule J, Wenger K, Suger G, Liener U, Kinzl L.** The influence of stiffness of the fixator on maturation of callus after segmental transport. *J Bone Joint Surg* [Br] 2000; 82:142-8.

IN VIVO LONGITUDINAL ASSESSMENT OF BONE RESORPTION IN A FIBULAR OSTEOTOMY MODEL USING MICRO-COMPUTED TOMOGRAPHY

Kim A. Powell,[1,2,3] Larry Latson,[1,3] Michael O. Ibiwoye,[3] Alan Wolfman,[4] Mark D. Grabiner,[4] Maciej Zborowski,[3] Yoshitada Sakai,[3] Ronald J. Midura[2,3]

ABSTRACT

Longitudinal *in vivo* micro-computerized tomography (CT) imaging was used to monitor bone resorption in a rat fibula osteotomy model. Quantitative image post-processing techniques were developed for spatially aligning the longitudinal data sets. Nominal length and bone volume in the proximal and distal segments of the fibula after the osteotomy were measured, and quantitative comparisons of bone loss over a 13-week period post-surgery were made in five individual rats. A significant decrease in nominal length and bone volume of the distal segment was observed 13 weeks post surgery. A significant decrease in bone volume was also observed in the proximal segment. However, no change in nominal length was observed for the proximal segment of the fibula. This study illustrates the power of this non-invasive technology to measure *in vivo* small changes in bone length and volume using just a small cohort of animals.

[1]The Whitaker Biomedical Imaging Laboratory

[2]Orthopaedic Research Center

[3]Department of Biomedical Engineering

[4]Department of Cell Biology
The Lerner Research Institute
The Cleveland Clinic Foundation
Cleveland, Ohio and the
Department of Movement Sciences
University of Illinois at Chicago

Correspondence:
Kim Powell, Ph.D.
Department Biomedical Engineering ND20
The Lerner Research Institute,
The Cleveland Clinic Foundation
9500 Euclid Avenue
Cleveland, Ohio 44195
Phone: (216) 445-9364
Fax: (216) 444-9198
E-mail: powell@bme.ri.ccf.org

INTRODUCTION

Micro-computed tomography (micro-CT) is a non-invasive imaging technology that has been used widely to monitor various treatment effects in small animals over time. For example, it has been used to study *in vivo* changes in trabecular architecture of the tibia in ovariectomized rats[1] and the effects of hormone replacement therapy in estrogen-depleted rats.[2] Although previous studies were typically performed using a synchrotron light source, more recent longitudinal *in vivo* studies have utilized commercially available micro-CT imaging systems.[3] Some of the advantages of this system are that it provides high-resolution (50-100 μm) three-dimensional images of the structures under investigation and the image acquisition is faster (less than 15 minutes per sample) as compared to other non-invasive high-resolution imaging techniques.

In the present study, we investigated the dynamic changes in bone tissue volume using a critical-sized osteotomy of the rat fibula. We chose a critical-sized osteotomy, since this experimental bone trauma often exhibits detectable changes in bone structure over time. The goal of this study was to accurately monitor changes in bone area and volume over time post-osteotomy, and to develop a methodology that could be potentially useful in the development and validation of treatment plans for bone-related pathological conditions.

METHODS

Study Sample

All animal procedures used in this study were reviewed and approved by the Institutional Animal Care and Use Committee. The protocol involved the use of five adult (11 months old) male Sprague-Dawley rats (Harlan Sprague-Dawley, Inc., Indianapolis, Indiana) weighing 500-600 g. Bilateral fibula osteotomies were performed on the animals' hind limbs using a modification of the procedure first described by Petersson and Johnell.[4] Each rat was anesthetized with an intraperitoneal (IP) injection of Nembutal (Abbot Laboratories, Abbot Park, Illinois; 60 mg/kg body weight (BW). They were also given an IP injection of cefazolin (Abbot Laboratories, Abbot Park, Illinois; 30 mg/kg BW) as an antibiotic prophylaxis. A fine-toothed clipper was used to



Figure 1. Photograph of the rat mounted on the X-Y-Z rotating platform stage with hind limbs secured and raised into the X-ray source beam. The X-ray source is on the left side of the photograph and the detector and CCD camera are located on the right side of the photograph. The inset figure represents a magnified view looking toward the X-ray source and illustrates the complete shielding of the rodent's body from the X-ray source.

circumferentially shave the entire hind limb from the knee to the ankle and the shaved region was disinfected with Betadine solution.

The rats were draped and under sterile conditions, a lateral incision was made that extended vertically from immediately below the knee joint to a point just above the ankle joint. The deep fascia was incised and the lateral intermuscular septum was divided by blunt dissection to separate the anterior and posterior compartment muscles, and to gain access to the lateral surface of the fibula and the attachments for the musculus peronei longus and brevis. With the anterior and posterior muscle groups fully retracted, a six-millimeter portion of the exposed fibula was excised by proximal and distal cuts using a high-speed rotary saw-tooth blade (Fine Science Tools, Foster City, CA). To prevent heat-induced necrosis at the osteotomy site, the rotating blade was pre-cooled to four degrees Celsius by constant irrigation with sterile physiological saline containing antibiotics. After completion of the fibula osteotomies, the gastrocnemius lateralis and medialis muscles were rejoined by a 3-0 absorbable suture (Ethicon, Inc, U.S.A.). The skin incision was closed using a pair of Michele clips and bacitracin ointment was applied to the closed wound. The rats were allowed unrestricted cage activities after surgery and were examined daily for evidence of infection, malnutrition or pain. None of these signs was detected in any of the animals.

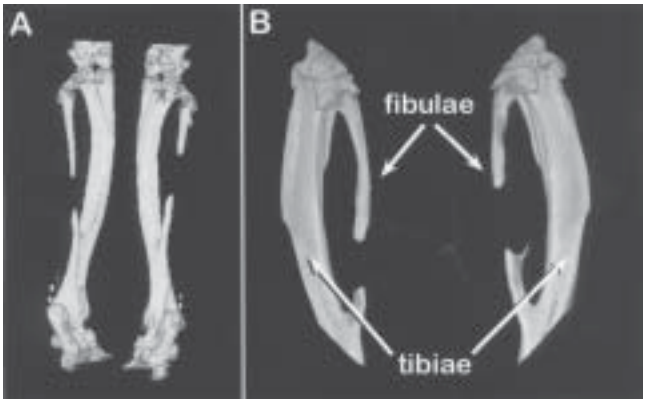

Figure 2. Three-dimensional reconstructions of hind limbs from animal number three. A) Posterior view of the hind limbs showing the fibula osteotomies. B) Enlarged views of the left (on left side), and right legs (on right).

Micro-CT Data Acquisition and Three-Dimensional Reconstruction

The animals' osteotomized hind limbs were imaged using X-ray micro-computed tomography three, five, ten and 13 weeks following surgery. For each imaging session, the animals were anesthetized for approximately 60 minutes by IP injection of Nembutal (Abbot Laboratories, Abbot Park, Illinois; 60 mg/kg BW). While under anesthesia, the animals were secured in a supine position onto the rotating platform of the micro-CT imaging system,[5] and their hind limbs were rigidly supported in the X-ray beam (Figure 1). The animal's torso, head and hind quarters were shielded with a 2-mm thick lead covering to limit the amount of X-ray exposure to other parts of the body. The images were collected at 34 kV, 450 A and one-second exposure time. A lead shuttering system was used to shield the animal from unnecessary exposure to X-ray beam during stage rotation. Isotropic (voxel size = 0.1 x 0.1 x 0.1 mm) three-dimensional volumes were reconstructed (512^3) of the hind limbs (Figure 2).[6]

Three-Dimensional Spatial Registration

To accurately assess bone resorption longitudinally at the osteotomy site, the data collected at different timepoints was spatially registered to a reference data set (micro-CT data from three weeks post surgery). Because the two fibular segments were unconstrained and free to move relative to one another after the osteotomy, spatial registration of the proximal and distal ends of the fibula was performed separately. The three-dimensional reconstructed images of the hind limbs were manually cropped into a sub-image of the left and right hind limbs (Figure 2B). The left and right hind limbs

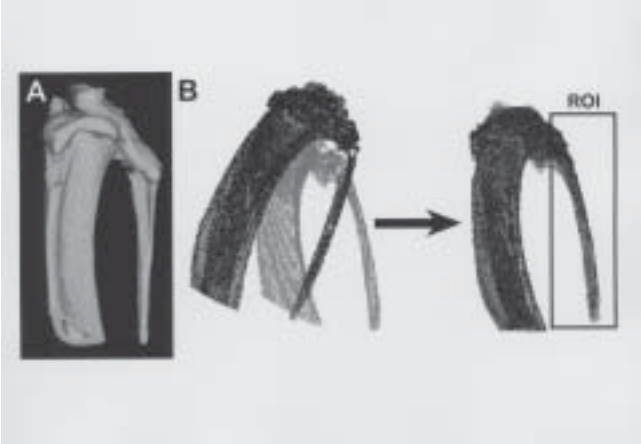

Figure 3. A) Three-dimensional reconstruction of left proximal tibia and fibula from animal number three taken three weeks post surgery. B) Outer outlines of segmented left proximal tibia and fibula from three weeks (grey) and 13 weeks (black) post surgery. These data sets are shown before and after spatial registration to one another.

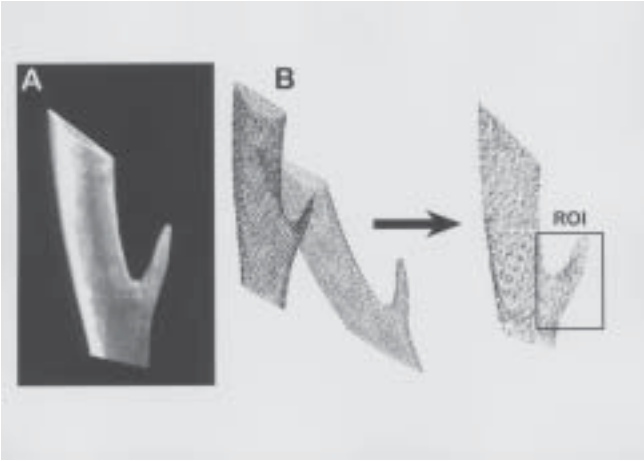

Figure 4. A) Three-dimensional reconstruction of left distal tibia and fibula from animal number three taken three weeks post surgery. B) Outer outlines of segmented left distal tibia and fibula from three weeks (grey) and 13 weeks (black) post-surgery. These data sets are shown before and after spatial registration to one another.

were further manually cropped into images of the proximal (Figure 3A) and distal (Figure 4A) ends of the fibula. The bone in these sub-images was segmented from its surrounding background using a global threshold. The outer boundary of the segmented bone was automatically identified and these boundary points were used for the spatial registration. For the proximal segment of the fibula, a ROI that extended from the joint between the fibular head and the upper end of the tibia, to the osteotomy site was used for the spatial registration (Figure 3B). For the distal segment, a region of interest (ROI) that included the distal third of the fibula and the region of the bony fusion between the distal ends of the tibia and fibula was used for spatial registration (Figure 4B). An iterative closest point (ICP) method was used for registering the outer boundaries of the segmented regions.[7] The ICP algorithm is a least-squares approach that minimizes the distances between two sets of data points. Single-value decomposition was used to calculate the transformation for minimizing the distances between the two sets of data points. The ICP algorithm is complete when the mean distance between the paired points does not change in successive iterations more than a fixed amount (that is, 0.5). Once the data transformation matrices from the registration were obtained, tri-linear interpolation was used for the rigid body transformations of five, 10 and 13 weeks post-surgery (Figures 3B and 4B).

Once the data were spatially registered to the reference data sets, the proximal and distal ends of the fibula were further segmented from the tibia by identifying an oblique clipping plane in a three-dimensional volume visualization program (Volsuite v2.2) and cropping the volumetric images along this clipping plane. The clipping plane for the proximal end was chosen at the start of the growth plate for the fibula. The clipping plane for the distal end was chosen at the fusion point of the fibula with the tibia. These cropped data sets were then spatially oriented relative to their principal axis and minor manual adjustments were made to the clipping planes based on review of the principally oriented datasets.

Quantitative Morphometrics

The lengths of the proximal and distal fibula segments were determined along the principal axis of each segment. The cross-sectional area as a function of nominal length was calculated by summing the segmented pixels in each cross-sectional slice orthogonal to the principal axis of the bone segment. The change in cross-sectional area along the bone segment was plotted for each imaging time-point and changes in area relative to the first time-point (three weeks post surgery) in the longitudinal imaging sequence were noted. Visual inspection of the spatially registered three-dimensional data sets was used to verify the changes in cross-sectional area and nominal length calculated using the quantitative analyses. The bone volume of the segment was calculated by integrating the cross-sectional areas along the length of the bone. Normalized bone volume was calculated relative to the volume calculated three weeks post surgery.

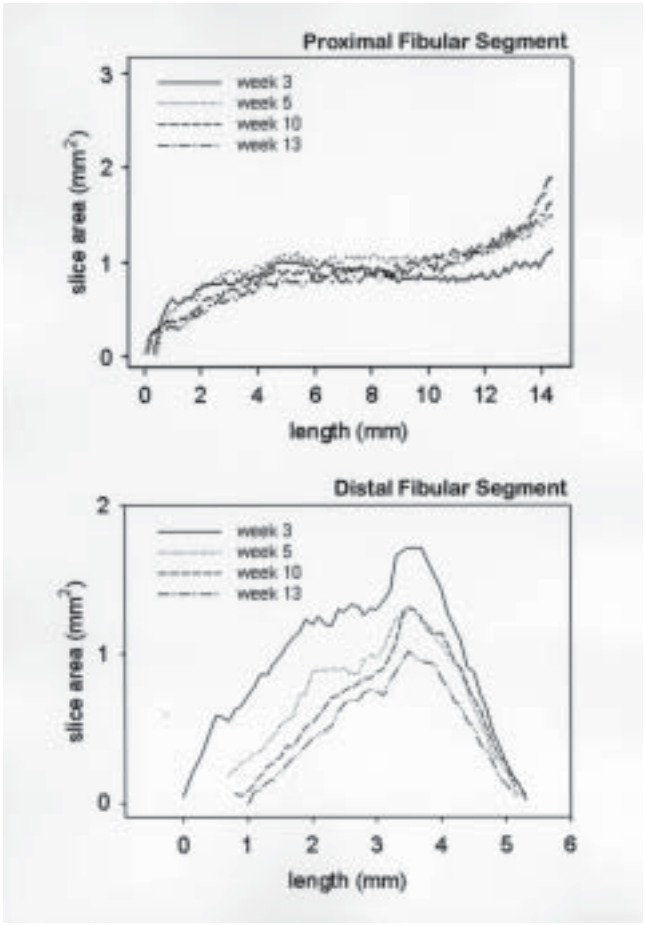

Figure 5. Plots of cross-sectional area versus length for three, five, ten and 13 weeks post surgery for animal number three. Staring point (nominal length=0) is located at the site of the osteotomy for both the proximal and distal end. The nominal length is oriented along the principal axis of each segment.

TABLE 1
Bone Length (mm)

Animal	Proximal End				Distal End			
	Weeks (post surgery)				Weeks (post surgery)			
	3	5	10	13	3	5	10	13
1	12.0	12.0	11.9	12.2	6.9	6.9	6.6	6.8
2	13.7	13.7	13.6	13.7	5.5	5.2	4.6	4.9
3	14.4	14.3	14.6	14.7	3.5	2.8	2.9	2.5
4	10.7	10.7	10.7	10.6	7.8	7.4	7.2	7.2
5	15.7	15.7	15.6	15.8	4.0	3.3	2.9	2.7

TABLE 2
Normalized Bone Volume

Animal	Proximal End				Distal End			
	Weeks (post surgery)				Weeks (post surgery)			
	3	5	10	13	3	5	10	13
1	1.0	0.79	0.79	0.81	1.0	0.85	0.69	0.84
2	1.0	0.79	0.88	0.88	1.0	1.14	0.80	0.85
3	1.0	1.14	1.06	0.98	1.0	0.60	0.47	0.37
4	1.0	0.97	0.82	0.83	1.0	0.94	0.84	0.87
5	1.0	0.83	0.78	0.76	1.0	0.78	0.58	0.55

Statistics

Paired t-tests ($\alpha = 0.05$) were performed to determine whether there was a significant difference in the nominal lengths or in bone volume of the proximal and distal bone segments five, 10 and 13 weeks post surgery relative to three weeks post surgery.

RESULTS

The spatially registered data sets for the proximal and distal ends of the fibula (animal number three) are presented in Figures 3 and 4, respectively. The ICP registration technique worked well for most cases; however, it was extremely sensitive to the ROI chosen for registration. Although care was taken to identify ROIs that were similar in both data sets (particularly in the distal ends of the fibula), there were cases where the ROI had to be adjusted multiple times to obtain the best registration possible. Additionally, the registration technique tended to perform better in the distal segment of the fibula than in the proximal segment. This was due to the beam-hardening artifacts (that is, high grey-level intensity streaks in the image) coming from the larger tibia near the proximal end of the fibula (Figure 3A). These artifacts resulted in a poor segmentation of the proximal fibula, and thus, inaccurate boundary points in this region.

The change in cross-sectional area as a function of nominal length and time are presented for the proximal and distal segments (animal number three) in Figure 5. In this example, we observed a slight decrease in bone volume along the entire length of the proximal segment without a change in the nominal length of the proximal segment. We observed a much larger decrease in bone volume in the distal segment than its corresponding proximal segment (63% versus 20% decreases, respectively), with a concurrent decrease in the distal segment nominal length.

The nominal lengths of the proximal and distal segments for all animals and time-points are listed in Table 1. No significant change in nominal length was observed in the proximal segment 13 weeks post surgery. The small differences (± 0.2 mm) in nominal length observed in this region could be attributed to errors in segmentation and registration of the longitudinal data sets. A significant decrease in nominal length was observed in the distal segment starting at five weeks post

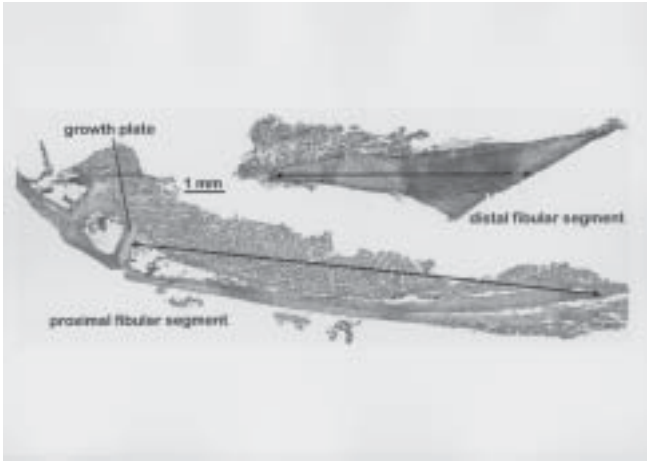

Figure 6. Digital images of hematoxylin- and eosin-stained tissue sections of proximal and distal segments of fibula from animal number one. These sections were cut longitudinally along the middiathesis of the fibula. The nominal lengths of these bone segments are shown as black lines with double arrows.

surgery. This decrease was particularly evident in those cases where the distal segment was less than six millimeters in length by three weeks post surgery. In these cases we observed as much as a 33% decrease in nominal length 13 weeks post surgery.

The normalized bone volume for the proximal and distal ends, over time, is listed in Table 2. We observed a 20-25% decrease in bone volume in the proximal end 13 weeks post surgery with the exception of animal number three, which showed very little change in bone volume. We also observed a 15% decrease in bone volume by 13 weeks post surgery in the distal end of the fibula, except in the cases where it was less than six millimeters in nominal length by three weeks post surgery. These cases exhibited as much as a 63% decrease in bone volume. For the study sample, there was a statistically significant difference in normalized bone volume for both the distal and proximal segments 13 weeks post surgery. However, the statistical power of this test was below 0.8 for the distal segment. This indicates that additional samples need to be obtained in order to verify this finding.

Independent validation of these micro-CT measurements was sought using conventional histological methods. Figure 6 shows decalcified tissue sections of both the proximal and distal fibular segments from animal number one. The nominal lengths of this animal's proximal and distal fibular segments were measured as 12.1 mm and 6.9 mm, respectively. These morphometric values are only ~2% different from the measurements of these same fibular segments made from the micro-CT images (Table 1). These histological images also revealed relatively normal-appearing cortical bone tissue in these fibular segments.

DISCUSSION

We present in this study an animal model for evaluating *in vivo* bone resorption longitudinally. Two aspects of this model illustrate its potential importance: first, as a means to study the process of bone loss under a situation of disrupted mechanical loading and second, to provide a potential *in vivo* model for evaluating the effectiveness of pharmacologic treatments to prevent or reverse bone loss. This bilateral osteotomy model is designed so each animal can serve as its own internal control for local treatment protocols (that is, left versus right side). Such a within-animal control yields a greater statistical power to observe changes due to treatment in experiments with a reduced number of animals, translating into a reduction in the expense and time for completion of an experiment, and an enhanced ability to identify small structural changes in an individual bone. Additionally, the results of this analysis appeared to correlate well with measurements made from two-dimensional histological sections.

In general, we observed that the proximal and distal bone segments decreased in cross-sectional area along the nominal length of the bone, while maintaining their overall length. This was true to the extent that the initial segments were longer than six millimeters in nominal length. The greatest amount of bone resorption was observed in the small distal segments of the fibula. This could be due to a decrease in mechanical stimulation at that site due to the disruption of normal weight-bearing load transmission over the length of the fibula caused by the osteotomy. Alternatively, this resorption of fibular bone mass may be affected by its connection to the tibia, as the distal part of the fibula fuses into the tibia. This connection of the two bones allows the sharing of common marrow tissue through the continuity of their medullary cavities, thereby permitting access of osteoclastic precursor cells from the tibia into the fibula.

Some of the problems we encountered during the *in vivo* imaging sessions included misalignment of the rotational stage, movement of the animal during an imaging session, and the beam-hardening artifacts observed in the region of the proximal fibula. The problem of a misalignment of the stage was addressed by using a method described by No et al.[8] for automatically identifying the center-axis of rotation and reorienting this axis relative to the x-ray source and detector prior to data collection. More secure methods of fixing an animal's hind limbs to a rigid object such as the rotating stage platform are being investigated to limit the effects of even small motion artifacts. Finally, techniques for correcting the beam-hardening artifacts are currently being evaluated and will be implemented in the future.[9,10]

As previously reported by our group,[5] each imaging session generated only a low dose of X-ray radiation to the lower hind limbs (0.64 Gy). Besides a low cumulative X-ray dosage, we observed that only some of the bone segments in some of the animals showed changes in bone length and volume. We believe that these findings are better explained by a disrupted mechanical loading pattern after a large osteotomy, rather than a cumulative X-ray irradiation effect.

ACKNOWLEDGMENTS

This study was supported by a grant from the Orthopaedic Research and Education Foundation (OREF) with funding provided by Orthofix Inc., and a grant from the Department of Defense.

REFERENCES

1. **Lane NE, Thompson JM, Haupt D, Kimmel DB, Modin G, Kinney JH.** Acute changes in trabecular bone connectivity and osteoclast activity in ovariectomized rat *in vivo*. *J Bone Miner Res* 1998; 13: 229-236.
2. **Lane NE, Haupt D, Kimmel DB, Modin G, Kinney JH.** Early estrogen replacement therapy reverses the rapid loss of trabecular bone volume and prevents further deterioration of connectivity in the rat. *J Bone Miner Res* 1999; 14:206-214.
3. **Waarsing JH, Day JS, van der Linden JC, Ederveen AG, Spanjers C, De Clerk N, Sasov A, Verhaar JAN, Weinans, H.** Detecting and tracking local changes in the tibia of individual rats: a novel method to analyze longitudinal in vivo micro-CT data. *Bone* 2004; 34: 163-169.
4. **Petersson J, Johnell O.** Electrical stimulation of osteogenesis in delayed union of the rabbit fibula. *Arch Orthop Trauma Surg* 1983; 101: 247-250.
5. **Latson L, Kuban B, Bryan J, Stredney D, Davros W, Midura RJ, Apte S, Powell KA.** X-ray microcomputed tomography system: Novel application in bone imaging. Engineering, Medicine and Biology Society International Meeting, October 2003.
6. **Grass M, Kohler TH, Proksa R.** 3D cone-beam CT reconstruction for circular trajectories. *Phys Med Biol* 2000; 45:329-347.
7. **Besl PJ, McKay ND.** A method for registration of 3-D shapes. IEEE Trans. *Pattern Analysis and Machine Intelligence* 1992; 14:239-256.
8. **Noo F, Clackdoyle R, Mennessier C, White TA, Roney TJ.** Analytical method based on identification of ellipse parameters for scanner calibration in cone-beam tomography. *Phys. Med. Biol.* 2000; 45:3489-3508.
9. **Yan CH, Whalen RT, Beaupré GS, Yen SY, Napel S.** Reconstruction algorithm for polychromatic CT imaging: Application to beam hardening correction. *IEEE Trans on Medical Imaging* 2000; 19:1-11.
10. **De Man B, Nuyts J, Dupont P, Marchal G, Suetens P.** An iterative maximum-likelihood polychromatic algorithm for CT. *IEEE Trans on Medical Imaging* 2001; 20:999-1008.

EFFECTS OF RECOMBINANT HEMATOPOIETINS ON BLOOD-LOSS ANEMIA IN MICE

Kevin B. Jones, M.D.,[1] David W. Anderson, Ph.D.,[2] Gregory D. Longmore, M.D., M.S.[3]

ABSTRACT

Use of recombinant human erythropoietin (rhEPO) for treatment of pre-operative anemia in anticipation of orthopaedic surgical blood loss has become a routine practice. Use of rhEPO to help manage unanticipated blood loss from elective surgery or major orthopaedic trauma is limited by the rate and volume of erythropoiesis that is achievable with exogenously administered rhEPO. The rate and volume of erythropoiesis may be limited by the available population of cells responsive to EPO. Cytokines known to affect these early hematopoietic progenitors may potentiate the effects of rhEPO. In this study, mice were rendered anemic by loss of approximately one-third of their total blood volume. A control group received only iron supplementation. Mice in three experimental groups received three injections of rhEPO. Two of these groups also received either recombinant murine stem cell factor (rmSCF) or recombinant murine interleukin-3 (rmIL-3). Both were before and in conjunction with rhEPO. Animals were sacrificed for peripheral blood testing at baseline, after initiation of rmSCF and rmIL-3 prior to rhEPO administration, and at three time points after dosing of rhEPO. Additionally, the bone marrow was harvested and cultured to determine the concentration of erythroid progenitors after treatment with rmIL-3 or rmSCF, and after further treatment with rhEPO. Hematocrits were significantly higher in the first measurement point after administration of rhEPO in the groups receiving additional cytokines. The control and rhEPO-only groups were not different at this early time point. The maximal rate of erythropoiesis was also elevated in the groups receiving additional cytokines. The bone marrow of mice receiving SCF had a dramatically increased number of erythroid progenitors compared to all other groups. The population of EPO-responsive cells, dependent on cytokines not controlled by hypoxia, is a major rate-limiting and volume-limiting factor in the response to rhEPO during recovery from blood-loss anemia. Administration of earlier-acting cytokines has the potential to increase the rate and volume of exogenously stimulated erythropoiesis.

INTRODUCTION

Allogenic blood transfusions, though much safer than they were at times in the past, are not risk-free. While transmission of human immunodeficiency virus (HIV) or the hepatitis C virus via transfusion occurs only once per one-and-one-half million units transfused in the United States, other viruses such as hepatitis B and emerging pathogens cannot be as thoroughly screened for.[1] In addition, transfusion reactions occur approximately once per fifty units transfused. Further, the immunomodulation resulting from blood transfusion has been suspected to increase post-operative infections and delay wound healing.[2-6] The desire to minimize or eliminate patient exposure to transfusion risks has harnessed improving understanding of hematologic physiology and pathophysiology to engineer means by which anemia may be otherwise treated.

Erythropoietin (EPO), the most potent regulator of red blood cell development, or erythropoiesis, is a glycoprotein hormone secreted primarily by cells in the interstitium of the renal cortex. Its expression and secretion are very tightly linked to tissue hypoxia. EPO exerts its influence in the bone marrow, where it regulates the proliferation and differentiation of red blood cell precursors.

Recombinant human EPO (rhEPO) has been available for exogenous administration since the mid-1980s.[7] By 1989, the U.S. Food and Drug Administration had

[1]Department of Orthopaedics and Rehabilitation
University of Iowa Hospitals and Clinics,
Iowa City, Iowa

[2]Department of Biological Sciences
Graceland University
Lamoni, Iowa

[3]Department of Hematology and Oncology
Washington University
St. Louis, Missouri

Correspondence:
Kevin B. Jones, M.D.
Department of Orthopaedics and Rehabilitation
University of Iowa Hospitals and Clinics
John Pappajohn Pavilion, 01051 Lower Level
200 Hawkins Drive
Iowa City, Iowa 52242
kevin-jones@uiowa.edu

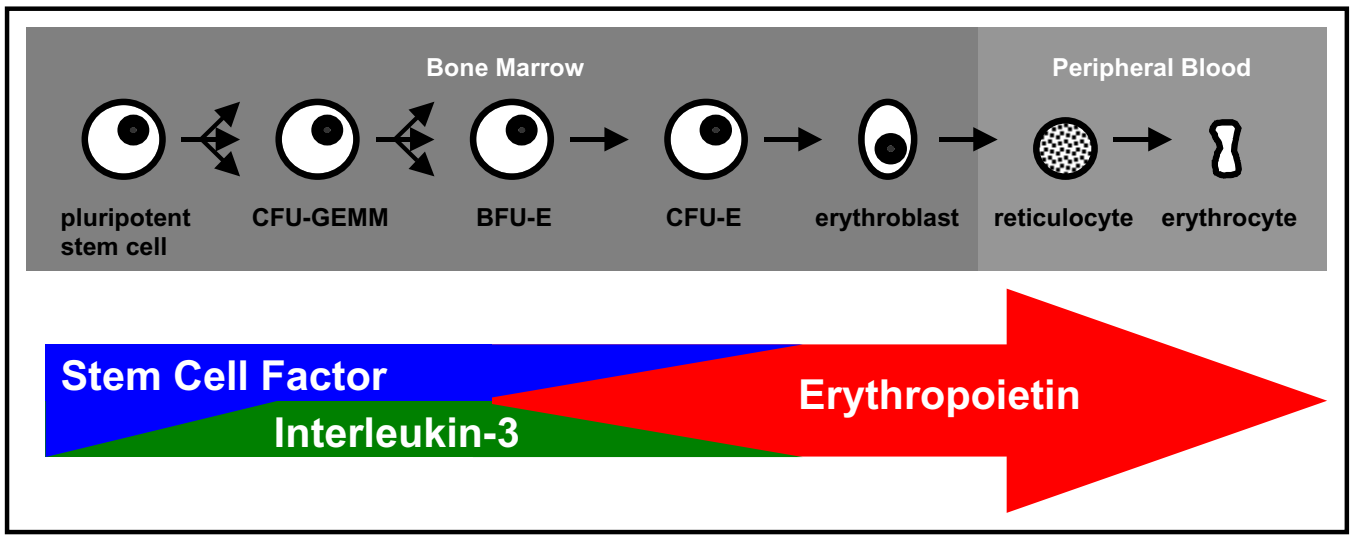

Figure 1. This schematic illustrates the effects of three hematopoietins on proliferation and differentiation in the myeloid lineage and its erythroid arm. The myeloid lineage initially includes cells with the ability to form colonies of precursors to granulocytes, erythrocytes, megakaryocytes and monocytes/macrophages (CFU-GEMM). The earliest cell to express the erythropoietin receptor and respond to stimulation with erythropoietin is the burst-forming unit-erythrocyte (BFU-E); it is also the earliest dedicated erythroid progenitor, ultimately proliferating/differentiating into a burst-like array of colony-forming units-erythrocytes (CFU-Es). These CFU-Es continue to respond to erythropoietin as they form a colony of erythroblasts, which lose the ability to proliferate and begin to terminally differentiate and build hemoglobin stores prior to release into the peripheral blood circulation and degradation of the nucleus.

approved its use for treating the anemia associated with chronic renal failure. Renal failure patients were the first obvious targets for treatment with the recombinant protein; their associated anemia is largely attributable to a deficiency of EPO secretion in their failing kidneys. From that point, use of exogenous rhEPO expanded to treating anemias of varied etiologies.

Blood-loss anemia from surgery and/or trauma remains a major indication for allogenic blood transfusion today.[8] The acuity of erythrocyte mass reduction adds unique challenges to anemia from this etiology. Erythrocyte mass replacement must be rapid to avoid cardiovascular strain and physiologic devastation. It is not surprising, therefore, that most of the research with perioperative rhEPO has focused on the pre-operative period prior to elective orthopaedic surgery.[9-15] Recently, the FDA approved use of pre-operative rhEPO for patients with moderate chronic anemia who are preparing for elective hip and knee surgeries, for which significant blood loss is expected.

One study is currently exploring the use of rhEPO in orthopaedic trauma, specifically with pelvis fracture patients,[16] but use of rhEPO to deal with recovery from unanticipated blood loss has been limited.[17] Victims of other major orthopaedic trauma and patients with unexpectedly large intraoperative blood loss from elective surgeries continue to have large transfusion requirements during their hospitalizations. Improved understanding of the physiologic regulation of erythropoiesis may lead to safer options, minimizing the need for allogenic transfusions.

Use of rhEPO after blood loss is partly hampered by the biology by which it exerts its influence. For a cell to be effected by EPO, either recombinant or endogenous, it must express the EPO receptor on its surface. The earliest erythrocyte progenitor to express this receptor, and respond to stimulation by EPO, is the burst-forming unit erythrocyte (BFU-E). Proliferation of the early BFU-E and its precursors is dependent on cytokines other than EPO (Figure 1). Secretion of none of these other cytokines is directly linked with tissue hypoxia. The supply of early BFU-Es may therefore be the major production-limiting factor during the body's attempt to rapidly recover from blood-loss anemia. To evaluate this hypothesis, two factors known to support earlier non-erythroid-specific progenitors were selected to be used in conjunction with rhEPO in a mouse model of blood-loss anemia. The factors selected were stem cell factor (SCF) and interleukin-3 (IL-3).

Stem cell factor, also called steel factor, is the ligand for the c-kit receptor, found on pluripotent stem cells in the hematopoietic as well as other cell lineages. Its presence stimulates proliferation and early differentiation of hematopoietic progenitors, especially in the myeloid line. Interleukin-3 is a stimulator of proliferation more specific for the myeloid lineage.

METHODS

After obtaining approval from the Washington University Animal Care and Use Committee, blood-loss anemia was induced in sixty anaesthetized 20-gram female mice by microcapillary disruption of the retro-orbital plexus and drainage of 0.4 ml of blood, or one-third of the calculated total blood volume. Beginning two days later, all mice received daily subcutaneous injections of saline with albumin as a vehicle for administration of the various treatment regiments. All mice received a single injection of 10mg of iron dextran, 1 week after induction of blood-loss anemia, to remove iron deficiency as a confounding source of persistent anemia.

Treatment Groups

The control group received only vehicle injections, daily for one week, beginning at two days post-bleed. All three experimental groups received injections of 20 units of recombinant human erythropoietin (rhEPO) on the last three days of the week. The first of these experimental groups received only vehicle for the first four days. The second group received a single injection of 480 units of recombinant murine interleukin-3 (rmIL-3), followed by six daily injections of 750 units of recombinant murine interleukin, in addition to the three rhEPO injections. The third experimental group received 0.2 micrograms (mcg) of recombinant murine stem cell factor on the first day and 0.3 micrograms on the subsequent six days, in addition to the three rhEPO injections.

Hematologic Testing

Two days after induction of blood-loss anemia, three mice were euthanized to test for baseline pretreatment anemia, applicable to all groups. Three mice from the IL-3 and SCF groups and three mice from the still-identical EPO/control group were euthanized for testing six days after anemia induction, or the day of the first intended EPO administration. Subsequently, three mice from the IL-3 and SCF groups and five mice from the EPO and control groups were euthanized for testing nine, 13, and 15 days post-anemia-induction.

On testing days, after humane euthanasia, blood was drawn via cardiac puncture, and placed in EDTA-coated microtubes. Automated complete blood counts were performed on a Serono-Baker Diagnostics System 9000 (Allentown, Pennsylvania). Blood for manual reticulocyte counts was stained using the new methylene blue Unopette Test 5821 (Becton-Dickinson, New Jersey) and smeared. Both manual reticulocyte count percentages and reticulocyte production indices (RPIs, corrected for an increased or lowered hematocrit) were calculated.

Bone Marrow Culture

From mice sacrificed on days six and nine post bleed, or just before and just after the three doses of rhEPO, bilateral tibiae and femora were harvested and the marrow collected. This was then cultured in a semi-solid culture, Methocult M3230 (Stemcell Technologies, British Columbia, Canada). Cultures were supported by a standard milieu of multiple hematopoietic cytokines, at 20% carbon dioxide at 37 degrees Celsius. Marrow from one mouse from each group at six days post bleed and two mice from each group at nine days post bleed was cultured. Cultures were scored for the concentration of colony-forming unit erythrocytes (CFU-Es) on day four of culture, and burst-forming unit erythrocytes (BFU-Es) on day eight of culture. These scorings provided a percentage of cells, representative of the time they were obtained from the marrow, that were dedicated to erythrocyte lineages, or a measure of how much the marrow was directed toward erythropoiesis, specifically.

Statistics

One-way analysis of variance was performed initially. Any testing day noted to have significant variance was further tested with a Fisher's pair-wise comparison using individual group-to-group comparison t-tests. Alpha was set at 0.05. No statistical comparisons were performed on the bone marrow culture results, due to the small numbers tested.

RESULTS

Hematologic Data

The hematocrit at the pre-treatment baseline, two days post bleed, was 31.6 ± 2.5. By post-bleed day six, before any rhEPO treatments but after initial treatments with IL-3 and SCF, the groups did not differ significantly. By day nine, immediately after completion of all injection regimens, the EPO-only and control groups did not differ significantly. The SCF group had a significantly higher hematocrit than any other group. The IL-3 group had a significantly higher hematocrit than the control and EPO-only groups. By days 13 and 15, the EPO-only group was no longer superceded by the IL-3 and SCF groups, but all three were still increased over the control group (Figure 2).

The reticulocyte counts and production indices demonstrated higher rates of erythropoiesis in the IL-3 and SCF groups at day nine compared to the EPO-only and control groups (Figure 3). The EPO-only group did have an elevated rate of erythropoiesis over the control by day nine, but the lack of elevation in hematocrit by that point demonstrates that it was newly elevated. Rates of erythropoiesis dropped to below-normal levels in all groups but the control by day 15, reflecting the

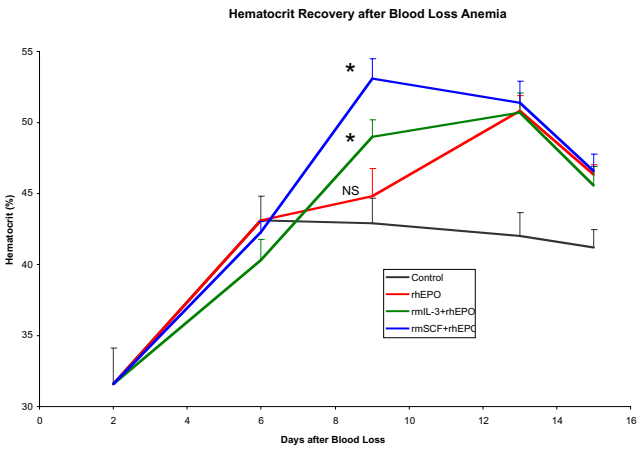

Figure 2. This chart demonstrates the change in hematocrit over time for different cytokine treatment regimens for blood-loss anemia. The groups receiving recombinant murine stem cell factor (rmSCF) or recombinant murine interleukin-3 (rmIL-3) in addition to recombinant human erythropoietin (rhEPO) demonstrate higher and earlier peaks in hematocrit. Recombinant human erythropoietin (rhEPO) alone is not significantly different than the control at day nine. The asterisks denote statistically significant differences from all other groups at the same time point ($p>0.05$). NS denotes no significant difference. Error bars represent standard deviations from the mean.

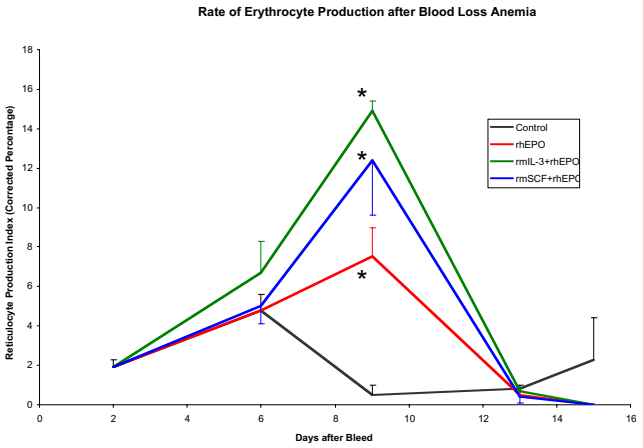

Figure 3. This chart demonstrates the change in reticulocyte production index over time for different cytokine treatment regimens for blood-loss anemia. The reticulocyte production index is a corrected (for hematocrit) percentage of reticulocytes, or recently released, immature red blood cells, among total erythrocytes in the peripheral blood. The index is a measure of the number of red blood cells that have completed the bone marrow stages of erythropoeisis in approximately the last 24 hours, and therefore a measure of the rate of red blood cell production. The groups receiving recombinant murine stem cell factor (rmSCF) or recombinant murine interleukin-3 (rmIL-3) in addition to recombinant human erythropoietin (rhEPO) demonstrate a higher peak rate of erythropoiesis. These groups drop to subnormal rates of red cell production when exogenous cytokines are no longer circulating, as the endogenous secretion of EPO is suppressed by the lack of hypoxia resulting from the supranormal hematocrit. Asterisks denote statistically significant differences from control groups ($p<0.05$). Error bars represent standard deviations from the mean.

supranormal hematocrit, which prevents baseline hypoxia and endogenous EPO secretion.

Bone Marrow Culture Assay

Cultures demonstrated that the mice that received SCF had dramatically higher concentrations of CFU-Es and BFU-Es in their bone marrow both before (Figure 4) and after (Figure 5) exogenous rhEPO administration.

DISCUSSION

A major limiting factor to the effectiveness of exogenously administered rhEPO is the provision of a population of cells able to respond to its stimulation. In these mice, young and healthy, other than their blood-loss anemia, no statistically significant effect on blood restoration over the control was afforded by exogenous administration of EPO alone, until 13 days after induction of anemia, and seven days after initiation of EPO treatments. This argues that endogenous EPO secretion, up-regulated from the hypoxia due to blood loss, may have already saturated the receptors available on EPO-responsive cells. This is in stark contrast to previous experiments in mice without blood loss, which demonstrated a statistically significant and dramatic increase in hematocrit over control mice (60.0% compared to 54.5%) on the first day following three consecutive rhEPO administrations identical to this experiment. The presence of blood loss in an otherwise healthy mouse may have induced sufficient endogenous EPO secretion to render the exogenous rhEPO initially extraneous.

Administration of cytokines known to affect earlier stages of hematopoiesis potentiated the effects of rhEPO on erythropoiesis. Both IL-3 and SCF demonstrated statistically significant increases in hematocrit after administration of exogenous rhEPO. This experiment did not test whether these factors administered without exogenous EPO may have stimulated similarly rapid blood restoration by potentiating the hypoxia-induced elevation in endogenous EPO. While the peripheral blood measures of erythropoiesis were not elevated after the initial doses of SCF and IL-3, but before EPO administration, it cannot be concluded that the exogenous EPO was necessary for the subsequent increase in blood mass over the control. The cells affected by these factors require from four to eightdays to mature into peripheral blood erythrocytes.

That the bone marrow cultured from the SCF treatment group demonstrated markedly increased concentration of erythrocyte-specific progenitors over the control mice, argues that the increased endogenous level of EPO was already directing the proliferation of these

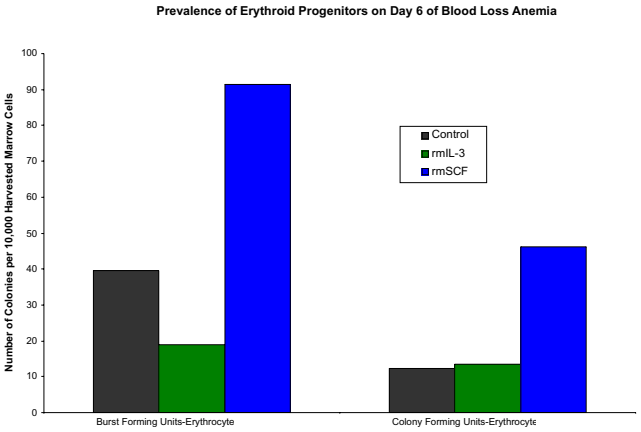

Figure 4. This chart illustrates the concentration of dedicated, early erythrocyte progenitors cultured from the bone marrow of mice after four days of injections with recombinant murine stem cell factor (rmSCF), recombinant murine interleukin-3 (rmIL-3), or vehicle alone. These cells are the earliest cells that will respond to stimulation by erythropoietin. The strength of this population of cells appears to be a major rate-limiting factor in the effectiveness of erythropoietin administration.

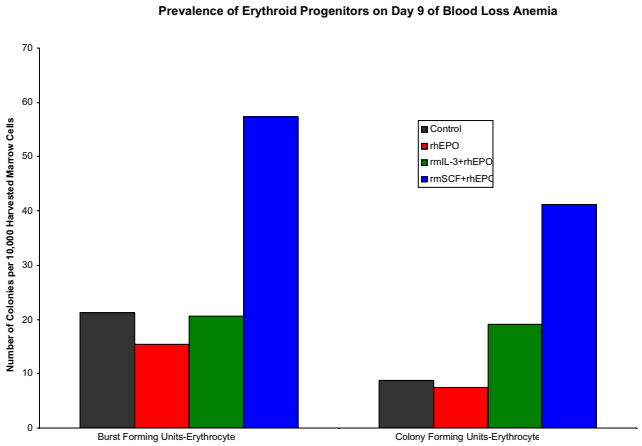

Figure 5. This chart illustrates the concentration of dedicated, early erythrocyte progenitors cultured from the bone marrow of mice after treatment with vehicle alone, recombinant human erythropoietin (rhEPO) alone, or rhEPO with recombinant murine stem cell factor (rmSCF), or with recombinant murine interleukin-3 (rmIL-3). The rhEPO-only group appears to have a lower-than-normal presence of these cells, suggesting that the combination of exogenous and high endogenous levels of EPO, without prior priming to build up the early progenitor population, has depleted it, explaining the lag in red blood cell production in this group.

early progenitors toward the erythroid lineage. While the factors used were expected to increase the number of available cells for EPO to stimulate, they should not have individually stimulated the marrow to focus on erythropoiesis. Perhaps more interesting was that the group receiving rhEPO treatments without other cytokines had a somewhat reduced presence of erythroid progenitors compared to the control. This is important because the increased demand for these cells by the presence of additional EPO did not stimulate a replenishment of their population.

The cytokines which regulate the proliferation of cells leading up to the EPO-responsive BFU-E are not linked to tissue hypoxia as endogenous EPO secretion is. This probably results in a physiologic lag in the erythropoietic response to the endogenous EPO surge induced by tissue hypoxia. Once the available population of BFU-Es is throughput by EPO to mature erythrocytes, the marrow may be slow to replace it. The possibility of stimulating its replacement or even initial build-up with exogenous cytokines holds promise for enabling the body to recover blood volume in a much more rapid sequence.

The higher hematocrits, observed in the groups receiving early-acting cytokines, are explained by the elevated rate of erythropoiesis, which is directly measured with the reticulocyte count and production index. By stimulating the proliferation of progenitors to EPO-responsive cells, the maximal rate of erythropoiesis was both higher and reached earlier. The rate of erythropoiesis was elevated on the first testing after administration of rhEPO alone, but the lack of elevation in hematocrit at this time point argues that this was a very newly elevated rate of production. Further, the rhEPO-only group's reticulocyte production indices were markedly lower than those at the same time point after an identical EPO regiment, outside the setting of blood-loss anemia (15.4 compared to 7.5). The week of endogenously stimulated increased erythropoiesis after the anemia induction had likely depleted the population of EPO-responsive cells. This, along with the suggestion from the bone marrow culture data that the rhEPO group had fewer erythroid progenitors than the control, strengthens the argument that there is a physiologic lag in replenishment of EPO-responsive cells, due to the fact that the factors stimulating the progenitors to that cell population are not up-regulated by tissue hypoxia.

The data demonstrate that it is possible to potentiate the effects of exogenous EPO by administration of cytokines that stimulate proliferation of earlier erythroid progenitors. This information is yet far from being clinically applicable. Recombinant human IL-3 is currently only under FDA-approved investigation for oncologic treatments and recombinant human SCF is not even approved yet for human research. However, these data identify one of the major rate-limiting and volume-limiting factors in the effects of rhEPO on blood restoration: The population of cells responsive to EPO. Expediting and increasing the magnitude of the response to exogenous rhEPO may improve its utility for recovery from blood loss, as opposed to only preparation for

blood loss. As science moves forward, clinical methods of acutely increasing the EPO-responsive cell population may improve the ability to use recombinant cytokines in the management of post-operative and traumatic blood-loss anemia.

REFERENCES

1. **Dodd, R. Y.:** Current safety of the blood supply in the United States. *Int J Hematol,* 80(4): 301-5, 2004.
2. **Bierbaum, B. E.; Callaghan, J. J.; Galante, J. O.; Rubash, H. E.; Tooms, R. E.; and Welch, R. B.:** An analysis of blood management in patients having a total hip or knee arthroplasty. *J Bone Joint Surg Am,* 81(1): 2-10, 1999.
3. **Blumberg, N.:** Allogeneic transfusion and infection: economic and clinical implications. *Semin Hematol,* 34(3 Suppl 2): 34-40, 1997.
4. **Borghi, B., and Casati, A.:** Incidence and risk factors for allogenic blood transfusion during major joint replacement using an integrated autotransfusion regimen. The Rizzoli Study Group on Orthopaedic Anaesthesia. *Eur J Anaesthesiol,* 17(7): 411-7, 2000.
5. **Innerhofer, P.; Walleczek, C.; Luz, G.; Hobisch-Hagen, P.; Benzer, A.; Stockl, B.; Hessenberger, G.; Nussbaumer, W.; and Schobersberger, W.:** Transfusion of buffy coat-depleted blood components and risk of postoperative infection in orthopedic patients. *Transfusion,* 39(6): 625-32, 1999.
6. **Murphy, P.; Heal, J. M.; and Blumberg, N.:** Infection or suspected infection after hip replacement surgery with autologous or homologous blood transfusions. *Transfusion,* 31(3): 212-7, 1991.
7. **Groopman, J. E.; Molina, J. M.; and Scadden, D. T.:** Hematopoietic growth factors. Biology and clinical applications. *N Engl J Med,* 321(21): 1449-59, 1989.
8. **Goodnough, L. T.; Riddell, J. t.; Verbrugge, D.; and Marcus, R. E.:** Blood transfusions in hip fracture patients: implications for blood conservation programs. *J Orthop Trauma,* 7(1): 47-51, 1993.
9. Effectiveness of perioperative recombinant human erythropoietin in elective hip replacement. Canadian Orthopedic Perioperative Erythropoietin Study Group. *Lancet,* 341(8855): 1227-32, 1993.
10. **Adamson, J.:** Perisurgical use of epoetin alfa in orthopedic surgery patients. *Semin Hematol,* 33(2 Suppl 2): 55-8; discussion 59, 1996.
11. **de Andrade, J. R.; Jove, M.; Landon, G.; Frei, D.; Guilfoyle, M.; and Young, D. C.:** Baseline hemoglobin as a predictor of risk of transfusion and response to Epoetin alfa in orthopedic surgery patients. *Am J Orthop,* 25(8): 533-42, 1996.
12. **Faris, P. M.; Spence, R. K.; Larholt, K. M.; Sampson, A. R.; and Frei, D.:** The predictive power of baseline hemoglobin for transfusion risk in surgery patients. *Orthopedics,* 22(1 Suppl): s135-40, 1999.
13. **Goldberg, M. A.; McCutchen, J. W.; Jove, M.; Di Cesare, P.; Friedman, R. J.; Poss, R.; Guilfoyle, M.; Frei, D.; and Young, D.:** A safety and efficacy comparison study of two dosing regimens of epoetin alfa in patients undergoing major orthopedic surgery. *Am J Orthop,* 25(8): 544-52, 1996.
14. **Schlaeppi, B.; Gunter, P.; and Nydegger, U. E.:** Enhancing the efficacy of preoperative autologous blood donation by erythropoietin. *Transfus Sci,* 15(2): 171-7, 1994.
15. **Tryba, M.:** Epoetin alfa plus autologous blood donation and normovolemic hemodilution in patients scheduled for orthopedic or vascular surgery. *Semin Hematol,* 33(2 Suppl 2): 34-6; discussion 37-8, 1996.
16. **Mears, D. C.; Durbhakula, S. M.; and Miller, B.:** Developments in blood management: the potential therapeutic role for epoetin alfa in orthopedic trauma. *Orthopedics,* 22(1 Suppl): s151-4, 1999.
17. **Hoynck van Papendrecht, M. A.; Jeekel, H.; Busch, O. R.; and Marquet, R. L.:** Efficacy of recombinant erythropoietin for stimulating erythropoiesis after blood loss and surgery. An experimental study in rats. *Eur J Surg,* 158(2): 83-7, 1992.

CYTOGENETICS OF SWARM RAT CHONDROSARCOMA

Jeff W. Stevens, Ph.D.,[1] Shivanand R. Patil, Ph.D.,[2] Diane K. Jordan, Ph.D.,[3]
James H. Kimura, M.D.,[4] Jose A. Morcuende, M.D., Ph.D.[1]

ABSTRACT

The Swarm rat chondrosarcoma is a tumor tissue line derived from a tumor that arose spontaneously in a Sprague-Dawley rat. The original tissue has given rise to several tissue lines and cell lines that have been prepared in different laboratories. It has been observed that these lines differed in their growth rates and biochemical characteristics. We have characterized our Swarm rat chondrosarcoma tissue and cell lines currently in use in terms of their cytogenetic profiles and their tumorigenic properties *in vivo*. We found a wide variety of chromosomal abnormalities among cell lines, including translocations, deletions and polyploidy. There were also significant differences in their growth properties *in vivo*, giving rise to tumors of a few milligrams in the case of Ng cells, to 35 grams in the tissue line JWS. The cytogenetic complexity of the Swarm rat chondrosarcoma between and among different lines makes it very suitable to address questions about the changes that occur as a result of karyotypic abnormalities and to provide links between cytogenetic abnormalities and the dynamic oncogenic machinery.

[1]Department of Orthopaedics and Rehabilitation
University of Iowa Hospitals and Clinics
Iowa City, Iowa

[2]Department of Pediatrics
University of Iowa Hospitals and Clinics
Iowa City, Iowa

[3]Cytogenetics Laboratory
OSF St. Francis Medical Center
Peoria, Illinois

[4]Department of Surgery
John A. Burns School of Medicine
Honolulu, Hawaii

Correspondence:
Jeff W. Stevens, Ph.D.
Department of Orthopaedics and Rehabilitation
Ignacio V. Ponseti Laboratory of Biochemistry
and Molecular Biology
200 Hawkins Drive
Iowa City, IA 52242-1181
Phone: (319) 335-7752
Fax: (319) 335-7968
E-mail: jeff-stevens@uiowa.edu

INTRODUCTION

Chondrosarcoma represents the second most common primary malignant skeletal tumor, comprising up to 24% of all bone tumors. Despite the new advances in adjuvant therapy, surgical resection is the only effective standardized treatment. Chondrosarcomas do not respond to chemotherapy or radiation therapy, therefore, metastatic disease in these tumors is rarely amenable to curative treatment. The five-year survival for patients with grade III tumors is only 29%. To improve survival rates in patients with high-grade chondrosarcomas, a better understanding of its biology is necessary.

The Swarm rat chondrosarcoma[2] is a tumor tissue line derived from a tumor that arose spontaneously in a Sprague-Dawley rat.[9] It has been maintained through the years by serial subcutaneous transfer from rat to rat. Histologically, the tumor is a well-differentiated chondrosarcoma with mild-to-moderate cellular atypia. Interestingly, several tissue and cell lines derived from this primary tumor are available in a number of laboratories. These tissue and cell lines have been the subject of extensive biochemical studies on extracellular matrix molecules and chondrocyte metabolism.[1-17]

We have previously reported a comprehensive gene expression profiling on a tissue line (JWS) of the Swarm rat chondrosarcoma.[12] This tissue line grows very aggressively when injected subcutaneously, reaching up to 35 grams about four weeks after injection. A survey of some of the groups that have been maintaining other lines of this tumor revealed that the various cell and tissue lines exhibit a wide variation in tumor growth and extracellular matrix metabolism. In this study, we evaluate the cytogenetic and *in vivo* tumor growth characteristics of several tissue and cell lines of Swarm rat chondrosarcoma to determine if the variation in tumor behavior can at least in part be accounted for by variations in karyotype.

MATERIAL AND METHODS

Swarm Rat Chondrosarcoma Tissue Lines and Cell Lines

Two tissue lines (TGO and JWS) and four different cell lines (LTC 86, LTC 93, Rex, and Ng)[7] were used. The TGO and JWS are tissue lines derived from the

TABLE 1
Chromosome numbers in Swarm rat chondrosarcoma

	chromosome count															
source	**<42**	**modal#**	**diploid**	**43**	**70**	**<75**	**84**	**78-89**	**<82**	**74-82**	**82-84**	**>84**	**86-90**	**90-100**	**~160**	**total**
TGO	1		4		1	1	2									9
JWS	5		26	4				6						12		53
Rex									15		3				2	20
Ng									6		9	5				20
LTC86		96								3			3	19		25
LTC93		77				4			11		5					20

TABLE 2
Chromosomal rearrangements in Swarm rat chondrosarcoma

Chromosome	TGO	JWS	Ng	Rex	LTC86	LTC93
1	-1, -1		der(1)	der(1)		-1, t(1q;11)
2			+2	-2, add(2p)		-2, t(1q;2)
3	-3, i(3q), t(3q;11)x2		-3, -3, -3	-3, -3, i(3q)	add(3p), (3q;11), +t(3q;11)x2	-3,-3, ?add(3q)
4	+i(4q),	+4	+add(4q), add(4q)x2	+4, +add(4q)x2	+4, +add(4q), +t(4q;11)	-4, ?der(4), i(4q) i(4q)
5	-5, -5		-5, add(5p)x2	-5, -5, -5, t(5q;8)	add(5p), t(5q;8)	-5, -5, -5, t(5q;8)
6	-6, i(6q)		add(6q)	-6, i(6q)	-6	-6
7	add(7p)x2		-7	-7, t(7q;9)	+7, +add(7p)	+t(7q;8), add(7p), t(7q;?9)
8	add(8p), t(8q;10)	-8	-8, t(8q;X)	-8, -8	+8	-8, -8, -8, 8?
9	-9	-9	-9	t(9q;11)	-9, -9	-9,-9, 9?
10	-10, -10, -10		-10	+10	-10	t(10q;11)
11	-11		+11, +add(11q)	-11, -11, add(11p)	add(11p)	+add(11q) x2
12		-12	-12, -12	-12, -12	add(12q)	-12,
13	i(13q)		-13	-13, add (13p)	del(13q)	-13, -13, ?add (13p), add (13q)
14	-14,-14,-14		add(14q)	-14, -14	i(14p)x3	add(14q)
15	-15,-15		-15, -15, add(15p)	-15, -15	-15, i(15q)x2	-15, add(15q), i(15q)
16	-16,-16			-16	-16, -16	
17	-17,-17		-17, -17	-17, -17	+17	-17, -17, -17
18	-18,-18			-18	-18, -18	-18, -18
19	+19,+19		-19		+19, +19	-19, -19, -19
20			-20, -20		add(20q)	-20
markers	5	0	16	16	13	15
X	XXXX, t(X;8)	XX	XX	XX	XX	X, t(Xq;4)
Y	Y	YY	YY	YY	YY	Y?Y?

Swarm rat chondrosarcoma tumor and they have been maintained by serial subcutaneous injections. The LTC line which can be propagated entirely *in vitro* was derived from long-term culture of rat chondrosarcoma tumor tissue with repeated selection for non-adherent or floating cells. Continued propagation of this line led to several variant cell lines as well as a few clonally derived cell lines.[7] LTC 86 was from an early passage in 1986, while LTC 93 was from a passage seven years later in 1993. Rex and Ng were lines cloned from the LTC parent line.

Tumor Induction and Tumor Growth Measurement

Animal care protocol was approved by the University of Iowa. Male, four-week-old Sprague-Dawley rats were used. Tumor induction was performed by injection of the tissue line or cell line subcutaneously on both sides of the lumbar spine (2 injections per animal). For tissue lines (TGO and JWS), 40-50 ml (~5 x 10^5 cells) of tumor slurry[6] was used. For cell lines, 1 x 10^7 (LTC 86, LTC 93, Rex, Ng) in 0.5 ml of Dulbecco's Modified Eagle Medium was used for each injection. The animals were euthanized 35 days post injection in the case of tumor slurries and at 70 days after injection of tissue-cultured cell lines. The tumors were removed, weighed, and processed for histology as previously described.[16] A necropsy was performed to establish the presence or absence of metastases.

Cytogenetic Analysis

The cytogenetic techniques used for chromosome analysis have been described previously.[15] Aseptically collected 1- to 2-cm^3 samples were mechanically and enzymatically disaggregated[6] and cultured in RPMI 1640 medium supplemented with 20% fetal bovine serum, 1% penicillin/streptomycin, and 1% L-glutamine for one to ten days. Three to eight hours before harvest, cells were exposed to colcemid (0.02 mg/ml) to achieve metaphase arrest. After incubation in hypotonic solution, the preparations were fixed three times with 3:1 methanol:glacial acetic acid, and dropped onto water-rinsed slides. Chromosomes were stained by the GTW (G-bands by trypsin using Wright's stain) banding method. The chromosome number was determined by microscopic analysis and cells were examined for the presence or absence of detectable structural rearrangements. Karyotypes were prepared from digitized images of these metaphases. When possible, about 15-20 metaphases were scored (counted and checked for markers) for each specimen. However, a detailed analysis and complete karyotype were only performed on a small number of the cells (minimum of two) from each sample. In some cases, there was only a limited characterization of structural abnormalities, due to the complexity of the karyotypes. Normal male rat cells were used as controls. Karyotypes were based on the nomenclature rules for rat chromosome G-bands.[8] The system for rat chromosome nomenclature closely follows the international system for human cytogenetic nomenclature.[10]

RESULTS

Karyotype Analysis

The results of the cytogenetic analysis from the different Swarm rat chondrosarcoma tissue and cell lines are presented in Tables 1 and 2. Abnormal karyotypes were observed in all cases. No cultures contained any de-differentiated cells.

TGO cells were the only cells demonstrating a very slow growth when cultured for cytogenetic studies. Five cultured flasks were used for analysis. Only a limited number of cells were available for analysis after multiple attempts to obtain dividing cells. Nine cells were counted; five cells were in the diploid range (37-42 chromosomes); and four cells were in the hypertriploid to tetraploid range (70-84 chromosomes). Several chromosomal abnormalities were observed in this tissue line, including deletion of chromosomes 1, 5, 9, 10, 11, 12, 14-18; i(3q); t(3q;11)x2; +i (4q); -6, i(6q); add (7p)x2; t(8q;10); i(13q); +19; and XXXX , t(X;8).

JWS cells (53 examined) demonstrated that the majority of cells (26) were diploid, with 42 chromosomes, or near-diploid (nine cells), with 40-43 chromosomes. Six cells were in the tetraploid range, with 78-89 chromosomes. The remainder of the cells were in the hypertetraploid to hypopentaploid (90-100 chromosomes) range. There was no evidence of structural abnormalities.

LTC 86 cells (25 examined) demonstrated 12 cells in the near-tetraploid range, with 74 to 94 chromosomes. The remaining 13 cells were in the hypopentaploid range, with 95 to 99 chromosomes. The modal chromosomal number was 96. Numerous structural rearrangements and marker chromosomes were present (Table 2).

LTC 93 cells (20 examined) demonstrated four cells in hypertriploid range, with 70 to 73 chromosomes. The remaining 16 cells were in the near-tetraploid range, with 75 to 84 chromosomes. The modal chromosomal number was 77. Numerous structural rearrangements and marker chromosomes were present (Table 2).

Rex cells (20 examined) demonstrated 18 cells in the near-tetraploid range, with 76-82 chromosomes. Two cells were octaploid, with approximately 160 chromosomes. Numerous structural rearrangements and marker chromosomes were present (Table 2).

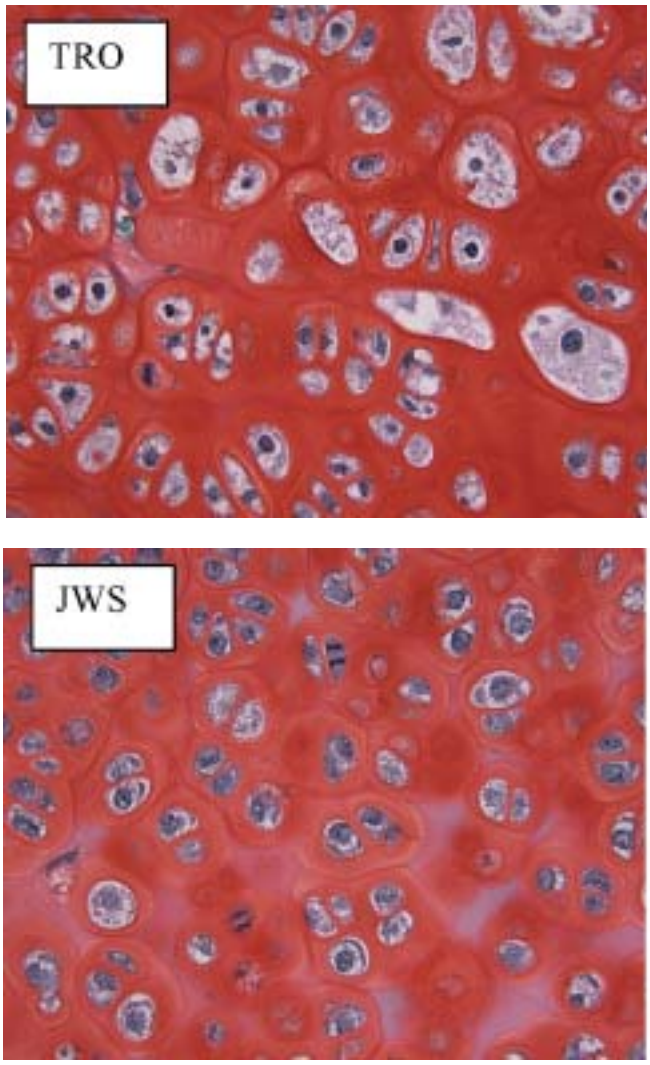

Figure 1. Histopathological features of the Swarm rat chondrosarcoma. Note a well-differentiated chondrosarcoma with mild to moderate cellular atypia. Safranin O staining, 400x

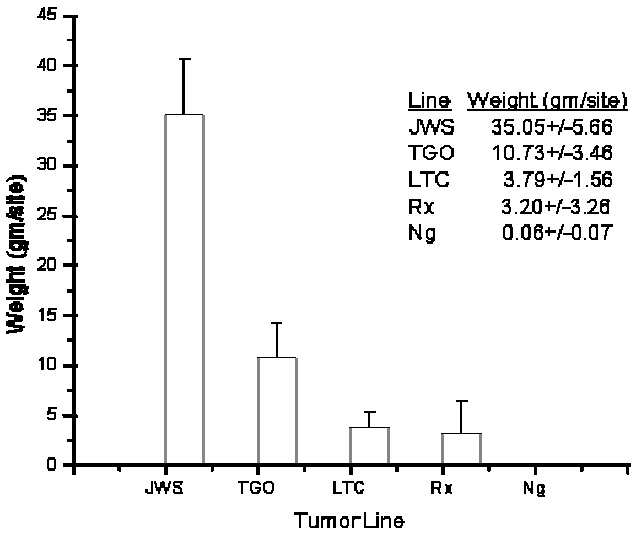

Figure 2. *In vivo* tumor growth of the different tumors and cell lines.

Ng cells (20 examined) had chromosome counts in the hypertriploid to hypertetraploid range, with 69-86 chromosomes. Numerous structural rearrangements and marker chromosomes were present (Table 2).

In vivo Tumor Growth

Tissue lines and cell lines were injected subcutaneously into both sides of the lumbar spine. The animals were sacrificed 35 or 70 days post injection. The tumor lines were of a well-differentiated chondrosarcoma with mild cellular atypia (Figure 1). The tumors were weighed. It was found that there was a great variability in tumor growth among cell lines (Figure 2). JWS grew up to 35 grams of tumor in most cases, more than doubling the size of the TGO-induced tumors. Both LTC and Rex grew moderately-sized tumors (3 grams). However, Ng cells did not result in much tumor growth (about 60 mg). There was no evidence of metastases in any of the tissue or cell lines.

DISCUSSION

Swarm rat chondrosarcoma is one of the most useful cell culture systems for the study of cartilage metabolism. The cells grow very reliably under many culture conditions and they produce great amounts of extracellular matrix. In addition, when injected into the subcutaneous tissue or into the bone, they behave in a manner closely resembling the behavior of human chondrosarcoma.

Since the isolation of the tumor in the 1960's, many laboratories have maintained tissue lines and cell lines for experimental work. Due to investigator preferences and to differences in experimental designs, a selection in cell populations has occurred over the years. Since many of the biochemical extracellular matrix characteristics have been very consistent among laboratories, and because the cells came from the same original tumor, it has been assumed that these tissue and cell lines were similar.

However, in this study, we observed that the karyotypes and *in vivo* tumor growth of several tissue lines and cell lines were very different. The cytogenetic analysis also demonstrated a wide range of numerical and structural abnormalities among the lines. While caution must be used in comparing the significance of chromosomal differences among the cell lines due to the lim-

ited number of cells that were completely karyotyped because of the complex chromosome constitution, some differences were found. For instance, the two tissue lines (TGO and JWS) have complex cell populations with cells in hypodiploidy and other cells in pentaploidy (cells with >100 chromosomes). However, TGO cells demonstrated several chromosome deletions and numerous structural abnormalities that were not present in JWS. Interestingly, the karyotypes of the LTC cell subclones (Ng, Rex) indicate that these cells are related, with the later LTC (1993) clone having fewer chromosomes but more stable cell counts than the earlier clone (1987).

The *in vivo* tumor growth varied from just a few milligrams in the case of the Ng cells up to 20 grams of tumor in JWS. Interestingly, the *in vitro* growth of the different tissue and cell lines demonstrate the same growth curves (data not shown). There was no evidence of metastases in any of the cell lines when injected subcutaneously.

The present view of malignant transformation and tumor progression requires the accumulation of multiple genetic alterations such as chromosomal abnormalities, oncogene activation, loss of tumor suppressor genes, or abnormalities in genes that control DNA repair and genetic stability. This view correlates with the increasing complexity of karyotypes seen during tumor progression. Importantly, in malignant human cartilage tumors, a strong cytogenetic-pathologic correlation between complex karyotypes and high-grade chondrogenic tumors has been reported. The cytogenetic complexity of the Swarm rat chondrosarcoma model, therefore, makes it very suitable for experimental work designed to address questions on the changes that occur as a result of the DNA abnormalities and to provide links between genetic abnormalities and the dynamic oncogenic machinery. Further studies will take advantage of micro-array hybridization technology and SAGE technology to increase our understanding of the biology of chondrosarcoma, and that might allow the development of more specific and targeted therapies.

ACKNOWLEDGMENTS

We acknowledge Gail Kurriger for the technical support in this study, Dr. Jerry A. Maynard for his assistance with microscopy, and Dr. Theodore R. Oegema, Jr. for the Swarm chondrosarcoma samples.

REFERENCES

1. **Caterson, B.; and Baker, J. R.:** The link proteins as specific components of cartilage proteoglycan aggregates in vivo. Associative extraction of proteoglycan aggregate from Swarm rat chondrosarcoma. *J. Biol. Chem*., 254:2394-2399, 1979.
2. **Choi, H.U.; Meyer, K.; and Swarm, R.:** Mucopolysaccharide and protein-polysaccharide of a transplantable rat chondrosarcoma. *Proc. Natl. Acad. Sci. U. S. A.*, 68:877-879, 1971.
3. **Faltz, L.L.; Caputo, C.B., Kimura, J. H.; Schrode, J; and Hascall, V.C.:** Structure of the complex between hyaluronic acid, the hyaluronic acid-binding region, and the link protein of proteoglycan aggregates from the Swarm rat chondrosarcoma. *J. Biol. Chem*., 254:1381-1387, 1979.
4. **Fernandes, R. J.; Schmid, T. M.; Harkey, M. A.; and Eyre, D. R.:** Incomplete processing of type II procollagen by a rat chondrosarcoma cell line. *Eur. J. Biochem*., 247:620-624, 1997.
5. **Kimata, K.; Hascall, V.C.; Kimura, J.H.:** Mechanisms for dissociating proteoglycan aggregates. *J. Biol. Chem*., 257:3827-3832, 1982.
6. **Kimura, J. H.; Hardingham, T. E.; Hascall, V. C.; and Solursh, M.:** Biosynthesis of proteoglycans and their assembly into aggregates in cultures of chondrocytes from the Swarm rat chondrosarcoma. *J. Biol. Chem*., 254:2600-2609, 1979.
7. **King, K.B.; and Kimura, J.H.:** The establishment and characterization of an immortal cell line with a stable chondrocytic phenotype. *J. Cell. Biochem*., 89:992-1004, 2003.
8. **Levan, G.:** Nomenclature for G-bands in rat chromosomes. Hereditas 77:37-52, 1974.
9. **Maibenco, H.C.; Krehbiel, R.H.; and Nelson, D.:** Transplantable osteogenic tumor in the rat. *Cancer Res*., 27:362-366, 1967.
10. **Mitelman F** (ed): *An international system for human cytogenetic-nomenclature*, S. Karger, Basel, 1995.
11. **Mason, R. M.; and Bansal, M. K.:** Different growth rates of Swarm chondrosarcoma in Lewis and Wistar rats correlate with different thyroid hormone levels. *Connect. Tissue Res*., 16:177-185, 1987.
12. **Morcuende, J.A., Huang, X.D., Stevens, J., Kucaba, T.A., Brown, B., Abdulkawy, H., Sheetz, T.E., Malchenko, S., Bonalda, F., Casavant, T.L., Soares, B.:** Identification and initial characterization of 6,000 expressed sequenced tags (ESTs) from rat normal-growing cartilage and swarm rat chondrosarcoma cDNA libraries. *Iowa Orthop J.*, 22:28-34, 2002.
13. **Oegema, T.R., Jr.; Hascall, V.C.; and Dzwiewiatkowski, D.D.:** Isolation and characterization of proteoglycans from the Swarm rat chondrosarcoma. *J. Biol. Chem*., 250:6151-6159, 1975.

14. **Oegema, T. R., Jr.; and Parzych, S.M.:** Effect of the retinoic acid analog Ro 11-1430 on proteoglycans of Swarm rat chondrosarcoma. *J. Natl. Cancer Inst.*, 67:99-106, 1981.
15. **Priest, J.H.:** General cell culture principles and fibroblast culture. In *The AGT cytogenetics laboratory manual*, Third edition. Barch, M.J.; Knusten, T.; and Spurbeck, J.L. (eds). Lippincott-Raven Publishers, Philadelphia, pp 173-197, 1997.
16. **Stevens, J.W.; Kurriger, G.L.; Carter, A.S.; and Maynard, J.A.:** CD44s expression in the developing and growing rat intervertebral disc. *Dev. Dynamics.* 219:381-390, 2000.

LIMITATIONS OF ISOKINETIC TESTING TO DETERMINE SHOULDER STRENGTH AFTER ROTATOR CUFF REPAIR

David Yen, M.D.

ABSTRACT

Some investigators have reported incomplete data when using isokinetic testing as a means of analyzing shoulder strength after rotator cuff repair. An explanation provided has been that the subjects could not reach the speed at which the machine was set. The purpose of this study was to determine if strength data could be generated for all motions being tested by using not only the one or two speeds employed by others, but three speeds across the spectrum of those available. Inclusion criteria were a minimum of two years since surgery with a normal contralateral shoulder. All eligible subjects had isokinetic testing of the non-operated shoulder followed by the operated shoulder, in flexion, abduction and external rotation, tested at 60˚, 120˚ and 180˚ per second. Fourteen patients were eligible and tested. Isokinetic data showed deficiencies in strength in the operated shoulder compared to the opposite side for abduction, external rotation and flexion of 14%, 27% and 20% respectively. In 10/123 (8%) of the tests, the patients could not reach the preset velocity to yield valid data. One patient could not place and maintain the operated arm in the test position of 90˚ of shoulder abduction. There was a significant deficiency in abduction at only one of three speeds. This study confirms that isokinetic testing is a powerful tool that lends itself well to producing objective data on shoulder strength after rotator cuff repair, but it also has the limitation that some patients cannot reach the preset velocity for some motions, or place and maintain the operated arm in the test position for the movements being tested. Therefore, to optimize the chances of obtaining isokinetic data for all movements after rotator cuff repair, we suggest using speeds for all motions and consideration of scapular, frontal and sagittal planes for testing.

Department of Surgery
Division of Orthopaedics
Queen's University
Kingston, Ontario, Canada

Correspondence:
David Yen, M.D.
Assistant Professor
Program Director
Division of Orthopaedics
Douglas 5
Kingston General Hospital
76 Stuart Street
Kingston, Ontario, Canada K7L 2V7
telephone: (613) 548-2545
fax: (613) 548-2518
e-mail: yend@kgh.kari.net

INTRODUCTION

Over recent years, various studies have reported good results for surgical treatment of open, mini-open and arthroscopic rotator cuff repairs.[1-11] Some of these studies have employed objective testing.[1,2,3,4,5,6,7] Isokinetic testing has been reported as an objective, useful, reliable and accurate means of analyzing shoulder strength after rotator cuff repair.[2,3,5,6] A review of the literature found that some reports had incomplete isokinetic data for their patients.[2,3,4] In the paper by Walker et al.,[2] four of 46 patients had incomplete isokinetic data. In the study by Grana et al.,[4] only 33 of 54 had isokinetic evaluation, but the authors did not elaborate on the incomplete evaluations. Rabin and Post[3] reported that only 33% of their patients could generate enough torque to begin the test, and only 13% completed the test.

Reports of strength following rotator cuff repair using isokinetic testing, employ one or two speeds. It is customary to use a slow speed for strength and a fast speed for power, with the optimum test speeds being unknown.[2] Investigators have reported results using 60˚ per second,[6] 90˚ per second,[3,5] and both 60˚ and 120˚ per second.[2] Shklar and Dvir [12] have used 60˚, 90˚ and 120˚ per second to test healthy volunteers.

We hypothesized that using three speeds to test patients having had rotator cuff repairs would facilitate obtaining isokinetic data for all motions being testing in these subjects. The objective of this study was to determine the efficacy of using isokinetic testing at speeds of 60˚, 90˚ and 120˚ per second in minimizing loss of isokinetic data.

METHODS

Inclusion criteria for study entry were: a minimum of two years since rotator cuff surgery, no procedures to the shoulder other than those under investigation, an asymptomatic pain-free contralateral non-operated shoulder, no inflammatory lesion of either shoulder which could affect function, and informed consent to participate in the study. All rotator cuff repairs were performed using open techniques by two staff surgeons at two hospitals—Kingston General Hospital, Ontario, and Hotel Dieu Hospital, Ontario.

All subjects had isokinetic testing using the Cybex II isokinetic dynamometer (Lumex, Ronkonkoma, New York) incorporating the Cybex Data Reduction Computer. The non-operated side was tested first,followed by the operated side. Shoulder flexion, abduction and external rotation were tested with five repetitions at each of three different speeds: 60˚, 120˚ and 180˚ per second. The order of movement patterns and speeds was determined randomly. For all testing, a minimum of five minutes was permitted between the testing of the different movement patterns, and a minimum of two minutes between testing at the different speeds. Verbal encouragement for maximal speed, and as full a range of motion as possible, was provided throughout the testing procedure.

The isokinetic testing was done according to the protocol per Cybex. For flexion, the subject was supine with the axis of rotation of the shoulder joint aligned with the axis of rotation of the Cybex dynamometer arm. The handgrip and Cybex lever arm were adjusted to permit full elbow extension. For testing of abduction, the subject was seated on the bench tilted 40˚ from the vertical. The Cybex dynamometer was tilted backward, also to 40˚, to ensure that it and the subject's arm were in the same plane of movement. For testing of external rotation, the subject was supine with the arm abducted to 90˚. The upper arm was secured by a Velcro strap into a padded V-shaped support so the upper arm was parallel to the floor. The rotational axis of the dynamometer was aligned with the rotational axis of the shoulder joint. The forearm was at 90˚ to the upper arm as the subject grasped the hand grip.

Results were given as a relative percentage deficiency in strength of the operated side compared to the non-operated side. Data was examined with a paired t-test.

RESULTS

Retrospective chart review of 52 consecutive patients with rotator cuff repairs identified 14 that fit the inclusion criteria and provided data for analysis. The average age was 58 years old (range, 37 to 78). There were 13 males and one female. The average time from onset of symptoms until repair was 15 months (two weeks to 13 years). The dominant arm was repaired in nine and non-dominant in five. Time since repair averaged four years (two to nine years). The type of open repair was side-to-side in four, and attachment to a trough in ten.

Analysis of the isokinetic data for shoulder abduction using the t-test showed a significant deficiency in strength ($p<0.05$) of the operated shoulder only at the speed of 120˚ per second. The average deficit in strength across all speeds for shoulder abduction was 14%.

All isokinetic data related to shoulder rotation was for 13 subjects only. This is because one subject was unable to place and maintain the operated arm in the test position of 90˚ of shoulder abduction.

Application of the t-test to the data for shoulder external rotation showed a significant deficiency at all three speeds tested ($p<0.05$). The average deficit in strength across all speeds for shoulder external rotation was 27%.

Application of the t-test to the data for flexion showed significant weakness of the operated shoulder compared to the non-operated side ($p<0.05$) at all three speeds tested. The average deficit in strength across all three speeds for shoulder flexion was 20%.

In ten out of 123 tests (8%), there was a 100% difference between the operated and non-operated shoulders: subjects eight and 13 at 180˚ in flexion; subject six at 60˚ and 120˚; subject 11 at 180˚; subject 13 at 120˚ and 180˚ in abduction; subject 12 at 60˚, 120˚ and 180˚ in external rotation.

DISCUSSION

Over the years, there has been an evolution from open to mini-open to arthroscopic surgery to treat rotator cuff tears. In studies comparing and contrasting the results of different surgical techniques, some investigators have reported clinical grading of strength after rotator cuff repair, while others have used maximum isometric contraction to gauge strength.[1,8] These methods test strength at a single joint position. Isokinetic testing has the advantage of allowing dynamic torsional forces to be recorded throughout the functional range of motion.

Using isokinetic testing, Kirschenbaum et al., Rokito et al. and Walker et al. have found strength values of 104%, 142% and 97%; 90%, 91% and 84%; 80%, 90% and 75% for abduction, external rotation and flexion, respectively, at one year following rotator cuff repairs.[2,5,6]

Converting the amount of strength deficit found in our study to the corresponding relative strength values of the operated versus opposite shoulder yields results of 85%, 73% and 80%. Although no conclusions concerning the effect of surgical repair of rotator cuff tears could

be made due to our retrospective study design and small sample size, our results obtained are in general agreement with those reported in the literature, supporting the validity of our method of isokinetic testing.

With our method of isokinetic testing we were able to generate objective data amenable to analysis. However, we discovered that there was an instance in which the data indicated that at a speed of 120˚ per second, there was a 100% deficiency in performing shoulder abduction on the operated arm compared to the non-operated side, while for the same motion at 60˚ per second, the opposite was true. The explanation for this phenomenon lies in the way the apparatus works.

The machine is designed to record a subject's attempt to exceed the preset velocity. It is this attempted acceleration that the machine measures and converts into moments around the dynamometer axis. If a subject does not reach this preset value, a "0" output is registered. Consequently, regardless of the absolute value recorded on the comparison side, provided some value is recorded, a 100% deficit will be registered when bilateral comparisons are made. Therefore, the comparison is not quantified, but rather is arbitrary, and no useful data for analysis is yielded for that speed. Data for that particular motion must be obtained using a different testing speed. These phenomena must be suspected whenever a 100% deficit is measured. Upon closer examination of all of the data, we discovered that this occurred in 10 out of 123 (8%) of the tests, and involved various patients and testing speeds. In addition, when considering the pooled data, there was a significant deficiency in abduction at only one of three speeds. These findings demonstrate that, similar to other studies, we also had incomplete isokinetic data. However, because we used three speeds to test each motion, we were able to find a speed whereby a measurement of subject performance could be registered for each motion.

If we had only used the one or two speeds routinely employed in previous studies, there would have been instances where no data for a particular movement would have been obtained. Specifically, in subjects eight and 13, we would not have obtained data for flexion if only 180˚ was used; in subject six, we would not have obtained data for abduction if either 60˚ or 120˚ were used; in subject 11, we would not have obtained data for abduction if only 180˚ was used; in subject 13, we would not have obtained any data for abduction if either 120˚ or 180˚ were used.

Another problem encountered in using the Cybex II isokinetic dynamometer was that one subject could not place their arm in the test position of 90˚ of shoulder abduction for testing of external rotation. Leroux et al. reported that 56 of their 128 patients were excluded from isokinetic testing following anterior acromioplasty, sometimes combined with rotator cuff repair, because of pain and articular range limitations.[13] We were not sure from this that they had the same problem we found. Other authors have reported isokinetic testing of external rotation in normal volunteers employing the scapular rather than traditional frontal or sagittal planes.[14,15]

Although this is a different patient population, it is worth considering testing rotator cuff repairs in several planes in order to find a circumstance in which some measurement of subject performance can be registered. We had not anticipated this positioning problem, and when it was discovered we could not logistically retest internal rotation for all of our patients using the scapular plane.

In seeking a reference in which to compare postoperative results, it was noted that preoperative power testing in the presence of rotator cuff lesions is limited by restricted range of motion and pain. Heterogeneous patient characteristics restrict the use of standardized values from healthy individuals. Therefore, in this study the patient's contralateral shoulder was used as the control and we restricted the subjects investigated to those having asymptomatic contralateral shoulders. Shklar and Dvir,[12] and Ivey and colleagues,[16] have reported that there is no statistical difference in isokinetic testing between dominant and nondominant shoulders in normal volunteers, therefore providing support for our method of obtaining controls. Watson[17] reported that the results of rotator cuff repair continued to improve postoperatively, reaching a plateau at two years after surgery. Therefore, we selected patients that were a minimum of two years post-operative to maximize their ability to perform the isokinetic te sting. All of these factors resulted in a small but unique subgroup of the total cuff repairs (14/52) that were done over the investigation period.

In conclusion, this study confirms that isokinetic testing is a powerful tool that lends itself well to producing objective data on shoulder strength after rotator cuff repair. However, unlike the situation with normal volunteers, we found that when used in patients after rotator cuff repair, some subjects were not able to reach the preset velocity and were not able to place and maintain the operated arm in the test position. Therefore, to optimize the chances of obtaining isokinetic data for all movements after rotator cuff repair, we suggest using speeds of 60˚, 120˚ and 180˚ per second for all motions, and consideration of scapular, frontal and sagittal planes for testing.

REFERENCES

1. **Gore DR, Murray MP, Sepic SB, Gardner GM:** Shoulder-muscle strength and range of motion following surgical repair of full-thickness rotator-cuff tears. *J Bone Joint Surg* 1986; 68A: 266-272.
2. **Walker SW, Couch WH, Boester GA, Sprowl DW:** Isokinetic strength after repair of a torn rotator cuff. *J Bone Joint Surg* 1987; 69A: 1041-1044.
3. **Rabin SI, Post M:** A comparative study of clinical muscle testing and cybex evaluation after shoulder operations. *Clin Orthop* 1990; 258: 147-156.
4. **Grana WA, Teague B, King M, Reeves RB:** An analysis of rotator cuff repair. *Am J Sports Med* 1990;22:585-8.
5. **Kirschenbaum AS, Coyle MP, Leddy JP, et al:** Shoulder strength with rotator cuff tears: Pre- and postoperative analysis. *Clin Orthop* 1993; 288, 174-178.
6. **Rokito AS, Zuckerman JD, Gallagher MA, Cuomo F:** Strength after surgical repair of the rotator cuff. *J Shoulder Elbow Surg* 1996; 5(1): 12-17.
7. **Rokito AS, Cuomo F, Gallagher MA, Zuckerman JD:** Long-term functional outcome following large and massive rotator cuff repair. *J Shoulder Elbow Surg* 1998; 7(3): 310-311.
8. **Romeo AA, Hang DW, Bach BR, Shott S:** Repair of full thickness rotator cuff tears: Gender, age, and other factors affecting outcome. *Clin Orthop* 1999; 367: 243-255.
9. **Cofield RH, Parvizi J, Hoffmeyer PJ, et al:** Surgical repairs of chronic rotator cuff tears. A prospective long-term study. *J Bone Joint Surg* 2001;83A:71-7.
10. **Yamaguchi K:** Mini-open rotator cuff repair. *J Bone Joint Surg* 2001; 83A: 764-771.
11. **Yamaguchi K, Levine WN, Marra G, Galatz LM, Klepps S, Flatow E:** Transitioning to arthroscopic rotator cuff repair: The pros and cons. *J Bone Joint Surg* 2003; 85A: 144-155.
12. **Shklar A, Dvir Z:** Isokinetic strength relationships in shoulder muscles. *Clin Biomech* 1995;10:369-73.
13. **Leroux J-L, Hebert P, Mouilleron, et al:** Postoperative shoulder rotators strength in stages II and III impingement syndrome. *Clin Orthop* 1995;320:46-54.
14. **Greenfield BH, Donatelli R, Wooden MJ, Wilkes J:** Isokinetic evaluation of shoulder rotational strength between the plane of scapula and the frontal plane. *Am J Sports Med* 1990;18:124-8.
15. **Kuhlman JR, Iannotti JP, Kelly MJ, et al:** Isokinetic and isometric measurement of strength of external rotation and abduction of the shoulder. *J Bone Joint Surg* 1992;74A:1320-33.
16. **Ivey FM, Calhoun JH, Rusche K, Bierschenk J:** Isokinetic testing of shoulder strength: normal values. *Arch Phys Med Rehabil* 1985; 66: 384-386.
17. **Watson M:** Major ruptures of the rotator cuff. The results of surgical repair in 89 patients. *J Bone Joint Surg* 1985; 67B: 618-624.

ACL TEARS IN COLLEGIATE WRESTLERS: REPORT OF SIX CASES IN ONE SEASON

Andrew J. Lightfoot, B.S.; Todd McKinley, M.D.; Matthew Doyle, M.S. ATC; Annunziato Amendola, M.D.

ABSTRACT

Six NCAA Division I wrestlers at The University of Iowa tore an anterior cruciate ligament (ACL) during the 2002-03 season. In comparison, between the years of 1993 and 2002, only five wrestlers sustained the same injury. Retrospective review and video data analysis were performed. All six were injured while their knee was near terminal extension and in a vulnerable position. Eighty-three percent of all injuries occurred during takedowns. Five of the six wrestlers' mechanism of injury involved rotation and stress on the weight-bearing knee. Eighty-three percent sustained their injuries while their foot was firmly planted on the ground. Five of the injuries occurred in competition. Of the six wrestlers injured, four underwent immediate rehabilitation in hope of wrestling that same season. Three ultimately needed surgery and one continued to wrestle in the same season without having surgery. Of the five wrestlers who underwent surgical reconstruction of their ACL, each had bone-patellar-bone grafts.

INTRODUCTION

Wrestling continues to be popular, with the number of wrestlers at the collegiate level at over 6300 participants from 257 different schools.[1] In comparison to other major sports, wrestling has received little attention with respect to injury rate, and in particular, ACL injuries. In wrestling, injury rates are relatively high with overall per 1000 athlete-exposures averaging 27/1000 in competition, and 6/1000 in practice, depending on the study.[1-4] An athlete exposure occurs when one athlete is exposed to the risk of injury while participating in one competition or one practice. According to Jarret et al.,[1] who looked at injuries that occurred in NCAA sports over an 11-year period, wrestling finished second only to spring football for the highest rate of injury at 9.6 injuries per 1000 athlete-exposures.[1] Some studies suggest the chance of getting a severe injury in wrestling is high.[5]

Injuries to the knee tend to be severe in wrestling.[6] Over an 11-year period in NCAA wrestling, 65%of injuries requiring surgery involved the knee. In the same study, 21% of injuries leading to greater than one week absence from competition involved the knee.[1] In several longitudinal studies of collegiate wrestling teams, the knee is the most commonly injured body part.[1,3,5,7-12]

Although knee injuries appear to be very common in wrestling, ACL tears are not, comprising between 0% and 9.1% of all knee injuries.[1,3,11-13] Snook followed the University of Massachusetts' wrestling program over a five-year period of time and documented no ACL injuries.[11]

During a one-year period involving 14 different schools, Pasque et al.[3] documented 219 injuries, 38 of which involved the knee. Of the 38 recorded knee injuries, two were ACL tears.[3] Similarly, Wroble et al.[12] documented that of 136 injuries sustained by The University of Iowa wrestling team between 1976 and 1982, 64 involved the knee and three were ACL tears.

During the 2002-2003 wrestling season, six elite NCAA Division I wrestlers at The University of Iowa sustained ACL tears. The reasons for this rate of ACL tears in that one year are unclear. The purpose of this study is to report the injury, demographics, and management. Information from athletic trainers, team physicians and orthopaedic surgeons, and the student-athletes were reviewed to identify predisposing factors and implement preventive intervention strategies.

METHODS

Information was gathered from a questionnaire filled out by the head athletic trainer for wrestling, with help from the student-athletes, and from summary reports detailing each individual injury. Descriptive reports on injuries sustained by The University of Iowa wrestling

Department of Orthopaedics and Rehabilitation
University of Iowa Hospitals and Clinics
200 Hawkins Drive
Iowa City, IA 52242

Correspondence:
Annunziato Amendola, M.D.
Department of Orthopaedics and Rehabilitation
University of Iowa Hospitals and Clinics
200 Hawkins Drive
Iowa City, IA 52242
Phone: 319-356-4230
FAX: 319-353-6754
email: ned-amendola@uiowa.edu

team from 1993-2003 were obtained to assess overall incidence of ACL injuries in competitive collegiate athletes.

Two types of summary information from the athletic training staff were used for this review. The first was student-athlete specific. In these summaries the ACL injury was described in detail, including mechanism of injury, time of injury, and physical tests used to determine that the athlete tore his ACL. The second summary received from the athletic training staff described injuries that occurred on the wrestling team between 1993 and 2003. Injury frequencies were calculated, and time loss from practice and competition was also determined.

RESULTS

Clinical Data and Management

At The University of Iowa, the wrestling preseason starts when wrestlers begin intense practices in September, and lasts until the first competition in November. The regular season lasts from mid-November until early March. Finally, the post season runs until mid- to late March, and consists of two tournaments, the Big Ten championships and the NCAA championships.

Of the six wrestlers injured, two were heavyweights and four were middle-weights (149 lb, 157 lb, 165 lb, and 174 lb). One of the wrestlers was a freshman, one was a sophomore, three were juniors and one was a senior. Three of the six wrestlers were starters on the varsity team.

Four of the torn ACLs were in the right leg, and two were in the left leg. Two of the wrestlers had previous knee surgery prior to the ACL injury. One had undergone two surgeries: one for a chondral fracture, and another for plica excision. The other wrestler had a prepatellar bursa excision.

Five ACL injuries occurred during the regular season and one during the postseason. Five of the six wrestlers were injured in competition: one in the first period, three in the second period, and one in the third period. The only practice injury occurred in one wrestler during the final quarter. The mechanism of injury was similar for most of the athletes. Video recordings were available for four of the six wrestlers at the time of injury. Of the six wrestlers, five experienced external tibial rotation with coronal knee stress (either valgus or varus). Five of the six wrestlers had a foot planted firmly on the ground at the onset of injury.

Wrestler 1, while in the neutral position, believes he hyperextended his knee while countering a takedown. No film was taken of this match.

In the neutral position, wrestler 2 rotated his body while keeping his foot planted, externally rotating his tibia as his opponent fell on his knee applying a valgus force.

In the disadvantage position, wrestler 3 had his leg lifted while his knee was being flexed and a varus stress was applied. This is the only injury in practice. This wrestler is the only wrestler who did not have his foot planted at the onset of injury. There was also no film verification.

Standing in the advantage position, wrestler 4 tripped his opponent with his right leg and his weight-bearing left leg twisted and gave out.

In the neutral position, wrestler 5 was tripped during his match and suffered a knee injury on his weight-bearing right leg.

Wrestler 6 was in the neutral position and, while countering a takedown, he twisted his knee.

Five of the six injuries occurred during takedowns, and the other one occurred in the disadvantage position. Four of the six wrestlers performed rehabilitation to return to competitive wrestling during the same season. Only one wrestler continued to wrestle soon after the injury. Three wrestlers underwent extensive rehabilitation and were eventually able to return to competition that season. The remaining two wrestlers had no intention of returning to competition during the same season and opted to undergo surgical repair of their ACL shortly after the injury. The combined record for all the wrestlers before their injury was 47 wins and 20 losses. The combined record for the wrestlers that attempted to wrestle after the injury was 5 wins and 10 losses. Essentially, five of the six wrestlers opted for surgery. Wrestler 3 was the most successful with a 3-1 record. Wrestler 6 is the only one that opted not to undergo surgery, and continues to function and wrestle at this point with minimal complaints.

After their injury, all six of the wrestlers reported knee instability. All of the wrestlers had moderate swelling around their knee within 12-24 hours after the onset of injury. Upon examination, six of the athletes demonstrated a positive Lachman test, six showed a positive anterior drawer test, and two had a positive pivot-shift test. All six of the wrestlers' MRIs showed a complete proximal injury of their ACL. Furthermore, two of the athletes had other related knee injuries at the time of the ACL injury. Wrestler 4 had a complex tear in his meniscus, and Wrestler 5 had a bucket-handle tear in his meniscus. It should be noted that both of these wrestlers underwent rehabilitation and eventually wrestled during the same 2002-2003 season.

All five athletes who had surgery had arthroscopic bone-patellar-bone reconstructions. None of the wrestlers had any complications, and all are expected to return to wrestling. The rehabilitation staff directed a

physician-approved accelerated postoperative rehabilitation protocol.

University Athletic Injury Demographics

Over the academic year of 2002-03, there were a total of 27 documented injuries on The University of Iowa wrestling team that caused an athlete to miss one or more days of competition and/or practice. Of those injuries, 13 (48%) involved the knee. Six of the thirteen injuries were ACL tears, representing 22% of all of the injuries. Of the 1,354 total days lost to injury, 805 days, or 60%, were lost because of knee injuries. On average, the athletes missed 50 days per injury

Information gathered from 1993-2002 showed that over that ten-year period, there were a total of 94 knee injuries sustained by wrestlers. Overall, the athletes missed a total of 2,158 days, or roughly 23 days per knee injury. During that time period, there were five ACL tears (5.3% of all knee injuries).

DISCUSSION

Five of the athletes were injured during the regular season and one was injured during the post-season. This is similar to other reports. Jarret et al.[1] reported that most collegiate wrestling injuries occurred in preseason and regular season, not postseason. The average injury rate for each season was 10.1, 9.5 and 4.4 per 1000 athlete exposures. None of the six injuries in this report occurred in the preseason. This may reflect the intensive year-round maintenance of physical conditioning at The University of Iowa by Division I athletes compared to athletes in Division II or Division III competition, which were included in the study by Jarret.[1]

The majority of our in-season injuries occurred early in the regular season with four injuries being sustained within the first 30 days of competition. This is similar to the previous findings of Wroble et al.,[12] from our institution. They found that 37 out of 94 injuries in collegiate wrestlers occurred during the first month of season, whereas only ten injuries were noted during the last month of competition.[12] Even though these athletes are well conditioned, they may not be at their peak at the end of preseason. Early in the competitive season, the athlete may not yet be prepared for the added intensity and emotion associated with competition compared to practice. This may partially explain why these injuries occur during competition during the early part of the season.

Five of the athletes in our study were injured in competition and the other was injured during practice. This is similar to previous data showing that average injury rates per 1000 exposures for practice and competition for all collegiate wrestlers, was 5.5 and 24.8, respectively.[2,4] In our patients injured during competition, one was injured in the first period, three in the second, and one in the third. Others have failed to find a correlation between period of match and injury rate.[8,12,14] Pasque et al.[3] noted that 67% of injuries sustained during practice occurred during the second half of practice. They also found that 78% of injuries during competition were sustained in the second and third periods. Based on the available data, fatigue may mildly predispose competitive wrestlers to ACL injuries.

Three of the six wrestlers injured were in the upper one-third of the weight divisions (one at 174 lbs and two heavyweights). The other three wrestlers were all in the middle one-third of the weight divisions (one at 149 lbs, one at 157 lbs and one at 165 lbs). None were in the three lightest weight classes. Previous studies have not found any association between injury and weight class.[1,12-15] Wrestling deliberately matches the physical size of competitors, which may explain the lack of correlation between injury and weight class.

Five of the six wrestlers were injured during takedown scrambles, four were countering a takedown and the fifth was attempting a takedown. This compares to other studies documenting that at least 50% and as many as 68% of all wrestling injuries occur during takedowns.[1,3,5,8,12-13,15] Takedown scrambles are particularly hazardous to the knee,[8,12] and five of the six ACL injuries in this study occurred during takedowns. Our data reconfirm that takedowns are consistently one of the most dangerous acts involved in the sport of wrestling. Unlike wrestling down on the mat, takedowns likely involve greater inertial forces, thus placing the wrestler at increased risk.

Regardless of the wrestling position (neutral, advantage or disadvantage), each athletes' knee was in or near full extension at the time of injury, thus impairing the leverage of the hamstrings to resist forces applied to the knee by the quadriceps. In general, when the quadriceps muscle contracts, it creates an anterior tibial translation which is countered by the posterior tibial translation of the hamstring muscle contraction.[16] Between 15 and 60 degrees of flexion, the hamstring co-contraction is extremely important in reducing excessive forces exerted on the ACL.[17] As the knee moves closer to full extension, it becomes less effective at countering the quadriceps contraction, and is therefore less able to protect the ACL.[18]

All six of the injuries sustained by the wrestlers involved a knee in or near full extension, five of the six injuries involved a rotational knee injury and five of six wrestlers had the foot of their injured leg firmly planted on the ground at the time of injury. These precarious and dangerous positions stemmed from either poor

technique or from the wrestler being acted upon by his opponent.

To the best of our knowledge, no previous study has addressed the success of wrestlers returning to competition after an ACL injury. Four of our wrestlers in this study tried to return to competition in the same season, and only one of four compiled a winning record. This wrestler chose to have his ACL reconstructed after the season due to instability. Two of the other wrestlers chose to undergo surgery because of their lack of success wrestling with an ACL-deficient knee. The fourth wrestler has decided not to have reconstructive surgery and will attempt to wrestle and improve his stability and comfort through rehabilitation.

Retrospective analysis of six ACL tears sustained by collegiate wrestlers from one team suggests that wrestlers are at a greater risk for an ACL tear during competition compared to practice. Wrestling in the neutral position may be the greatest risk factor for sustaining an ACL tear. Wrestlers may be more prone to injury early in the competitive season. Coaches and athletic trainers should emphasize proper technical positioning while wrestling in the neutral position, avoiding positions with the knee near full extension. Our data suggest it is difficult to return to competitive wrestling with an ACL-deficient knee, even after extensive rehabilitation.

REFERENCES

1. **Jarret GJ, Orwin JF, Dick RW.** Injuries in collegiate wrestling. *Am J Sports Med* 1998; 26:674-80.
2. **Dick RW.** *2001-02 NCAA Sports Medicine Handbook*: National Collegiate Ahletic Association, 2001.
3. **Pasque CB, Hewett TE.** A prospective study of high school wrestling injuries. *Am J Sports Med* 2000; 28:509-15.
4. **Potts KA, Dick RW.** *2000-01 NCAA Sports Medicine Handbook*: National Collegiate Athletic Association, 2000.
5. **Requa R, Garrick JG.** Injuries in Interscholastic Wrestling. *Phys Sportsmed* 1981; 9:44-51.
6. **Lorish TR, Rizzo TD, Jr., Ilstrup DM, et al.** Injuries in adolescent and preadolescent boys at two large wrestling tournaments. *Am J Sports Med* 1992; 20:199-202.
7. **DeHaven KE, Lintner DM.** Athletic injuries: comparison by age, sport, and gender. *Am J Sports Med* 1986; 14:218-24.
8. **Estwanik JJ, Bergfeld J, Collins HR, et al.** Injuries in Interscholastic Wrestling. *Phys Sportsmed* 1980; 8:111-21.
9. **Garrick JG, Requa R.** Medical Care and Injury Surveillance in the High School Setting. *Phys Sportsmed* 1981; 9:115-20.
10. **Jackson DS, Furman WK, Berson BL.** Patterns of injuries in college athletes: a retrospective study of injuries sustained in intercollegiate athletics in two colleges over a two-year period. *Mt Sinai J Med* 1980; 47:423-6.
11. **Snook GA.** Injuries in intercollegiate wrestling. A 5-year study. *Am J Sports Med* 1982; 10:142-4.
12. **Wroble RR, Mysnyk MC, Foster DT, et al.** Patterns of knee injuries in wrestling: a six year study. *Am J Sports Med* 1986; 14:55-66.
13. **Estwanik JJ, Bergfeld J, Canty T.** Report of injuries sustained during the United States Olympic wrestling trials. *Am J Sports Med* 1978;6:335-40.
14. **Kersey RD, Rowan L.** Injury account during the 1980 NCAA wrestling championships. *Am J Sports Med* 1983; 11:147-51.
15. **Strauss RH, Lanese RR.** Injuries among wrestlers in school and college tournaments. *Jama* 1982; 248:2016-9.
16. **Cowling EJ, Steele JR.** The effect of upper-limb motion on lower-limb muscle synchrony. Implications for anterior cruciate ligament injury. *J Bone Joint Surg Am* 2001; 83-A:35-41.
17. **Li G, Sakane KM, Ma CB, et al.** The importance of quadriceps and hamstring muscle loading on knee kinematics and in-situ forces in the ACL. *J Biomech* 1999; 32:395-400.
18. **Pandy MG, Shelburne KB.** Dependence of cruciate-ligament loading on muscle forces and external load. *J Biomech* 1997; 30:1015-24.

DIRECT ARTHROSCOPIC DISTAL CLAVICLE RESECTION: A TECHNICAL REVIEW

Gregory N. Lervick, M.D.

ABSTRACT

Degenerative change involving the acromioclavicular (AC) is frequently seen as part of a normal aging process. Occasionally, this results in a painful clinical condition. Although AC joint symptoms commonly occur in conjunction with other shoulder pathology, they may occur in isolation. Treatment of isolated AC joint osteoarthritis is initially non-surgical. When such treatment fails to provide lasting relief, surgical treatment is warranted. Direct (superior) arthroscopic resection of the distal (lateral) end of the clavicle is a successful method of treating the condition, as well as other isolated conditions of the AC joint. The following article reviews appropriate patient evaluation, surgical indications and technique.

INTRODUCTION

Symptomatic osteoarthritis (OA) of the AC joint can be treated effectively with both non-surgical and surgical means. Historically, patients that have failed non-operative management have been treated with resection of the distal clavicle, typically through an open superior incision.[14,19,31,33] With the acceptance of the arthroscopic treatment of shoulder pathology, many surgeons now prefer arthroscopic resection of the distal clavicle. Technically, arthroscopic resection of the distal clavicle is feasible either from a direct (superior) approach, in which the instrumentation and dissection remains entirely intra-articular, or from a bursal approach, which is usually performed concomitantly with acromioplasty, subacromial bursectomy, and/or rotator cuff repair. Occasionally, AC joint arthrosis occurs in isolation; in these situations, it may be preferred to avoid trauma to the subacromial region, thereby minimizing postoperative inflammation and scarring, and potentially reducing recovery time. The following review article discusses appropriate patient selection, technique, and expected results when performing a direct arthroscopic distal clavicle resection.

Correspondence:
Gregory N. Lervick, M.D.
Minnesota Sports Medicine
Orthopaedic Consultants, PA
775 Prairie Center Dr.
Suite 250Eden Prairie, MN 55344
greglervick@ocpamn.com

ANATOMY

The AC joint is a diarthrodial joint formed by the medial facet of the acromion and the lateral, or distal, end of the clavicle, both of which are covered with hyaline cartilage. The joint has a variable degree of inclination in both sagittal and coronal planes. There is an intra-articular fibrocartilaginous disk of variable size and shape; a complete disk is noted in less than 10% of the population.[4,15] Developmentally, there is no physeal plate at the distal clavicle. The articular cartilage of the distal clavicle may function in the longitudinal growth of the clavicle.[12]

Stabilityof the AC joint is primarily provided by the capsular ligaments that are located anterior, posterior, superior, and inferior.[15,20,21] The superior AC ligament is the strongest and blends with the fascial attachments of the deltoid and trapezius muscles. The capsular ligaments provide anteroposterior (horizontal) stability of the distal clavicle.[7,22,30] Slight upward and downward movement between the clavicle and acromion results in approximately 20 degrees of rotational movement between the two structures; however, this is likely variable on an individual level.[12] The capsular insertion is approximately 1.5 cm medial from the end of the distal clavicle; therefore, resections of greater than 2 cm can compromise horizontal stability. The vertical stability of the distal clavicle is provided by the coracoclavicular (CC) ligaments, which are injured in moderate to high grade (i.e. II-V) AC joint separations.

NATURAL HISTORY

It is well documented that the fibrocartilaginous disk of the AC joint deteriorates with age. This natural aging process begins in the second decade of life.[4] Several studies have demonstrated such changes in cadaveric studies or radiographic or magnetic resonance imaging of asymptomatic patients.[9,17-18,23,25-28] Despite the abundant evidence that degenerative changes at the AC joint are common with aging, little is understood about the likelihood that such changes will eventually result in clinical symptoms.

In a study of 100 patients with osteoarthritis of other joints, there was a 70% incidence of AC joint tenderness.

Treatment was provided for 30 consecutive patients in the series with intra-articular corticosteroid injections with successful results.[32] The long-term efficacy of injection therapy for AC arthritis is unclear. While the previous study demonstrated success, others have found such injections provide only short-term relief, with a majority of patients ultimately requiring surgical treatment.[10]

EVALUATION

History

A detailed history is critical to making an accurate diagnosis of AC joint pathology. Pain is universally the chief complaint. The patient should be questioned to determine the onset, location, and character of pain. In addition, a history of prior trauma or surgery should be excluded. Finally, previous treatment, and the response to that treatment, should be known.

Pain associated with isolated AC joint arthrosis or synovitis is typically anterosuperior in location, in direct proximity to the joint itself. Not infrequently, the pain may radiate anterior, posterior, proximal, or distal, and may mimic pain experienced with other shoulder conditions, such as rotator cuff tears, subacromial or subcoracoid impingement, bicipital tendonitis, or labral or other intra-articular pathology. Most commonly, pain is described as a dull ache, but may be sharp or burning. Symptoms are usually activity related but may be present either at rest or during the night, and patients may experience symptoms when sleeping on the affected shoulder.

The patient should be asked about typical activities that produce symptoms. Using the affected arm across the body (in shoulder adduction) or behind the back (such as reaching a wallet or tucking in a shirt) may be particularly bothersome. As well, reaching with the arm elevated or overhead can produce pain, not unlike that associated with impingement pathology. The patient may also describe crepitation that localizes to the AC joint with certain maneuvers. However, such mechanical sensations can be difficult to localize and should be correlated during the physical examination.

Physical Examination

The examination begins with a thorough inspection of the entire shoulder girdle. Male patients should have the shirt removed, while female patients should be appropriately gowned to leave the shoulder girdle exposed. The resting posture of the shoulder is assessed, including the sternoclavicular (SC) joint, clavicle, AC joint, scapula, and surrounding musculature. Prior incisions should be documented, particularly in the region of the AC joint. Occasionally, the AC joint may demonstrate swelling, hypertrophic change, or resting deformity consistent with prior AC joint ligamentous injury.

Anatomic landmarks should be palpated for tenderness. This includes the SC joint, AC joint, acromion, proximal humerus, and periscapular region. Palpation tenderness at the AC joint is the hallmark of the condition. However, this should be compared to the unaffected side. As well, the patient may not have direct tenderness at the joint on examination, but should be asked whether the joint is the typical location of pain.

Next, shoulder range of motion is assessed. Movement in forward elevation, abduction, external rotation (both adducted and abducted) and internal rotation are documented. In patients with isolated AC joint pathology, there typically is no primary limitation to shoulder movement. As well, scapular control and scapulohumeral rhythm are evaluated to rule out underlying neurologic injuries or dysfunction. Additionally, strength and function of the rotator cuff, deltoid, trapezius and distal extremity are assessed.

Finally, specific tests to elicit isolated AC joint symptoms are performed. There are three tests which are utilized. First, the cross-body adduction test is performed with the arm in 90˚ elevation and maximal adduction across the body. The maneuver increases contact pressure at the AC joint and often reproduces symptoms. Second, the active compression test is performed with the arm in 90˚ elevation and 10-15˚ adduction, with the arm in maximal internal rotation with the thumb pointed down. Likewise, this maneuver loads the AC joint and often reproduces pain. It must be determined the pain is located mainly at the AC joint, as this test is also used to demonstrate superior labral pathology.[16] Finally, pain reproduced at the AC joint with the arm in maximal internal rotation is a common finding, and may be the most sensitive test. Ranging the shoulder through full circumduction may also reproduce pain and crepitation at the AC joint.

Imaging

A standard radiographic series is obtained on all patients with a chief complaint of shoulder pain. In general, a series of four views are recommended that will evaluate for most degenerative and inflammatory conditions of the shoulder. Typically, true anteroposterior (AP) views of the glenohumeral joint with the humerus in both internal and external rotation, supraspinatus outlet, and axillary radiographs are obtained. In addition, when the clinician desires a specific evaluation of the AC joint, a Zanca radiograph is preferred, which is

taken in the AP plane of the joint with a 10 degree cephalic tilt.[34] This view is also particularly helpful in the postoperative evaluation of a distal clavicle resection.

Further imaging is often performed prior to considering surgical treatment. Magnetic resonance imaging (MRI) is preferred due to its ability to evaluate both bone and soft tissue. MRI of the shoulder allows detailed visualization of the rotator cuff, subacromial and subdeltoid bursae, acromion, greater tuberosity, coracoid process, subcoracoid interval, and medial clavicle. Intra-articular contrast may be used when further detail of the glenohumeral chondral surfaces or glenoid labrum is desired. It is important to include T2 weighted sequences that will demonstrate edema of the distal clavicle and medial acromion. Such findings are more suggestive of symptomatic AC joint arthrosis than are hypertrophic changes (i.e., osteophyte formation) alone.[25] In addition, MRI allows evaluation of the coracoclavicular (CC) ligaments in situations where the patient has AC joint symptoms following a prior type I or II AC separation. Such an evaluation may be helpful in determining treatment in these instances. It is recommended that patients with prior AC joint injuries, even in the remote past, be thoroughly examined for residual distal clavicular instability. Caution should be exercised in selecting such patients for the procedure, as it has been demonstrated that such patients are at higher risk for postoperative failure.[2,6]

NONSURGICAL TREATMENT

Nonsurgical modalities include medical management with nonsteroidal anti-inflammatories (NSAIDs) and analgesics, local modalities such as moist heat, ice, or ultrasound, and physical rehabilitation to correct underlying rotator cuff or intra-articular pathology, or periscapular dysfunction. When associated conditions have been either ruled out or corrected, the ideal form of treatment of isolated AC joint arthrosis or synovitis is an intra-articular corticosteroid injection. When symptoms have persisted beyond 6 months despite transiently effective injections, surgical treatment of the problem is reasonable.

SURGICAL INDICATIONS

The indication for surgical treatment of AC joint arthrosis is the failure of nonsurgical management to return the patient to the desired level of daily work and recreational functioning. With regard to isolated treatment of the AC joint (i.e., with open or arthroscopic resection of the distal clavicle), it cannot be overemphasized that the key to an appropriate surgical indication is making an accurate preoperative diagnosis. This is again done with a specific and detailed history, physical examination, evaluation of pertinent radiographic and MRI images, and a documented clinical response to diagnostic and therapeutic injections.

TECHNIQUE

The author prefers patient positioning in the beach chair position; however, the procedure may be alternatively be performed in the lateral decubitus position. A regional interscalene block for shoulder surgery is utilized. Care is taken to position the head and neck in neutral, and all potential peripheral pressure areas are thoroughly padded. The patient is given appropriate preoperative antibiotics. The shoulder is draped sterile using a standard arthroscopic shoulder drape that provides excellent exposure and collects excess fluid during the procedure. Bony landmarks are then marked, which is critical to creating the precise portals necessary to perform the procedure. The scapular spine, coracoid process, acromion, and clavicle are all accurately drawn.

The standard portals for direct arthroscopic resection of the distal clavicle are typically 1.5 centimeters directly anterior and posterior to the AC joint itself. In larger patients with thicker subcutaneous tissue, the portals must be referenced further from the joint, such that the instruments will track beneath the skin for a distance, thus entering the joint at the appropriate location.

The joint initially is localized using two 22 gauge needles and a 10 cc syringe with normal saline. The needles are directed into the joint from anterior and posterior, and fluid injected to distend the joint. With appropriate placement, the anterior needle should allow outflow from the joint, suggesting accurate portal location. The skin is then incised in the desired locations with a #11 blade. The joint is initially inspected with a 2.7mm arthroscope (i.e., used for ankle or wrist arthroscopy) through the posterior portal. A needle is then utilized to create an anterior portal using an outside in technique. The portal is created with a #11 blade and widened at the level of the joint capsule with a blunt obturator. A 3.5 mm full radius resector is used to remove any inflammatory tissue or remaining meniscal remnants which may be present. A tissue ablation device (TurboVac 90, Arthrocare, USA) is used to subperiosteally expose the lateral end of the clavicle in its entirety from the level of the anterior capsule to the posterior capsule. As well, the bone must be exposed from inferior to superior, while keeping the respective capsular attachments intact. Maintaining the integrity of the capsular attachments minimizes the amount of bleeding and trauma into the subacromial space, thereby decreasing postoperative pain and shortening

the recovery period. As well, preserving the posterior and superior aspects of the capsule avoids creating iatrogenic distal clavicular horizontal instability. This is particularly important in the unusual situation where the procedure is being performed following a previous type I or II AC separation (see previous text).

Once the lateral clavicle is exposed and any impinging soft tissue removed, the surgeon may switch to visualization with a standard 4.0 mm arthroscope, if the patient's anatomy allows. Resection of the distal clavicle is then performed with a 6.5 mm oval bur, beginning anterior and working toward the posterior aspect of the joint. If the joint space is excessively narrow to begin with, resection may be started with a smaller bur (i.e. 3.5mm round), before progressing to the larger bur. Care is taken to create an even resection from superior to inferior; typically, 6-7 mm of bone is removed, which has been shown to be adequate to prevent bone to bone contact with rotation of the scapula.[30]

The arthroscope is then moved to the anterior AC joint portal, to allow complete visualization of the posterior aspect of the distal clavicle and posterior capsule. If necessary, the ablation device is used to further expose the posterior clavicle. The bur is then used through the posterior portal to complete an even resection of bone, and confirm adequate decompression of the posterior portion of the joint. This step is critical, as a common technical error is inadequate visualization and resection of the posterior clavicle when performing the procedure arthroscopically.

Finally, in situations where it is desirable to inspect the glenohumeral joint as part of the same procedure, this can be done through a standard posterior portal established in the soft spot just medial and inferior to the posterolateral corner of the acromion. The anterior AC joint portal may be used for outflow and instrumentation, or a more standard anterior glenohumeral portal can be established. Such an inspection may or may not be preferred, depending upon the index of suspicion of intra-articular pathology based on clinical exam or by imaging modalities.

The portals are closed with nylon suture and standard dressings applied. The patient is placed in a Cryocuff (Aircast, USA) for postoperative comfort and to minimize swelling, as well as protect the arm while the regional block remains effective. It is typically discontinued 3-4 days after surgery. The patient begins gentle postoperative therapy 3-5 days after surgery, performing active assisted range of motion exercises within their tolerance level. The level of therapy is progressed to full active motion and isometrics in the ensuing 7-10 days. Typically, the patient progresses to a strengthening protocol 3 to 4 weeks post surgery. Most patients can expect full recovery in 8 to 10 weeks post surgery.

Figure 1. Supraspinatus outlet view in patient one demonstrating a flat acromial morphology consistent with successful prior arthroscopic acromioplasty. Patient continued to complain of anterosuperior shoulder pain.

Postoperative radiographs, consisting of a Zanca and axillary lateral view, are obtained to confirm the clavicular resection has been adequate. Alternatively, these can be obtained immediately postoperatively or intraoperatively, depending on the confidence level of the surgeon. The author recommends the routine use of intra-operative fluoroscopy or plain radiography when the technique is being used for resection of distal clavicle nonunions or excision of ectopic bone. This avoids the unwanted complication of inadequate resection, which may lead to continued symptoms postoperatively.

RESULTS

The results of direct arthroscopic distal clavicle resection have been published previously. In a series of 29 patients with isolated AC joint arthrosis, 93% had excellent or good results at minimum 2 year follow up.[6] This is consistent with the extensive reported literature evaluating either open distal clavicle resection,[14,19,31,33] or arthroscopic resections performed using the more common bursal approach.[1,5,8,11,13,24,29] A higher incidence of failure has been demonstrated in patients with prior AC joint instability (i.e., previous type II AC separation).[2,6]

Figure 2A

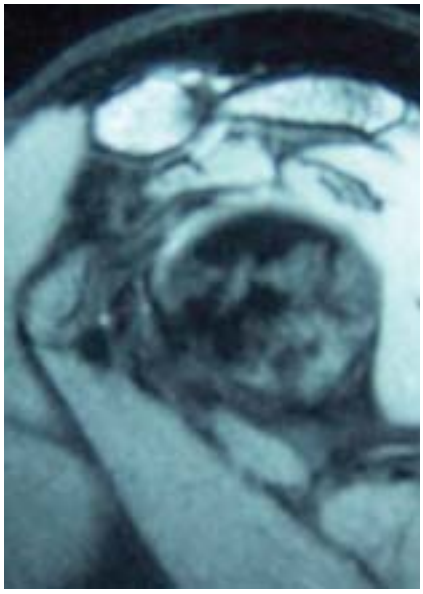

Figure 2B

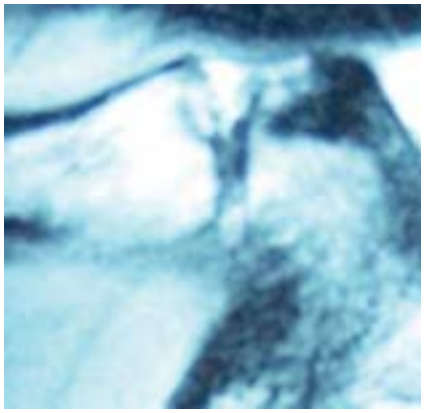

Figure 2C

Figure 2. T2-weighted coronal (A), sagittal (B), and axial (C) MRI sequences of patient one. Note the edema pattern of the distal clavicle and medial acromion, with subchondral cyst formation.

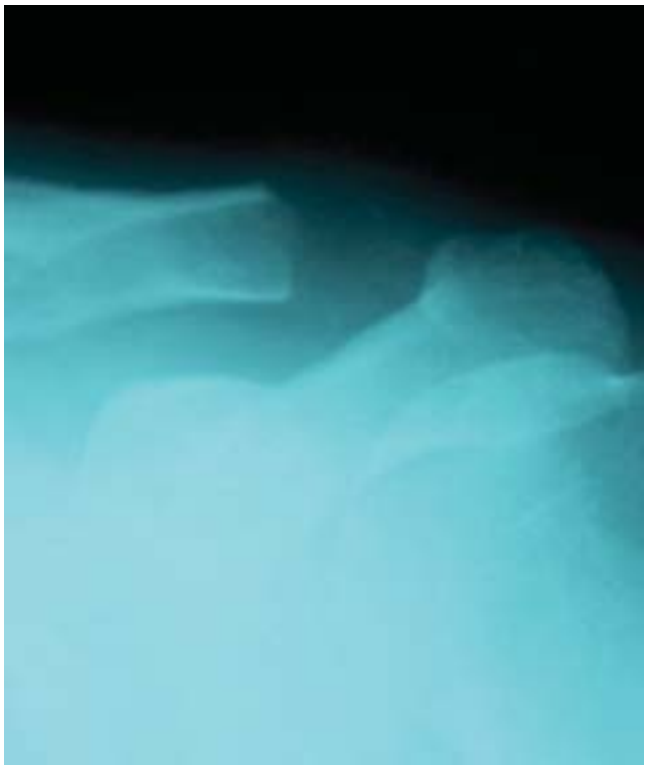

Figure 3. Postoperative Zanca radiograph of patient one after arthroscopic distal clavicle resection. Note the even resection of bone.

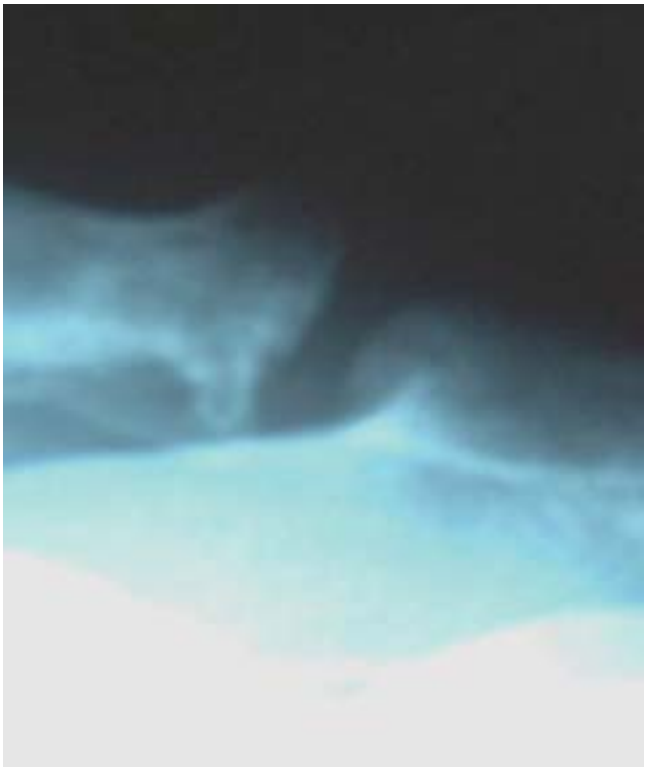

Figure 4. Preoperative AP radiograph of patient two demonstrating hypertrophic degenerative change of the AC joint.

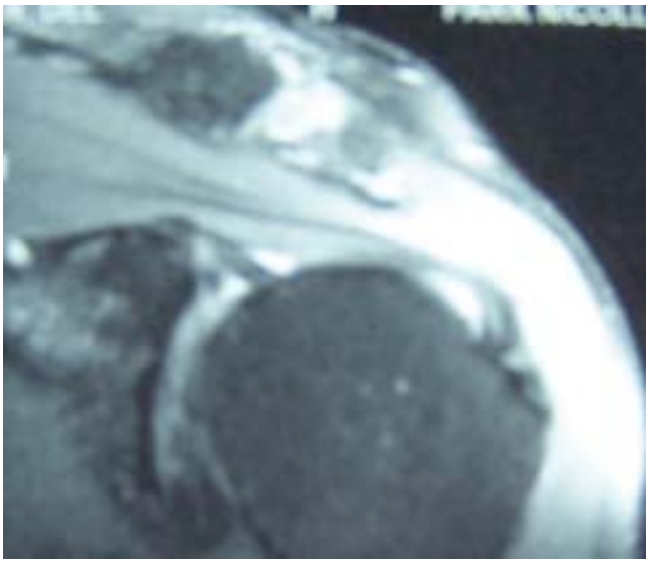

Figure 5. T2-weighted coronal MRI sequence of patient two demonstrating edema pattern of the medial acromion and fluid within the AC joint space.

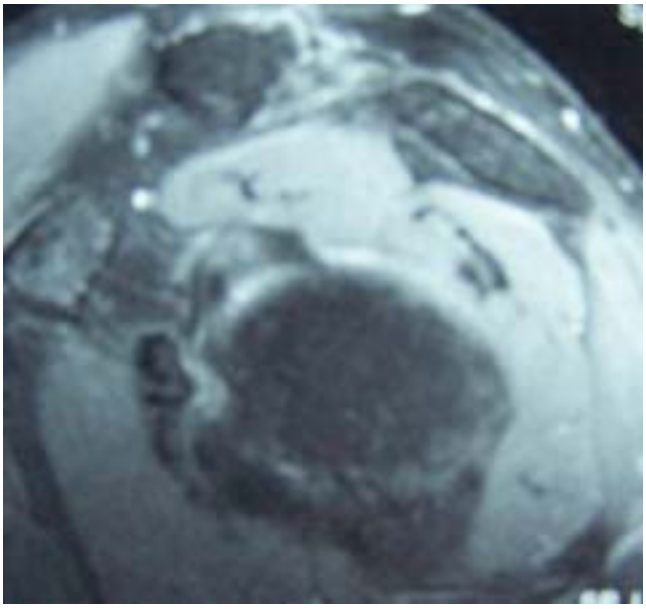

Figure 6. T2-weighted sagittal MRI sequence. Note the intact coracoclavicular ligaments. The patient had suffered a prior AC joint separation.

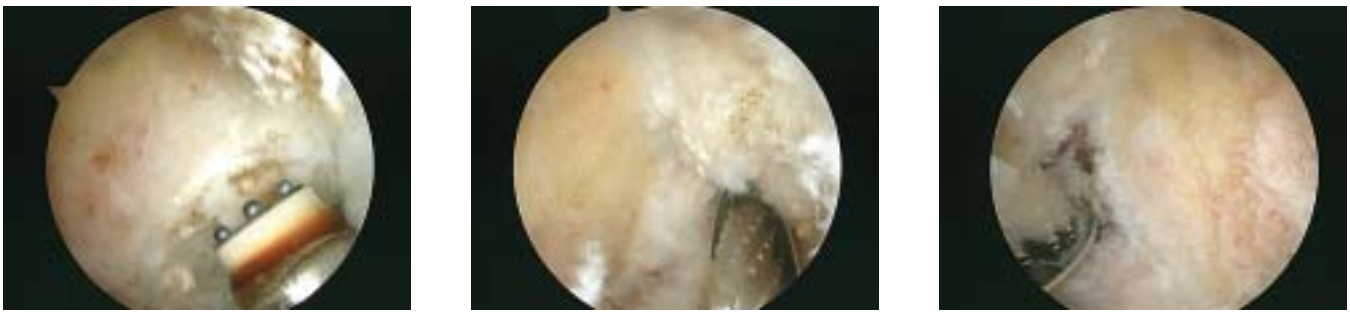

Figure 7. (A) A tissue ablation device is used to denude the distal end of the clavicle of residual soft tissue, in preparation for resection. The device is also used to maintain hemostasis. (B) View from anterior portal of the left AC joint. A 6.5mm bur is used to complete the posterior resection of the clavicle. (C) View from posterior of the completed left distal clavicle resection.

CASE EXAMPLES

Patient One

A 39-year-old female was referred for evaluation of persistent anterosuperior shoulder pain 6 months following prior arthroscopic subacromial decompression. The patient was active in racquet sports and bowling, and reported discomfort with rotational and overhead movements of the shoulder. In particular, overhead weighted presses, pushups, and reaching behind the back were inciting activities.

Physical examination demonstrated healed prior arthroscopic portals and no resting deformity of the shoulder. Range of motion was full in all planes, although maximal internal rotation behind the back produced pain specifically at the AC joint. Neer and Hawkins impingement signs were negative. Cross body adduction and active compression tests reproduced symptoms at the AC joint. No signs of generalized laxity or pathologic glenohumeral instability were evident.

Standard radiographs demonstrated prior acromioplasty and relatively minimal degenerative change of the AC joint (Figure 1). An MRI was obtained which revealed brightly enhancing edema pattern of the distal clavicle and medial acromion, with associated subchondral cystic change (Figures 2A-C). No rotator cuff, bicipital, or labral pathology was identified.

The patient underwent a diagnostic and therapeutic AC injection of 4cc 1% plain Lidocaine and 1cc of depomedrol, which demonstrated complete resolution of symptoms. Other nonsurgical treatment included scheduled NSAID use, modification of activity, and rotator cuff and periscapular strengthening. She experi-

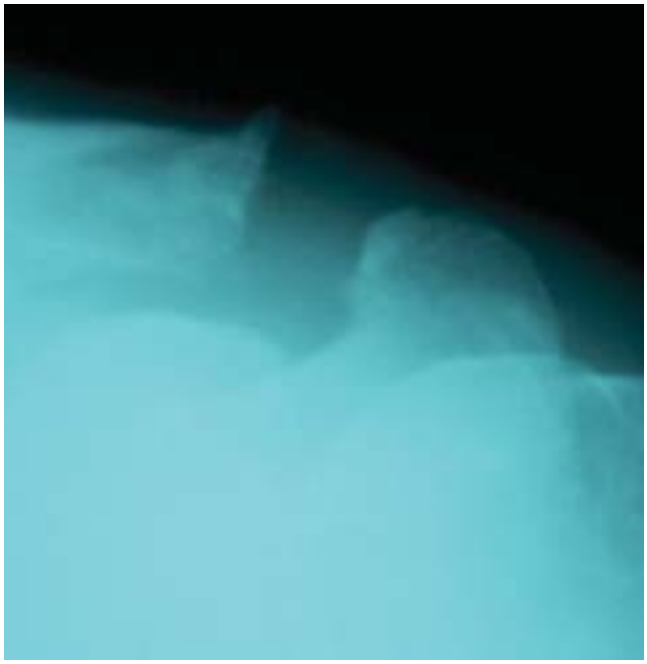

Figure 8. Postoperative Zanca radiograph of same patient demonstrating distal clavicle resection. Again, note even bone resection and avoidance of excessive bone removal, particularly in the setting of a prior AC joint injury.

enced lasting relief for roughly 5 to 6 weeks, with gradual return of pain. A subsequent injection produced similar results in terms of duration and clinical efficacy.

When her symptoms again recurred, the patient then elected to proceed with arthroscopic distal clavicle resection. Postoperative radiographs demonstrated adequate clavicular resection (Figure 3). The patient underwent standard postoperative protection and physiotherapy, and returned to full activity without restriction at 8 weeks following surgery. At 6 months, she continues to be pain free and pleased with the outcome.

Patient Two

A 61-year-old male presented with an 8 month history of left anterosuperior shoulder pain of gradual onset. He reported an AC joint separation suffered roughly 23 years prior that was treated nonsurgically without complication. He denied subjective instability to the distal clavicle with functional activities, which included weight training, swimming, hunting, and fishing. Once again, pain was particularly noted when reaching across the body or behind the back.

Physical examination demonstrated moderate hypertrophic change at the AC joint, but no superior translation of the distal clavicle relative to the acromion. There were no previous incisions. Range of motion and strength of the shoulder were symmetric to the contralateral side, and impingement signs were negative. There was no gross manual translational instability of the distal clavicle, although slight crepitation in this region was produced with circumduction of the shoulder. Positive tests included cross-body adduction and active compression, with pain located specifically at the AC joint.

Standard radiographs demonstrated maintenance of the AC joint space, but marked hypertrophic degenerative change (Figure 4). MRI demonstrated an effusion of the AC joint with a moderate edema pattern on T2 weighted sequences (Figure 5). The coracoclavicular ligaments were demonstrated and intact on sagittal oblique sequences (Figure 6). The remaining bone, cartilage, and rotator cuff were normal in appearance.

This patient likewise underwent a diagnostic and therapeutic AC injection of 4cc 1% plain Lidocaine and 1cc of depomedrol, which demonstrated complete resolution of symptoms. He experienced lasting relief for roughly 7 to 8 months, with gradual return of pain. A subsequent injection produced similar improvement for 2 months. He also elected to proceed with arthroscopic distal clavicle resection (Figure 7A-C).

Postoperative radiographs demonstrated adequate bone resection and no obvious translation of the clavicle relative to the acromion (Figure 8). He underwent a standard postoperative protocol and returned to swimming and other functional activities at 8 weeks following surgery. He remains pain free at one year following surgery, with no complaints of mechanical instability of the distal clavicle.

SUMMARY

Direct arthroscopic resection of the distal clavicle is an acceptable method of treating osteoarthrosis or synovitis of the AC joint that has failed to respond to a reasonable course of nonoperative treatment. Other AC joint disorders, such as distal clavicle osteolysis or nonunion of the distal clavicle, may also be treated with this technique. The procedure should only be performed when it is determined preoperatively that the AC joint is the isolated area of pathology. The only exception to this is the rare situation when it is preferred to diagnostically inspect the glenohumeral joint, but not perform extensive work either there, or in the subacromial or subcoracoid space. In comparison to other techniques, it allows precise resection of bone with minimal trauma to the surrounding soft tissue structures, which may decrease postoperative discomfort and shorten the recovery time. In addition, the procedure is quite pleasing from a cosmetic standpoint, and minimizes scar irritation from clothing or luggage straps that may occur with a larger superior incision.

REFERENCES

1. **Auge WK, Fisher RA.** Arthroscopic distal clavicle resection for isolated atraumatic osteolysis in weight lifters. *AJSM* 26:189-192, 1998.
2. **Bigliani LU, Nicholson GP, Flatow EL.** Arthroscopic resection of the distal clavicle. *Orth Clin N America* 24:133-141, 1993.
3. **Branch TP, Burdette HL, Shatiriari AS, et al.** The role of the acromioclavicular ligaments and the effect of distal clavicle excision. *AJSM* 24:293-297, 1996.
4. **DePalma AF.** The role of the disks of the sternoclavicular and the acromioclavicular joints. *CORR* 13:222-233, 1959.
5. **Flatow EL, Cordasco FA, Bigliani LU.** Arthroscopic resection of the outer end of the clavicle from a superior approach: A critical, quantitative radiographic assessment of bone removal. *Arthroscopy* 8:55-64, 1992.
6. **Flatow EL, Duralde XA, Nicholson GP, Pollock RG, Bigliani LU.** Arthroscopic resection of the distal clavicle with a superior approach. *J Shoulder Elbow Surg* 4:41-50, 1995.
7. **Fukuda K, Craig EV, An K, Cofield RH, Chao EYS.** Biomechanical study of the ligamentous system of the acromioclavicular joint. *JBJS* 68A:434-440, 1986.
8. **Gartsman GM.** Arthroscopic resection of the acromioclavicular joint. *AJSM* 21:71-77, 1993.
9. **Horvath F, Ke·ry L.** Degenerative deformations of the acromioclavicular joint in the elderly. *Arch Gerontol Geriatric* 3:259-265, 1984.
10. **Jacob AK, Sallay PI.** Therapeutic efficacy of corticosteroid injections in the acromioclavicular joint. *Biomed Sci Instrum* 34:380-385, 1997.
11. **Jerosch J, Steinbeck J, Schroder M, Castro WHM.** Arthroscopic resection of the acromioclavicular joint. *Sports Traum Arthroscopy* 1:209-215, 1993.
12. **Jobe CM, Coen MJ.** Gross anatomy of the shoulder. In *The Shoulder*, Rockwood et al, eds, 3rd edition, 2004.
13. **Kay SP, Ellman H, Harris E.** Arthroscopic distal clavicle excision. *CORR* 301:181-184, 1994.
14. **Mumford EB.** Acromioclavicular dislocation. *JBJS* 23: 799-802, 1941.
15. **Nuber FW, Bowen MK.** Disorders of the Acromioclavicular Joint: Pathophysiology, diagnosis, and management. In *Disorders of the Shoulder: Diagnosis and Management*, Iannotti and Williams, eds, 1999.
16. **O'Brien SJ, Pagnani MJ, Fealy S, McGlynn SR, Wilson JB.** The active compression test: A new and effective test for diagnosing labral tears and acromioclavicular joint abnormality. *AJSM* 26:610-613, 1998.
17. **Petersson CJ:** Degeneration of the acromioclavicular joint: A morphological study. *Acta Orth Scand* 54:434-438, 1983.
18. **Petersson CJ, Redlund-Johnell I.** Radiographic joint space in normal acromioclavicular joints. *Acta Orth Scan* 54:490-491, 1983.
19. **Petersson CJ.** Resection of the lateral end of the clavicle: a 3- to 30-year follow-up. *Acta Orth Scand* 54:904-907, 1983.
20. **Richards RR.** Acromioclavicular joint injuries. *Inst Course Lect* 42:259-269, 1993.
21. **Rockwood CA Jr., Williams GR Jr, Young DC.** Disorders of the Acromioclavicular Joint. In *The Shoulder*, Rockwood et al, eds, 3rd edition, 2004.
22. **Salter EG Jr, Nasca RJ, Shelley BS.** Anatomical observations on the acromioclavicular joint and supporting ligaments. *AJSM* 15:199-206, 1987.
23. **Schweitzer ME, Magbalon MJ, Frieman BG, et al.** Acromioclavicular joint fluid: Determination of clinical significance with MR imaging. *Radiology* 192:205-207, 1994.
24. **Snyder SJ, Banas MP, Karzel RP.** The arthroscopic Mumford procedure. *Arthroscopy* 11:157-164, 1995.
25. **Stein BE, Wiater JM, Pfaff HL, Bigliani LU, Levine WN.** Detection of acromioclavicular joint pathology in asymptomatic shoulders with magnetic resonance imaging. *J Shoulder Elbow Surg* 10:204-208, 2001.
26. **Stenlund B, Marions O, Engstrom KF, Goldie I.** Correlation of macroscopic osteoarthrotic changes and radiographic findings in the acromioclavicular joint. *Acta Radiol* 29:571-576, 1988.
27. **Stenlund B, Goldie I, Hagberg M, et al.** Radiographic osteoarthritis in the acromioclavicular joint resulting from manual work or exposure to vibration. *Br J Sports Med* 49:588-593, 1992.
28. **Stenlund B.** Shoulder tendonitis and osteoarthrosis of the acromioclavicular joint and their relation to sports. *Br J Sports Med* 27:125-130, 1993.
29. **Tolin BS, Snyder SJ.** Our technique for the arthroscopic Mumford procedure. *Orth Clinic N America* 24:143-151, 1993.
30. **Urist MR.** Complete dislocations of the acromioclavicular joint: The nature of the traumatic lesion and effective methods of treatment with analysis of 41 cases. *JBJS* 28:813-837, 1946.
31. **Wagner C.** Partial claviculectomy. *Am J Surg* 85:259-265, 1953.
32. **Waxman J:** Acromioclavicular disease in rheumatologic practice—the forgotten joint. *J La State Med Soc* 129:1-3, 1977.
33. **Worchester JN, Green DP.** Osteoarthritis of the acromioclavicular joint. *CORR* 58:69-73, 1968.
34. **Zanca P.** Shoulder pain: Involvement of the acromioclavicular joint: Analysis of 1000 cases. *Am J Roent* 112:493-506, 1971.

RARE BILATERAL FEMORAL SHAFT STRESS FRACTURES IN A FEMALE LONG-DISTANCE RUNNER: A CASE REPORT

Kirsten L. Weind, Ph.D.[1] and Annunziato Amendola, M.D.[2]

INTRODUCTION

Stress fractures are a frequent injury in the running population, commonly affecting the lower limb and foot. The tibia is reported to be the most common site, representing up to 64 percent of stress fractures, while the metatarsals represent 21 percent.[1] Femoral stress fractures are less common and can be divided into those involving the femoral neck, condyles or shaft. Those of the femoral shaft are reported to comprise between 2.8 and 21 percent of femoral stress fractures in athletes.[1,2,4,5] There is debate as to whether they are more prevalent in the female population.[2,6] Bilateral stress fractures have been reported in the tibia and metarsals,[1] but have only been reported twice in the femur—one associated with an endocrine disorder, and one associated with bilateral tibia fractures.[7,8]

There are several factors that put athletes at risk for stress fractures. These include inappropriate training with overuse. Other suspected causes include malalignment, nutritional deficiencies, and endocrine disorders.[1,3,5,6,9] Stress fractures in the female athlete also are associated with the female athletic triad, involving disordered eating patterns, amenorrhea, and low bone mineral density.[3,6]

Here, we report a case of bilateral femoral shaft stress fractures in a 15-year-old female long-distance runner. To date, there has only been one other report of bilateral femoral stress fractures in a medically healthy runner, but that occurred following bilateral tibial fractures.[7]

[1]Department of Medicine
The University of Melbourne
The Royal Melbourne Hospital
Royal Parade, Parkville
Victoria, Australia 3050
Phone: 613 8344 6252
Fax: 613 9347 1863

Correspondence:
Annunziato Amendola, M.D.
University of Iowa, Sports Medicine Center
Department of Orthopaedics and Rehabilitation
Iowa City, 52242, USA
Tel: 319-356-4230
Fax: 319-353-6754
ned-amendola@uiowa.edu

CASE REPORT

A 15-year-old female cross-country runner was seen in the sports medicine clinic complaining of bilateral thigh pain. The aching pain started following a training increase from 32 to 72 kilometres per week over a six week period. While at first the pain was only present with continued running, it soon occurred with walking, and was felt predominantly on impact. She continued running with two weeks of worsening pain and ultimately stopped running due to the pain.

Menstrual status was found to be normal and a healthy diet supplemented with additional calcium was being followed. There was no history of weight loss in the previous six months and anthropometric measurements established a BMI of 17.64. Physical exam of the lower extremities revealed no significant swelling or deformity. Thomas test and Ober's test were negative bilaterally. Bilateral lower limb motion, strength, sensation, flexibility, and tone were normal. Of significance, a unilateral leg hop reproduced the pain on each side with impact. A more directed physical exam of the proximal third of the left femur found it to be tender to palpation.

Bilateral long-leg lateral radiographs were normal with normal alignment. A technetium-99m bone scan of the both lower limbs revealed bilateral mid-femoral stress fractures localized to the posteromedial aspect on both sides, left worse than right (Figure 1).

Treatment initially involved low-impact conditioning using twice-daily pool workouts to maintain cardiovascular fitness. With a decrease in symptoms over one month, the intensity of her physiotherapy was increased to include cross-training with Nordic track, stationary bicycle, and aqua jogging, along with strengthening of both lower extremities using closed-chain activities. When she was free from pain, weight training with lunges was added. Following this, a 10-week gradual return to running program was instituted. This began with one minute of jogging followed by one minute of walking for a total of five minutes every other day over two weeks. Swimming therapy was continued on the other days for a total of five training days per week. This progressed to 10- and then 15-minute periods over the next four weeks. Finally the 15-minute regimen was performed for five days a week for two weeks, and increased to 20 minutes for the last two weeks of the pro-

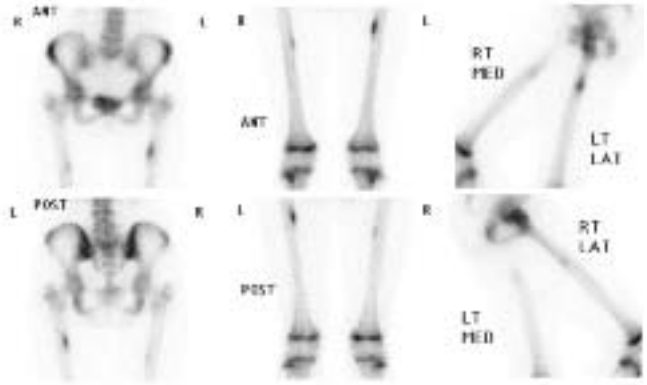

Figure 1. Anterior and posterior planar images and lateral views of the technicium-99m bone scan of the lower extremities. Increased tracer uptake in the posteromedial aspects of both femurs is consistent with femoral shaft stress fractures with findings on the left being worse than those on the right.

gram. After completing the 10-week return to activity program, she remained pain-free and returned to a normal running program.

DISCUSSION

This case illustrates some aspects of the clinical presentation of femoral stress fractures and the difficulties that may arise in their diagnosis and management. In addition, a practical rehabilitation regimen is outlined for the treatment of stable stress fractures.

A bone scan made the diagnosis that stress fractures occurred in both femurs, localized to both posteromedial shafts. This area of the femur has been shown to have the greatest strain in the sagittal plane, but is also susceptible to stress fracture due to the origin of the vastus medialis and the insertion of the adductor brevis.[2,9,10] The mechanism and etiology of stress fractures in general is debatable.[4,9] In cases of overuse and elevated bone stress, it is suspected that either muscle fatigue leads to a decrease in the ability to absorb shock, and/or highly concentrated forces act through small areas of tendinous insertion to overload bone. In the case of female athletes, there is controversy in the literature as to the role of the female athletic triad in increasing the risk of stress fractures due to decreased bone density and strength.[3,11] In our case, we describe an athlete who clinically does not fit the female athlete triad and who gives a history of bilateral thigh pain following a considerable increase in training intensity over a short period of time.

Successful rehabilitation protocols have been discussed in the literature.[4,9,12] In low-risk stable stress fractures,[13] a progressive loading regimen can usually be followed as directed by symptoms. A similar philosophy of low impact strength training and rest from running with a gradual return to activities was employed in our case. Reduced pain was used as a marker for improvement and progression of activity level. She did not at any time rest completely from all activities. We did not repeat a bone scan and would only have pursued further imaging if symptoms did not resolve or increased in intensity.

In conclusion, hip and thigh pain is a common complaint in runners. Femoral stress fracture should always be in the differential diagnosis. Bilateral femoral stress fractures are extremely uncommon, and in this case the etiology seemed to be overload of normal bone from significantly increased running mileage over a short interval. Femoral shaft stress fractures are stable stress fractures that can be treated with a progressive rehabilitation program as discussed here.

REFERENCES

1. **Matheson GO, Clement DB, McKensie DC, Taunton JE, Lloyd-Smith DR, MacIntyre JG:** Stress fractures in athletes. A study of 320 cases. *Am J Sports Med* 1987;15(1):46-58.
2. **Johnson AW, Weiss CB , Wheeler, DL:** Stress fractures of the femoral shaft in athletes – More common than expected. A new clinical test. *Am J Sports Med* 1994;22(2):248-256.
3. **Barrow GW, Saha S:** Menstrual irregularity and stress fractures in collegiate female distance runners. *Am J Sports Med* 1988;16(3):209-216.
4. **Monteleone GP:** Stress fractures in the athlete. *Orthop Clin North Am* 1995;26(3):423-432.
5. **Myburgh KH, Hutchins J, Fataar AB, Hough SF, Noakes, TD:** Low bone density is an etiologic factor for stress fractures in athletes. *Ann Intern Med* 1990;113:754-759.
6. **Callahan LR:** Stress fractures in women. *Clin Sports Med* 2000;19(2):303-314.
7. **Blatz DJ:** Bilateral femoral and tibial shaft stress fractures in a runner. *Am J Sports Med* 1981;9(5):322-325.
8. **Frelson M, Soyer J, Iborra JP, Hadjadj S, Pries P, Clarac JP:** An unusual cause of a stress femoral fracture in a long-distance runner: A case of bilateral fracture. *J Trauma* 2004;56(2):433-436.
9. **Boden BP, Speer KP:** Femoral stress fractures. *Clin Sports Med* 1997;16(2):307-317.
10. **O'Kane JW, Matsen LJ:** Mid-third femoral stress fracture with hip pain. *J Am Board Fam Pract* 2001;14(1):64-67.
11. **Bennell KL, Brukner PD:** Epidemiology and site specificity of stress fractures. *Clin Sports Med* 1997;16(2):179-196.

12. **Clement DB, Ammann W, Taunton JE, Lloyd-Smith R, Jesperson D, McKay H, Goldring J, Matheson GO:** Exercise-induced stress injuries to the femur. *Int J Sports Med* 1993;14:347-352.

13. **Kaeding CC, Spindler KP, Amendola A:** Management of troublesome stress fractures. *AAOS Instructional Course Lectures* 2004;53:455-469.

PATELLOFEMORAL REALIGNMENT: DYNAMIC INTRAOPERATIVE ASSESSMENT

Matthew Lavery, M.D.; John Bell, M.D.; *Theresa Rickelman, D.O.;
*Andre Boezaart, MBChB, FFA(CMSA), Ph.D; John P. Albright, M.D.

ABSTRACT

We describe a method of dynamic assessment of patellar tracking intraoperatively during a Fulkerson osteotomy. We utilize an electrically conductive catheter intraopertively to directly stimulate the femoral nerve to cause quadriceps muscle contraction. The resultant active knee extension allows dynamic assessment of patellofemoral tracking prior to and after final Fulkerson fixation. This dynamic intraopertive technique allows us to approximate *in vivo* patellofemoral motion better than with passive motion assessment.

INTRODUCTION

Symptomatic recurrent patellofemoral instability that does not respond to conservative measures is often relieved by surgical intervention. While there may be numerous underlying factors that lead to clinical patellofemoral dislocation and subluxation episodes, the most common is a malalignment of the quadriceps based extensor mechanism of the thigh. Because of the slight skeletal valgus that normally exists at the knee and the slightly lateral based attachment of the patellar tendon on the tibial tubercle, there is tendency for the normal patella to displace laterally. This tendency is balanced passively by the medial patellofemoral ligaments and by the buttress effect of the lateral femoral trochlea.[6] From a dynamic standpoint, it is the orientation of the distal vastus medialis portion of the quadriceps muscle that provides a medial restraint during patellar tracking. When instability episodes occur, there is a net resultant disequilibrium causing the patella to be pulled laterally out of the trochlear groove on the femur. The variety of combinations of anatomic factors contributing to patellofemoral instability necessitates that treatments are tailored specifically to the individual patient.

As a general rule, a medial transfer of the tibial tubercle with or without lateral retinacular release is the most commonly employed treatment for the unstable lateral tracking patella. Surgical procedures used include release of tight lateral structures, tightening or advancement of lax medial structures, transposition of the patellar tendon insertion, and, more rarely, derotational osteotomies and trochleoplasty. Although the senior author (J.P.A) has employed numerous techniques described for tibial tubercle osteotomy and transposition (e.g., the Hauser distal and medial transfer, the Elmslie–Trillat medialization, the Southwick sliding dovetail medialization),[2,4,5] we currently use the Fulkerson osteotomy,[3] which moves the tubercle into a more anterior and medial position.

Passive Intraoperative Assessment

Regardless of the technical aspects of the procedure, the intraoperative determination of the amount of medialization that is needed to produce a stable patella traditionally depends upon passive intraoperative methods of assessment. The surgeon's clinical judgment is relied upon to determine the distance that the patellar tendon attachment must be moved to allow the patella to track centrally in the femoral groove. A number of passive mechanical flexions of the knee are conducted during the operation and the tuberosity is moved a certain distance so that the surgeon is convinced that regardless of the position of the knee, the patella will remain stable within the trochlear groove.

First, with the leg in full extension, the patella is laterally displaced manually as passive knee flexion is initiated with the coupled forces of external rotation and valgus applied to the knee. Lateral subluxation is considered to be gross evidence of undercorrection. Conversely, over correction is assessed by displacing the patella medially with the knee extended, then flexing the knee and applying the opposite forces of varus and internal rotation. Gross medial displacement with this maneuver suggests overcorrection.

Unfortunately, regardless of the type of medialization procedure employed, over- and undercorrection must be avoided. It is felt that the intraoperative assessment of the appropriate amount of medialization of the tu-

From the Department of Orthopaedics and Rehabilitation and the *Department of Anesthesiology, University of Iowa Hospitals and Clinics. Iowa City, IA 52242.

Correspondence:
Matthew Lavery, MD
Department of Orthopaedics and Rehabilitation
University of Iowa Hospitals and Clinics
200 Hawkins Drive
Iowa City, IA 52242

Figure 1. Schematic of needle localization for placement of femoral nerve stimulator.

bercle remains a notable shortcoming because the anesthetized patient is unable to produce the complicated dynamic forces generated by the quadriceps.

Our technique reported here attempts to recreate those dynamic forces to allow an intraoperative assessment of approximate dynamic patellofemoral tracking. The concept that this was possible emanated from the popularization of the femoral nerve block anesthesia and the particular nerve stimulator technique employed to localize the nerve introduced by one of us (A.B.).

METHODOLOGY

Preoperative Technique

The patient has a "stimulating" femoral catheter placed in the supine position with the operative leg in the neutral position (neither externally nor internally rotated). The inguinal crease and femoral artery are identified and marked, and needle entry is one cm below the inguinal crease, and one cm lateral to the patient's femoral artery (Figure 1). Using sterile technique, local anesthetic is administered to the skin and subcutaneous tissue at the point of needle entry and the area of planned catheter tunneling. A nerve stimulator is attached to a 17-guage insulated Tuohy needle (StimuCath, Arrow International, Reading PA), and the needle is advanced in a postero-caudad direction at a 45-degree angle with the skin. The fascia lata and fascia iliaca are penetrated and a motor response is elicited of the quadriceps muscles. The current of the nerve stimulator is initially set to a current output of 1 mA, a frequency of 2 Hertz and a pulse width of 100–300 μs. Once a motor response is elicited, the stimulator is turned down and the needle position is adjusted until brisk twitches of the quadriceps muscles are still present at an output of 0.3–0.5 mA. The stimulating catheter (StimuCath, Arrow International, Reading PA) is threaded through the needle as it is held steady to maintain quadriceps stimulation. The catheter is threaded 5–10 cm past the needle tip and along the femoral nerve in a cephalad direction. Because the nerve stimulation is now *via* the stimulating catheter, the quadriceps twitches should remain unchanged throughout catheter advancement. It is possible to advance the catheter too far, under which circumstance the adductors of the thigh will twitch due to stimulation of the obturator nerve. The catheter would then be withdrawn slightly.

After placement, the catheter is tunneled subcutaneously for approximately 8–10 cm to secure position of the catheter during surgery. The same catheter can be used postoperatively to provide analgesia by way of a continuous femoral nerve block, though no local anesthetic agent is injected through the catheter until the operation is nearly complete.

The electrical nerve stimulator is now clipped to the catheter. After induction of general anesthesia or spinal anesthesia, but before surgery, the nerve stimulator is set to a frequency of 50 Hertz and the current is increased incrementally until the correct motor response in the quadriceps muscle is elicited. The motor response is less active if the nerve stimulator leads are changed from the usual, so the negative lead (the anode) is grounded on the patient and the positive lead (the cathode) is attached to the catheter. Careful testing and recording of the nerve stimulator settings are made, keeping in mind that a slightly higher current output would most likely be required after a tourniquet has been applied and after muscle fatigue following repeated muscle contractions.

Intraoperative Technique

Prior to the Fulkerson tibial tubercle medialization, a preliminary assessment of the dynamic tracking of the patella is made by femoral nerve stimulation. The intensity of the stimulus is refined to the point that a physiologic speed and force of quadriceps contraction

Figure 2. Patellar position just prior to quadriceps stimulation.

Figure 3. Quadriceps stimulated with central patellar tracking.

is approximated. Since it is common that the J-sign is the most obvious indicator of dynamic maltracking, the knee is then supported at 10-20∞ flexion in order to observe the extrinsically induced J-sign as the knee is actively extended by the femoral nerve activated quadriceps muscle contraction. Comparisons are made to the preoperative tracking characteristics of the patella.

After stimulation, a medial parapatellar arthrotomy is made through a medial parapatellar skin incision. The tibial tubercle is exposed and an osteotomy is made from superficial medial to deep lateral, allowing for an anterior and medial slide. A dovetail joint is cut proximally and a periosteal hinge is left distally. Passive assessments are made of patellofemoral tracking as described above. After the tubercle is appropriately positioned, it is provisionally fixed with K-wires. The knee is then supported at 10-20˚ flexion in order to observe the J-sign as the knee is again actively extended. At this point, the femoral nerve stimulator is utilized to attempt to recreate the forceful contraction of the quadriceps muscles (Figures 2 & 3). Slightly higher nerve stimulator output currents may be required at this stage to achieve the desired effect. The effect of the quadriceps muscle contraction at varying levels of force is then observed and the position of the tubercle altered accordingly.

DISCUSSION

We have found this technique useful. In one case, the information from the dynamic assessment resulted in us shifting the tubercle further laterally than we would have otherwise done, because we feared subsequent medial instability. In two other cases, the tubercle was shifted more medially because the force of the quad was insufficient to normalize the lateral maltracking.

Prior to the institution of this novel technique of dynamic assessment, we had two patients who developed medial patellar instability around one year post operatively. We feel this phenomenon may have been due to the fact that their quadriceps strength continued to improve after surgery and eventually the stronger VMO pulled the patella medially. It is uncertain that intraoperative femoral nerve stimulation would have changed the outcome, but it remains a possibility.

In terms of problems utilizing this technique, we have had one patient whose quadriceps contracted forcefully enough to dislodge the fixation intraoperatively. In this instance, the distal bone bridge had been inadvertently disrupted. Interestingly, the two screw, bi-cortical fixation was simply felt to have been inadequate to prevent this pullout. This does raise the concern that provisional or final fixation must be secure prior to a dynamic assessment of quadriceps function than it would otherwise need to be during passive assessment. Assurance against detachment of the transferred tibial tubercle is maximized by several maneuvers: 1) maintenance of a sturdy bone bridge distally; 2) creating a dovetail undercut of the proximal part of the osteotomy that locks the transferred tubercle under the proximal tibial cortex; 3) temporary fixation of the bone block with pins; 4) active counter pressure with the surgeons thumb, compressing the bone block in its bed and; 5) determining the most effective level of electrical stimulus to avoid the more violent muscle contractions.

We are encouraged that the use of intra-operative femoral nerve stimulation may help address some of the problems of passive assessment of patellofemoral tracking and improve the success rate of patellofemoral realignment procedures. A similar technique has previously been described for intraoperative stimulation of

the suprascapular nerve in rotator cuff repairs,[1] but to our knowledge, no such technique has been described for intraoperative femoral nerve stimulation. We believe that utilization of the described technique for dynamic patellofemoral assessment helps more accurately realign the extensor mechanism intraoperatively. Further prospective analysis will be required to assess its long-term benefit in the outcome of patellofemoral realignment procedures.

REFERENCES

1. **Boezaart AP, de Beer JF, van Rooyen K.** Rotator Cuff Tear: Intraoperative Electrical Stimulation of the Suprascapular Nerve. *Arthroscopy.* 2000;16(7).
2. **Cox JS.** An evaluation of the Elmslie-Trillat procedure for management of the patellar dislocations and subluxations. *Am J Sports Med.* 1976;4:72.
3. **Fulkerson JP.** Anteromedialization of the Tibial Tuberosity for Patellofemoral Malalignment. *Clin. Orthop.* 1983;177:176-181.
4. **Hauser ED.** Total tendon transplant for slipping patella. *Surg. Gnecol. Obstet.* 1938;66:199.
5. **Southwick WO, Becker GE, and Albright JA.** Dovetail patellar tendon transfer for recurrent dislocating patella. *JAMA.* 1968;204:665.
6. **Walsh MW.** Recurrent Dislocation of the Knee in the Adult. In DeLee JC, Drez D (eds): *Orthopaedic Sports Medicine,* 2nd ed. Philadelphia, Saunders, 2003: 1710-49.

TREATMENT OF ANTERIOR FEMOROACETABULAR IMPINGEMENT WITH COMBINED HIP ARTHROSCOPY AND LIMITED ANTERIOR DECOMPRESSION

John C. Clohisy, M.D. and J. Thomas McClure, M.D.

ABSTRACT

Anterior femoroacetabular impingement results from abnormal abutment of the anterolateral femoral head-neck junction with the anterior acetabular-labral complex resulting in pain and progressive hip dysfunction. This under-recognized problem could be the manifestation of acetabular or proximal femoral deformity, and when left untreated leads to the development of osteoarthritis of the hip. Conservative treatment is usually unsuccessful and the optimal surgical treatment for these disorders needs to be determined. We present our technique for treating femoral (cam) impingement which combines hip arthroscopy and a limited open anterior head-neck osteoplasty as a less invasive and more conservative surgical approach, which still adequately addresses the anatomy and pathophysiology of this disease.

INTRODUCTION

Impingement of the femoral neck on the anterior rim of the acetabulum (anterior femoroacetabular impingement) has been described in conjunction with malunited femoral neck fractures,[3] acetabular dysplasia,[12] acetabular retroversion,[32,33] and as a complication of periacetabular osteotomy.[25] Increasingly, it is being recognized as a cause of significant hip pain and disability and is strongly implicated as a cause of secondary osteoarthritis.[5,6,23] In 1999, Ganz and colleagues reported the development of a secondary impingement syndrome as a complication of periacetabular osteotomy.[25] The femoral head-neck junction abutted the anterior rim of the acetabulum leading to pain in five patients after repositioning of the dysplastic acetabulum. Most importantly, successful resolution of anterior impingement symptoms was noted after surgical treatment of the anterior impingement lesion.

Although anterior femoroacetabular impingement was initially described as a complication of surgery and noted to be secondary to several other deformities, it has recently and appropriately been recognized as a disease process unto itself and as a significant cause of hip pain in younger patients.[1,5,23,34,38] Femoroacetabular abutment is classified as either pincer or cam impingement.[5] Pincer-type impingement has been associated with acetabular retroversion,[32] protrusio acetabuli, and coxa profunda[33] due to the relative over-coverage by the anterior rim producing a linear contact between the rim and femoral neck.[5] Cam impingement is the result of decreased head-neck offset with a gradual aspherical contour from the femoral head to the neck anterolaterally with a relative retroversion of the femoral head.[10,34] This results in an increased radius of curvature anteriorly with a triangular shaped extension of bone and articular cartilage onto the femoral neck. This osteochondral lesion impacts the acetabular rim with flexion and internal rotation of the hip.[34] The suspected etiology of this lesion is abnormal physeal development [6,20,28] but it can also occur in slipped capital femoral epiphysis (SCFE),[15,30] Legg-Calve-Perthes disease, and malunited femoral neck fractures.[3]

Interestingly, the histopathological and morphological changes seen in the labrum and cartilage with both cam and pincer impingements are similar to and consistent with chronic degeneration without signs of acute inflammation[9] and an etiology of repetitive microtrauma. Impingement of the femoral head-neck prominence onto the acetabular rim initially leads to hypertrophy of the anterior-superior labrum with intrasubstance degeneration. Over time, delamination of the acetabular cartilage of the superior acetabular rim-labral junction occurs, and degenerative labral tears are produced anteriorly by repetitive compression and sheer forces. As the femoral head levers out of the acetabulum with flexion, a distraction force occurs on the posterior capsular-labral junction resulting in the development of a posterior counter-lesion with small tears noted in the posterior labrum. As severity of the disease progresses, the entire labrum becomes degenerative with further delamination of the acetabular articular cartilage and subsequent wear damage to the anterior portion of the

Department of Orthopedic Surgery
Barnes-Jewish Hospital / Washington University School of Medicine
St. Louis, Missouri

Correspondence:
John C. Clohisy, MD
660 South Euclid, Campus Box 8233
St. Louis, MO 63110
Telephone: 314-747-2566
FAX: 314-747-2599
jclohisy@msnotes.wustl.edu

Figure 1. Radiograph demonstrating severe arthrosis of the right hip secondary to untreated femoroacetabular impingement in a thirty-eight year old patient. Note the aspherical femoral heads bilaterally.

femoral head. The end result of this process is the development of global hip arthrosis (Figure 1).

Early surgical intervention has been proposed to avert the pathologic sequence of events starting with impingement and resulting in end-stage arthrosis. Specifically, Ganz and colleagues have recommended surgical dislocation of the hip to treat this disorder.[4] The purpose of this report is to describe an alternative, less-invasive surgical strategy for the treatment of early femoroacetabular impingent that combines hip arthroscopy and a limited osteoplasty of the anterior head-neck junction.

CLINICAL AND RADIOGRAPHIC EVALUATION OF ANTERIOR FEMOROACETABULAR IMPINGEMENT

History

Anterior femoroacetabular impingement usually presents in young athletic patients less than 50 years old and involved in activities that require repetitive hip flexion. These patients frequently complain of hip discomfort with sitting and hip flexion activities. The location of the discomfort is predominantly in the groin (anterior inguinal), but can be associated with buttock and lower lumbar discomfort. Anterior femoroacetabular impingement is consistently associated with anterior labral pathology. Therefore, patients may complain of mechanical symptoms (locking, catching, and giving way) indicative of labral tears or articular cartilage delamination lesions. Patients with more severe deformity may also complain of restricted hip motion, specifically limited hip flexion and limited internal rotation in flexion. When interviewing the patient, it is important to elicit any history of previous hip disease or hip surgery, especially SCFE. After characterization of the patient history and symptoms, a careful physical examination is critical.

Figure 2a

Figure 2. Case Example—A 21-year old collegiate wrestler with symptomatic anterior femoroacetabular impingement. AP (a) and frog-leg lateral (b) radiographs demonstrate an aspherical femoral head with deficient head-neck offset anterolaterally. Eighteen-month follow-up frog lateral.

Figure 2b

Figure 2c. MR arthrogram shows hypertrophic degenerative labral tear and aspherical femoral head.

Physical Examination

On physical examination, the patient's gait is either normal or slight limp will be present occasionally. A Trendelenburg test may be positive, especially if the disease is more established. Abductor strength is routinely assessed and commonly reveals slight weakness. Hip motion should be evaluated very carefully. A restriction of hip flexion and hip internal rotation is quite common. Many of these patients have hip flexion limited to 90-100 degrees (normally 120-130 degrees). Internal rotation in 90 degrees of flexion is quite restricted and is usually between 0 and 10 degrees. This restricted internal rotation in hip flexion is due to osseous impingement of the anterolateral femoral head-neck junction with the acetabulum.[27] The anterior impingement test is almost universally positive and should reproduce the symptom of groin pain.[18] Posterior impingement of the hip is assessed with the patient in a prone position. The hip is extended and externally rotated to produce posterior impingement of the head-neck junction with the posteroinferior rim of the acetabulum. Posterior impingement is more common as the disease progresses and a posteroinferior traction osteophyte develops which can produce clinical symptoms of posterior impingement in extension.

Radiographic Evaluation

Radiographic evaluation includes an AP pelvis, false-profile view, frog lateral view, and cross-table lateral view of the hip. The cartilage space of the hip is assessed and any structural abnormalities about the hip are noted. Specifically assess the acetabular version,[19] lateral femoral head coverage,[14] anterior femoral head coverage,[40] inclination of the acetabular articular surface,[39] and the contour and sphericity of the femoral head.[2,7,22,24] Specific attention is directed to the head-neck region. Fullness or a prominence of this region laterally on the AP view is indicative of anterolateral disease (Figure 2a). The frog lateral and cross-table lateral radiographs are used specifically to quantify the femoral head-neck offset along the anterolateral aspect of the head-neck junction (Figure 2b). [2,6,24] The head-neck offset is measured on the cross-table lateral radiograph using a method described by Eijer et al.[2] A line bisecting the longitudinal axis of the femoral neck is drawn; however, this is not necessarily through the center of the femoral head. A parallel line tangent to the anterior femoral neck and a second parallel line tangent to the anterior femoral head are then drawn. The perpendicular distance between these two lines is the measured head-neck offset, with a value less than nine millimeters being abnormal. The offset ratio is determined by the ratio of the head-neck offset distance relative to the diameter of the femoral head, with a value of less than 0.17 being abnormal.[2] In patients with subtle radiographic findings and questionable femoroacetabular impingement, a hip motion exam with fluoroscopy can determine the presence or absence of osseous impingement.

MRI arthrography can provide additional information regarding the integrity of the acetabular labrum, anatomy of the head-neck junction and the degree of acetabular cartilage deterioration (Figure 2c).[11,16,17,29]

Surgical Techniques

The basic principle of surgical treatment of anterior femoroacetabular impingement is to restore sphericity to the femoral head, thereby relieving the impingement, and to also address the pathologic changes in the labrum and articular cartilage. Treatment can be tailored to the specific pattern of the disease. In cases of cam anterior femoroacetabular impingement, the offending lesion is consistently located in the anterolateral aspect of the femoral head-neck junction.[27] This has led to the treatment approach we describe below which addresses this disorder with a less-invasive surgical approach.

The patient is positioned supine on a standard fracture table. We presently prefer general endotracheal anesthesia with muscle relaxation to aid in distraction

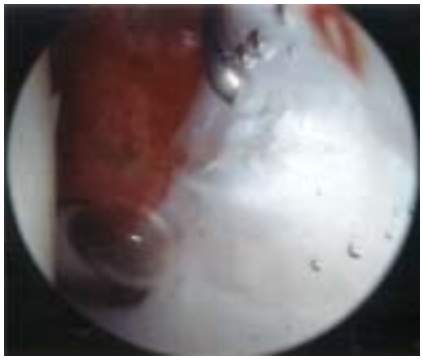

Figure 2d

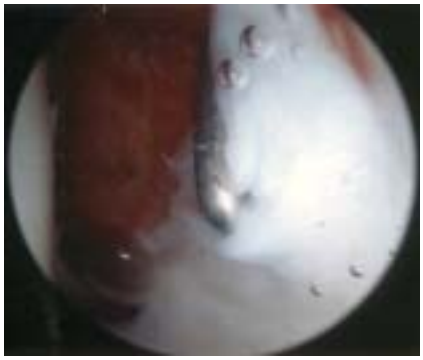

Figure 2e

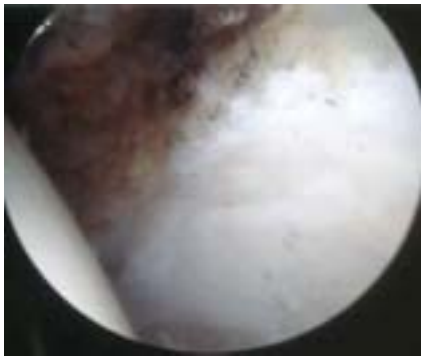

Figure 2f

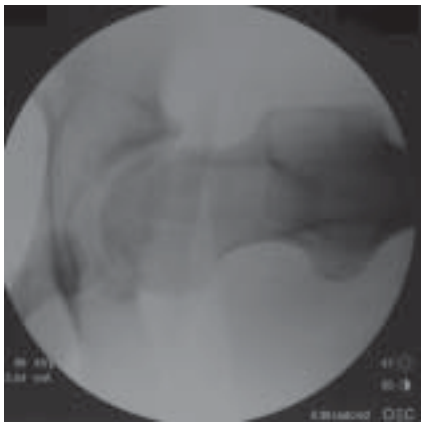

At arthroscopy, the patient had an anterior labral tear (d), and early articular cartilage delamination (e). These lesions were treated with arthroscopic debridement (f). Intraoperative fluoroscopic views demonstrating the aspherical femoral head (g) and restoration of head-neck offset (h) after anterolateral osteoplasty.

of the joint. The first stage of the operation is a hip arthroscopy to inspect the severity of disease and to address labral and articular cartilage lesions. We perform this with slight hip abduction (5˚) and slight internal rotation of the lower extremity (5˚). The hip is maintained in a neutral position of flexion and extension. The joint is distracted 8-10 mm with fracture table traction. We utilize the anterior, anterolateral and posterolateral portals. These are established with fluoroscopic assistance placing 5.0, 4.5 and 4.0 mm cannulated hip arthroscopy cannulas (Dyonics, Smith&Nephew, Andover, MA) in the respective portals. The joint is systematically evaluated with both a 70-degree and 30-degree angled arthroscope. The articular cartilage of the femoral head, the acetabulum and the acetabular labrum are inspected. In patients with anterior femoroacetabular impingement complex, degenerative tears of the anterior and anterolateral acetabular labrum are common (Figure 2d). These labral lesions are frequently associated with delamination of the adjacent articular cartilage at the transition zone (Figure 2e). In more severe cases, the labral and adjacent articular cartilage disease can extend along the entire anterior and lateral margin of the acetabulum. It is also common to find articular cartilage disease at the articular-labral transition zone posteroinferiorly. In early stages, these posterior changes are mild, and major unstable flaps of articular cartilage are uncommon. Labral disease posteriorly is commonly less extensive and less severe. After careful inspection of the joint, the unstable labrum and articular cartilage disease are treated with conservative debridement (Figure 2f). We employ the combination of a ligament chisel (Vulcan EAS, Oratec Interventions, Menlo Park, CA), full-radius shaver and an aggressive arthroscopic shaver (Linvatech, Largo, FL) to debride unstable flaps of acetabular labrum and associated articular cartilage flaps. Care is taken to resect only unstable regions of the labrum and articular cartilage. Further delamination of the articular margin is possible if aggressive resection is performed. After the anterior labral and chondral debridement is performed, we proceed with a conservative debridement of the posteroinferior acetabular labrum and associated articular cartilage if necessary. After arthroscopic debridement is completed, the joint is irrigated, instruments are removed, and traction is released.

After completion of the hip arthroscopy, the patient remains in the same position and open debridement is performed or the patient is repositioned for a limited, open anterior decompression of the hip. Prior to incision, fluoroscopy images are taken to insure excellent visualization of the proximal femur, specifically the femoral head-neck junction. This is best visualized with a cross-table lateral or a frog-leg lateral view (Figure 2g). Internal rotation in the frog lateral position can better define the anterolateral osteochondral prominence. An 8-10 cm incision is then made, starting just inferior to the anterior superior iliac spine and incorporating the previous anterior arthroscopy portal incision. Dissection is carried through the subcutaneous tissue laterally to dissect directly onto the fascia of the tensor fascia lata muscle. The fascia is incised, and the muscle belly is retracted laterally. The fascia is reflected medially. This medial sleeve of tissue contains the lateral femoral cutaneous nerve which should be protected by placing the fascial incision lateral to the tensor-sartorius interval. The interval between the tensor and sartorius is then developed. The rectus origin is identified, and the direct and reflected heads are released. The rectus is reflected distally and the adipose tissue and iliocapsularis muscle fibers are dissected off the anterior hip capsule. An "I"-shaped capsulotomy is then performed to provide adequate exposure of the anterolateral femoral head-neck junction. Most commonly, an outgrowth of osteochondral tissue is observed along the anterolateral head-neck junction. The offset from the femoral head to the neck in this region is deficient. The normal head-neck offset anteromedially serves as a reference point for resection of the abnormal osteochondral lesion. A half-inch curved osteotome is utilized to perform an osteoplasty at the head-neck junction. The osteotome is directed distally and posteriorly to perform a beveled resection to prevent delamination of the retained femoral head articular cartilage. After the osteoplasty is performed and the head-neck offset has been established anterolaterally, the accuracy of the surgical resection is confirmed with intra-operative fluoroscopy. The frog-leg lateral or cross-table lateral views in neutral and varying degrees of internal rotation are very effective for visualizing the anterolateral head-neck junction (Figure 2h). The hip can also be examined at this time to assess impingement in hip flexion and combined flexion and internal rotation. This is performed while palpating the anterior hip to test for residual impingement. If the anterior acetabular rim is overgrown secondary to labral calcification or osteophyte formation, this is carefully debrided until adequate clearance is achieved. Hip motion should improve at least 5-15 degrees in flexion and at least 5-20 degrees in internal rotation. The goal of the osteoplasty is to remove all prominent anterolateral osteochondral tissue that contributes to an aspherical shape of the femoral head. If sphericity has not been achieved, additional resection of the head-neck junction is performed. Bleeding from the surface of the osteoplasty is controlled with bone wax. The joint is irrigated and the longitudinal and superior transverse arms of the arthrotomy are closed with absorbable sutures. The direct and reflected heads of the rectus tendon are repaired with nonabsorbable suture and the remainder of the wound is closed in standard fashion.

Post-operative Care

Postoperatively, patients are observed overnight in the hospital. Physical therapy is instituted for toe-touch weight bearing with crutches to minimize the risk of femoral neck stress fracture. A pillow is used under the thigh to protect the rectus repair and active flexion is avoided for six weeks. Abductor strengthening is instituted immediately and continued with a home exercise program. Crutches are discontinued at six weeks and activities are resumed gradually as tolerated. Impact activities like running are not encouraged for at least six months. Aspirin 325mg is taken as thromboembolic prophylaxis and indomethacin 75mg sustained release is utilized for heterotophic ossification prophylaxis. Both are taken for six weeks.

DISCUSSION

The contour of the femoral head and neck radiographically has been noted to be a predictor of anterior femoroacetabular impingement.[27] The oval-shaped head, as seen on the AP radiograph, has been described as a pistol-grip deformity.[37] This anterolateral prominence, however, is best recognized on lateral radiographs.[2] The pistol-grip deformity has, over the years, been correlated with idiopathic osteoarthritis.[7] Subclinical slipped capital femoral epiphysis has been suggested as a possible cause of this deformity, and thus, of secondary osteoarthritis.[24,35,36,37] Other authors have disputed this suggestion and attribute the deformity to secondary remodeling of the proximal femur as a result of idiopathic osteoarthritis itself.[8,31] Goodman et al. noted that the post-slip morphology was present at a constant rate in multiple age groups, thus implying that the deformity was primary and not secondary to remodeling from osteoarthritis.[6] It was also suggested in the same study that the deformity might represent an anatomical variant in the shape of the adult femur instead of a consequence of unrecognized childhood disease. Moreover, it was hypothesized that this variant could result in contact between the femoral neck and acetabulum with flex-

ion and internal rotation, leading to the development of osteoarthritis. The contention that the deformity is an anatomic variant rather than the consequence of a subclinical SCFE is further supported by an MRI study showing that the orientation of the capital physeal scar remains in normal position in these patients.[34]

Surgical treatment of femoroacetabular impingement has been described by Ganz and colleagues,[5] who developed an approach that involves dislocation of the hip joint anteriorly with a trochanteric flip osteotomy.[4] This allows for access to the femoral head for debridement, and open debridement of the labrum and acetabular rim, and has been combined with femoral osteotomy, when needed, to address the various causes of femoroacetabular impingement.[1,3,5,13,23,25,38] This surgical approach was reported in 2001 by Ganz for the treatment of multiple hip pathologies and included 164 patients with anterior impingement.[4] Average blood loss was 300ml with an average of eight weeks until osteotomy healing, and four to six additional weeks to regain abductor strength. The overall incidence of heterotopic ossification was 37 percent and there were two transient sciatic nerve palsies. While there were no reported cases of avascular necrosis (AVN) in the initial description of the procedure, laser Doppler flowmetry showed transient changes in head perfusion during the procedure, which returned to baseline after reduction of the joint.[26] The dislocation also requires the rupture or division of the ligamentum teres with loss of its proprioceptive nerve fibers, the consequences of which are currently unknown. In a midterm report of 19 patients with average follow-up of 4.7 years, Beck et al. noted that there was significant improvement in the pain score and the overall Merle d'Aubigne hip score. Five hips were converted to total hip arthroplasty(THA), while the rest were rated with good or excellent results. There were no instances of AVN reported.[1]

Possible surgical treatment options for anterior femoroacetabular impingement include hip dislocation with trochanteric osteotomy, arthroscopy alone, or as we recommend, hip arthroscopy with limited anterior decompression. The inciting mechanical lesion in primary anterior femoroacetabular impingement is consistently located along the anterolateral head-neck junction.[27] In early and mid stages of the disease process, intraarticular pathology is limited to labral degeneration and tears associated with small articular cartilage lesions and delamination around the acetabular rim.[9] These lesions can be addressed appropriately with the arthroscopic portion of the procedure. Advanced chondral lesions have not responded well to open debridement, with a high incidence of progression and subsequent conversion to THA.[1,23] In their original reported

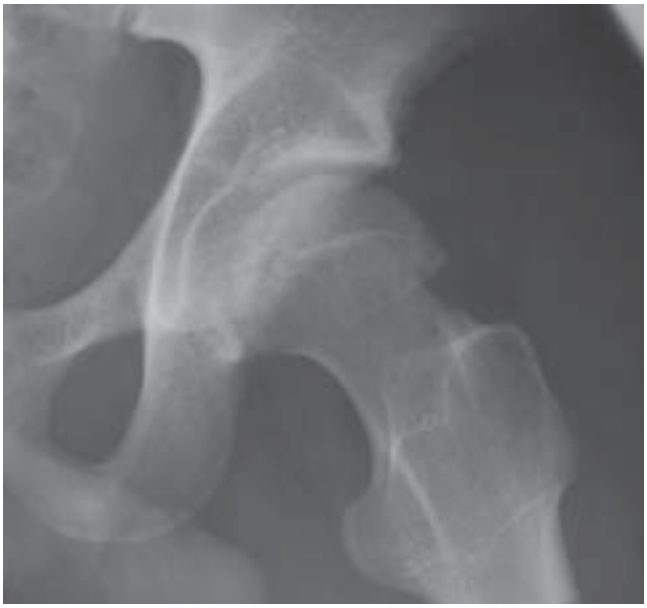

Figure 2i. Demonstrates maintained head-neck offset without progression of degenerative changes.

series of open debridements via hip dislocation, Ganz and colleagues made an intraoperative decision to perform primary THA on patients with advanced chondral lesions.[4]

While we admittedly have no experience with arthroscopic debridement of the bony impingement deformity, our experience with hip arthroscopy[11] has verified the efficacy of arthroscopy for labral pathology. Our current opinion is that debridement of the femoral head-neck junction arthroscopically has certain potential disadvantages including the potential for inadequate exposure of the anterolateral head-neck junction, the potential for bony debris to become entrapped in the joint, and the possibility of inadequate osseous debridement.

We have taken an intermediate approach to treating this disease, which combines the advantages of hip arthroscopy with an open osteoplasty of the femoral head-neck junction. The arthroscopy addresses the labral disease at the acetabular margin and any associated chondral damage. Additionally, posterior labral and articular cartilage disease is accessed and treated arthroscopically. The open osteoplasty is performed via a limited anterior approach through the Smith-Peterson interval. This allows excellent exposure of the anterolateral femoral head-neck junction and the anterior and lateral acetabular rims. This provides adequate exposure for osteoplasty of these anatomic sites. The exposure also allows visualization of the anteromedial head-neck junction, which is an excellent reference point for normal neck contour. This exposure combines the ad-

vantages of a less invasive surgery with a theoretical lower complication rate. Importantly, we do not advocate the use of this procedure for more advanced disease with posterior impingement lesions, or for hips that have circumferential lesions of the femoral head. In these cases, trochanteric osteotomy and surgical dislocation as described by Ganz et al. provides superior exposure to address more extensive disease patterns.[4]

This report presents our current surgical technique for primary cam femoroacetabular impingement and the disease pattern relevant to its development. In our initial cohort of patients treated with this procedure (Clohisy, unpublished data), we have been very satisfied with the rapid recovery and clinical results over the short term (Figure 2i). While our early results with this technique are promising, continued follow-up for mid-term and long-term results is essential to verify the efficacy of this technique.

REFERENCES

1. **Beck M, Luenig M, Parvizi J, et al.** Anterior femeroacetabular impingement: part II. Midterm results of surgical treatment. *Clin Orthop.* 2004;418:67-73.
2. **Eijer H, Leunig M, Mahomed MN, Ganz R.** Cross-table lateral radiograph for screening of anterior femoral head-neck offset in patients with femoro-acetabular impingement. Hip Int. 2001;11:37-41.
3. **Eijer H, Myers SR, Ganz R.** Anterior femoroacetabular impingement after femoral neck fractures. *J Orthop Trauma*. 2001;15:475-481.
4. **Ganz R, Gill TJ, Gautier E, et al.** Surgical dislocation of the adult hip: A technique with full access to the femoral head and acetabulum without the risk of avascular necrosis. *J Bone Joint Surg.* 2001;83B:1119-1124.
5. **Ganz R, Parvizi J, Beck M, et al.** Femoroacetabular impingement: A cause for osteoarthritis of the hip. *Clin Orthop.* 2003:417:112-120.
6. **Goodman DA, Feighan JE, Smith A, et al.** Subclinical slipped capital femoral epiphysis. *J Bone Joint Surg.* 1997;79A:1489-1497.
7. **Harris WH.** Etiology of osteoarthritis of the hip. *Clin Orthop.* 1986:213:20-33.
8. **Hoaglund FT, Steinbach LS.** Primary osteoarthritis of the hip: Etiology and epidemiology. *J Am Acad Orthop Surg.* 2001:9:320-327.
9. **Ito K, Leunig M, Ganz R.** Histopathologic features of the acetabular labrum in femoroacetabular impingement. *Clin Orthop.* 2004;429:262-271.
10. **Ito K, Minka II MA, Leunig M, Ganz R.** Femoroacetabular impingement and the cam effect. *J Bone Joint Surg.* 2001;83B:171-176.
11. **Keeney JA, Peele MW, Jackson J, et al.** Magnetic resonance arthrography verses arthroscopy in the evaluation of articular hip pathology. *Clin Orthop.* 2004;429;163-169.
12. **Klaue K, Durnin CW, Ganz R.** The acetabular rim syndrome: A clinical presentation of dysplasia of the hip. *J Bone Joint Surg.* 1991;73B:423-429.
13. **Lavigne M, Parvizi J, Beck, et al.** Anterior femoroacetabular impingement: Part I: Technique of joint preserving surgery. *Clin Orthop.* 2004;418:61-66.
14. **Lequesne M, deSeze S. Lefaux profil du bassin.** Nouvelle incidence radiographique pour l'tude de la hanche. Son utilite dans les dysplasies et les differentes coxopathies. *Rev Rhum Mal Osteoartic.* 1961;28:643-652.
15. **Leunig M, Cassilas MM, Hamlet M, et al.** Slipped capital femoral epiphysis: Early mechanical damage caused by the prominent femoral metaphysic. *Acta Orthop Scand.* 2000:71:370-375.
16. **Leunig M, Podeszwa D, Beck M, et al.** Magnetic resonance arthrography of labral disorders in hips with dysplasia and impingement. *Clin Orthop*. 2004;418:74-80.
17. **Leunig M, Werlen S, Ungersbock A, Ito K, Ganz R.** Evaluation of the acetabular labrum by MR arthrography. *J Bone Joint Surg.* 1997;79B:230-234.
18. **MacDonald SJ, Garbaz D, Ganz R.** Clinical evaluation of the symptomatic young adult hip. *Semin Arthroplasty.* 1997;8:3-9.
19. **Mast JW, Brunner RL, Zebrack J.** Recognizing acetabular version in the radiographic presentation of hip dysplasia. *Clin Orthop.* 2004;418:48-53.
20. **Meyer AW.** The "cervical fossa" of Allen. *Am J Phys Anthropol.* 1924;7:257-269.
21. **Morgan JD, Somerville EW.** Normal and abnormal growth at the upper end of the femur. *J Bone Joint Surg.* 1960;42B:264-272.
22. **Mose K.** Methods of measuring in Legg-Calve-Perthes disease with special regard to the prognosis. *Clin Orthop.* 1980;150:103-109.
23. **Murphy S, Tannast M, Kim YJ, et al.** Debridement of the adult hip for femoroacetabular impingement: Indications and preliminary clinical results. *Clin Orthop.* 2004;429:178-181.
24. **Murry RO.** The aetiology of primary osteoarthritis of the hip. *British J Radiol.* 1965;38:810-824.
25. **Myers SR,Eijer H, Ganz R.** Anterior femoro-acetabular impingement after periacetabular osteotomy. *Clin Orthop.* 1999;363:93-99.
26. **Notzli HP, Siebenrock KA, Hempfing A, et al.** Perfusion of the femoral head during surgical dislocation of the hip: Monitoring by laser Doppler flowmetry. *J Bone Joint Surg.* 2002;84B:300-304.

27. **Notzli HP, Wyss TF, Stoecklin MR, et al.** The contour of the femoral head-neck junction as a predictor for the risk of anterior impingement. *J Bone Joint Surg.* 2002;84B:556-560.
28. **Odgers PNB.** Two details about the neck of the femur: (1) the eminentia, (2) the empreinte. *J Anat.* 1931;65:352-362.
29. **Petersilge CA, Haque MA, Peterslige WJ, et al.** Acetabular labral tears: Evaluation with MR arthrography. *Radiology* 1996; 200:231-235.
30. **Rab GT.** The geometry of slipped capital femoral epiphysis: Implications for movement, impingement and corrective osteotomy. *J Pediatr Orthop.* 1965;19:419-424.
31. **Resnick D.** The "tilt deformity" of the femoral head in osteoarthritis of the hip: A poor indicator of previous epiphysiolysis. *Clin Radiol.* 1976;27:355-363.
32. **Reynolds D, Lucas J, Klaue K.** Retroversion of the acetabulum: A cause of hip pain. *J Bone Joint Surg.* 1999;81B;281-288.
33. **Seibenrock KA, Schoniger R, Ganz R.** Anterior femoroacetabular impingement due to acetabular retroversion: Treatment with periacetabular osteotomy. *J Bone Joint Surg.* 2003;85A:278-286.
34. **Seibenrock KA, Wahabm KH, Werlen S, et al.** Abnormal extension of the femoral head epiphysis as a cause of cam impingement. *Clin Orthop.* 2004:418:54-60.
35. **Solomon L.** Patterns of osteoarthritis of the hip. *J Bone Joint Surg.* 1976;52B:176-183.
36. **Stulberg SD, Harris WH.** Acetabular dysplasia and development of osteoarthritis of the hip. The Hip. Proceedings of the Second Open Scientific Meeting of The Hip Society, pp. 82-93. St. Louis, C.V. Mosby, 1974.
37. **Stulberg SD, Cordell LD, Harris WH, et al.** Unrecognized childhood hip disease: a major cause of idiopathic osteoarthritis of the hip. The Hip. Proceedings of the Third Open Scientific Meeting of the Hip society, pp. 2112-228. St. Louis, C. V. Mosby, 1975.
38. **Tanzer M, Noiseux N.** Osseous abnormalities and early osteoarthritis: The role of hip impingement. *Clin Orthop.* 2004;170-177.
39. **Tonnis D.** *Congenital dysplasia and dislocation of the hip in children and adults.* Telger TC, translator, pp.113-130,156-161. New York, Springer, 1987.
40. **Wieberg G.** Studies on dysplastic acetabula and congenital subluxation of the hip joint. *Acta Chir Scand.* 1939;83: Suppl. 58.

A REVIEW OF HIP ARTHROSCOPY AND ITS ROLE IN THE MANAGEMENT OF ADULT HIP PAIN

Christopher M. Larson, M.D.[1]; Jennifer Swaringen M.D.[1]; Grant Morrison M.D.[1]

INTRODUCTION

Intra-articular hip pathology has recently received increased attention in the literature. Hip arthroscopy was first introduced by Burman in 1931.[1] Acetabular labral tears were first described in 1957 and 1959, and were identified through an open approach after irreducible traumatic hip dislocations.[2,3] The first arthroscopic description of an acetabular labral tear was in 1986.[4] More recently hip arthroscopy has become a minimally invasive diagnostic and therapeutic tool. The indications for hip arthroscopy have expanded, and its usefulness continues to be better defined in the literature.

ANATOMY

The hip joint is a ball and socket joint consisting of the femoral head and acetabulum. This articulation provides multiple planes of movement and is highly congruent. Articular cartilage, consisting of type II collagen, covers the majority of the femoral head. The acetabulum peripherally consists of articular cartilage while the central floor is non-articular and filled with a fatty layer termed the pulvinar. The ligamentum teres arises from both the tranverse acetabular ligament and the central non-articular layer of the acetabulum and attaches to the central femoral head. It may play a role in stabilizing the hip joint.[5]

The acetabular labrum is a fibrocartilaginous structure that runs circumferentially around the periphery of the acetabulum (Figures 1 and 2). Inferiorly, the transverse acetabular ligament connects the anterior and posterior portions of the labrum. The labrum is attached to the acetabular articular cartilage via a thin transition zone of calcified cartilage layer on the articular side.[6] The non-articular side of the labrum is directly attached to bone.[6] Only the peripheral one-third or less of the labrum has a rich blood supply, and this is provided by branches from the obturator, superior gluteal and inferior gluteal arteries.[6,7] The central two-thirds of the labrum is avascular.[6,7] Pain fibers have been identified within the labrum and are most concentrated anteriorly and anterosuperiorly.[8] The labrum also appears to provide a stabilizing force for the hip joint by increasing the acetabular volume by 33% and helping to create a negative intra-articular pressure.[6,9]

Three major ligaments surround the hip joint capsule. The iliofemoral ligament of Bigelow lies anteriorly, and has an inverted Y-shape.[10,11] This ligament tightens with hip extension.[10] The inferior aspect of the iliofemoral ligament blends distally with the pubofemoral ligament, which covers the inferior and medial aspect of the hip joint capsule.[10,11] This ligament tightens with hip extension and abduction.[10] The ischiofemoral ligament lies posteriorly and its fibers spiral upward to blend with the zona orbicularis, a band that courses circumferentially around the femoral neck.[10,11] The ischiofemoral ligament also tightens with extension which explains why some degree of hip flexion increases capsular laxity and allows for better exposure during arthroscopic procedures.[10]

HISTORY AND PHYSICAL EXAMINATION FOR HIP DISORDERS

Determining the etiology of hip pain can be very elusive. Both extra-articular and intra-articular hip structures can give rise to pain, creating a challenge for many practitioners. The term “hip” is often not well defined and is used to identify the groin, lateral trochanteric region, lateral, medial or anterior thigh, as well as the posterior pelvis, buttock and lower back.

The history for patients with intra-articular hip pathology can range from an acute twisting or falling episode to the insidious onset of pain that increases over months to years. Athletes participating in sports that involve repetitive hyperextension and external rotation (soccer, skating, hockey, tennis, golf) seem to be at a higher risk for developing intra-articular hip disorders.[12] The typical pain referral pattern is anterior groin or medial thigh pain following an L3 dermatomal pattern. Patients will occasionally complain of lateral and posterior hip or pelvic pain. Byrd has described the classic “C” sign where the patient places their index finger over

[1] Minnesota Sports Medicine
Orthopaedic Consultants P.A.
Edina Sports Health and Wellness

Correspondence:
Christopher M. Larson M.D.
Director of Education: Minnesota Sports Medicine/
Orthopaedic Sports Medicine Fellowship Program
Orthopaedic Consultant P.A.
Prairie Center Drive, Eden Prairie, MN
clars@med.unc.edu

Figure 1. Normal Anterior Acetabular Labrum

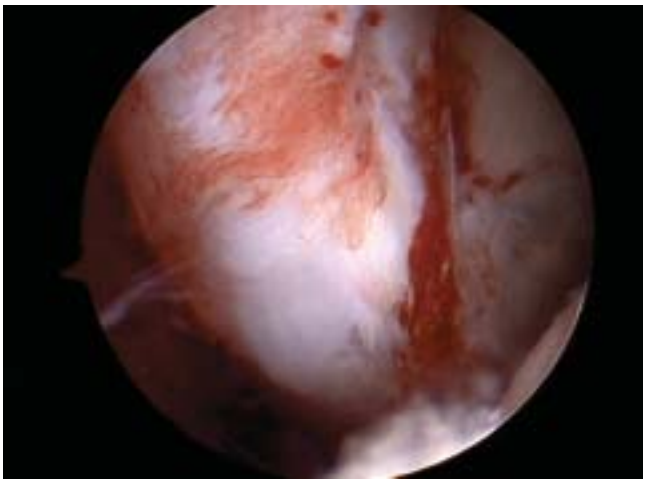

Figure 2. Normal Posterior Acetabular Labrum

the anterior aspect of the hip and thumb over the posterior trochanteric region to indicate the location of their pain.[13] Pain is typically worse with twisting activities and ascending or descending stairs or inclines.[14] Patients may also complain of painful catching in the hip, particularly when going from positions of flexion to extension such as with rising from a seated position.[14]

Physical examination begins with gait evaluation. Patients with intra-articular pathology may stand with the hip flexed and walk with an antalgic gait with a shortened stance phase and shortened stride length. Palpation typically does not elicit tenderness with an intra-articular lesion. Range of motion is next evaluated and includes a side-to-side evaluation of internal and external hip rotation, hip abduction and adduction, flexion, and presence of a hip flexion contracture as indicated by the Thomas test.[5]

Pain with supine log-rolling of the hip is the most specific test for intra-articular pathology.[13] A more sensitive measure of intra-articular pathology is recreation of pain with the impingement test, which involves forced flexion, adduction, internal rotation, and axial loading of the hip.[13,15] This may be present in patients with both anterolateral labral tears and femoroacetabular impingement.[13,15] Forced external rotation with an axial load and hip flexion can cause pain in patients with posterior labral pathology.[12] Pain may also be elicited with a resisted straight-leg raise. Moving the hip from full flexion, external rotation, and abduction to a position of extension, internal rotation and adduction can recreate pain and snapping in patients with anterolateral labral tears and iliopsoas snapping hip.[16] Any of the above provocative maneuvers can recreate mechanical symptoms in addition to pain, which can indicate labral, chondral or ligamentum teres pathology, loose bodies, or sometimes extra-articular pathology secondary to a snapping hip syndrome.

DIFFERENTIAL DIAGNOSIS

There are other diagnoses to consider in the evaluation of patients with any of the above symptoms and physical findings. In the young athlete, musculotendinous strain, bony avulsion, stress or traumatic fracture, slipped capital femoral epiphysis, Legg-Calve-Perthes disease, developmental dysplasia, synovitis and septic arthritis are possible diagnoses.[5,13] Pain can be referred from genitourinary, intra-abdominal, and abdominal wall structures.[5,13] Back pain, sacroiliac disorders, radiculopathies and sciatica can mimic some of the above findings.[5,13] The snapping hip can be related to the iliopsoas tendon snapping over the brim of the pelvis or the iliotibial band over the greater trochanter.[5,13] Many of these above diagnoses may be differentiated based on additional history or physical examination findings, but may require certain imaging studies.[5,13]

IMAGING

The first radiographic studies that should be obtained when evaluating patients presenting with hip pain are plain radiographs. Plain radiographs are useful to identify arthritic changes involving the hip joint, avascular necrosis, hip joint dysplasia, active and residua of Legg-Calve-Perthes disease, slipped capital femoral epiphysis, femoroacetabular impingement, ossified loose bodies and other pelvic and lower lumbar pathology. Practitioners evaluating these plain films should be familiar with techniques for identifying the above-mentioned disorders, which go beyond the scope of this article. Normal plain radiographs by no means rule out intra-articular pathology.

Magnetic resonance imaging (MRI) is the preferred radiographic method for diagnosing intra-articular hip joint pathology (Figure 3). Byrd has shown conventional MRI has high false negative rates (42 percent) but low

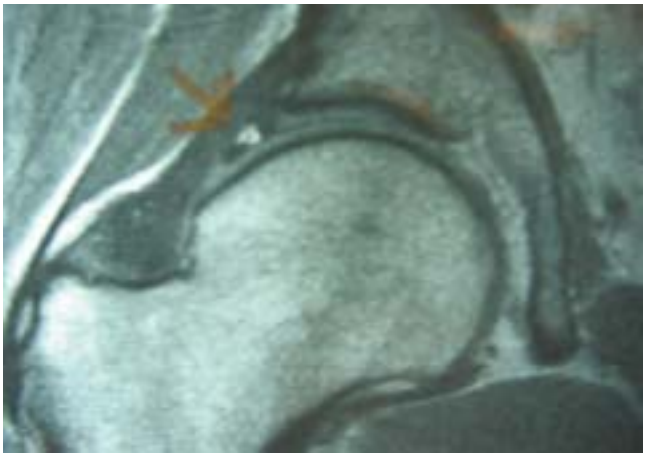

Figure 3. Anterosuperior Labral Tear

false positive rates (10 percent) when used to evaluate intra-articular hip pathology.[14] Indirect evidence of intra-articular pathology on conventional MRI includes the presence of an effusion, paralabral cysts, and subchondral cysts.[14,17,18,19,20] MRI arthrography is preferred over conventional MRI because of its greater than 90 percent sensitivity in diagnosing hip joint pathology.[14,17,18] Higher false positive results of up to 20 percent are noted with MRI arthrogram, however, when compared to conventional MRI.[14] Both MRI and MRI arthrography have been shown to have poor sensitivity and excellent specificity when evaluating cartilage lesions.[14] The use of MRI arthrography also allows for the addition of an intra-articular anesthetic injection, which we feel is the single most important diagnostic factor when evaluating candidates for hip arthroscopy. Byrd has found a positive response to this injection 90 percent accurate for detecting intra-articular pathology, consistent with our personal experience, also.[14] (C.M.L. unpublished data). It is imperative that patients can recreate their symptoms prior to the injection in order to evaluate whether or not symptoms are temporarily improved.

INDICATIONS FOR HIP ARTHROSCOPY

Hip arthroscopy is still in its infancy to some degree and longer-term outcomes and improved techniques should continue to better define the role for hip arthroscopy. Currently, common indications include symptomatic labral tears, loose bodies, ligamentum teres lesions, focal symptomatic chondral lesions and septic arthritis.[5,13]

The role for hip arthroscopy in the arthritic hip is being better defined and is following a pattern similar to that seen in the knee and other joints. The concept of femoroacetabular impingement is gaining popularity

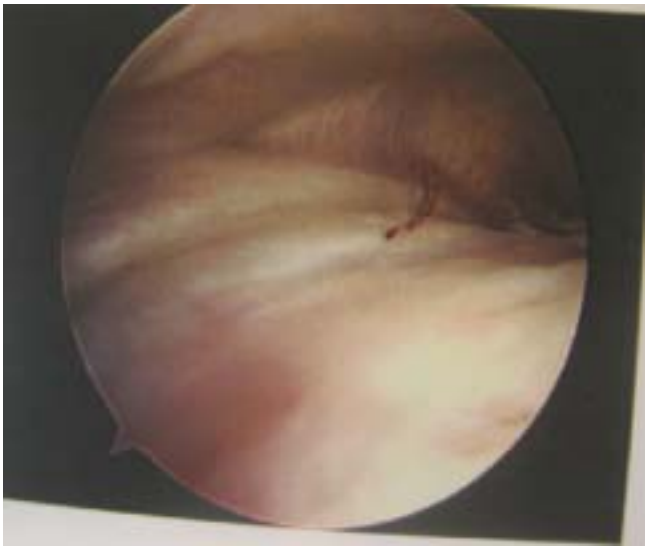

Figure 4. Labrum, Femoral Head and Neck and Viewed from the Peripheral Capsular Approach

and there may be a role for treating this arthroscopically in some cases.[15,21] There have been reports of arthroscopic treatment of pigmented villonodular synovitis, synovial chondromatosis and iliopsoas tendon release or lengthening for the snapping hip as well.[5,22] Other controversial roles for hip arthroscopy include avascular necrosis and hip instability.[5,13,23] Contraindications for hip arthroscopy include advanced osteoarthritis, avascular necrosis with collapse, an ankylosed joint, significant heterotopic ossification, or any other condition that prohibits entry into the hip joint.

HIP ARTHROSCOPY TECHNIQUE PRINCIPLES

Hip arthroscopy is performed with the use of traction in either the lateral, supine, or modified supine position under fluoroscopic guidance. There is a steep learning curve, but as the surgeon becomes more comfortable with the procedure and variations in anatomy, the hip joint and peripheral capsular structures should be well visualized with relative ease and safety. The structures that should be visualized in each case include the femoral head, acetabulum, pulvinar, ligamentum teres, anterior, superior, and posterior labrum, the zona orbicularis, standard medial plicae, femoral neck, peripheral femoral head-and-neck junction, peripheral labrum and occasionally the iliopsoas tendon attachment (Figure 4). The use of three small standard portals and occasionally accessory portals allows for visualization and treatment of the above structures and associated pathology. It is critical to know the anatomy adjacent to the standard portals and this is well described.[24]

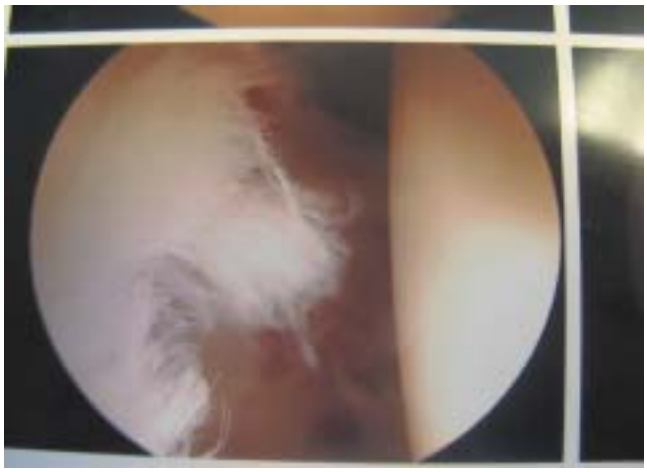

Figure 5. Anterosuperior Labral Tear

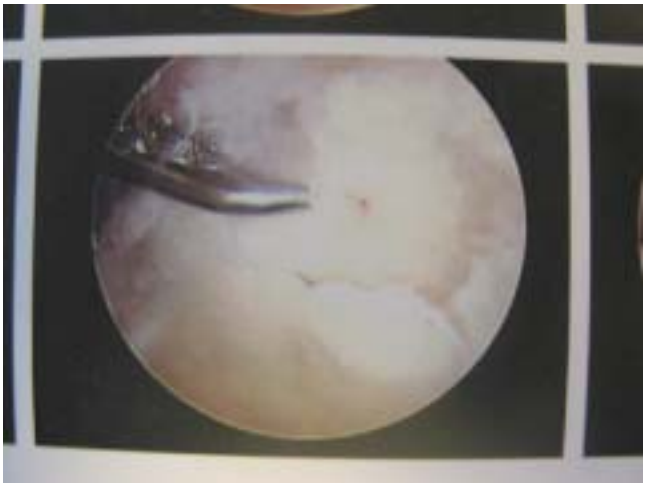

Figure 6. Microfracture to Acetabular Defect

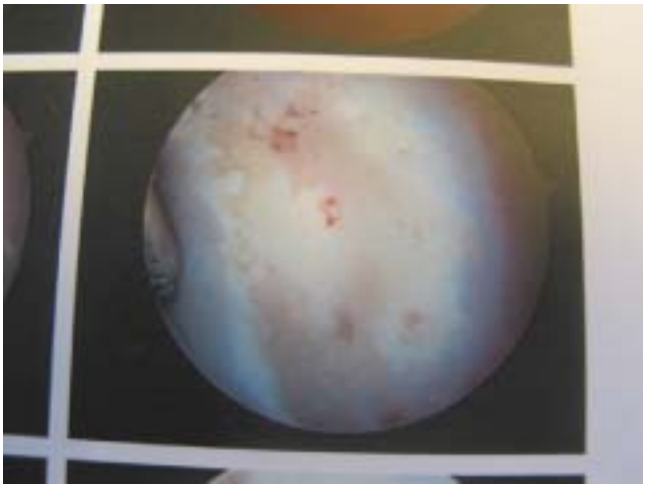

Figure 7. After Chondral Debridement and Microfracture

HIP DISORDERS WITH A ROLE FOR HIP ARTHROSCOPY

Labral Pathology

Multiple studies have documented successful treatment of labral tears arthroscopically (Figure 5).[5,19,21,22,27,28,29] Excellent outcomes are reported in 67 to 91 percent of individuals when treating labral tears.[5,19,21,22,27,28,29] When labral tears are associated with chondral or arthritic changes, results are less predictable.[5,19,21,27] Farjo reported that 46 percent of individuals found to have significant arthritic changes at the time of hip arthroscopy eventually underwent total hip arthroplasty (THA) within 14 months.[19] McCarthy has reported that the size of the chondral lesion is a predictor of outcome, and with diffuse degenerative joint disease 78 percent of patients had a poor result and 43percent went on to THA.[21,27] Byrd has reported finding greatest improvement after arthroscopy in patients with loose bodies and labral tears.[22]

There is limited data regarding nonsurgical management of labral tears. Non-surgical treatment may be most effective when treating an acute labral tear. Reasons for this limited data may include patients infrequently presenting with acute labral tears, labral tears often going misdiagnosed for months to years, and some labral injuries becoming asymptomatic without ever confirming the presence of an intra-articular lesion.

There is some evidence that if diagnosed early, nonoperative treatment of labral tears can be successful.[25,26] Ikeda et al found six of seven patients that presented with acute labral tears became asymptomatic with partial weight bearing.[26] Fitzgerald, however, found only seven of fifty-five patients with documented labral tears were successfully treated with partial weight bearing.[16] In our practice we have had success treating some patients with acute labral tears with protected weight bearing. The majority, however, have had continued symptoms and eventually underwent hip arthroscopy. (C.M.L. unpublished data)

Focal Articular Cartilage Injury

Although there is little in the literature with respect to chondral resurfacing procedures performed arthroscopically in the hip, McCarthy reported his experience with utilizing a microfracture technique.[21,27] Good to excellent results were achieved in 71 percent of patients with lesions less than one centimeter in diameter compared to 40 percent for lesions greater than one centimeter in size (Figures 6 and 7).[21,27] We currently await further reports on the utility of osteochondral autograft and allograft procedures performed open and arthroscopically in patients with focal chondral defects.

Avascular Necrosis

Traditionally, avascular necrosis (AVN) of the hip has been treated with various techniques including core decompression, vascularized and nonvascularized fibular grafts, osteotomies, and ultimately joint reconstruction.[30] Byrd has reported a decrease in outcome measures after treating hip AVN arthroscopically.[22] McCarthy reported on a series of seven patients with hip AVN treated arthroscopically, and found it useful for accurate staging of AVN and treating patients with mechanical symptoms and pain secondary to loose bodies, synovitis, chondral flap tears and labral tears.[31] O'Leary also reported improved outcomes after arthroscopy in patients with hip AVN when mechanical symptoms were present.[28] We currently feel that hip arthroscopy is indicated for patients presenting with AVN when there is intra-articular evidence of loose bodies, labral tears, and chondral flaps in the absence of significant joint space narrowing and femoral head collapse. Hip arthroscopy can also be helpful for more accurate staging of AVN when contemplating various treatment options. We have found hip arthroscopy useful for staging at the same setting as core decompression for patients with hip AVN.

Ligamentum Teres Lesions

Ligamentum teres lesions have been increasingly reported in the literature and have been reported to be the third most common finding during hip arthroscopy in athletes.[14,22] Typically, these patients present with deep anterior groin pain with or without mechanical symptoms.[32] Activities reported to be associated with these injuries include motor vehicle accidents, falls from a height, football, skiing, and hockey.[32] MRI has not been shown to be effective in diagnosing these lesions. MR arthrography is slightly better, with reported 29 percent sensitivity and 67 percent specificity for diagnosing these lesions.[14,32] The diagnosis of ligamentum teres lesions continues to be made based on history, clinical examination and arthroscopic evaluation. The treatment consists of simple debridement of the injured portion of the ligamentum teres with reported significant improvement in outcomes scores.[32]

Femoroacetabular Impingement

There is an increasing awareness of the diagnosis of femoroacetabular impingement. It is typically identified in young individuals (16 to 40 years old) and may be a nondysplastic etiology of osteoarthritis.[15] Patients typically present with groin pain and a positive impingement test.[15,33,34] A positive impingement test is pain with flexion, internal rotation, and adduction of the hip joint with the patient in the supine position. There can be a combination of anatomic characteristics that result in femoroacetabular impingement. The typical features include increased anterior coverage of the femoral head from acetabular retroversion, a non-spherical femoral head, short anterior head-neck offset, retroversion of the femoral head, and a deep acetabulum (Figures 8 and 9).[15,21,33,34] This type of impingment has been divided into cam and pincer types. Cam impingment is the result of impingement of a non-spherical femoral head against the acetabular rim and labrum.[15,33,34] This typically leads to labral detachment and adjacent chondral abrasion.[15,33,34] Frog lateral radiographs typically reveal a prominence or "bump" on the anterolateral portion of

Figure 8. Normal Head Neck Offset in Patient Who Underwent Prior Proximal Hamstring Repair

Figure 9. Non-spherical Femoral Head, Short Anterior Head-neck Offset Seen in Femoroacetabular Impingement

Figure 10. "Cross Over sign" indicative of Pincer type of femoral acetabular impingement

the femoral head neck junction. Normally the head is contained within a circle about the center of the femoral head. In cam impingment, the anterolateral portion of the femoral head lays lateral or outside of this circle. There may also be a pistol grip deformity as seen after slipped capital femoral epiphysis. Pincer impingement is the result of linear contact between the acetabulum and femoral head-neck junction.[15,34] In this second situation, the head-neck junction is often morphologically normal and impingement results from relative retroversion of the acetabulum or overcoverage of the anterior-superior acetabulum.[15,34] On a true antero-posterior radiograph, a line drawn along the anterior and posterior walls will reveal an overlap of the two lines superiorly called a "cross-over" sign which indicates relative acetabular retroversion or anterior overcoverage of the acetabulum (Figure 10). Pincer impingement can lead initially to anterior labral lesions followed by posterior inferior chondral lesions if impingement persists.[15,34]

Initial surgical management of femoroacetabular impingement has focused on removal of the anterior-superior acetabular prominence and removal of any non-spherical portion of the femoral head.[33,34] Beck reported on results of surgical dislocation and offset creation in 19 patients with a mean age of 36 years.[33] At a mean follow-up of 4.7 years, 13 hips were rated excellent to good, and five eventually underwent THA.[33] Arthroscopic proximal femoral resurfacing has recently been presented in 25 patients and although early results have been promising there is no published series in the peer reviewed literature to date.[21] We have had limited experience with two patients undergoing proximal femoral resurfacing arthroscopically with good early results (C.M.L. unpublished data).

Instability

The diagnosis of hip instability has recently received more attention, but there is little data regarding the specifics in diagnosing and treating this entity. It has been reported to be a potential source of disability in certain patients with unresolved hip pain.[5,23] The inherent stability of the hip joint makes this difficult to define. The labrum plays a role in stabilizing the hip joint, and labral deficiency could theoretically contribute to hip instability, as could the presence of capsular laxity in some individuals.[5,23] Patients with connective tissue disorders or generalized ligamentous laxity may present with symptoms of giving way or habitual subluxation or dislocation. [5,23]

This condition has primarily been described in elite athletes involved in sports requiring repetitive hip rotation with axial loading such as baseball, ballet, gymnastics, football, figure skating and golf.[5,23] Pelvic rotation and, in particular, external rotation has been reported to cause pain in these patients.[5,23] Thermal capsulorrhaphy in addition to labral debridement has resulted in improvement in symptoms in over 80 percent of individuals according to one author.[5,23] The diagnosis is typically made based on clinical suspicion and the presence of capsular laxity seen at the time of hip arthroscopy. Increased hip external rotation on examination or under anesthesia may indicate incompetence or relative laxity of the iliofemoral ligament. The introduction of a large amount of saline into the hip joint at the time of surgery (>50 cc) may also indicate relative laxity of the hip joint capsule. One must take into account the typical history and examination findings when making the diagnosis of hip instability. Unfortunately, there is little published in the literature regarding outcomes in a large series of patients and it remains unclear whether capsulorrhaphy in conjunction with labral debridement provides additional relief when compared to labral debridement alone.

SUMMARY

The diagnosis and management of patients presenting with hip pain is often challenging. A thorough history and physical examination, imaging studies and selective injections can help define the source of pain in many of these individuals. As technology and technical skills continue to improve, the role for hip arthroscopy will continue to expand. Further well-designed studies will better refine the indications for hip arthroscopy in managing patients with hip pathology.

REFERENCES

1. **Burman, M.:** Arthroscopy or the direct visualization of joints. *J Bone Joint Surg*, 4:669-695, 1931.
2. **Patterson, I.:** The torn acetabular labrum; a block to reduction of a dislocated hip. *J Bone Joint Surg Br*, 39(2):306-9, 1957.
3. **Dameron, T.B., Jr.:** Bucket-handle tear of acetabular labrum accompanying posterior dislocation of the hip. *J Bone Joint Surg Am*, 41(1):131-4, 1959.
4. **Suzuki, S., Awaya, G., Okada, Y., Maekawa, M., Ikeda, T., Tada, H.:** Arthroscopic diagnosis of ruptured acetabular labrum. *Acta Orthop Scand*, 57(6):513-5, 1986.
5. **Kelly, B.T., Williams, R.J., III, Philippon, M.J.:** Hip arthroscopy: current indications, treatment options, and management issues. *Am J Sports Med*, 31(6):1020-37, 2003.
6. **Seldes, R.M., Tan, V., Hunt, J., Katz, M., Winiarsky, R., Fitzgerald, R.H., Jr.:** Anatomy, histologic features, and vascularity of the adult acetabular labrum. *Clin Orthop*, 382:232-40, 2001.
7. **McCarthy, J.C., Noble, P.C., Schuck, M.R., Wright, J., Lee, J.:** The role of labral lesions to development of early degenerative hip disease. *Clin Orthop*, 393:25-37, 2001.
8. **Kim, Y.T., Azuma, H.:** The nerve endings of the acetabular labrum. *Clin Orthop*, 320:176-81, 1995.
9. **Takechi, H., Nagashima, H., Ito, S.:** Intra-articular pressure of the hip joint outside and inside the limbus. *J Jpn Orthop Assoc*, 56(6):529-36, 1982.
10. **Kallas, K.M., Guanche, C.A.:** Physical examination and imaging of hip injuries. *Oper Tech Sports Med*, 10(4):176-83, 2002.
11. **Gray, H., Williams, P.L., Bannister, L.H.:** *Gray's Anatomy: The anatomical basis of medicine and surgery* (38 ed). New York, NY, Churchill Livingstone, 1995.
12. **Huffman, G.R., Safran, M.R.:** Arthroscopic treatment of labral tears. *Oper Tech Sports Med*, 10(4):205-14, 2002.
13. **Byrd, J.W.:** Hip arthroscopy: patient assessment and indications. *Inst Course Lect*, 52:711-9, 2003.
14. **Byrd, J.W., Jones, K.S.:** Diagnostic accuracy of clinical assessment, magnetic resonance imaging, magnetic resonance arthrography, and intra-articular injection in hip arthroscopy patients, *Am J Sports Med*, 32(7):668-74, 2004.
15. **Ganz, R., Parvizi, J., Beck, M., Leunig, M., Notzli, H., Siebenrock, K.A.:** Femoroacetabular impingement: a cause for osteoarthritis of the hip. *Clin Orthop*, 417:112-23, 2003.
16. **Fitzgerald, R.H., Jr.:** Acetabular labrum tears. Diagnosis and treatment. *Clin Orthop*, 311:60-8, 1995.
17. **Czerny, C., Kramer, J., Neuhold, A., Urban, M., Tschauner, C., Hofmann, S.:** Magnetic resonance imaging and magnetic resonance arthrography of the acetabular labrum: comparison with surgical findings. *ROFO Fortschr Geb Rontgenstr Nuklearmed*, 173(8):702-7, 2001.
18. **Czerny, C., Hofmann, S., Neuhold, A., Tschauner, C., Engel, A., Recht, M.P., Kramer, J.:** Lesions of the acetabular labrum: accuracy of MR imaging and MR arthrography in detection and staging, *Radiology*, 200(1):225-30, 1996.
19. **Farjo, L.A., Glick, J.M., Samson, T.G.:** Hip arthroscopy for acetabular labral tears. *Arthroscopy*, 15(2):132-7, 1999.
20. **Edwards, D.J., Lomas, D., Villar, R.N.:** Diagnosis of the painful hip by magnetic resonance imaging and arthroscopy. *J Bone Joint Surg Br*, 77(3):374-6, 1995.
21. **Byrd, J.W., McCarthy, J.C., Sampson, T.G., Glick, J.M.:** Hip Arthroscopy. AAOS 71st Annual Meeting Instructional Course Lecture, March 11, 2004, San Francisco, CA.
22. **Byrd, J.W., Jones, K.S.:** Prospective analysis of hip arthroscopy with 2-year follow-up. *Arthroscopy*, 16(6):578-87, 2000.
23. **Philippon, M.J.:** The role of arthroscopic thermal capsulorrhaphy in the hip. *Clin Sports Med*, 20(4):817-29, 2001.
24. **Byrd, J.W., Pappas, J.N., Pedley, M.J.:** Hip arthroscopy: an anatomic study of portal placement and relationship to the extra-articular structures. *Arthroscopy*, 11(4):418-23, 1995.
25. **Hase, T., Ueo, T.:** Acetabular labral tear: arthroscopic diagnosis and treatment. *Arthroscopy*, 15(2):138-41, 1999.
26. **Ikeda, T., Awaya, G., Suzuki, S., Okada, Y., Tada, H.:** Torn acetabular labrum in young patients. Arthroscopic diagnosis and management. *J Bone Joint Surg Br*, 70(1):13-6, 1988.
27. **McCarthy, J.C.:** The diagnosis and treatment of labral and chondral injuries. *Inst Course Lect*, 53:573-7, 2004.
28. **O'Leary, J.A., Berend, K., Vail, T.P.:** The relationship between diagnosis and outcome in arthroscopy of the hip. *Arthroscopy*, 17(2):181-8, 2001.
29. **Santori, N., Villar, R.N.:** Acetabular labral tears: result of arthroscopic partial limbectomy. *Arthroscopy*, 16(1):11-5, 2000.
30. **Lavernia, C.J., Sierra, R.J., Grieco, F.R.:** Osteonecrosis of the femoral head. *J Am Acad Orthop Surg*, 7(4):250-61, 1999.

31. **McCarthy, J.C., Puri, L., Barsoum, W., Lee, J.A., Laker, M., Cooke, P.:** Articular cartilage changes in avascular necrosis: an arthroscopic evaluation. *Clin Orthop*, 406:64-70, 2003.
32. **Byrd, J.W., Jones, K.S.:** Traumatic rupture of the ligamentum teres as a source of hip pain. *Arthroscopy*, 20(4):385-91, 2004.
33. **Beck, M., Leunig, M., Parvizi, J., Boutier, V., Wyss, D., Ganz, R.:** Anterior femoroacetabular impingement: part II. Midterm results of surgical treatment. *Clin Orthop*, 418:67-73, 2004.
34. **Lavigne, M., Parvizi, J., Beck, M., Siebenrock, K.A., Ganz, R., Leunig, M.:** Anterior femoroacetabular impingement: part I. Techniques of joint preserving surgery. *Clin Orthop*, 418:61-6, 2004.

A FUTURE MODEL OF MUSCULOSKELETAL REHABILITATION AT THE UNIVERSITY OF IOWA HOSPITALS AND CLINICS: SPANNING THE CONTINUUM OF CARE

Joseph J. Chen, MD

ABSTRACT

Models of rehabilitation care vary widely within academic medical centers, with most housing their own inpatient rehabilitation units. The University of Iowa Hospitals and Clinics focuses both on acute hospital inpatient and outpatient rehabilitation care instead of leaving rehabilitation to local community-based hospitals. This article discusses a method to provide adult inpatient rehabilitation care, and simultaneously provide specialized rehabilitation teams capable of spanning the entire continuum of rehabilitative care from admission at a Level I Trauma Center to the conclusion of successful outpatient rehabilitation needs. The costs of implementation of this plan can be justified by avoiding increased expenses already being incurred in addition to successful capture of outpatient rehabilitation revenues.

THE CURRENT MODEL OF INPATIENT REHABILITATION CARE AT ACADEMIC MEDICAL CENTERS

Most academic medical centers provide a comprehensive array of acute medical services ranging from specialized burn and trauma units and pediatric bone marrow transplant units, to outpatient specialty clinics and other "Centers of Excellence." Most academic medical centers also felt the need to develop an inpatient rehabilitation unit to serve their patients with neuromuscular injuries or diseases. When hospitals and academic medical centers were forced to utilize Diagnosis Related Group payments for their hospitalized patients, many inpatient rehabilitation units flourished as they continued to be paid for actual charges under a fee-for-service type of contract. However, with the recent development of the Prospective Payment System for Rehabilitation, running a viable rehabilitation unit has posed increasingly difficult economic challenges. For those academic medical centers without an inpatient rehabilitation unit, these challenges are yet another barrier to the development of an inpatient rehabilitation unit. However, when examining the costs of an academic health center without such an inpatient rehabilitation unit, one must realize that there is a tremendous potential for cost-savings by shaping the model of rehabilitation to one that spans the continuum of care from admission to a Level I Trauma Center to successful capture of outpatient rehabilitation services.

THE PAST MODEL OF INPATIENT REHABILITATION CARE AT UIHC

The University of Iowa Hospitals and Clinics (UIHC) has traditionally focused on providing only acute care hospital services and leaving rehabilitation care to its local community hospitals in Cedar Rapids, Waterloo, Davenport, Dubuque, and Des Moines. Patients admitted for stroke or multiple traumatic injuries had their acute neurological and orthopaedic surgical care provided by world-renowned neurologists, neurosurgeons, orthopaedic surgeons and trauma surgeons. When they reached medical stability, they were transferred to the local rehabilitation unit nearest to their home, provided that they had medical insurance or readily qualified, given their new neuromuscular injuries or disabilities.

In August 2000, the University of Iowa Hospitals and Clinics hired its first physiatrist (a physical medicine and rehabilitation physician) for the main purpose of running an outpatient musculoskeletal and spine practice for many of their non-surgical chronic spine pain patients within the Department of Orthopaedics. UIHC and the Carver College of Medicine did not have a Department or Division of Physical Medicine & Rehabilitation recognized within its College of Medicine.

In January 2005, the University of Iowa Hospitals and Clinics appointed its first Medical Director of Rehabilitation to coordinate rehabilitative services for its organization. Many positive changes had occurred for rehabilitation specialists within the past five years. The Center for Disabilities & Development, formerly the University Hospital School, has opened its eight-bed Pediatric Neuro-Trauma Rehabilitation Unit, similar to

Medical Director of Rehabilitation
University of Iowa Hospitals and Clinics
Iowa City, Iowa

Correspondence:
Joseph J. Chen, M.D.
Department of Orthopaedics and Rehabilitation
University of Iowa Hospitals and Clinics (UIHC)
200 Hawkins Drive
Iowa City, Iowa 52242

a model of care existing at Denver Children's Hospital. The Department of Rehabilitation Therapies, a hospital-based department, consisted of a consolidation of prior departments of physical therapy, occupational therapy and activities therapy led by an experienced physical therapy administrator. During a review by the American College of Surgeons Committee on Trauma, UIHC was criticized for its lack of physician-directed rehabilitation services during a review of their Level I Trauma Center. In response, UIHC developed a Trauma Rehabilitation Consultation Service to provide physiatry consultation and coordination of care for its spinal-cord injured and traumatic brain-injured patients. The Department of Orthopaedics also changed its name to the Department of Orthopaedics and Rehabilitation, thus reflecting the spectrum of care provided and the fact that its two physiatrists were recognized by its College of Medicine. The Spine Rehabilitation Program became even better-recognized by physicians within The State of Iowa for its expertise in treating patients with complex chronic musculoskeletal pain by utilizing an interdisciplinary team approach with physical therapists, psychologists, medical social workers and vocational counselors. Despite these advances, there still continues to be significant room for improvement within the spectrum of rehabilitation care at UIHC in the future.

THE CURRENT MODEL OF INPATIENT REHABILITATION CARE AT UIHC

There are several reasons why many other academic health centers have abandoned the current model of rehabilitation utilized at UIHC in favor of "condition-specific" rehabilitation teams. The current model of rehabilitation at UIHC relies upon a physician referral from one of the medical or surgical units (Figure 1). There exists a wide variation in practice patterns by individual trauma surgeons, neurosurgeons, neurologists, hospitalists, etc., so that some patients may get early physical therapy referrals, other patients may be referred much later during their hospitalization, and unfortunately, some may not receive a referral. This may explain why our inpatient physical therapy staff is much smaller than comparable units in other academic health centers (University of North Carolina, University of Missouri, Mayo Clinic) and even our local community hospitals (Mercy—Iowa City, St. Lukes, Covenant Hospital). In addition, many patients do not get occupational therapy referrals, which may explain why we have fewer than six inpatient occupational therapy specialists staffing our traditional inpatient floors, while most other centers have over twenty, including those without inpatient rehabilitation units.

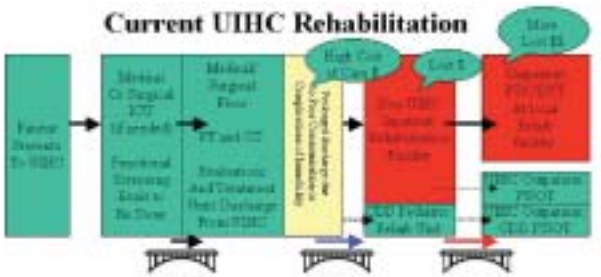

Figure 1.

When rehabilitation services are requested, a physician specializing only in rehabilitation does not coordinate the rehabilitation team members. A patient admitted to one of the ICUs may get some basic physical therapy (PT) services for range-of-motion exercises or stretching, but when the patient improves enough to be transferred to the general medical/surgical floor, usually a completely different team, another physical therapist and sometimes even a different attending physician will then resume medical or surgical treatment. Some physicians may also still feel that physical therapy could be delayed until after discharge from the intensive care unit settings, even though there have been documented studies of the loss in functional capacity of the musculoskeletal and cardiovascular systems.[1] Similar studies also show earlier achievement of functional milestones, improved satisfaction after uncomplicated coronary artery bypass graft (CABG) surgery, and therefore earlier discharges from an acute care hospital setting.[2]

Lack of involvement in physical medicine and rehabilitation is central to the problem of inconsistent physician referrals for physical therapy, under-utilization of physical therapy, and prolonged lengths of stay. Many academic medical centers have physicians in a Department or Division of Physical Medicine and Rehabilitation who are consulted when a patient with significant neuromuscular disease or disability is admitted to any service. This physician then coordinates the rehabilitation interventions for the patient throughout the hospitalization and even arranges outpatient follow-up in his/her rehabilitation clinic if needed. In the absence of this service, some non-rehabilitation physicians may lose interest or the ability to plan an appropriate discharge setting. This puts the social workers, nurses, physical therapists and occupational therapists in the awkward position of helping determine appropriate discharge recommendations and follow-up. The Continuum of Care Management Department has greatly helped in moving patients from UIHC to another setting, but this

system does not take into account how to get the patient back to UIHC for outpatient medical or rehabilitation follow-up.

In addition, many of our patients who are sent to an inpatient rehabilitation unit will need outpatient physical therapy, occupational therapy or speech therapy. These outpatient therapies are typically well-reimbursed by Medicare compared to inpatient rehabilitation services. Because UIHC does not have an inpatient rehabilitation unit, UIHC receives fewer referrals for outpatient stroke therapy compared with other local hospitals. There is a significant ability to improve our outpatient stroke rehabilitation offerings by increasing outpatient physical therapy, occupational therapy and speech therapy staffing. Because these patients require multiple rehabilitation disciplines within UIHC, they are best managed by a UIHC physiatrist and not by an outside referring physician.

In the recent UIHC practice to provide acute care hospital services and leave rehabilitation to local hospitals, we may inadvertently be sustaining significant costs by not capturing revenue from outpatient rehabilitation services. It is essential that we utilize and organize our rehabilitation inpatient and outpatient services effectively. This new model of rehabilitation care can improve our hospital operating margin by reducing length of stay and increasing our outpatient rehabilitation services.

In summary, concerns with the current model of rehabilitation at UIHC include: a) Relying upon individual physician prescribing patterns

for who gets PT/OT; b) A different therapist typically treats the patient on the floor after the intensive care unit stay; c) Weekend PT services are provided only if the potential for prolonged discharged would otherwise occur; d) Patient discharge planning is left to the primary physician, continuation of care manager, social worker, physical therapists and occupational therapists, and not a rehabilitation physician; f) No team-specific rehabilitation team – Rehabilitation physician, physical therapist, occupational therapist, social worker or registered nurse; g) UIHC lengths of stay that are greater than UIHC data for select populations; and h) Poor capture of outpatient PT and OT services after discharge from UIHC.

Therefore, we suspect that a Physical Medicine & Rehabilitation Consultation for all patients with neuro-musculo-skeletal impairments or disability as a part of early discharge planning would reduce length of stay for all inpatients by creating a care plan for rehabilitation, and allow an opportunity for nursing units, Continuum of Care navigators, the primary medical or surgical teams, and rehabilitation specialists to improve communication.

Figure 2.

THE NEXT GENERATION MODEL: SPECIALIZED REHABILITATION SERVICE MODELS

Many hospitals abandoned the prior model of care 20 to 30 years ago when sufficient physical medicine and rehabilitation physicians became available, trained in the management of neuro-musculo-skeletal disease and disability. Some hospitals formed their own inpatient rehabilitation units managed by these physical medicine and rehabilitation physicians. Another state hospital, the University of Missouri in Columbia, partnered with HealthSouth Rehabilitation to provide rehabilitation care for most of their patients, while the Missouri Rehabilitation Center receives money from the Missouri Legislature to provide rehabilitation services for indigent residents of Missouri. Still other prominent rehabilitation hospitals such as the Rehabilitation Institute of Chicago, the Rehabilitation Institute of Michigan, the Charlotte Institute of Rehabilitation and the National Rehabilitation Hospital provide specialized rehabilitation centers while allowing acute care hospitals to focus on medical/surgical growth opportunities. Many of the hospitals that did not create their own rehabilitation units have created specialized hospital units trained to care for specific patient populations (Figure 2). The most common type of unit is a comprehensive stroke unit. There are also a number of specialized comprehensive geriatric units (or Acute Care for the Elderly –ACE units) in the country. As mentioned before, the Center for Disabilities and Development has developed a Pediatric Neuro-Trauma Rehabilitation Unit from a model of care that has been successful at the Denver Childrens Hospital for over 15 years.

THE ROLE OF THE PHYSICAL MEDICINE AND REHABILITATION PHYSICIAN

Physical medicine and rehabilitation physicians provide a unique ability to thoroughly assess problems ranging from medical, surgical and psychosocial impairments that may impact the patient's ability to return to become a productive member of society. This includes the prevention of medical complications related to swal-

lowing problems (dysphagia or aspiration pneumonias), skin breakdown (costly pressure sores or wound treatments), venous thrombosis and pulmonary embolus, bowel and bladder dysfunction, malnutrition and pain. Evaluation of impairments in communication (speech therapy), mobility (physical therapy), cognitive deficit or visual and spatial deficiency (occupational therapy), psychological or emotional deficit, and sensory impairments are also important considerations in a patient's rehabilitation program. Psychosocial assessment and family/caregiver support and education on prognosis is vital at the early stages of a devastating neurological illness such as a spinal cord injury or traumatic brain injury. An assessment of function prior to entry into a formal inpatient rehabilitation program is also necessary and can best be provided by a physical medicine and rehabilitation physician coordinating communication among the primary medical and surgical teams, the nurses and rehabilitation specialists, the patient, and family.

SPECIALIZED SERVICES: STROKE UNITS AND GERIATRIC TEAMS

These comprehensive stroke units use "specialized stroke teams—an interdisciplinary approach to care, and a single unit where the patient remains in the same bed throughout the acute and rehabilitation stages of care." Commitment to the new delivery model by formal leaders, informal leaders, and front-line staff, as well as a supportive organizational structure, contributed to an expedited and successful implementation. Bisaillon et al. showed that average length of stay is shorter than the national standard, and that provider and patient satisfaction has improved.[3] Ma et al. revealed in a randomized trial of either stroke unit or general ward for treatment of stroke, that stroke patients treated in a special stroke unit were able to return to normal daily activities earlier, with better social abilities and reduced neurological defects, without increasing the overall economic burden.[4]

A randomized controlled trial of 370 geriatric medical/surgical patients in an early-discharge rehabilitation service team setting used fewer days in hospital at three months (average nine days, median difference four days). This patient-centered service set clear goals, worked as a team, and considered physical, psychological, social and environmental issues. Cunliffe et al. concluded some older people can be discharged from the hospital sooner, with better health outcomes using a well-staffed and organized patient-centered early discharge service providing rehabilitation.[5]

EARLY INITIATION OF THERAPY

Physical therapy is typically started as early as possible and given as much as needed. The VA/Department of Defense Clinical Practice Guideline for the Management of Stroke Rehabilitation "strongly recommend(s) that rehabilitation therapy start as early as possible, once medical stability is reached." Cifu et al. demonstrate in a systematic review of 38 randomized control trials dating back to 1965, that early rehabilitation therapy appears to have a strong relationship with improved functional outcome at hospital discharge and follow-up.[6] Paolucci et al. also found a strong inverse relationship between the start date of rehabilitation and functional outcome.[7] The earliest starters had significantly higher effectiveness of treatment than did the medium or latest groups. Treatment initiated within the first 20 days was associated with a significantly high probability of excellent therapeutic response, and beginning later was associated with a poor response.

INTENSITY OF THERAPY

Two meta-analyses both concluded that greater intensity produces slightly better outcomes. Langhorne et al. found that intensive physiotherapy input was associated with a reduction in the combined poor outcome of death or deterioration and may enhance the rate of recovery.[8] Kwakkel et al.[9] reported a small but statistically significant intensity-effect relationship in the rehabilitation of stroke patients. Therefore the Clinical Practice Guideline recommendation is "that the patient receives as much therapy as needed to adapt, recover and/or reestablish the premorbid or optimal level of functional independence."[10]

IMPROVED PATIENT SATISFACTION

Improvements in patient satisfaction are usually intangible and difficult to measure using standard fiscal markers of return on investment. When a patient has a good experience during a hospitalization, this can lead to increased returns for elective procedures such as elective admissions, outpatient visits, and physical therapy and occupational therapy visits. Because UIHC does not have an inpatient rehabilitation unit, few patients return here for outpatient PT and OT. Furthermore, the costs of inpatient physical therapy and occupational therapy are included in the inpatient DRG payment while outpatient physical therapy and occupational therapy costs are reimbursed under Medicare Part B. When patients return to their dismissing rehabilitation facility for additional therapy instead of returning to UIHC, we lose further revenue. Development of additional specialized rehabilitation teams to span the continuum of inpatient and outpatient services are es-

sential for our state mission, to provide comprehensive health care to all Iowans, in addition to meeting patient expectations of our ability to offer the full continuum of health care services.

In summary, the benefits of specialized rehabilitation team acute care are: a) early physical medicine and rehabilitation assessment to provide care plan for rehabilitation; b) PT started as early as possible, given as much as needed (in ICU and on weekends); c) Decreased complications of immobility through early mobilization; d) Decreased length of stay; e) Increased elective admissions and outpatient PT/OT visits; f) Enhances state mission to provide comprehensive health care for all Iowans.

A current model for a specialized rehabilitation service is the Trauma Rehabilitation Consultation Service. This service involves a team-based approach including the trauma/burn surgeon, trauma/burn nurse, physical medicine and rehabilitation physician, medical social worker, physical therapist, occupational therapist and nutritionist/dietitian. When patients are admitted with severe neuro-musculo-skeletal injuries, the surgeons consult the physical medicine and rehabilitation physician in addition to implementing the standard physical therapy and speech therapy services. The physical medicine and rehabilitation physician is consulted on the patient and manages the overall rehabilitation care including PT and OT for these patients, throughout the patient's ICU stay, to the medical/surgical floor, and even to the housed outpatient floor if needed. Recommendations are made for whether patients are appropriate to transfer to acute inpatient rehabilitation facilities, subacute rehabilitation facilities, or outpatient rehabilitation. Follow-up visits into the rehabilitation medicine clinic are also arranged when patients have ongoing nerve or muscle injuries or need extensive outpatient rehabilitation services. The team meets weekly with the Trauma Service and the physiatrist frequently meets with the rehabilitation therapists more frequently, or even daily if needed.

A FUTURE OF REHABILITATION: SPANNING THE CONTINUUM OF CARE

Even the development of additional inpatient rehabilitation services would not bring us up to what will shape the future of rehabilitation care for an academic medical center. Many academic medical centers that already have specialized stroke units, geriatric units, or even inpatient rehabilitation units, are experimenting with a care process that expedites discharge from these units followed by outpatient day rehabilitation programs or other such services that allow patients to move through their continuum of care more quickly than

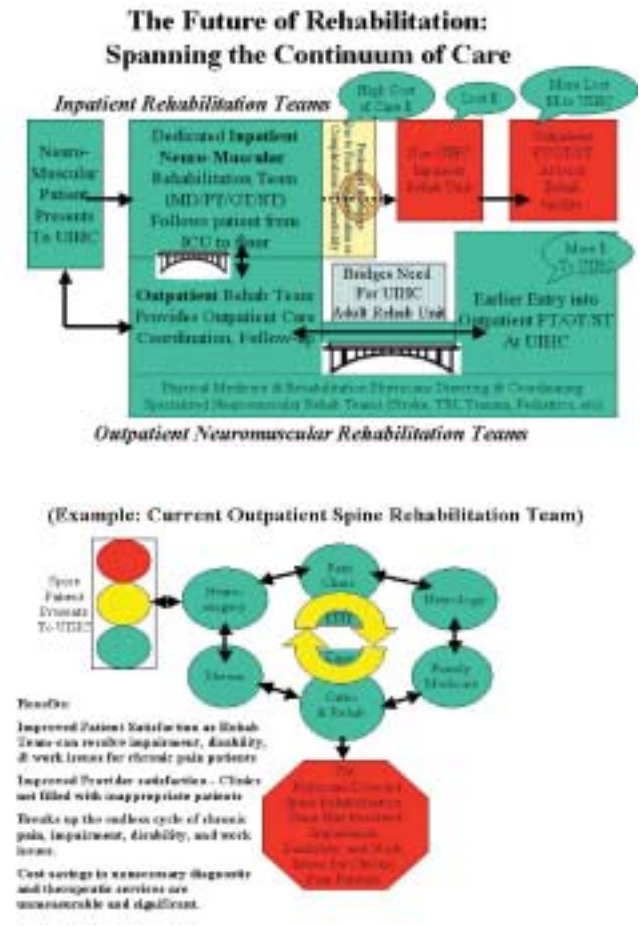

Figure 3.

before (Figure 3). In another study, Fjaertoft et al.[11] in 2003 studied 320 acute stroke patients who were randomized into an ordinary stroke unit service or a stroke unit with early supported discharge and further rehabilitation. The authors concluded that more patients treated in the early supported discharge setting were independent with this type of care compared to ordinary stroke unit care. These newest models of rehabilitative care represent the future standard in rehabilitation. We have an opportunity as well as a responsibility to provide this level of expert care to the residents of Iowa. Not only will this improve our patient care, but any costs will likely be offset in decreased lengths of stay through earlier discharge, increased outpatient revenues, or improved patient or provider satisfaction.

Fortunately, we are not alone when compared to other academic health centers in term of having specialized outpatient rehabilitation programs. In fact, many other academic health centers such as the University of North Carolina, Dartmouth and others, are trying to

develop an effective spine rehabilitation program for their chronic pain patients. Our Spine Rehabilitation Team has treated difficult, complicated chronic pain patients for almost 20 years. By using an interdisciplinary team including physical therapists, clinical psychologists, spine nurses, a medical social worker and a vocational counselor, we have provided cost-effective and clinically effective care for patients with chronic back pain, as revealed by Lanes et al.,[12] and Patrick et al.[13] Not only are these patients difficult from a medical or surgical evaluation standpoint, they typically have many medico-legal or psychosocial impairment and disability issues that play a significant role in the medical treatment of chronic pain.

Impairment and disability are words that generate little enthusiasm in many physicians. Many patients with chronic pain believe they are temporarily or permanently disabled from society's work force. A physician-led team of rehabilitation specialists knowledgeable of impairment and disability can resolve these issues, and rehabilitate a patient to still get back into the work force. When patients with chronic pain are seen by physicians unaware of impairment and disability issues, medical costs increase substantially due to inappropriate diagnostic testing, subspecialty consultations, or referrals for functional capacity evaluations. These chronic pain patients are frequently dissatisfied by bouncing among clinics in neurosurgery, anesthesia/pain, neurology, rheumatology, internal medicine and family medicine. When patients with significant neuromuscular impairment are sent to the housed outpatient unit, waiting up to 90 days for their disability determination, this also leads to significant costs to UIHC.

The Spine Rehabilitation Team model for treatment of chronic pain patients provides outpatient assessment and a team approach toward teaching a patient to manage chronic pain through an active exercise program and other pain- and stress-management exercises. Evidence-based medicine shows that treatment of chronic spine pain utilizing physical and cognitive-behavior interventions is just as effective as surgical treatment, as revealed by Keller and Brox et al.[14]

Patients with chronic pain and neuromuscular impairments are costly to UIHC. Chronic pain patients with disability issues are not patients that most departments want to return to their clinics. Management of these patients in a cost-effective and clinically effective manner is vital to our success. Without such a service, patients with chronic pain or musculoskeletal impairments would continue to seek and occupy outpatient clinics and housed outpatient units. Growth and expansion of services in Orthopaedics, Neurosurgery, Neurology, and the Pain Clinic at UIHC in these areas would be curtailed by these unnecessary visits. The Spine Rehabilitation Team's approach is interdisciplinary, remains patient-centered, improves patient satisfaction, and follows evidence-based guidelines for treatment of chronic pain, impairment and disability. This is exactly the model of care that hospitals and academic health centers should adopt for management of chronic musculoskeletal diseases and disabilities.

In summary, a model of rehabilitation at UIHC should include a specialized inpatient rehabilitation team with early discharge services based on diagnosis/impairments, focusing on: a) Patients receiving rehabilitation treatments based on diagnosis/impairments, not specific referring physician patterns; b) Early physical medicine and rehabilitation assessment to provide a necessary care plan for rehabilitation and improve communication among teams; c) Improved provider (MD/PT/OT/SW) satisfaction – development of specific rehabilitation teams; d) Decrease complications of immobility through early mobilization (PT, activity order); e) Improved patient satisfaction – developing a patient-centered approach; f) Decrease length of stays, bring level of stay to below UIHC standards.

The model will also increase specialized outpatient rehabilitation services like the spine rehabilitation team, focusing on: a) Improved capture of UIHC elective outpatient PT/OT services after supported inpatient discharge, bypassing the need for UIHC Inpatient Rehabilitation Unit; b) Unmeasurable potential financial benefits in increased outpatient PT/OT revenues, avoidance of lost revenues due to current loss in outpatient PT/OT referrals, reduction of expenses (housed outpatient unit), avoidance of increased expenses in management of preventable recognized medical complications (pressure ulcers, DVTs/Pulmonary emobli, aspiration pneumonias, etc. and; c) patient satisfaction.

REFERENCES

1. **Topp R.; Ditmyer, M.; King K.; Doherty, K.; Hornyak, J. III;** The effect of bed rest and potential of rehabilitation on patients in the intensive care unit. *AACN Clin Issues* 13:263-76, 2002.
2. **Van der Peijl, ID.; Vliet Vlieland, T.P.; Versteegh, M.I.; Lok, J.J.; Munneke, M., Dion, R.A.:** Exercise therapy after coronary artery bypass graft surgery: a randomized comparison of a high and low frequency exercise therapy program. *Ann Thorac Surg*. 77:1535-41, 2004.
3. **Bisaillon, S.; Douloff, C.; Leblanc, K.; Pageau, N.; Selchen, D.; Woloshyn, N.:** Bringing innovation to stroke care: development of a comprehensive stroke unit. *Axon*. 25:12-7. 2004.
4. **Ma, R.H.; Wang, Y.J.; Qu, H.; Yang, Z.H.:** Assessment of the early effectiveness of a stroke unit in comparison to the general ward. *Chin Med J (Engl)*. 117:852-5, 2004.
5. **Cunliffe AL; Gladman, J.R.; Husbands, S.L.; Miller, P.; Dewey, M.E.; Harwood, R.H.:** Sooner and healthier: a randomized controlled trial and interview study of an early discharge rehabilitation service for older people. *Age Ageing* 33:246-52, 2004.
6. **Cifu, D.X.; Stewart, D.G.:** Factors affecting functional outcome after stroke: a critical review of rehabilitation interventions. *Archives of Phys Med & Rehab*. 80:S35-9, 1999.
7. **Paolucci S.; Antonucci, G.; Grasso, M.G.; Morelli, D.; Troisi, E.; Coiro, P.; Bragoni, M.:** Early versus delayed inpatient stroke rehabilitation: a matched comparison conducted in Italy. *Arch Phys Med & Rehabil*. 81:695-700, 2000.
8. **Langhorne, P.; Wagenaar, R.; Partridge, C.:** Physiotherapy after stroke: more is better? *Physiotherapy Research International* 1:75-88, 1996.
9. **Kwakkel, G.; Wagenaar, R.C.; Twisk, J.W.:** Intensity of leg and arm training after primary middle cerebral stroke: a randomised trial. *Lancet* 354: 191-6, 1999.
10. www.oqp.med.va.gov/cpg/str/str_cpg, Stroke Rehabilitation Clinical Practice Guidelines by the Office of Quality and Performance, Veterans Administration, Department of Defense, February 2003.
11. **Fjaertoft, H.; Indredavik, B.; Johnsen, R.; Lydersen, S.:** Acute stroke unit care combined with early supported discharge. Long-term effects on quality of life. A randomized controlled trial. *Clinical Rehabilitation* 18:580-6, 2004.
12. **Lanes, T.C.; Gauron, E.F.; Spratt, K.F.; Wernimont, T.J.; Found E.M.; Weinstein J.N.:** Long-term follow-up of patients with chronic back pain treated in a multidisciplinary rehabilitation program. *Spine* 20:801-6, 1995.
13. **Patrick, L.E.; Altmaier, E.M; Found, E.M.:** Long-term outcomes in multidisciplinary treatment of chronic low back pain: Results of a 13-year follow-up, *Spine* 29: 850-5, 2004.
14. **Keller, A.; Brox, J.I.; Gunderson, R.; Holm, I.; Friis, A.; Reikeras, O:** Trunk muscle strength, cross-sectional area, and density in patients with chronic low back pain randomized to lumbar fusion or cognitive intervention and exercises. *Spine* 29:3-8, 2004.

GLUTEUS MEDIUS TENDON RUPTURE AS A SOURCE FOR BACK, BUTTOCK AND LEG PAIN: CASE REPORT

Dennis Bewyer, P.T., and Joseph Chen, M.D.

ABSTRACT

A 67-year-old woman with chronic lumbosacral and hip symptoms involving gluteus medius tendon rupture and strain injury is presented here. We report her work-up and management. Although this is an uncommonly reported pathology, many patients with back, buttock and leg pain see physicians who often focus on lumbar spinal stenosis, lumbar radiculopathy or hip/knee osteoarthritis. Careful physical examination guided us to this patient's diagnosis.

INTRODUCTION

The gluteus medius muscle is important in stabilizing the ipsilateral hip in the stance phase of gait. When patients are unable to maintain pelvic neutrality, the energy cost of ambulation increases. We speculate that patients with weakness in the gluteus medius will subsequently develop low back pain, buttock pain or trochanteric bursitis pain.

We present a woman whose weakness in the gluteus medius was discerned through physical examination for back pain. Her weakness was treated with an appropriate rehabilitation program. Her pain then subsequently subsided.

CASE REPORT

The patient is a 67-year-old retired woman with a chief complaint of low back pain, right buttock pain and lateral thigh pain down to the knee. Her symptoms started four years previous with no specific precipitating traumatic event. Her symptoms worsened recently. They have now limited her walking and stair climbing. She stopped many of her outside activities like shopping, exercising at the health club or babysitting her grandchildren. Her pain was aggravated the most with any weight bearing on the right side. Standing and walking were painful, as was prolonged sitting. She could not lie on her right side in bed.

She had an extensive work-up. She initially saw her family physician locally, where x-rays of the lumbar spine were obtained which indicated spondylosis. She was referred for physical therapy that included lumbar stabilization exercises. She did not appreciate much relief and was sent for a lumbar spine magnetic resonance imaging (MRI) that indicated moderate spondylosis without significant canal stenosis. She was referred to a pain management facility locally for an interlaminar epidural steroid injection followed by lumbar facet injections at L4-5 bilaterally, both only producing temporary relief. Lumbar facet radiofrequency denervation was done at the same level without significant relief. A CT-myelogram of the lumbar spine as well as hip x-rays were negative. She also had electromyography and nerve conduction studies which were normal. Two more interlaminar epidural steroid injections at the L4-5 level were done with minimal benefit. She also had a trochanteric bursal injection which afforded only temporary relief.

Since she was continuing to have worsening pain and inability to ambulate, further treatment involved consideration of a spinal cord stimulator. She requested a second opinion regarding this procedure and came to our physiatry and physical therapy clinic.

Her physical exam revealed a positive Trendelenburg sign in stance and with gait. Hip rotational movements were normal without groin pain, but painful in the buttocks on the right. Neurologic examination was normal with no neural tension signs or weakness in toe extensors or ankle dorsiflexor muscles. Trunk flexion and extension movements in standing were limited 25% with pain in the gluteal area. She had adequate abdominal muscle control. Most notably, manual muscle testing for the gluteus medius muscle (side-lying, hip in extension, with the leg in abduction) on the right was 2/5 and reproduced her pain symptoms. Testing on the left was 5/5 and pain free. There was considerable tenderness over the right trochanter and in the gluteal muscles lateral to the posterior superior iliac spine (PSIS).

Department of Orthopaedics and Rehabilitation
Iowa Spine Research and Rehabilitation Center
University of Iowa
200 Hawkins Drive
Iowa City, IA, 52246-1009

Correspondence:
Dennis C. Bewyer, P.T.
Senior Physical Therapist
University of Iowa Hospital and Clinics
Iowa Spine Research and Rehabilitation Center
200 Hawkins Drive
Iowa City, IA 52246-1009

Figure 1. Coronal and axial T2 MRI views of the pelvis indicating strain injury and a large tear (curved arrow) of the right gluteus medius muscle. The opposite side is normal (straight arrow).

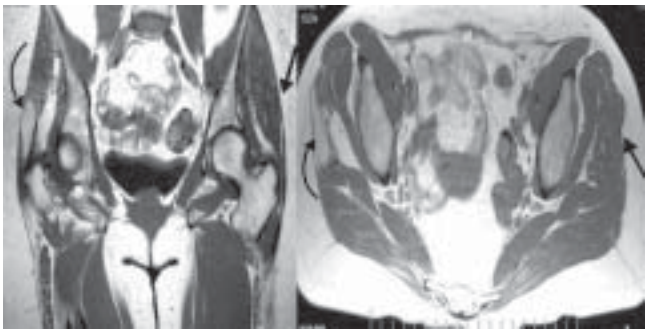

Figure 2. Coronal and axial T2 MRI views of the pelvis indicating healed muscle belly and persisting tear (curved arrow) after 4 months. The opposite side is normal (straight arrow).

We obtained MRI of the pelvis to rule out a stress fracture or other hip joint pathology, as well as examine the integrity of the gluteal muscles. The MRI revealed a strain injury as well as a large tear of the right gluteus medius muscle at the musclotendinous junction. (Figure 1).

Treatment involved protection of the strain injury during ambulation with the use of a straight cane and frequent use of cold packs over the gluteal muscles and trochanteric bursa. She also began a very low-level exercise program for strengthening the gluteus medius muscle. She was seen for follow-up in one month and reported a significant reduction in her painful symptoms and was making progress with strength. Manual muscle testing indicated a grade 3/5 that was still painful. Her exercise program was progressed and she continued use of the cane whenever she was out of the house. At four months, she was essentially asymptomatic and had returned to her regular activities. She no longer used a cane but continued to do her strengthening exercises. Manual muscle testing was a 4/5 and was not painful. A follow-up MRI was obtained which indicated healing of the strain injury, but the rupture remained (Figure 2).

DISCUSSION

In the past several years, there has been limited literature describing MRI and ultrasound diagnosis of gluteus medius strains or tears. Bird et al. found 46% of 24 patients with chronic buttock pain and symptoms ranging between 1-5 years, to have a gluteus medius tendon tear by MRI.[2] The Trendelenburg test was the most sensitive and specific physical exam finding for this condition. Chung looked specifically at elderly women with buttock pain and found six out of six women age 62-79 with full- or partial- thickness tendon tears by MRI findings. Three had surgical intervention for repair.[4] Connell et al. reported on ultrasound imaging in 75 patients, and found 63 had tendinopathy with 25 showing full-thickness or partial-thickness tears.[5] MRI parameters for diagnosing hip abductor strain and tendinopathy have been described as yielding an accuracy of 91%. Sensitivity and specificity of T2 hyperintensity superior to the greater trochanter are 73% and 91% respectively.[10]

Gluteus medius tendon tears have been described mostly in relation to findings during hip surgeries or gamma nailing procedures for proximal femur fractures in which up to 27% of the gluteus medius tendon insertion is disrupted during correct placement of this hardware.[8] Kagan found seven patients who had a partial tear of the gluteus medius tendon during treatment for refractory trochanteric bursitis, and reattached the tendons.[9] At median follow-up of 45 months, patients were pain free. Other studies report the surgical repair of some tears, but some authors have concluded that not all of them need to be surgically repaired.[14] Little is written regarding non-surgical treatment for gluteus medius tears. Bewyer and Bewyer reported a recommended treatment protocol and algorithm.[1]

The authors feel this problem is not as rare as most commonly thought. In a pilot study through our spine clinic, 70% of people presenting with lumbosacral and/or leg pain were found to have painful, weak gluteus medius muscles on examination. Not all of these people had tendon ruptures, but muscle strain versus tendinopathy versus tendon tear would seem to be a consideration. We are in the process of a more formal prevalence study of 150 consecutive patients. We hope to be able to describe this problem more completely in terms of diagnostic work-up as well as treatment.

REFERENCES

1. **Bewyer D, Bewyer K.** Rationale for treatment of hip abductor pain syndrome. *Iowa J Ortho.* Vol.23;57-60.
2. **Bird P, Oakley S, Shnier R, Kirkham B.** Prospective evaluation of magnetic resonance imaging

and physical examination inpatients with greater trochanteric pain syndrome. *Arth and Rheum*. Vol. 44, No. 9, Sept. 2001, 2138-45.

3. **Bunker T.** Rotator cuff tear of the hip. *J Bone Joint Surg*, Vol. 79-B, No. 4, July 1997, 618-20.
4. **Chung C, Robertson J, Cho G, Vaughan L, Copp S, Resnick D.** Gluteus medius tendon tears and avulsive injuries in elderly women: imaging findings in six patients. *Am J Roent.* 1999 Aug; 173(2):351-3.
5. **Connell D, Bass C, Sykes C, Young D, Edwards E.** Sonographic evaluation of gluteus medius and minimus tendinopathy. *Eur Radiol*. 2003 Jun;13(6):1339-47.
6. **Gabrion A. Vernois J. Havet E. Mertl P. de Lestang M.** Gluteus medius tendon tear and degenerative hip disease. *Revue de Chirurgie Orthopedique et Reparatrice de l Appareil Moteur.* 89(7):640-2, 2003 Nov.
7. **Hertel J. Sloss BR. Earl JE.** Effect of foot orthotics on quadriceps and gluteus medius electromyographic activity during selected exercises. *Archives of Physical Medicine & Rehabilitation*. 86(1):26-30, 2005 Jan.
8. **Honl M, Dierk O, Gauck C, Carrero V, Lampe F, Dries S, Quante M, Schwieger K, Hille E, Morlock M.** Comparison of robotic-assisted and manual implantation of a primary total hip replacement. A prospective study. *J Bone Joint Surg*. 2003 Aug;85-A(8):1470-8.
9. **Kagan A.** Rotator cuff tears of the hip. *Clin Ortho and Related Research.* 1999, No. 368:135-40.
10. **Kumagai M, et al.** Functional evaluation of hip abductor muscles with the use of magnetic resonance imaging. *J of Clin Research*. 15:888-93.
11. **LaBan MM. Weir SK. Taylor RS.** 'Bald trochanter' spontaneous rupture of the conjoined tendons of the gluteus medius and minimus presenting as a trochanteric bursitis. *American Journal of Physical Medicine & Rehabilitation*. 83(10):806-9, 2004 Oct.
12. **Lehman G, Lennon D, Tresidder B, Rayfield B, Poschar M.** Muscle recruitment patterns during the prone leg extension. *BMC Musculoskeletal Disorders*. Feb. 2004, 5(1):3.
13. **McConnell T, Tornetta P, Benson E, Manuel J.** Gluteus medius tendon injury during reaming for gamma nail insertion. *Clin Orthop Res*. 2003; Feb;(407):199-202.
14. **Ozcakar L. Erol O. Kaymak B. Aydemir N.** An underdiagnosed hip pathology: apropos of two cases with gluteus medius tendon tears. *Clinical Rheumatology*. 23(5):464-6, 2004 Oct.

BIGELOW'S WIRE TECHNIQUE FOR A HUMERAL SHAFT FRACTURE: BRIEF CASE REPORT AND HISTORICAL PERSPECTIVE

Twee Do, M.D., Mack Clayton, M.D.

ABSTRACT

An older technique of limited open reduction and wire fixation was applied in the treatment of an open transverse humeral shaft fracture in a 14-year-old female. The original operative technique by H. Bigelow is described.

INTRODUCTION

Fractures of the humerus have tremendous capacity to heal with closed treatment. Infrequently, however, operative treatment of humeral diaphyseal fractures may be required. Multiple methods of operative treatment are currently available in these situations, including open reduction internal fixation (ORIF) with dynamic compression plates (DCP), external fixation, and intramedullary (IM) stabilization. Another older method is lateral humeral tension band wiring, based on an idea advocated by Bigelow in 1867, for treatment of non-union in long bones.[1] This is a limited open procedure with minimal soft tissue stripping and good healing rates in non-unions of the humerus, radius and femur. We report here the use of this technique in a meromelic 14-year-old skeletally immature female with an open transverse right humerus fracture.

BIGELOW TECHNIQUE HISTORICAL DESCRIPTION

The humerus is approached laterally with a small single incision made through the skin and subcutaneous tissue down to the bone, avoiding the radial nerve by careful dissection. In the case of a non-union, the non-union site is often covered by fibrous tissue interspersed with callus that is subsequently debrided. With help from an assistant, the denuded ends of the non-union are flexed gently into view. The irregularities of the fracture fragments and inflamed tissues are removed. Minimal periosteal stripping over the area of bone to be excised (usually 1.5-2 cm) is undertaken. Tissue protectors are crucial in avoiding unnecessary local soft tissue injury as the roughened edges are finished with a straight cut using a mini saw. The length of bone resected determines the amount of periosteum that is stripped (usually 1.5-2 cm). A unicortical drill hole is then placed into the proximal fragment approximately 1.5 cm from the fractured end, and a #10 wire is passed through the drill hole into the intramedullary (IM) canal. The wire is then passed from the IM canal through another drill hole 1.5 cm from the fracture on the distal fragment, and the fractured ends are brought into apposition. The wire ends are then pulled slightly off the surface of the bone to compress the fracture site, are twisted tightly into place and buried. Wound closure is undertaken in a meticulous manner. Post-operatively, the humerus is placed in a concave coaptation splint with an axillary pad to increase the compression of the fracture site and immobilize the limb. The position of immobilization is at 90 degrees of flexion at the elbow with neutral rotation at the wrist. The post-operative splint is continued for several weeks until there are clinical signs of union. At that time, range of motion of the elbow and shoulder is initiated. The wire is left in place until clinical healing is complete and is only removed if irritation persists.

Figure 1. Pre-operative x-ray of a 14-year-old female with an open midshaft humerus fracture that is transverse and shortened.

Children's Hospital Medical Center
3333 Burnet Avenue, OSB-3
Cincinnati, Ohio

Correspondence:
Twee T. Do, MD
Children's Hospital Medical Center
3333 Burnet Avenue, OSB-3
Cincinnati, Ohio 45229
Ph (513) 636-4785
Fax (513) 636-3928
Twee.do@cchmc.org

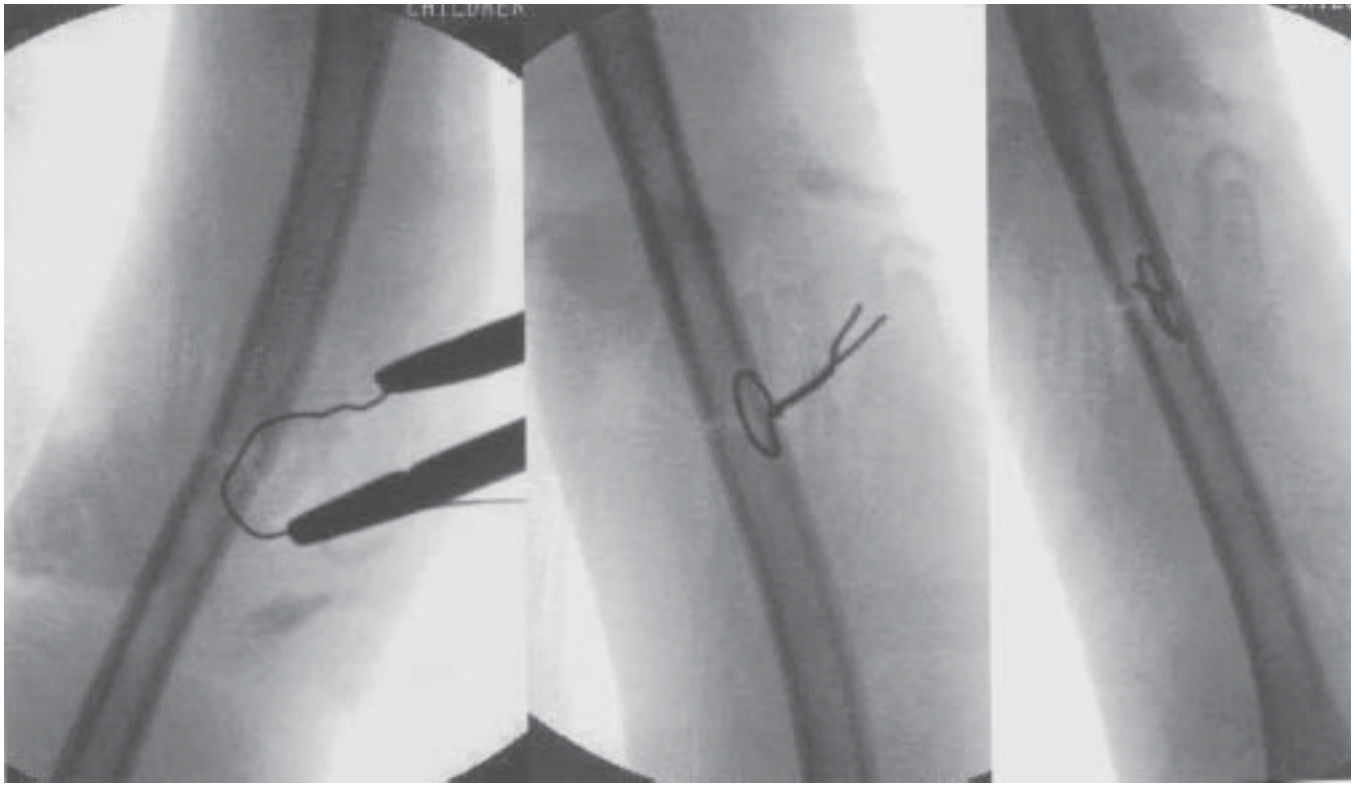

Figure 2. The technique of limited open reduction and wire fixation is demonstrated.

CASE REPORT

The patient is a 14-year-old female who was crossing the street when an oncoming car at moderate speed hit her. She had transient loss of consciousness but was easily aroused at the scene. Glascow coma score (GCS) was 15. Her injuries included abrasions over the right eye, periorbital edema with ecchymosis, Grade III liver laceration, diffuse pain localizations, and a grade I open midshaft humerus fracture of her right meromelic limb. Neurovascular status was completely intact.

She was evaluated by all services, and cleared for an irrigation and debridement of the open fracture within six hours of injury. The 1cm laceration was posteromedial, and was surgically extended by 1cm proximally and distally for complete exposure of the bone ends and thoroughly irrigated with saline under pulsatile lavage. It was a transverse midshaft fracture that could be manipulated with direct intraoperative pressure to maintain alignment (Figure 1). Because of the open fracture in an already shortened limb, it was decided to internally stabilize her fracture. A tension wire construct was chosen, and placed as lateral as possible using the technique closely approximating the fracture ends, as described by Bigelow[1] (Figure 2). Post-operatively, she was placed into a long arm cast.

Because of the posteromedial nature of the tension band, mild varus drift occurred in the loosened cast, but no shortening resulted (Figure 3). She also missed initial follow-up appointments. She was then placed into a functional brace until complete consolidation of the bone was appreciated (Figure 4). She was then released to regular activities. She only complained of mild irritation at the wire site because of her thin arm. The discomfort was not enough to want hardware removal. She is now active and able to carry out activities of daily living (Figure 5).

DISCUSSION

For isolated fractures of the humeral shaft, non-operative methods are the accepted form of treatment, especially in shaft fractures not associated with neurovascular injuries.[2] The majority of these fractures heal rapidly, without significant residual disability. The humeral functional brace further improves conservative closed treatment, providing effective stabilization while minimizing upper extremity joint stiffness associated with other immobilization techniques.[3] Surgical intervention in the acute setting is generally reserved for fractures with neurovascular injuries, open fractures, multiple fractures with associated ipsilateral extremity injuries, bilateral fractures and pathologic fractures.[4,5]

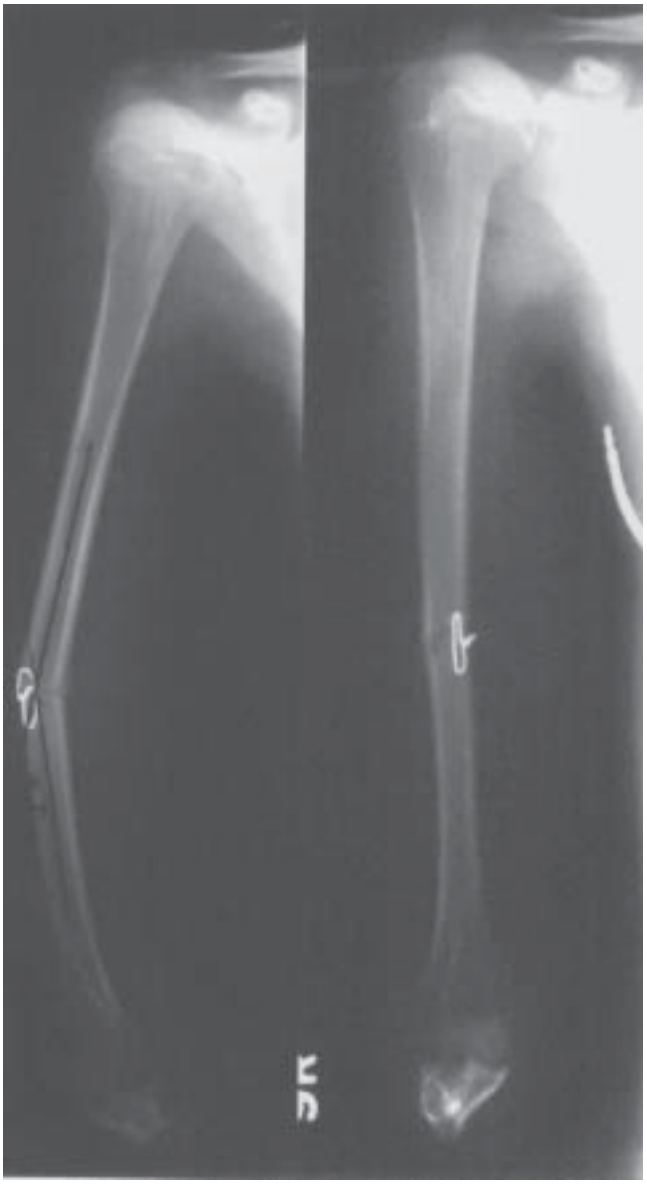

Figure 3. Because the wire was not directly lateral (due to the open laceration on the posteromedial humerus), direct tensioning effects could not be maintained with external immobilization and the fracture angulated at the next followup (left). The fracture was then manipulated in clinic and placed into a functional brace with good restoration of alignment (right).

In our current case, the open fracture was stabilized with the lateral wire after thorough irrigation and debridement. No further periosteal stripping was necessary to place the wire and the fracture remained more stable. She was able to mobilize the shoulder and elbow early (within four weeks).

In 1867, Bigelow first published a series of long-bone non-unions treated through this limited approach and insertion of a lateral longitudinal wire. This is essentially the first description of the modern tension-band wiring technique.[1] In his series of 11 non-united fractures (nine humeri, one radius and one femur), all healed except for one patient with a pathologic fracture who desired an above-elbow amputation five months after wire fixation. The success of Bigelow's technique is based on the understanding that delayed unions and non-unions are more probable to occur with more severe local soft tissue injury with altered vascularity. The Bigelow operative procedure, at the time of its inception, was successful at positively affecting healing because it involved minimal violation of soft tissue and periosteum, and provided bone-to-bone apposition as along as the extremity was further stabilized with an external post-operative splint.

Figure 4. Final radiograph taken at seven months after complete healing. No significant problems are encountered, except occasional mild irritation from the wire tips.

Another factor underlying Bigelow's successful procedure for non-unions resides in the inherent anatomy and biomechanics of the arm. The musculature around the humerus, including the powerful deltoid and pectoralis major, tends to place a varus deforming force on mid-diaphyseal fractures. With this lateral angulation, the medial side of the fracture experiences compres-

Figure 5. Clinical photographs showing the small incision and the excellent alignment of the limb.

sive forces, while strong tensile forces are created on the lateral side. By inserting a lateral wire on the convex side of the fracture, the wire directs an eccentric load on the bone and acts as a tension band. Consequently, the wire in this system absorbs all of the tensile forces and affects dynamic compression across the fracture site. Pauwels was one of the first authors to demonstrate the success of tension-band wiring in a series of fractures, osteotomies and pseudarthroses[6]. It has now become the standard of treatment in fractures of the patella[7] and olecranon,[8] areas where the inherent fracture stability is compromised by excessive tensile forces. Unlike the olecranon and patella, where normal range of motion further induces dynamic compression of the tension band, the humerus fracture relies on the muscular pull and support from an external splint to affect its compression.

Even in Bigelow's period, despite the lack of radiographs, antisepsis and antibiotics, ten out of 11 chronic non-unions healed in his series including a femur fracture. The only failure occurred in a patient with pathologic bone who did not allow sufficient time for complete union before desiring an amputation.

REFERENCES

1. **Bigelow, J:** Operations for ununited fractures. *Boston Medical and Surgical Journal*, pp. 259-88, 1867.
2. **Michiels, I; Broos, P; Gruweg, J:** The operative treatment of humeral shaft fractures. *Acta Chir Belg* 86(3):147-52, 1986.
3. **Zagorski, J; Latta, L; Zych, G; Finnieston, A:** Diaphyseal fractures of the humerus. Treatment with pre-fabricated braces. *JBJS* 70A(4):607-10, 1988.
4. **Nast-Kolb, D; Schweiberer, L:** Changes and progress in fracture treatment of the humeral shaft. *Orthopade* 18(3):208-13, 1989.
5. **Healy, W; White, G; Mick, C; Broker, A; Weiland, A:** Nonunion of the humeral shaft. *Clin Orthop* **(**219):206-13, 1987.
6. **Pauwels, F:** *Gesammelte abhandlungen zur funktionellen anatomie des bewegunsapparates.* Berlin-Heidelberg-New York. Springer 1965.
7. **Carpenter, J; Kasman, R; Matthews, L:** Fractures of the patella. *Instr Course Lect* (43):97-108, 1994.
8. **Hotchkiss, R; Green, D:** Fractures of the olecranon, in *Rockwood and Green's Fractures in Adults,* 3rd edition, pp. 795-805, 1991.

A CASE SERIES AND REVIEW OF SALVAGE SURGERY FOR REFRACTORY HUMERAL SHAFT NONUNION FOLLOWING TWO OR MORE PRIOR SURGICAL PROCEDURES

Todd A. Borus, M.D.[1], Edward H. Yian, M.D.[1] and Madhav A. Karunakar, M.D.[1]

ABSTRACT

The orthopedic surgery literature is replete with techniques for managing primary humeral shaft nonunions, with success rates upwards of 90 percent with plate fixation and autogenous bone grafting. Despite this success, persistent nonunion following one or more initial failed nonunion interventions can occur, imposing a significant clinical and surgical challenge. We report the application of a standard treatment protocol for refractory humeral shaft nonunions including optimization of patient co-morbidities in the peri-operative period, rigid 4.5mm compression plating with a minimum of eight cortices of fixation proximal and distal to the nonunion site, and utilization of autogenous bone grafting. This study, a retrospective review of seven patients, all managed based on this standard treatment protocol, revealed that all achieved fracture nonunion within six months of revision surgery. Six of seven patients were clinically satisfied with the outcome of surgery; one remained dissatisfied secondary to a chronic neuropathic pain syndrome. Although more complex surgical options such as Ilizarov external fixation and allograft cortical strut augmentation have been reported, and are available in the salvage situation of refractory humeral nonunions, we conclude strict application of basic nonunion principles can result in successful salvage of humerus nonunions in patients who have failed two or more prior surgical interventions.

Financial Disclosure: No funding or financial support was received related to the subject of this manuscript.

[1]Department of Orthopedic Surgery
University of Michigan
1500 E. Medical Center Drive
TC 2912 G
Ann Arbor, MI 48109-0328

Correspondence:
Madhav A. Karunakar, M.D.
1500 E. Medical Center Drive
TC 2912 G
Ann Arbor, MI 48109-0328
(734) 936-5690
e-mail: mkarun@med.umich.edu

INTRODUCTION

The incidence of nonunion after operative treatment of humeral shaft fractures has been reported to range between 2.5 and 13 percent.[1,2,3,4] Nonunions can result in significant patient morbidity by limiting activities of daily living secondary to pain and loss of function. Revision surgical management is indicated for treatment of nonunions following an initial failed surgical procedure. The literature is replete with studies outlining the various methods of treating humeral shaft nonunions following primary operative management[1,3,5,6,7,8,9,10,11,12,13,14,15,16,17] with success rates approaching 100 percent in achieving nonunion healing. Despite this success, no studies have focused specifically on the salvage of refractory nonunions after failure of one or more nonunion surgical interventions. The purpose of this study was to review a standard treatment protocol, including optimization of associated patient co-morbidities, rigid 4.5mm compression plating with at least eight cortices of fixation, and utilization of autologous bone grafting, in a select group of patients who had failed two or more operative procedures for a humeral shaft fracture (an index surgery and at least one additional nonunion intervention).

METHODS

Patient Selection

Following Institutional Review Board approval, eight consecutive patients who were referred to our institution between 1992-2001 with refractory humeral nonunions following failure of at least two prior surgical procedures, were retrospectively reviewed. One patient was excluded from the study because of incomplete/missing medical records. Seven patients fulfilled criteria to be entered in the study group.

All charts were reviewed from initial presentation to final follow-up for history and physical examination, operative reports, and all radiographs. Laboratory studies including complete blood count with differential, erythrocyte sedimentation rate (ESR) and C-reactive protein (CRP) were obtained to rule out infection. All patients presented with complaints of functional loss of the involved extremity due to pain and weakness and demonstrated radiographic evidence of humeral nonunion.

TABLE 1
Patient Demographics

Case No.	Sex	Age	Mechanism	Fracture Location	Co-morbidities	Time From Injury Until Definitive Procedure
1	F	69	Fall	Mid-shaft, closed	Diabetes, ipsilateral rotator cuff tear	31 months
2	M	36	MVA, polytrauma	Mid-shaft, closed	Smoker, ipsilateral above-knee amputation, ETOH	23 months
3	M	48	Fall	Mid-shaft, closed	Obesity	18 months
4	M	42	MVA, polytrauma	Mid-shaft, closed	Smoker, obesity	25 months
5	F	64	Fall	Mid-shaft, closed	Positive intra-operative cultures	54 months
6	F	42	Fall	Distal third	Mental retardation, smoker	22 months
7	F	61	Fall	Distal third	Diabetes, obesity	35 months

MVA—motor vehicle accident

The subjects (Tables 1 and 2) included four females and three males. Co-morbidities included smoking (2), polytrauma (2), obesity (3), diabetes mellitus (2), ipsilateral above-knee amputation (1) and mental retardation (1). The average age of the patients was 52 years (range 36-69). The average time interval between the initial procedure and definitive procedure was 29 months (range 18-54). An average of 2.3 (range 2-3) procedures had been performed on each patient prior to the final procedure. Fracture types included two transverse, four short oblique, and two long oblique. Two fractures were comminuted. All fractures were closed. There were five middle-third, and two extra-articular distal-third humeral fractures. The original mechanism of injury was a fall in five patients, and motor vehicle accident in two patients.

The initial operative indication was failure of closed treatment in four patients, polytrauma in two patients, and obesity in one patient. Initial operative procedures included open reduction and internal fixation with plate-and-screw fixation in four patients and intramedullary (IM) fixation in three patients. Secondary procedures consisted of revision open reduction and internal fixation (3), exchange intramedullary nailing (2), removal of intramedullary nail with open reduction and internal fixation (2), removal of internal fixation with external fixator placement (1) and internal bone stimulator implantation (1). Two patients received external bone stimulators.

All seven patients had persistent nonunions classified as atrophic. Four of the seven patients underwent autogenous bone grafting to the fracture site during at least one prior surgical procedure. Complications from prior management reported at presentation included radial nerve palsy in two patients, one of which was resolving and the other requiring a dynamic glove for support.

Surgical Management

Prior to undertaking revision surgery, patient co-morbidities were addressed. Within this study population, this included mandating smoking cessation (two patients) and optimizing medical management of diabetes mellitus (two patients). The operative approach selected for the revision procedure was based on prior skin incisions and the surgical approach necessary to remove hardware and expose the nonunion site. Four patients had undergone a prior posterior approach and three an anterolateral approach. The previously implanted hardware was removed in all patients, including an antegrade intramedullary nail in one patient and an external fixator in one patient. The radial nerve was identified and protected for the duration of the procedure. The intramedullary canal was reconstituted with a drill and bone ends were contoured to provide adequate diaphyseal contact. Tissue samples were sent to the microbiology lab for routine cultures. Compressive plating techniques with 4.5mm DCP plates were utilized and autogenous iliac crest bone graft was placed at the nonunion site. A minimum of eight cortices of fixation above and below the fracture site were obtained in all cases. If adequate cortical fixation could not be achieved, additional methods of fixation were utilized. Dual plating techniques were performed in (short-segment) distal fractures to obtain eight cortices of fixation of the distal fragment. Dual plating was also performed if any residual motion was detected at the nonunion site after primary plate fixation, to provide enhanced stability. With dual plating, one plate was positioned posteriorly, while the other was positioned either on the medial or lateral surface to create an orthogonal construct. In one patient with osteoporotic bone, methylmethacrylate was used to augment fixation.

TABLE 2
Surgical Information

Case Number	Number of Surgical Procedures Prior to Definitive Procedure	Initial Surgical Procedure, subsequent failed procedures	Implant Prior To Definitive Surgical Procedure	Bone Graft Utilized on prior procedures	Final Implant
1	2	ORIF, revision ORIF	8 hole narrow 4.5 DCP	Autograft	10-hole narrow 4.5 DCP
2	2	ORIF, revision ORIF	9 hole broad 4.5 DCP, 7 hole 3.5 LCDCP	Autograft	9-hole broad 4.5 DCP, 1 interfrag screw
3	2	ORIF, revision ORIF	6 hole narrow 4.5 DCP, 5 hole 3.5 LCDCP	Autograft	12-hole broad 4.5 DCP
4	2	IMN, exchange IMN	Antegrade Locked IMN,	None	8-hole narrow 4.5 DCP
5	3	IMN, exchange IMN, ORIF	7 hole 4.5 DCP .	None	8-hole 4.5 DCP, 7-hole 3.5 LCDCP with methylmethcralate screw augmentation
6	2	ORIF, HWR with External Fixator Placement	External Fixator	Autograft	8-hole 4.5 DCP, 7 hole 3.5 LCDCP
7	3	Rush Rod, HWR and ORIF, placement of internal bone stimulator	12 hole narrow peri-articular distal humerus plate	None	8-hole 4.5 DCP

ORIF—open reduction and internal fixation; IMN—intramedullary nail; HWR—hardware removal; DCP—dynamic compression plate; LCDCP—limited contact dynamic compression plate

Postoperatively, patients were placed in a sling for comfort for two weeks. Early gentle pendulum and active assisted shoulder and elbow range of motion were started within two weeks of surgery. Progression to strengthening and passive range of motion exercises was instituted after radiographic evidence of union.

At final follow-up, clinical outcome was assessed by active range of motion of the shoulder and elbow and the presence or absence of pain in the extremity when conducting activities of daily living. Patients were asked if they were satisfied with the outcome of the final surgical intervention and the level of their satisfaction. Union was determined by radiographic evidence of cortical bone bridging at the nonunion, stable hardware position on radiographs, as well as absence of pain with manual palpation of the nonunion site.

RESULTS

All patients had normal preoperative laboratory studies. All patients had negative intraoperative tissue gram stains. Operative cultures revealed rare amounts of coagulase-negative Staphylococcus in one patient, who was treated with six weeks of intravenous vancomycin resulting in uneventful healing. The average number of cortices with screw fixation was 8.5 following the definitive surgical procedure. Six of seven patients showed evidence of complete healing as defined by radiographic evidence of at least three out of four bridging cortices within three months of the revision procedure. One patient demonstrated clear bridging of two of four cortices with stable hardware position over a period of over nine months at final follow-up. Additionally, he was nontender over the fracture site with manual stress applied to the humerus, and therefore he was considered clinically healed. No new radial nerve palsies resulted from revision open reduction and internal fixation.

At final follow-up (Table 3), shoulder and elbow function was full (symmetric to the contralateral side) in five of seven patients. One patient who only regained 90 degrees of active shoulder forward flexion had an ipsilateral rotator cuff tear at the time of her initial surgical procedure at an outside institution that was repaired during that procedure. Despite the repair and active physical therapy, she never regained full shoulder motion. Another patient presented with 130 degrees of active forward flexion of the shoulder and a ten-degree elbow flexion contracture prior to definitive surgical intervention. Range of motion was not regained after surgery.

Six of seven patients reported that they were either very satisfied or satisfied with the outcome the revision nonunion surgery. One patient was dissatisfied. His initial humerus fracture resulted from a polytrauma motor vehicle accident in which he sustained a closed head injury and multiple other long bone injuries. He also had a history of a contralateral traumatic above-knee amputation from a previous trauma. Despite meeting criteria for humeral union after his revision procedure, he continued to complain of a vague, ill-defined pain in his upper arm that was not localized to a specific location or nerve distribution. He was diagnosed with a neuropathic pain syndrome and is currently being managed by a multidisciplinary pain clinic.

TABLE 3
Patient Outcomes

Case Number	Clinically and radiographically healed at 6 months?	Shoulder Function/ AROM	Elbow Function/ AROM	Patient Satisfaction
1	Yes	90 forward flexion	Full	Very Satisfied
2	Yes	Full	Full	Not Satisfied
3	Yes	Full	Full	Very Satisfied
4	Yes	Full	Full	Very Satisfied
5	Yes	Full	Full	Very Satisfied
6	Yes	Full	Full	Satisfied
7	Yes	130 forward flexion	10 flexion contracture	Satisfied

AROM – active range of motion

DISCUSSION

The surgical techniques required to successfully treat humeral shaft nonunions following initial operative management have been well described. The most commonly described techniques include exchange nailing following failed primary IM nailing[11,17] and open reduction and internal fixation with a dynamic compression plate and autogenous bone graft.[1,3,4,5,10,14,15] Considered the gold standard, the success rate reported using compression plating with a 4.5mm plate and autogenous bone grafting has been reported to be greater that 90 percent.[3,4,5,10,14,15] The most commonly reported cause of failure of operative treatment of primary humeral shaft fractures is inadequate internal fixation.[1,3,5,10,18,19] However, the recommendations for optimal fixation in both the primary fracture and nonunion settings are varied, ranging from six to ten cortices.[1,3,4,10,14,19,20,21]

Although various investigators have reported on the treatment of primary humeral diaphysis nonunions, few papers have focused exclusively on revision procedures for salvaging refractory nonunions following a failed initial nonunion intervention. Several papers have focused on complex surgical techniques for managing persistent nonunion following two or more surgical interventions. Hornicek et al described the successful use of cortical allograft bone plates or struts in conjunction with internal fixation by metal plates to achieve healing in six patients with diffuse osteopenia and refractory nonunion following two failed surgical procedures.[8] Patel utilized an Ilizarov circular external fixator in 16 patients averaging 2.6 previous surgeries to achieve union in 15 of the 16 cases.[13] Other authors have obtained successful results with an operative protocol similar to the present study. Marti recently reported a series of 51 patients with humeral diaphyseal nonunions, ten of which had undergone at least two prior surgical procedures prior to authors' intervention.[10] These patients underwent uniform surgical repair with decortication, 4.5mm compression plating (with a minimum of six cortices of fixation proximal and distal to the fracture site), and application of autogenous bone grafting. All nonunions demonstrated consolidation at one year with 96 percent excellent or good shoulder and elbow function. Although this series does include patients with multiple previous operative failures, it is a mixed population that includes failure of nonoperative management, or one or more previous procedures. The specifics of treatment in the multiple failure subset population are not discussed.

Within the present series, seven patients who failed at least two prior surgical interventions of a humeral shaft fracture underwent successful salvage of the persistent nonunion with a standard protocol that included rigid fixation with a 4.5mm DCP plate and a minimum of eight cortices of fixation on each side of the fracture, application of autogenous bone graft, and optimization of associated patient co-morbidities in the perioperative period. Adjunctive fixation techniques including dual plating (two cases) in distal fractures and methylmethacralate screw augmentation (one case) were utilized. All seven patients achieved clinical and radiographic union within six months, although one patient remained clinically dissatisfied secondary to a designated chronic pain syndrome.

With regard to our treatment protocol, although some authors have achieved success in the treatment of primary humeral shaft nonunions with a guideline of six cortices of fixation at each side of the nonunion site, we believe that in the salvage situation of multiple failed previous procedures, a minimum of eight, and possibly ten, cortices of fixation should be obtained. There are likely several reasons that the amount of fixation required to stabilize a nonunion (and especially a persistent nonunion) differs from that required for stabilization of an acute fracture. The surgical technique for nonunion surgery requires more extensive dissection, debridement of the fibrous nonunion tissue and shortening to bleeding bone. This frequently results in contoured bone ends that do not provide the same contact and stability as seen in acute fractures. Longer healing times are also common, requiring the implants to tolerate more stress for a longer period of time. In order to achieve the minimum of eight cortices of fixation, adjunctive techniques including dual plating were employed if necessary.[12,14,15,21]

Our standardized treatment protocol also re-emphasizes the importance of autogenous bone grafting during revision nonunion surgery, especially in the case of atrophic nonunions. The importance of autogenous

bone grafting has been reported previously and should be considered a standard adjunct to the surgical treatment of these nonunions.[3,4,7,10,15,20]

In addition to surgical factors, standard treatment of refractory humeral shaft nonunions in this series included the assessment and management of patient co-morbidities which may impair bone healing. Smoking has been implicated as a specific risk factor for humeral nonunion.[9] Similarly, others have found alcohol to be a risk factor for humeral nonunion based on a proposed mechanism of both physiologic (malnutrition, peripheral vascular impairment) and behavioral (noncompliance) mechanisms.[2] Smoking and alcohol cessation were mandatory before the definitive procedure. Although diabetes mellitus has not been demonstrated to be a specific risk factor for humeral shaft nonunion, several studies have demonstrated its impact on bone healing.[22] Before performing definitive surgery in diabetic patients, attention was given to medically optimizing blood glucose control and hemoglobin A1c levels. We believe that prior to undertaking a salvage procedure for refractory humeral nonunion, patient co-morbidities should be addressed, when possible.

Because of the retrospective nature of this series, there are limitations regarding the analysis that can be made about the causes of the multiple failures prior to definitive management. Possible contributing factors include: a combination of inadequate fixation (lack of six cortices of fixation on each side of the fracture site or utilization of a plate with inadequate mechanical strength), fracture distraction (antegrade IM nail or external fixation), or lack of autogenous bone grafting at the initial nonunion procedure. Moreover, tobacco and alcohol abuse cessation, as well as diabetes control, had not been optimized in certain patients. One patient, however, did meet all criteria of our treatment protocol at the time of her initial nonunion surgery, yet failed to achieve union. More specifically, prior to revision surgery she had no readily identifiable co-morbidities, and surgical data from an outside institution revealed eight cortices of screw fixation on both sides of the nonunion site with utilization of autograft. As the surgery did take place at an outside institution, however, we are unable to fully evaluate the intricacies of the surgical technique performed, such as whether adequate debridement, re-cannulization of the intramedullary canal, and decortication at the nonunion site were performed. At the definitive procedure, a longer plate with ten cortices of fixation was placed with repeat application of autograft. Nonunion healing ensued. Although more complex surgical procedures remained an option in this patient, revision surgery with application of standard nonunion principles proved successful.

In summary, although specialized techniques such as Ilizarov circular external fixators and utilization of cortical allograft strut augmentation provide additional surgical fixation options in the salvage of refractory humeral shaft nonunions following failure of two or more prior surgical interventions, a standard revision operative protocol of 4.5mm DCP plating with at least eight cortices of fixation and autogenous bone grafting, as well as optimization of patient co-morbidities, led to a high rate of union and significant improvements in patient function and outcome. These techniques can lead to bone healing in the revision setting even after multiple fixation attempts, including previous intramedullary nailing, intramedullary nail exchange or plate and screw fixation.

REFERENCES

1. **Foster RJ, Dixon GL, Bach AW, Appleyard RW, Green TM:** Internal fixation of fractures and nonunions of the humeral shaft. *J Bone Joint Surg* (Am) 1985;67(A): 857-865.
2. **Foulk DA, Szabo RM:** Diaphyseal humerus fractures: Natural history and occurrence of nonunion. *Orthopaedics* 1995;18: 333-335.
3. **Healy WL, White GM, Mick CA, Brooker AF, Weiland AJ:** Nonunion of the humeral shaft. *Clin Orthop* 1987; 219:206-213.
4. **Rosen H:** The treatment of nonunions and pseudoarthroses of the humeral shaft. *Orthop Clin North America* 1990;21:725-42.
5. **Ackerman G and Jupiter J:** Nonunions of fractures of the distal end of the humerus. *J Bone Joint Surg* (Am) 1988;70(A):75-83.
6. **Crosby LA, Norris BL, Dao KD, McGuire MH:** Humeral shaft nonunions treated with fibular allograft and compression plating. *Am J Orthop* 2000;29(1): 45-47.
7. **Gerber A, Marti R, Jupiter J:** Surgical management of diaphyseal humeral nonunion after intramedullary nailing: Wave-plate fixation and autologous bone grafting without nail removal. *J Shoulder Elbow Surg* 2003;12(4): 309-313.
8. **Hornicek FJ, Zych GA, Hutson JJ, Malinin TI:** Salvage of humeral nonunion with onlay bone plate allograft augmentation. *Clin Orthop* 2001;386: 203-209.
9. **Lammens J, Baudin G, Driesen R, et al:** Treatment of nonunion of the humerus using the Ilizarov external fixator. *Clin Orthop* 1998;353: 223-230.
10. **Marti RK, Verheyen CC, Besselaar PP:** Humeral shaft nonunion: Evaluation of a uniform surgical repair in fifty-one patients. *J Orthop Trauma* 2002;16: 108-115.

11. **McKee MD, Miranda MA, Riemer BL, et al:** Management of humeral nonunion after the failure of locking intramedullary nails. *J Orthop Trauma* 1996;10: 492-499.
12. **Murray WR, Lucas DB, Inman VT:** Treatment of nonunion of fractures of the long bones by the two-plate method. *J Bone Joint Surg* (Am) 1964;46(A): 1027-1048.
13. **Patel VR, Menon DK, Pool RD, Simonis RB:** Nonunion of the humerus after failure of surgical management. *J Bone Joint Surg* (Br) 2000;82(B): 997-983.
14. **Ring D, Perey BH, Jupiter JB:** The functional outcome of operative treatment of ununited fractures of the humeral diaphysis in older patients. *J Bone Joint Surg* (Am) 1999;81(A): 177-190.
15. **Trotter DH and Dobozi W:** Nonunions of the humerus: Rigid fixation, bone grafting, and adjuvant bone cement. *Clin Orthop*. 1986;204: 162-168.
16. **Wright TW, Miller GJ, Vander Griend RA, Wheeler D, Pell PC:** Reconstruction of the humerus with an intramedullary fibular graft. A clinical and biomechanical study. *J Bone Joint Surg* (Br) 1993;75: 804-807.
17. **Flinkkila T, Ristiniemi J, Hamalainen M:** Nonunion after intramedullary nailing of humeral shaft fractures. *J Trauma* 2001;50(3): 540-544.
18. **Boyd HB, Lipinski SW, Wiley JH:** Observations on nonunion of the shafts of the long bones, with a statistical analysis of 842 patients. *J Bone Joint Surg* (Am) 1961;43(A): 159-168.
19. **Heim D, Herket F, Hess P, Regazzoni P:** Surgical treatment of humeral shaft fractures – The Basel experience. *J Trauma* 1993;35(2): 226-232.
20. **Jupiter JB, von Deck M:** Ununited humeral diaphyses. *J Shoulder Elbow Surg* 1998;7(6): 644-653.
21. **Rubel I, Kloen P, Campbell D, et al:** Open reduction and internal fixation of humeral nonunions. *J Bone Joint Surg* (Am) 2002;84(A):1315-1322..
22. **Frey C, Halikus NM, Vu-Rose T, Ebramzadeh:** A review of ankle arthrodesis: Predisposing factors to nonunion. *Foot Ankle Int* 1994;15: 581-84.

NORMAL LEG COMPARTMENT PRESSURES IN ADULT NIGERIANS USING THE WHITESIDES METHOD

Johnson D Ogunlusi FMCS (Ortho),[1] Lawrence M Oginni FMCS, FWACS,[1,2]
Innocent C Ikem FMCS (Ortho),FICS[1,2]

ABSTRACT

In Caucasians, the range of normal intracompartmental pressure of the leg is from 0 mmHg to15 mmHg. In the literature, such measurements have not been done in Africa to identify normal leg intracompartmental pressures. We have sought to identify the normal range of pressures in such a population of Nigerians, and to demonstrate the reproducibility of the Whitesides injection technique with materials that are easily available in most hospitals so that compartment syndromes could be identified promptly and inexpensively in developing countries. We performed a 16-month hospital-based prospective study at Wesley Guild Hospital in Ilesa, Osun State, Nigeria, to measure the intracompartmental pressures in the anterior and deep posterior compartments of 49 contralateral uninjured legs of patients with closed contralateral tibial fractures, measured at presentation. The Whitesides infusion technique was used with the aim of determining the normal range of compartmental pressure in Nigerians. The anterior compartment pressures ranged from 3 mmHg to 18 mmHg with a mean 7.6 ± 2.6 mmHg. The pressure in the deep posterior compartment ranged from 3 mmHg to 14 mmHg with mean of 7.4 ± 2.7 mmHg. The values are similar to those reported in the literature. There was no statistically significant difference between the pressures in the two compartments (p = 0.668).

[1]Department of Orthopaedics and Traumatology
Obafemi Awolowo University
Teaching Hospitals Complex
Ile-Ife, Nigeria

[2]Department of Orthopaedics Surgery and Traumatology,
College of Health Sciences
Obafemi Awolowo University
Ile-Ife, Nigeria

Correspondence:
Dr JD Ogunlusi
C/o Dr L M Oginni
Department of Orthopaedics Surgery and Traumatology
College of Health Sciences, Obafemi Awolowo University
Ile-Ife, Osun State, Nigeria
Phone No: 234-80-553-36026
234-80-339-35176
Telefax: 234-362-30141
E mail: gbemidare@yahoo.com

INTRODUCTION

The fascial compartments of the limbs have unyielding walls and contain compressible neurovascular structures.[1] The leg has four compartments—anterior, lateral, superficial posterior and deep posterior.[2] Among Caucasians, both experimental and clinical experience has demonstrated that normal tissue pressures within closed compartments range between 0 to 15 mmHg.[3,4,5,6,7,8]

The objective of this work was to determine the average normal compartmental pressure in the legs of Nigerians using the simple pressure-measuring devices advocated with Whitesides.[9]

METHODS

This was a prospective hospital-based study of the measurement of compartmental pressure in the legs of adults that presented at the Wesley Guild Hospital (WGH). The WGH is located in Ilesa in the southwestern part of Nigeria within a major road network linking various parts of Nigeria. The hospital serves part of Osun state and is a referral center to the states of Ekiti, Ondo and part of Edo. Approval was obtained from the Obafemi Awolowo University Teaching Hospitals, Research and Ethical Committee.

Consecutive adult patients who were aged 16 years and above presented to the Accident and Emergency Department of WGH over a course of 16 months with unilateral closed tibial fractures. In fully resuscitated patients, consent was obtained for the measurement of normal compartmental pressures of both anterior and deep posterior compartments of contralateral uninjured legs of 49 patients with closed tibial fractures.

Excluded from the study were patients with soft tissue injury to the contralateral site of the fractured tibia. The measurement was done using the Whitesides' technique.[9] The procedure was carried out under aseptic conditions with the patient supine.

The data obtained was analyzed with Statgraphic software package version 5.0 (Statistical Graphics Corp. Inc., Rockville, MD). An average of two readings for each compartment was taken and presented in the frequency table (Table 1).

TABLE 1
Frequency distribution of compartmental pressure in adult Nigerian legs

Compartmental pressure (mm/Hg)	Frequency for Anterior Compartment	Frequency for deep posterior compartment
3	1	2
4	5	6
6	14	15
7	2	3
8	15	11
9	1	1
10	7	5
11	1	0
12	2	3
13	0	1
14	0	2
18	1	0
TOTAL	**49**	**49**

RESULTS

Over a sixteen-month study, 151 patients with tibial fractures were treated at the Wesley Guild Hospital Ilesa. Forty-nine had unilateral closed tibial fractures. There were 34 males (69.4%), and 15 females (30.6%) (M:F = 2.3:1).

The anterior compartmental pressure in the uninjured legs ranged between 3 mmHg and 18 mmHg with a mean of 7.6 ± 2.6 mmHg. The deep posterior compartmental pressure was 7.4 ± 2.7 mmHg with a range of 3-14 mmHg. The frequency distribution of the compartmental pressure in anterior and deep posterior compartments is shown in Table I.

There was no statistically significant difference between the anterior and the deep posterior compartments (p = 0.668). Using Spearman correlation coefficient, there was correlation between the measured anterior and deep posterior compartmental pressures (r = 0.36, p = 0.014).

DISCUSSION

Since the first reported measurement of compartment tissue pressures by Landerer in 1884, many measurements done with different measurement techniques have been used to measure intracompartmental pressure.[8] In this study, the simple Whitesides injection technique was used. Literature provides no data as to what constitutes the range of normal intracompartmental pressure in a West African patient population, although we hypothesized that they would be similar to data in Caucasian patients. The results obtained from this study are, in fact, similar to normal compartmental pressures obtained in six patients by McDermott in Halifax, Canada, who found the normal supine intracompartmental pressures using Solid-state Transducer Intracompartment Catheter (STIC) to be 7 ± 2 mmHg.[4] The San Diego group reported that this value is less than 10 mmHg.[3,5,6] Puranen reported an average compartmental pressure of 15 mmHg as the upper limit of normal.[7] Matsen found the anterior compartmental pressure to be 11.5 ± 0.5mmHg in seven normal limbs.[8] The intracompartmental pressures measured in seven patients in the studies done in Halifax and six patients in Washington are comparable to those in our 49 Nigerian patients in this study. Even though sophisticated and more modern equipment was used in determining the intracompartmental pressure in most of these other studies, the values obtained in this study using a simple Whitesides infusion method fall within the previously reported range. Also, larger numbers of patients were studied in our group than the six or seven in the previously mentioned studies. Concerns have been raised that the Whitesides method could generate falsely high pressure readings[10], but Clayton evaluated this injection technique by applying known pressures to the extremities of six rabbits with a pneumatic cuff, showing a good linear correlation with a slope of 1.03 (r =0.99)[11] The advantage of the Whitesides injection technique is that it uses materials that are easily available in most hospitals, and this technique can be used in developing countries to promptly detect compartmental syndrome.

REFERENCES

1. **Moore KL.** The Lower Limb. In *Clinically Oriented Anatomy 3rd edition*. Baltimore, Williams & Wilkins; 1992;443- 460.
2. **Pellegrini VD Jr, Reid S, Evants CM.** Complication, Compartment Syndrome. In: *Rockwood and Green, eds, Fractures in Adults, Volume 1, 4th edition*. Philadelphia, Lippincott-Raven, 1996;487-511.
3. **Mubarak SJ, Owen CA, Hargens AR, Garetto LP and Akenson WH.** Acute compartment syndrome diagnosis and treatment with the aid of the wick catheter. *J Bone Joint Surg* [Am] 1978 Dec;60-A(8):1091–1095.
4. **Mcdermott AGP, Marble AE, Yabsley RH.** Monitoring acute compartment pressure with the S.T.I.C. catheter. *Clin Orthop* 1984;190:192-198.
5. **Hargens A R, Romine JS, Spice JC, Evans KL, Mubarak SJ, Akenson WH.** Peripheral nerve conduction block by high muscular compartment pressure. *J Bone Joint Surg* [Am] 1979;61-A:192-200.
6. **Mubarak SJ, Hergens AR, Owen CA, Garetto LP, Akenson WH.** The Wick catheter technique of measurement of intramuscular pressure: A new research and clinical tool. *J Bone Joint Surg* [Am] 1976;58-A:1016-1020.

7. **Puranen J.** The medial tibial syndrome in the medial fascial compartment of the leg. *J Bone Joint Surg* [Br] 1974;56-B(4):712-715.
8. **Masten FA, Mayo KA, Sheridan GW et al.** Monitoring of intramuscular pressure. *Surgery,*1976 Jun;76 (6):702-709
9. **Whitesides TE Jr, Haney TC, Morimoto K, Harada K.** Tissue pressure measurement as a determinant for the need of fasciotomy. *Clin Orthop* 1975;113:43-51.
10. **Elliott KGB, Johnstone AJ.** Diagnosing acute compartment syndrome. *J Bone Joint Surg* [Br] 2003;85-B(5):625-632.
11. **Clayton JM, Hayes AC, Barnes RW.** Tissue pressure in perfusion in compartment syndrome. *J Surg Res* 1977;22:333-339.

SCAPHOLUNATE INSTABILITY FOLLOWING DORSAL WRIST GANGLION EXCISION: A CASE REPORT

Hossein Mehdian, M.D.[1]; Michael D. McKee, M.D., F.R.C.S.(C)[2]

INTRODUCTION

Ganglions on the dorsum of the wrist have been shown to originate from the scapholunate joint, often with direct attachment to the scapholunate interosseous ligament (SLIL).[1] It has long been recognized that non-surgical techniques for the treatment of dorsal wrist ganglia are unreliable with a high recurrence rate. Surgical intervention is often necessary. It has been recommended that surgical excision of the ganglion should be accompanied by excision of a small cuff of surrounding dorsal joint capsule, and removal of all attachments of the ganglion to the SLIL that are thought to minimize recurrence rate.[1,2] While excision of the dorsal carpal ganglion is a common operation performed on the wrist, carpal instability is rarely considered a complication of this surgery.

We present a case here of scapholunate instability occurring following excision of a dorsal wrist ganglion in a young patient. Surgeons should be aware of this complication. Obtaining preoperative radiographs of the wrist, not performed in this case prior to ganglionectomy, may help to rule out any pre-existing abnormality of the scapholunate joint.

[1]Clinical Fellow in Orthopaedics
Division of Orthopaedics
Department of Surgery
Upper Extremity Reconstructive Service
St. Michael's Hospital and the University of Toronto
Toronto, Ontario, Canada

[2]Associate Professor of Orthopaedics
Division of Orthopaedics
Department of Surgery
Upper Extremity Reconstructive Service
St. Michael's Hospital and the University of Toronto
Toronto, Ontario, Canada

Correspondence:
Michael D. McKee, M.D.
Suite 800, 55 Queen Street East
Toronto, Ontario, Canada,
M5C 1R6
mckee@the-wire.com
(416)864-5880
(416)359-1601 (fax)

CASE REPORT

A 23-year-old male environmental worker presented with a six-month history of a left dorsal wrist ganglion. He gave no history of pain or trauma, or any symptoms in his wrist aside from the general appearance of the wrist mass. He sought surgical removal of the dorsal ganglion. He underwent ganglionectomy at another center in June 1997, with an uneventful post-operative course. Three weeks after the operation, while he was playing table hockey, he had a mild twisting injury and experienced a painful pop in his wrist. Following this minor injury, he felt something move spontaneously in his wrist. He was seen by his hand surgeon, and was immediately referred to our center for further evaluation and treatment.

Active motion of the wrist was painful and accompanied by a click. A transverse well-healed scar was apparent on the dorsum of the wrist, with mild swelling and tenderness on the scapholunate joint. The range of motion of the wrist was limited, with dorsiflexion of 15° and palmar flexion of 60°. Pronation and supination of the forearm were within normal limits. The scapholunate ballottement test showed abnormal motion between the scaphoid and lunate bones, and was accompanied by pain at the scapholunate joint. The Watson test (scaphoid shift test) was painful and showed dorsal scaphoid displacement. The grip strength of his injured hand was one-third of the strength of the other hand. Radiographs of his left wrist showed evidence of scapholunate instability with a scapholunate interval of 15 mm, marked dorsal intercalated segment instability (DISI) deformity, a scapholunate angle of 110° and decreased carpal height (Figure 1).

He was subsequently treated with open reduction and ligamentous repair. This was performed one month after his ganglionectomy. Through a dorsal longitudinal incision, a Z-cut was made in the extensor retinaculum and the retinaculum was preserved for later reconstruction. The wrist capsule was approached between the third (extensor pollicis longus) and fourth (extensor digitorum communis) extensor compartments. A small rent was seen in the dorsal capsule from which synovium was expressed. A capsulotomy was performed

Figure 1a.

Figure 1b.

Figure 1. Anteroposterior (a) and lateral (b) radiographs of the wrist, 4 weeks after ganglionectomy following trivial injury to the wrist.

just distal to the insertion of the capsule onto the distal radius. Following capsular retraction, carpal malalignment was clearly evident. The scapholunate interosseous ligament (SLIL) appeared to be completely disrupted with only minimal remnants left behind, rendering primary repair impossible.

Therefore, the surface of the scaphoid and lunate were roughened, and following exact reduction of the scapholunate joint, three Kirschner wires were inserted to maintain the reduction (Figure 2). The capsule, retinaculum and skin were subsequently repaired and the

Figure 2. Anteroposterior (a) and lateral (b) radiographs of the wrist following open scapholunate reduction and fixation.

wrist was immobilized in mild flexion. Six weeks later, the cast was removed and limited wrist motion was allowed in a removable splint. The pins were removed ten weeks after their insertion and range of motion exercises were prescribed. Radiographs obtained six months after the operation (Figure 3) showed normal scapholunate alignment.

A year after surgery, he complained of no pain and was completely satisfied with his operation and resumed all his previous activities. Physical examination of the wrist showed a stable carpus with a negative Watson test and no tenderness on the scapholunate joint. The range of motion of the wrist was normal, with grip strength of 76% compared to the contralateral normal hand.

DISCUSSION

Watson[3] reported 25 patients with scapholunate instability following ganglion excision. Eight were found to have static instability, while the other 17 had either dynamic instability with a positive Watson test, or isolated arthritis of the scaphotrapeziotrapezoidal (STT) joint on the radiographs (felt to be indirect evidence of scapholunate instability). Apart from this striking report, there have only been three other case reports documenting this in the literature. Clay and Clement[4] evaluated 62 dorsal wrist ganglia following excision, and detected one case of scapholunate instability in their patients. Duncan[5] reported the occurrence of

Figure 3. Anteroposterior (a) and lateral (b) radiographs of the wrist three months after open reduction and internal fixation of the scapholunate joint.

scapholunate instability following a minor twisting injury in a patient who had had his ganglion removed four months before this event. Finally, Crawford and Taleisnik[6] reported a rotatory subluxation of the scaphoid after excision of a dorsal carpal ganglion and wrist manipulation. Apparently, the wrist in that case report was manipulated post-ganglionectomy to regain the loss of motion. The authors attributed the instability to the trauma imposed on the wrist during manipulation. In contrast, Kivett et al.[7] found no case of scapholunate instability after having evaluated the post-operative results in 91 ganglion excisions.

While it has been suggested that scapholunate instability occurs only after injury to the SLIL and radioscapholunate ligaments (a magnitude of injury unlikely following routine ganglion excision), anatomical studies[8] have revealed that the SLIL is the primary stabilizer of this joint. The relatively high tensile strength of the SLIL suggests the important role of this ligament in carpal kinematics. The SLIL has three distinct anatomical portions, of which the dorsal portion is considered the strongest,[8] and is considered by Kauer,[9] Ruby, and Linsheid[10] to be the major stabilizer of the proximal scaphoid. They have shown experimentally that sectioning of the dorsal portion of this ligament, as can occur in radical ganglion excision, can create scapholunate instability in the wrist.

Although our present case had no radiographs before ganglion excision to document the status of the scapholunate interval, the absence of symptoms (except for the ganglion mass itself) before ganglion removal suggests a normal SLIL pre-ganglionectomy. The trivial injury to the wrist post-operatively while playing table hockey, and the brief interval between the ganglionectomy and the appearance of scapholunate instability suggest an iatrogenic primary cause for this instability complication. It is remotely possible that underlying myxoid degeneration of the periarticular wrist connective tissue could have pre-existed, thus pre-disposing to the formation of dorsal wrist ganglia. In that setting, of a possibly degenerative scapholunate ligament and status post a ganglionectomy with excess dorsal wrist capsule excision, it is plausible that an innocuous wrist injury could have caused the significant scapholunate diastasis. Regardless of the proximate cause, the management of acute SLIL instability is open reduction and anatomic reduction with pinning.[11]

Considering our case and the literature, it seems prudent to avoid damage to the SLIL if at all possible during ganglion excision. The absence of preoperative wrist symptomatology does not guarantee a healthy and robust SLIL. At present, no clear risk factors can be identified to predict the potential complication of

scapholunate instability following ganglion excision. Further studies on scapholunate instability may identify the risk factors associated with this complication, which surgeons should be aware of.

REFERENCES

1. **Angelides AC, Wallace PF.** The dorsal ganglion of the wrist. Its pathogenesis, gross and microscopic anatomy, and surgical treatment. *J Hand Surgery*. 1976; 1: 228-235.
2. **Nelson CL, Sawmiller S, Phalen G.** Ganglions of the wrist and hand. *J Bone and Joint Surgery.* 1972; 54A: 1459-1464.
3. **Watson KH, Rogers WD, Ashmead IV D.** Re-evaluation of the cause of the wrist ganglion. *J Hand Surgery*. 1989; 14A: 812-817.
4. **Clay NR, Clement DA.** The treatment of dorsal wrist ganglia by radical excision. *J Hand Surgery*. 1988; 13B: 187-191.
5. **Duncan KH, Lewis RC.** Scapholunate instability following ganglion cyst excision—A case report. *Clinical Orthopaedics and Related Research*. 1988; 228: 250-253.
6. **Crawford GP, Taleisnik J.** Rotatory subluxation of the scaphoid after excision of dorsal carpal ganglion and wrist manipulation—A case report. *J Hand Surgery*. 1983; 8: 921-925.
7. **Kivett WF, Wood FM, Rausher GE, Taschler NA.** Does ganglionectomy destabilize the wrist over the long term? *Annals of Plastic Surgery*. 1996; 36: 466-468.
8. **Berger RA, Blair WF, Crowninshield RD, Flatt AE.** The scapholunate ligament. *J Hand Surgery*, 1982; 7: 87-91.
9. **Kauer JMG.** Functional anatomy of the wrist. *Clinical Orthopaedics and Related Research*. 1980; 149: 9-20.
10. **Ruby LK, Linsheid RL, Cooney WP.** The effect of scapholunate ligament section on scapholunate motion. *J Hand Surgery*. 1987; 12A: 767-771.
11. **Richards RR.** Ligamentous reconstruction and substitution. In: Richards RR(Ed.) *Soft Tissue Reconstruction in the upper extremity*. New York, Churchill Livingstone Inc., 1995; 223-236.

FAMILIAL BILATERAL CARPAL TUNNEL SYNDROME IN A NIGERIAN FAMILY: CASE REPORT

Johnson D. Ogunlusi, FMCS (Ortho);[1] Lawrence M. Oginni, FMCS, FWACS[2]

CASE PRESENTATION

In a family in the southwestern part of Nigeria, eight out of nine siblings had classical features of bilateral carpal tunnel syndrome (CTS). Their mother, first cousin, and an aunt also had bilateral involvement of their hands. They all presented similarly with nocturnal wrist pain and paresthesias in the media nerve territory. Their occupations all varied, but included physician, teacher, engineer, zoologist, businessman and mechanic.

In total, three male and five females were affected. All were right handed and all were above 40 years of age at the time of presentation. Medically, the oldest of the patients had hypertension. Otherwise, there was no family or patient history of diabetes mellitus, myxedema, obesity, gout or rheumatoid arthritis. They were all generally fit and muscularly built. There was thenar muscle wasting in one patient (the medical doctor) who presented late. Five of the siblings underwent release of the bilateral carpal tunnels at one sitting. Four surgeries were performed within five months of onset of symptoms, and one at 14 months of onset of symptoms. The releases were all done by the same orthopaedic surgeon under tourniquet and involving the vertical division of the flexor retinaculum and transverse carpal ligament under direct visualization, through a 5-cm skin incision. The incision extended from the junction of proximal third and distal two-thirds of the thenar crease, along the ulnar border of the thenar crease, almost to the transverse skin crease of the wrist. Bandaging with collar and cuff was applied for 14 days. All the wounds healed primarily. Splinting was not done. Postoperative physiotherapy was performed after the incisions healed for two weeks, and for six months for the patient with thenar atrophy who presented late. There was complete recovery of the neuromuscular function of the hands in the four patients that presented early for surgery and there was residual atrophy in the patient that presented late with thenar atrophy. The history and the management outcomes of the patients are shown in Table 1.

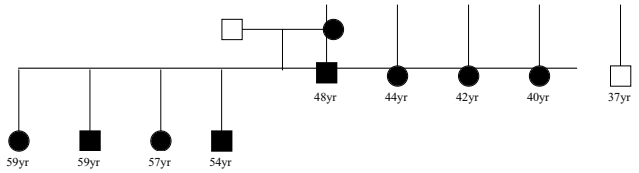

Figure 1. Family tree showing siblings and mother affected with CTS, and their ages at presentation.

DISCUSSION

The literature reveals that familial bilateral carpal tunnel syndrome may be a genetically distinct disorder.[1,2] In some reports, onset is in childhood.[3]

Familial bilateral carpal tunnel syndrome has been reported in siblings with mucolipidosis III (pseudo-Hurler polydystrophy).[4] Hereditary neuropathy with liability to pressure palsies (HNPP) is also a known cause of bilateral carpal tunnel syndrome in childhood, where the CTS may be the first manifestation of this systemic nerve pathology.[5] Swoboda et al. reported a case of a seven-month-old infant with familial CTS presenting with mutilated hands due to recurrent chewing of his digits in a median nerve distribution.[6] Gray et al. identified bilateral carpal tunnel syndrome in 19 out of 43 living persons of a nonconsanguineous family with no single common etiologic feature identified.[1] They suggested that an inheritable disorder transmitted by an autosomal dominant gene with high-degree penetrance might be responsible. Leifer et al. in Massachusetts reported two families with multiple members who had bilateral carpal tunnel syndrome, with a pattern consistent with autosomal dominance inheritance.[7] Stoll et al. in

[1] Department of Orthopaedics and Traumatology
Obafemi Awolowo University Teaching Hospitals Complex
Ile-Ife, Nigeria

[2] Department of Orthopaedics Surgery and Traumatology
Ile-Ife, Nigeria

Correspondence:
Dr. J. Ognlusi
Department of Orthopaedics Surgery and Traumatology
College of Health Sciences
Obafemi Awolowo University
Ile-Ife, Osun State Nigeria
Telephone: 23408055336926
Telefax: 23436230141
Email: gbemidare@yahoo.com

TABLE 1
The History and Management Outcome Bilateral Carpal Tunnel Syndrome in a Family

S/N in the famly	Age at presentation	Sex	Occupation	Associated disease	T M W at presentation	Bilateral Ct Release	Duration between onset & surgery	Outcome of Rx
1	59	F	Medical Practitioner	Hypertension	Present	+	14 months	Residual thenar muscles atrophy
2	59	M	Trading	Nil	Absent	+	4 months	Good Recovery
3	57	F	Teaching	Nil	Absent	-	-	-
4	54	M	Technician	Nil	Absent	+	2 months	Good Recovery
5	48	M	Agric Engineer	Nil	Absent	-	-	-
6	44	F	Teaching	Nil	Absent	+	4 months	Good Recovery
7	42	F	Teaching	Nil	Absent	+	3 months	Good Recovery
8	40	F	Zoologist	Nil	Absent	-	-	-

KEY
+ = Carpal Tunnel Release
- = No Carpal Tunnel Release yet
T M W= Thenar Muscles Wasting

Strasbourg, France reported a family with multiple early symptom onset with CTS between ages nine and 52 years of age, with an autosomal dominant inheritance pattern.[8] Braddom reported familial carpal tunnel syndrome, not bilateral, in seven members of three generations of a black African-American family in United States.[9] The ages of those affected ranged from 29 to 67 years.

Based on our search of the English-language literature, no case series of familial bilateral CTS has been reported in Africans in the literature. In our patients, traditional open carpal tunnel releases were performed. Bilateral releases were done at one surgical sitting to minimize the overall convalescence time, and surgical expenses. Bilateral releases have been reported to have acceptable outcomes in the literature.[10,11,12] It is also noteworthy that our patients presented with bilateral carpal tunnel symptoms at ages above forty. No genetic testing was performed for our patients. In general, our case and the literature reveal that familial bilateral carpal tunnel syndrome with autosomal dominant penetrance could present in patients in adulthood, not necessarily in children. The family history and past medical history of these patients needs to be evaluated in detail. In our case, there were no other obvious underlying familial medical conditions. Further basic science and genetic studies in such patients with familial bilateral carpal tunnel syndrome may someday help better understand the role of HNPP or some other underlying disorder.

REFERENCES

1. **Gray RG, Poppo MJ, Gottlieb NL.** Primary familial bilateral carpal tunnel syndrome. *Ann Intern Med.* 91(1):37-40, Jul. 1979.
2. **Vallat JM, Dunoyer J.** Familial carpal tunnel syndrome [Article in French]: *Sem Hop.* 54(17-20):661-2, Jun. 1978.
3. **Danta G.** Familial carpal tunnel syndrome with onset in childhood: *J Neurol Neurosurg Psychiatry.* 38(4):350-5, April 1975.
4. **Starreveld E, Ashenhurst EM.** Bilateral carpal tunnel syndrome in childhood. A report of two sisters with mucolipidosis III (pseudo-Hurler polydystrophy). *Neurology.* 25(3):234-8, March 1975.
5. **Cruz-Martinez A, Arpa J.** Pediatric bilateral carpal tunnel syndrome as first manifestation of hereditary neuropathy with liability to pressure palsies (HNPP). *Eur J Neurol.* 5(3):316-317, May 1998.
6. **Swoboda KJ, Engle EC, Scheindlin B, Anthony DC, Jones HR.** Mutilating hand syndrome in an infant with familial carpal tunnel syndrome. *Muscle Nerve.* 21(1):104-11, Jan. 1998.
7. **Leifer D, Cros D, Halperin JJ, Gallico GG 3rd, Pierce DS, Shahani BT.** Familial bilateral carpal tunnel syndrome: report of two families. *Arch Phys Med Rehabil.* 73(4):393-7, April 1992.
8. **Stoll C, Maitrot D.** Autosomal dominant carpal tunnel syndrome. *Clin Genet.* 54(4):345-8, Oct. 1998.
9. **Braddom RL.** Familial carpal tunnel syndrome in three generations of a black family. *Am J Phys Med.* 64(5): 227-34, Oct. 1985.

10. **Wang AA, Hutchinson DT, Vanderhooft JE.** Bilateral simultaneous open carpal tunnel release: a prospective study of postoperative activities of daily living and patient satisfaction. *J Hand Surg* [Am]. 28(5): 845-8, Sep. 2003.
11. **Weber RA, Boyer KM.** Consecutive versus simultaneous bilateral carpal tunnel release. *Ann Plast Surg.* 54(1): 15-9, Jan. 2005.
12. **Wilson JK, Sevier TL.** A review of treatment for carpal tunnel syndrome. *Disabil Rehabil.* 4; 25(3):113-9, Feb. 2003.